



QM

551

B677

1900

CORNELL UNIVERSITY.

THE

**Roswell P. Flower Library**

THE GIFT OF

ROSWELL P. FLOWER

FOR THE USE OF

THE N. Y. STATE VETERINARY COLLEGE.

1897



*This book was digitized by Microsoft Corporation in cooperation with Cornell University Libraries, 2007.*


*You may use and print this copy in limited quantity for your personal purposes, but may not distribute or provide access to it (or modified or partial versions of it) for revenue-generating or other commercial purposes.*











A TEXT-BOOK

OF

# HISTOLOGY

INCLUDING MICROSCOPIC TECHNIC

BY

A. A. BÖHM, M. D., and M. VON DAVIDOFF, M. D.

of the Anatomical Institute in Munich

Edited, with Extensive Additions to both Text and Illustrations

BY

G. CARL HUBER, M.D.

Junior Professor of Anatomy and Director of the Histological Laboratory  
University of Michigan

*Authorized Translation from the Second Revised German Edition*

BY

HERBERT H. CUSHING, M.D.

Demonstrator of Histology and Embryology, Jefferson Medical College, Philadelphia

---

WITH 351 ILLUSTRATIONS

---

PHILADELPHIA

W. B. SAUNDERS & COMPANY

LONDON: 161, STRAND, W. C.

1900

Digitized by Microsoft®

QM  
551  
B67t  
1900

~~B67t~~

COPYRIGHT, 1900,

By W. B. SAUNDERS & COMPANY

No 1721

---

PRESS OF  
W. B. SAUNDERS & COMPANY

TO THEIR TEACHER  
PROFESSOR C. VON KUPFFER  
THIS BOOK IS DEDICATED BY  
THE GRATEFUL AUTHORS

3

## EDITOR'S PREFACE.

---

THE "Text-book of Histology" by Böhm and v. Davidoff, as stated by the authors in the preface to the first edition, presents as fully as possible, from both the theoretic and technical standpoints, the subject-matter of the lectures and courses in histology given to students in the University of Munich. The authors further state that in the completion of their work they had the constant aid and advice of Professor von Kupffer, and had at their disposal the sections in the collection of the histologic laboratory in Munich, which were freely used in the selection and preparation of the illustrations accompanying the text.

The excellence of the text and illustrations of the German edition, attested by all familiar with the work, and the cordial reception which it has received from both students and investigators, justify the belief that an English translation will meet with approval from American and English teachers and students.

In the preparation of this American edition the editor has retained substantially all the subject-matter and illustrations of the second German edition, although certain minor changes in the arrangement of the text seemed desirable. Additions to the German text have been freely made. The sections on the Motor and Sensory Nerve-endings and on the Spinal and Sympathetic Ganglia have been greatly expanded, and the Innervation of Glands and Organs has been considered much more fully than in the original. Our knowledge of the normal function of tissues and organs is so dependent on a correct understanding of their innervation that this subject seemed deserving of fuller consideration than is generally given it in text-books of this scope. The glands with internal secretion have also been considered more fully than in the original text, their importance necessitating such treatment. More than one hundred illustrations, the majority of them from original drawings, have also been added. In making these and other minor additions the editor has striven to stamp his own work with the excellent features of the German text, and trusts that his endeavors may have added to the usefulness of the book.

The editor acknowledges with pleasure his indebtedness to Dr. Herbert H. Cushing for his excellent and accurate translation, and for suggestions received from him. The publishers, Messrs. Saunders & Company, have shown throughout the greatest interest in the work, and deserve the gratitude of the editor for their ready acquiescence in all suggestions made by him, for the excellent reproduction of his drawings, and for the suggestions made to him. The editor is particularly indebted to his able assistant, Dr. Lydia M. De Witt, for valuable assistance rendered, more especially in the tedious work of proof-correction, for which he expresses his sincere appreciation and gratitude.

G. CARL HUBER.

UNIVERSITY OF MICHIGAN, ANN ARBOR, MICH.  
*October, 1900.*



# CONTENTS.

## INTRODUCTION TO MICROSCOPIC TECHNIC.

	PAGE
Microscope and Its Accessories . . . . .	17
Microscopic Preparations . . . . .	20
Fixing Methods . . . . .	22
Infiltration and Imbedding . . . . .	25
Paraffin . . . . .	26
Celloidin . . . . .	28
Celloidin-paraffin . . . . .	30
Microtomes and Sectioning . . . . .	30
Further Treatment of the Section . . . . .	38
Fixation to the Slide and Removal of Paraffin . . . . .	38
Staining . . . . .	40
Section Staining . . . . .	40
Staining in Bulk . . . . .	45
Preparation of Permanent Specimens . . . . .	46
Introduction to Methods of Injection . . . . .	48

## GENERAL HISTOLOGY.

### I. THE CELL.

Cell-body . . . . .	52
Nucleus . . . . .	55
Nuclear and Cell-division . . . . .	56
Mitosis or Karyokinesis (Indirect Cell-division) . . . . .	57
Prophases . . . . .	60
Metaphases . . . . .	62
Anaphases . . . . .	63
Telophases . . . . .	64
Heterotypic Form of Mitosis . . . . .	64
Amitosis . . . . .	64
Process of Fertilization . . . . .	65
Chromatolysis . . . . .	68
Technic for the Cell . . . . .	68

### II. TISSUES.

Epithelial Tissues . . . . .	74
Simple Epithelium . . . . .	76
Simple Squamous Epithelium . . . . .	76
Simple Cubic Epithelium . . . . .	76
Simple Columnar Epithelium . . . . .	76
Pseudostratified Columnar Epithelium . . . . .	77
Stratified Epithelium . . . . .	77
Stratified Squamous Epithelium . . . . .	78
Transitional Epithelium . . . . .	79
Stratified Columnar Epithelium . . . . .	79
Glandular Epithelium . . . . .	81
Gland-cell . . . . .	81
General Consideration of the Structure and Classification of Glands . . . . .	82

	PAGE
Epithelial Tissues—Glandular Epithelium ( <i>Continued</i> ).	
Remarks on the Process of Secretion . . . . .	85
Neuro-epithelium . . . . .	85
Mesothelium and Endothelium . . . . .	85
Technic for Epithelial Tissues . . . . .	87
Connective Tissues . . . . .	89
Mucous Connective Tissue . . . . .	92
Reticular Connective Tissue . . . . .	92
Fibrous Connective Tissue . . . . .	93
Adipose Tissue . . . . .	99
Cartilage . . . . .	99
Bone . . . . .	103
Structure of Bone . . . . .	103
Development of Bone . . . . .	107
Technic for Connective Tissues . . . . .	117
Muscular Tissues . . . . .	123
Nonstriated Muscle-cells . . . . .	124
Striped Muscle-fibers . . . . .	124
Cardiac Muscle-cells . . . . .	132
Technic for Muscular Tissue . . . . .	132
Nervous Tissues . . . . .	133
Nerve-cells or Ganglion Cells; Cell-bodies of Neurones . . . . .	134
Nerve-fibers . . . . .	142
Peripheral Nerve Terminations . . . . .	147
Technic for Nervous Tissues . . . . .	164

## SPECIAL HISTOLOGY.

### I. BLOOD AND BLOOD-FORMING ORGANS, HEART, BLOOD-VESSELS, AND LYMPH-VESSELS.

Blood and Lymph . . . . .	168
Formation of Blood . . . . .	168
Red Blood-corpuscles . . . . .	169
White Blood-corpuscles . . . . .	173
Blood Platelets and Blood Plasma . . . . .	176
Behavior of Blood-cells in the Blood Current . . . . .	177
Lymphoid Tissue, Lymph-nodules, and Lymph-glands . . . . .	177
Spleen . . . . .	180
Bone-marrow . . . . .	185
Thymus Gland . . . . .	188

### II. CIRCULATORY SYSTEM.

Vascular System . . . . .	190
Heart . . . . .	190
Blood-vessels . . . . .	193
Arteries . . . . .	194
Veins . . . . .	197
Capillaries . . . . .	198
Anastomoses, Retia Mirabilia, and Sinuses . . . . .	199
Lymphatic System . . . . .	200
Lymph-vessels . . . . .	200
Lymph-capillaries, Lymph-spaces, and Serous Cavities . . . . .	201
Carotid Gland (Glandula Carotica, Glomus Caroticum) . . . . .	202
Technic for Blood and Blood-forming Organs . . . . .	203
Technic for Circulatory System . . . . .	210

### III. DIGESTIVE ORGANS.

Oral Cavity . . . . .	211
Teeth . . . . .	213
Structure of the Adult Tooth . . . . .	213

Oral Cavity—Teeth ( <i>Continued</i> ).	PAGE
Development of the Teeth . . . . .	217
Tongue . . . . .	221
Lingual Mucous Membrane and Its Papillæ . . . . .	221
Taste-buds . . . . .	223
Lymph-follicles of the Tongue (Folliculi Linguales) and the Tonsils . . . . .	225
Glands of the Oral Cavity . . . . .	227
Salivary Glands . . . . .	228
Parotid Gland (Serous Gland) . . . . .	228
Sublingual Gland (Mucous Gland) . . . . .	228
Submaxillary Gland (Mixed Gland) . . . . .	230
Small Glands of the Mouth . . . . .	231
Pharynx and Esophagus . . . . .	233
Stomach and Intestines . . . . .	235
General Structure of the Intestinal Mucous Membrane . . . . .	235
Stomach . . . . .	237
Small Intestine . . . . .	243
Large Intestine, Rectum, and Anus . . . . .	249
Blood, Lymph, and Nerve Supply of the Intestine . . . . .	251
Secretion of the Intestine and the Absorption of Fat . . . . .	256
Liver . . . . .	257
Pancreas . . . . .	265
Technic for Digestive Organs . . . . .	269

**IV. ORGANS OF RESPIRATION.**

Larynx . . . . .	275
Trachea . . . . .	276
Bronchi, their Branches, and the Bronchioles . . . . .	277
Respiratory Bronchioles, Alveolar Ducts, and Infundibula . . . . .	279
Thyroid Gland . . . . .	284
Parathyroid Glands . . . . .	285
Technic for Organs of Respiration . . . . .	286

**V. GENITO-URINARY ORGANS.**

Urinary Organs . . . . .	287
Kidney . . . . .	287
Pelvis of the Kidney, Ureter, and Bladder . . . . .	300
Suprarenal Glands . . . . .	301
Technic for Urinary Organs and Suprarenal Body . . . . .	305
Female Genital Organs . . . . .	306
Ovum . . . . .	306
Ovary . . . . .	306
Fallopian Tubes, Uterus, and Vagina . . . . .	316
Male Genital Organs . . . . .	323
Spermatozoon . . . . .	323
Testes . . . . .	324
Excretory Ducts . . . . .	329
Spermatogenesis . . . . .	334
Technic for Reproductive Organs . . . . .	340

**VI. THE SKIN AND ITS APPENDAGES.**

Skin (Cutis) . . . . .	341
Hair . . . . .	350
Nails . . . . .	355
Glands of the Skin . . . . .	357
Sweat-glands . . . . .	357
Sebaceous Glands . . . . .	358
Mammary Glands . . . . .	359
Technic for the Skin and Its Appendages . . . . .	362

**VII. THE CENTRAL NERVOUS SYSTEM.**

Spinal Cord . . . . .	365
Cerebellar Cortex . . . . .	372

	PAGE
Cerebral Cortex . . . . .	375
Olfactory Bulb . . . . .	379
Epiphysis and Hypophysis . . . . .	380
Ganglia . . . . .	382
General Survey of the Relations of the Neurones to One Another in the Central Nervous System . . . . .	389
Neuroglia . . . . .	392
Membranes of the Central Nervous System . . . . .	393
Blood-vessels of the Central Nervous System . . . . .	397
Technic for Central Nervous System . . . . .	397

**VIII. EYE.**

General Structure . . . . .	407
Development of the Eye . . . . .	407
Tunica Fibrosa Oculi . . . . .	409
Sclera . . . . .	409
Cornea . . . . .	410
Vascular Tunic of the Eye . . . . .	412
Choroid, Ciliary Body, and Iris . . . . .	412
Internal or Nervous Tunic of the Eye . . . . .	418
Pigment Layer . . . . .	418
Retina . . . . .	418
Region of the Optic Papilla . . . . .	420
Region of the Macula Lutea . . . . .	421
Ora Serrata, Pars Ciliaris Retinæ, and Pars Iridica Retinæ . . . . .	422
Müller's Fibers of the Retina . . . . .	422
Relations of the Elements of the Retina to One Another . . . . .	423
Optic Nerve . . . . .	425
Blood-vessels of the Optic Nerve and Retina . . . . .	426
Vitreous Body . . . . .	427
Crystalline Lens . . . . .	428
Fetal Blood-vessels of the Eye . . . . .	429
Interchange of Fluids in the Eyeball . . . . .	429
Protective Organs of the Eye . . . . .	430
Lids and Conjunctiva . . . . .	430
Lacrimal Apparatus . . . . .	432
Technic for the Eye . . . . .	433

**IX. ORGAN OF HEARING.**

External Ear . . . . .	435
Middle Ear . . . . .	437
Internal Ear . . . . .	439
Utriculus and Sacculus . . . . .	441
Semicircular Canals . . . . .	442
Cochlea . . . . .	443
Organ of Corti . . . . .	447
Nerves and Blood-vessels of the Cochlea . . . . .	452
Development of the Labyrinth . . . . .	454
Technic for Organ of Hearing . . . . .	455

**X. ORGAN OF SMELL.**

Technic for Nasal Mucous Membrane . . . . .	457
---	-----

**XI. GENERAL CONSIDERATIONS OF THE SPECIAL SENSE-ORGANS.**

REFERENCES TO LITERATURE . . . . .	461
INDEX . . . . .	483

# ILLUSTRATIONS.

FIG.	PAGE
1. Microscope . . . . .	18
2. Box for imbedding tissues . . . . .	26
3. Laboratory microtome . . . . .	31
4. Sliding microtome of Jung . . . . .	33
5. Apparatus for cutting tissues frozen by carbon dioxide . . . . .	36
6. Movements in honing . . . . .	37
7. Diagram of cell (Huber) . . . . .	52
8. Cylindric ciliated cells from the primitive kidney of <i>Petromyzon planeri</i> . . . . .	53
9-19. Processes of mitotic cell- and nuclear division . . . . .	58, 59
20-27. Mitotic cell-division of fertilized whitefish eggs (Huber) . . . . .	60, 61
28. Mitotic division of cells in testis of salamander (Benda and Guenther) . . . . .	63
29-34. Process of fertilization (Boveri) . . . . .	66, 67
35. Pigment cell from the skin of the head of a pike . . . . .	71
36. Isolated cells of squamous epithelium (Huber) . . . . .	76
37. Surface view of squamous epithelium from skin of a frog . . . . .	76
38. Simple columnar epithelium from the small intestine of man (Huber) . . . . .	77
39. Pseudostratified columnar epithelium . . . . .	77
40. Stratified pavement epithelium . . . . .	78
41. Cross-section of stratified squamous epithelium from esophagus of man (Huber) . . . . .	78
42. Isolated transitional epithelial cells from bladder of man (Huber) . . . . .	79
43. Cross-section of transitional epithelium from the bladder of a young child (Huber) . . . . .	79
44. Stratified columnar epithelium . . . . .	80
45. Ciliated cells from bronchus of dog . . . . .	80
46. Cross-section of stratified ciliated columnar epithelium from trachea of rabbit (Huber) . . . . .	80
47. Goblet cells from bronchus of dog . . . . .	81
48. Simple tubular glands . . . . .	82
49. Excretory ducts and lumina of the secretory portion of a compound tubular gland . . . . .	83
50. Lumina of the secreting portion of a reticulated tubular gland . . . . .	83
51. Glandular classification . . . . .	83
52. Mesothelium from pericardium of rabbit (Huber) . . . . .	85
53. Mesothelium from mesentery of rabbit (Huber) . . . . .	86
54. Mesothelium from peritoneum of frog . . . . .	86
55. Mesothelium covering posterior abdominal wall of frog (Huber) . . . . .	86
56. Endothelial cells from small artery of mesentery of rabbit (Huber) . . . . .	86
57. Mesenchymatous tissue from the subcutis of a duck embryo . . . . .	89
58. White fibrils and bundles from teased preparation of a fresh tendon from tail of rat (Huber) . . . . .	91
59. Elastic fibers from ligamentum nuchæ of ox . . . . .	91
60. Reticular connective tissue from lymph-gland of man . . . . .	93
61. Areolar connective tissue from subcutaneous tissue of rat (Huber) . . . . .	94
62. Cell-spaces in the ground-substance of areolar connective tissue of young rat (Huber) . . . . .	94
63. Connective-tissue cells from pia mater of dog (Huber) . . . . .	94
64. Pigment cells found on the capsule of sympathetic ganglion of frog (Huber) . . . . .	95
65. Leucocyte of frog with pseudopodia . . . . .	95
66. Fibrous connective tissue from great omentum of rabbit . . . . .	96
67. Longitudinal section of tendon . . . . .	97
68. Cross-section of secondary tendon bundle from tail of rat (Huber) . . . . .	97
69. Tendon cells from tail of rat (Huber) . . . . .	98
70. Cross-section of ligamentum nuchæ of ox (Huber) . . . . .	98
71. Fat-cell . . . . .	99

FIG.	PAGE
72. Hyaline cartilage . . . . .	100
73. Section through cranial cartilage of squid . . . . .	100
74. Insertion of the ligamentum teres into the head of the femur . . . . .	101
75. Elastic cartilage from external ear of man . . . . .	102
76. Longitudinal section through a lamellar system (v. Ebner) . . . . .	104
77, 78. Lamellæ seen from the surface (v. Ebner) . . . . .	104
79. Segment of a transversely ground section from the shaft of a long bone, showing lamellar system . . . . .	105
80. Portion of a transversely ground disc from the shaft of a human femur . . . . .	106
81. Longitudinal section through a long bone of a lizard embryo . . . . .	108
82. Longitudinal section of the proximal end of a long bone of a sheep embryo . . . . .	109
83. Longitudinal section through area of ossification from long bone of human embryo (Huber) . . . . .	110
84. Longitudinal section through epiphysis of arm bone of sheep embryo . . . . .	113
85. Section through the lower jaw of an embryo sheep . . . . .	114
86. Cross-section of developing bone from leg of human embryo, showing endochondral and intramembranous bone development (Huber) . . . . .	115
87. Cross-section of shaft (tibia of sheep) . . . . .	116
88. Smooth muscle from intestine of cat . . . . .	124
89. Cross-section of striated muscle-fibers . . . . .	125
90. Muscle-fiber from ocular muscles of rabbit . . . . .	125
91. Striated muscle-fiber of frog, showing sarcolemma (Huber) . . . . .	125
92. Diagram of structure of fibrils of a striated muscle-fiber (Huber) . . . . .	125
93. Transverse section through striated muscle-fiber of rabbit . . . . .	126
94. Diagram of transverse striation in the muscle of an arthropod . . . . .	127
95. Striated muscle-fiber of man . . . . .	128
96. Cross-section through the trapezius muscle of man . . . . .	128
97. Branched, striated muscle-fiber from tongue of frog (Huber) . . . . .	129
98. Cross-section of rectus abdominis of child, under low magnification (Huber) . . . . .	130
99. Longitudinal section through the line of junction between muscle and tendon . . . . .	130
100, 101. Longitudinal and cross-section of muscle-fibers from the human myocardium . . . . .	131
102. Bipolar ganglion cell from the ganglion acusticum of a teleost . . . . .	135
103. Chromatophile granules of a ganglion cell from the Gasserian ganglion of a teleost . . . . .	136
104. Nerve-cell from the anterior horn of the spinal cord of an ox . . . . .	136
105. Motor neurones from anterior horn of the spinal cord of new-born cat (Huber) . . . . .	137
106. A nerve cell with branched dendrites (Purkinje's cell), from cerebellar cortex of rabbit . . . . .	137
107. Pyramidal cell from cerebral cortex of man . . . . .	138
108. Nerve-cell with dendrites ending in claw-like telodendria . . . . .	139
109. Ganglion cell with a T-shaped process . . . . .	139
110. Ganglion cell from Gasserian ganglion of rabbit (Huber) . . . . .	140
111. Ganglion cells from spinal ganglion of rabbit embryo . . . . .	140
112. Neurone from inferior cervical sympathetic ganglion of rabbit (Huber) . . . . .	141
113. Longitudinal section of nerve-fiber . . . . .	142
114. Transverse section through sciatic nerve of frog . . . . .	143
115. Medullated nerve-fibers from rabbit . . . . .	144
116. Remak's fibers from pneumogastric nerve of rabbit . . . . .	144
117. Diagram to show composition of a peripheral nerve-trunk (Huber) . . . . .	146
118. Cross-section through a peripheral nerve . . . . .	146
119. Peripheral motor neurone (Huber) . . . . .	148
120. Motor nerve-ending in voluntary muscle of rabbit (Huber-De Witt) . . . . .	149
121-125. Motor endings in striated voluntary muscles . . . . .	150
126. Motor nerve-ending in striated voluntary muscle of frog (Huber-De Witt) . . . . .	151
127. Motor nerve-ending on heart muscle-cells of cat (Huber-De Witt) . . . . .	151
128. Motor nerve-ending on involuntary nonstriated muscle-cell from intestine of cat (Huber-De Witt) . . . . .	151
129. Peripheral sensory neurone (Huber) . . . . .	152
130. Termination of sensory nerve-fibers in the mucosa and epithelium of urethra of cat (Huber) . . . . .	153
131. End-bulb of Krause from conjunctiva of man (Dogiel) . . . . .	154
132. Meissner's tactile corpuscle (Dogiel) . . . . .	155
133. Genital corpuscle from glans penis of man (Dogiel) . . . . .	156

FIG.	PAGE
134. Cylindric end-bulb of Krause from intermuscular fibrous tissue septum of cat (Huber)	157
135. Pacinian corpuscles from mesorectum of kitten (Sala)	158
136. Corpuscle of Herbst from bill of duck	159
137. Intrafusal muscle-fiber from neuromuscular nerve end-organ of rabbit (Huber)	160
138. Cross-section of a neuromuscular nerve end-organ from interosseous muscle of man (Huber)	160
139. Neuromuscular nerve end-organ from plantar muscles of dog (Huber-De Witt)	161
140. Neurotendinous nerve end-organ from rabbit (Huber-De Witt)	162
141. Cross-section of neurotendinous nerve end-organ of rabbit (Huber-De Witt)	163
142. Ranvier's crosses from sciatic nerve of rabbit	165
143. Medullated nerve-fiber from sciatic nerve of frog	165
144. Ganglion cell from anterior horn of spinal cord of calf	166
145. Human red blood-cells	170
146. Rouleau formation of human erythrocytes	170
147. Hemin, or Teichmann's crystals, from blood stains on a cloth (Huber)	170
148. Crenated human red blood-cells	170
149. Red blood-corpuscles subjected to the action of water	170
150. Red blood-corpuscles from various vertebrate animals	171
151. White blood-corpuscles from normal blood of man	173
152. Ehrlich's leucocytic granules	174
153. Solitary lymph-nodule from human colon	178
154. Section through mesenteric lymph-gland of cat, with injected blood-vessels	179
155. Section from human lymph-gland	180
156. Section through the human spleen	181
157. Lobule of the spleen (Mall)	183
158. Cells containing pigment, blood-corpuscles, and hemic masses from spleen of dog	184
159. Section through human spleen showing reticular fibrils	184
160. Cover-glass preparation from bone-marrow of dog	186
161. Section through human red bone-marrow	187
162. Small lobule from thymus of child, with well-developed cortex	189
163. Hassal's corpuscle and a small portion of medullary substance from thymus of child ten days old (Huber)	189
164. Cross-section of human carotid artery	194
165. Section through human artery, one of the smaller of the medium-sized	195
166. Precapillary vessels from mesentery of cat (Huber)	195
167. Cross-section of human internal jugular vein	196
168. Section of small human vein	197
169. Endothelial cells of capillary and precapillary from mesentery of rabbit (Huber)	198
170. Small artery from oral submucosa of cat with nerve-terminations	199
171. Section of a cell-ball from glomus caroticum of man	203
172. Fibrin from laryngeal vessel of child	207
173. Section through lower lip of man	212
174. Longitudinal section through a human tooth, showing lines of Retzius	214
175. Portion of ground tooth from man, showing enamel and dentin	215
176. Longitudinal section through human molar from the center of the enamel layer	216
177. Cross-section of human tooth, showing cement and dentin	217
178. Nerve termination in pulp of rabbit's molar (Huber)	218
179-182. Four stages in the development of tooth in sheep embryo	219
183. Portion of cross-section through developing tooth	220
184. Fungiform papilla from human tongue (Huber)	221
185. Cross-section of human tongue showing filiform papillæ	222
186. Longitudinal section of foliate papilla of rabbit, showing taste-buds (Huber)	223
187. Longitudinal section of a human circumvallate papilla	224
188. Schematic representation of a taste-goblet (Hermann)	225
189, 190. Section through tonsil of dog	226
191. Scheme of salivary gland	227
192. Section through salivary gland of rabbit, with injected blood-vessels	229
193. Section from parotid gland of man	230
194. Section of human sublingual gland	230
195. Alveoli from submaxillary gland of dog (Huber)	231
196. Section of esophagus of dog	234
197. Section of human esophagus, showing duct of mucous gland	235

FIG.		PAGE
198.	Epithelium of human stomach, covering fold of mucosa between two gastric crypts . . . . .	237
199.	Vertical section through fundus of human stomach . . . . .	238
200.	Gastric glands from fundus of stomach of young dog (Huber) . . . . .	238
201.	Section through junction of human esophagus and cardia . . . . .	239
202.	Vertical section through human pylorus . . . . .	240
203.	Section through human pylorus . . . . .	241
204.	Section through fundus of human stomach in condition of hunger . . . . .	242
205.	Section through fundus of human stomach during digestion . . . . .	242
206.	Section through mucous membrane of human small intestine . . . . .	244
207.	Longitudinal section through summit of villus from human small intestine . . . . .	245
208.	Section through the junction of the human pylorus and duodenum . . . . .	247
209.	Section of solitary lymph-nodule from vermiform appendix of guinea-pig . . . . .	248
210.	Section through colon of man, showing glands of Lieberkühn . . . . .	249
211.	Solitary lymph-follicle from human colon . . . . .	250
212.	Section through fundus of injected cat's stomach . . . . .	251
213.	Schematic transverse section of human small intestine (Mall) . . . . .	253
214.	Portion of the plexus of Auerbach from stomach of cat (Huber) . . . . .	254
215.	Section of esophagus of cat showing nerve-terminations (Huber) . . . . .	255
216.	Section through liver of pig, showing chains of liver-cells . . . . .	257
217.	Section through injected liver of rabbit . . . . .	258
218, 219.	Human bile capillaries . . . . .	259
220.	Diagram of hepatic cord in transverse section . . . . .	260
221.	Section through the human liver, showing the beginning of bile-ducts . . . . .	260
222.	Injected blood-vessels in liver lobule of rabbit . . . . .	261
223.	Reticulum of dog's liver . . . . .	262
224.	Connective tissue from liver of sturgeon, showing reticulum . . . . .	263
225.	Section through liver lobule from dog, showing stellate cells . . . . .	264
226.	Transverse section through alveolus of frog's pancreas . . . . .	265
227, 228.	Section through human pancreas . . . . .	266, 267
229.	Relation of three adjoining alveoli to excretory duct, illustrating origin of centro acinal cells . . . . .	268
230.	Section of human pancreas, showing gland alveoli surrounding an area of Langerhans (Huber) . . . . .	268
231.	Vertical section through mucous membrane of human larynx . . . . .	275
232.	Longitudinal section of human trachea (Huber) . . . . .	277
233.	Transverse section through human bronchus . . . . .	278
234, 235.	Sections of cat's lungs . . . . .	279
236.	Internal surface of human respiratory bronchiole (Kölliker) . . . . .	280
237.	Inner surface of human alveolus, showing respiratory epithelium (Kölliker) . . . . .	281
238.	Respiratory epithelium in amphibia . . . . .	282
239.	Section of human lung, showing elastic fibers (Huber) . . . . .	283
240.	Section through injected rabbit's lung . . . . .	283
241.	Section through thyroid gland of child . . . . .	284
242.	Section from parathyroid of man (Huber) . . . . .	286
243.	Kidney of new-born infant . . . . .	287
244.	Isolated uriniferous tubules . . . . .	288
245.	Median longitudinal section of adult human kidney . . . . .	289
246.	Section of cortical substance of human kidney . . . . .	290
247.	Section of proximal convoluted tubules from man . . . . .	291
248.	Epithelium from proximal convoluted tubule of guinea-pig, with surface and lateral views . . . . .	292
249.	Cortical portion of longitudinal section of kidney of child (Huber) . . . . .	292
250.	Section of medulla of human kidney . . . . .	293
251.	Longitudinal section through papilla of injected kidney . . . . .	294
252.	Section through junction of two lobules of kidney . . . . .	295
253.	Diagrammatic scheme of uriniferous tubules and blood-vessels of kidney . . . . .	297
254.	Direct anastomosis between an artery and vein in a column of Bertini of child . . . . .	298
255.	Section of lower part of human ureter . . . . .	300
256.	Section of suprarenal cortex of dog . . . . .	302
257.	Arrangement of intrinsic blood-vessels in cortex and medulla of dog's adrenal (Flint) . . . . .	303
258.	Section from ovary of adult dog (Waldeyer) . . . . .	307
259.	Section from ovary of young girl . . . . .	308
260-263.	Sections from cat's ovary . . . . .	310

FIG.	PAGE
264. Representation of behavior of the chromatin during the maturation of the ovum (Rückert) . . . . .	312
265. Scheme of the development and maturation of an ascaris ovum (Boveri) . . . . .	314
266. Section of fully developed Graafian follicle from pig . . . . .	315
267. Section of oviduct of young woman . . . . .	317
268. Section from uterus of young woman . . . . .	319
269. Section of human vagina (Huber) . . . . .	320
270. Section of human labia minora (Huber) . . . . .	321
271. Diagram showing characteristics of spermatozoa of vertebrates . . . . .	323
272. Human spermatozoa . . . . .	324
273. Longitudinal section through human testis and epididymis . . . . .	325
274, 275. Sustentacular cells . . . . .	326
276. Section of human testis (Huber) . . . . .	327
277. Section through human vasa efferentia . . . . .	328
278. Cross-section of vas epididymidis of human testis (Huber) . . . . .	328
279. Section of dog's testis with injected blood-vessels . . . . .	329
280. Cross-section of vas deferens near epididymis (human) (Huber) . . . . .	330
281. Cross-section of wall of seminal vesicle (human) (Huber) . . . . .	331
282. Section of prostate gland of man (Huber) . . . . .	331
283. Schematic diagram of spermatogenesis as it occurs in ascaris (Boveri) . . . . .	335
284. Schematic diagram of section through convoluted seminiferous tubule of mammal (Hermann) . . . . .	337
285. Section of convoluted tubule from rat's testicle . . . . .	338
286. Under surface of the epididymis . . . . .	342
287. Cross-section of skin of child with injected blood-vessels . . . . .	343
288. Prickle cells from the stratum Malpighii of man . . . . .	344
289. Cross-section of human epidermis . . . . .	345
290. Cross-section of negro's skin . . . . .	346
291. Nerves of epidermis and papillæ from ball of cat's foot . . . . .	348
292, 293. Meissner's corpuscle from man . . . . .	349
294. Grandry's corpuscles from duck's bill . . . . .	350
295. Longitudinal section of human hair and follicle . . . . .	352
296. Cross-section of human hair with follicle . . . . .	353
297. Longitudinal section of cat's hair and follicle, showing nerve-termination . . . . .	354
298. Longitudinal section through human nail and its groove . . . . .	355
299. Transverse section through human nail and its sulcus . . . . .	356
300. Cross-section of coiled tubule of sweat-glands from human axilla . . . . .	357
301. Tangential section through coiled tubule of sweat-glands from human axilla . . . . .	357
302. Section of alveoli from sebaceous gland of human scalp (Huber) . . . . .	359
303. Section of mammary gland of nullipara (Nagel) . . . . .	360
304. Transverse section through human skin . . . . .	363
305. Cross-sections of human spinal cord . . . . .	366
306. Schematic diagram of spinal cord in cross-section (von Lenhossék) . . . . .	368
307. Schematic cross-section of spinal cord (Ziehen) . . . . .	369
308. Section through human cerebellar cortex vertical to the surface of the convolution . . . . .	372
309. Schematic diagram of cerebellar cortex . . . . .	373
310. Cell of Purkinje from human cerebellar cortex . . . . .	374
311. Granular cell from the granular layer of the human cerebellar cortex . . . . .	374
312. Schematic diagram of cerebral cortex . . . . .	377
313. Large pyramidal cell from human cerebral cortex . . . . .	377
314. Schematic diagram of cerebral cortex . . . . .	378
315. Olfactory bulb . . . . .	380
316. Longitudinal section of spinal ganglion of cat (Huber) . . . . .	382
317. Ganglion cell from the Gasserian ganglion of a rabbit (Huber) . . . . .	383
318. Diagram showing the relations of the neurones of a spinal ganglion (Dogiel) . . . . .	384
319. Neurone from inferior cervical sympathetic ganglion of a rabbit (Huber) . . . . .	385
320. From section of semilunar ganglion of cat (Huber) . . . . .	386
321. From section of stellate ganglion of dog (Huber) . . . . .	387
322. From section of sympathetic ganglion of turtle (Huber) . . . . .	388
323. From section of sympathetic ganglion of frog (Huber) . . . . .	388
324. Schematic diagram of a sensorimotor reflex arc according to the modern neurone theory . . . . .	389
325. Schematic diagram of a sensorimotor reflex cycle . . . . .	390
326. Schematic diagram of the reflex tracts between a peripheral organ and the brain cortex . . . . .	391

FIG.	PAGE
327. Neuroglial cells (Huber) . . . . .	392
328. Section through injected cerebral cortex of rabbit . . . . .	395
329. Schematic diagram of the eye (Leber and Flemming) . . . . .	408
330. Section through the anterior portion of human cornea . . . . .	410
331. Corneal spaces of dog . . . . .	411
332. Section through the human choroid . . . . .	413
333. Meridional section of the human ciliary body . . . . .	415
334. Injected blood vessels of the human choroid and iris . . . . .	417
335. Section of the human retina . . . . .	419
336. Section through point of entrance of human optic nerve . . . . .	421
337. Section through human macula lutea and fovea centralis . . . . .	421
338. Schematic diagram of the retina (Ramón y Cajal) . . . . .	424
339. Injected blood-vessels of the human retina . . . . .	426
340. Injected blood-vessels of human macula lutea . . . . .	426
341. Cross-section of upper eyelid of man . . . . .	431
342. Schematic representation of the complete auditory apparatus (Schwalbe) . . . . .	436
343. Cross-section of the Eustachian tube . . . . .	438
344. Right bony labyrinth (Quain, after Sömmering) . . . . .	439
345. Membranous labyrinth from five-month human embryo (Schwalbe, after Retzius) . . . . .	440
346. Transverse section through an osseous and membranous semicircular canal of an adult human being . . . . .	441
347. Vertical section through the anterior ampulla . . . . .	443
348. Section through a turn of the osseous and membranous cochlear duct of the cochlea of guinea-pig . . . . .	445
349. Organ of Corti (Retzius) . . . . .	448
350. Surface of organ of Corti, with surrounding structures (Retzius) . . . . .	451
351. Scheme of distribution of blood-vessels in labyrinth (Eichler) . . . . .	453

# INTRODUCTION TO MICROSCOPIC TECHNIC.

## I. THE MICROSCOPE AND ITS ACCESSORIES.

A detailed description of the microscope and its accessory apparatus hardly lies within the scope of this book. If, notwithstanding, a few points be touched upon, it is done only that the beginner may have a working knowledge of the different parts of the instrument which he must use. A more intimate knowledge of the theory of the microscope may be acquired by studying such works as those of Dippel, A. Zimmermann, and Carpenter.

1. Histologic specimens are examined with the aid of the microscope, an instrument which magnifies the objects by means of its optic apparatus. For this purpose **simple microscopes**, consisting usually of a single lens, are not sufficient; the aid of the **compound microscope**, which contains a combination of two systems of lenses, is necessary. These systems may be changed according to the needs of the case, and thus a variation in the magnification of the object obtained. The rest of the instrument consists of a framework called the **stand**, the lower portion of which consists of a foot-plate or **base**, which should rest firmly on the table. From the base rises the column or **pillar**, to which the other parts of the microscope are attached. From below upward come the movable mirror, the stage and substage with diaphragm and condenser, and the tube with pinion and fine adjustment.

One side of the mirror is concave, and serves to concentrate the rays of light in the direction of a central opening in the stage. The other side is plane, and is seldom used. If the objects are to be examined by direct illumination, and not by transmitted light, the mirror is so placed that the rays are reflected away from the opening in the stage.

2. The specimen to be examined is placed on the stage, over the central opening. If the light be too strong, the opening may be diminished in size by means of a **diaphragm**. In some instruments these diaphragms are placed in the opening of the stage, and consist of plates with different sized apertures. A better form is composed of one large disc containing several apertures of different sizes. This is fastened to the under surface of the stage in such a way that by revolving the disc the apertures may be brought one

after the other opposite the opening in the stage. A much better diaphragm, constructed on an entirely different principle, is the so-called **iris diaphragm**. Although its opening is not exactly circular, yet it has the advantage of being easily enlarged or contracted by manipulating a small handle controlling the metal plates sliding over one another.

3. The **tube**, which is contained in a close-fitting metal sheath, is attached to the upright of the microscope. In the simpler forms

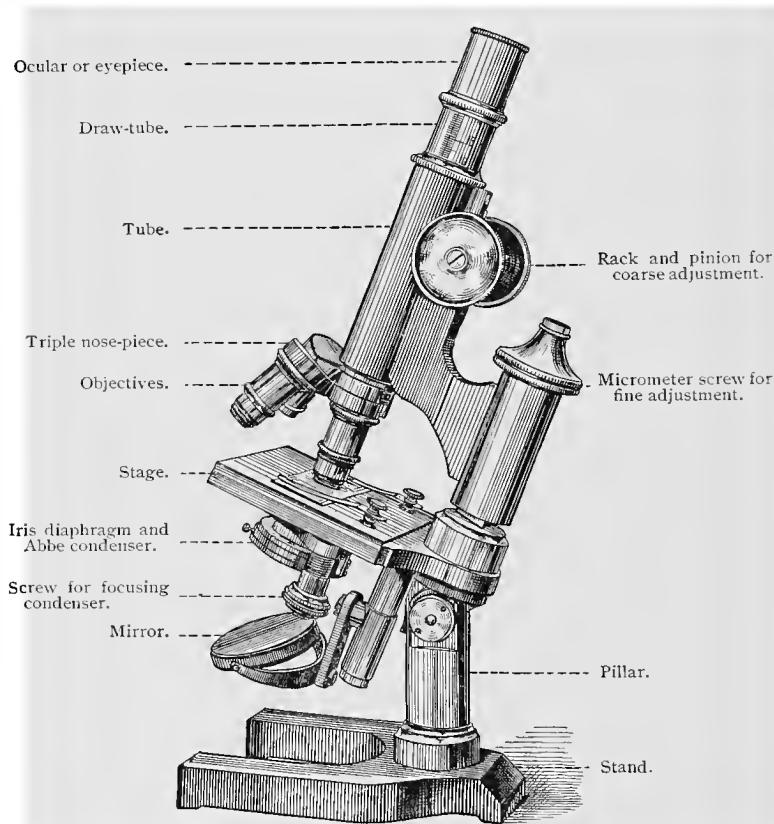


Fig. 1.—Microscope.

of microscopes the tube is raised, lowered, or twisted by hand. In more complicated instruments the upward and downward movements are accomplished by means of a rack and pinion—**coarse adjustment**. A micrometer screw—**fine adjustment**—situated at either the upper or the lower end of the upright, controls the fine adjustment. The tube possesses an upper and a lower opening, into which lenses may be laid and screwed.

4. The **ocular**, into the ends of which lenses are inserted, fits into

the upper opening. The upper is called the *ocular lens*, the lower the *collective lens*. The **objective system**, which is a combination of several lenses, the lowest and smallest of which is known as the *front lens*, is screwed into the lower opening of the tube.

5. All larger instruments possess several oculars and objectives, which together give different magnifications according to the combinations used. For most objects a magnification of 500 diameters is all that is required, but to obtain this and still have a clear and bright field the ordinary lenses are hardly sufficient. The greater the magnification, the darker is the field. To avoid this, illuminating mechanisms (**condensers**, Abbé's apparatus) have been constructed, by means of which the rays of light are concentrated and controlled. This arrangement is absolutely necessary for delicate work.

6. Even with the aid of such an apparatus the *dry objective systems* are not sufficient. With them the rays of light must pass through different media having various indices of refraction. The rays pass from the object through the cover-slip, and then through the air between the latter and the objective system. They are thus deflected in different directions—a defect which would be avoided if the rays were made to pass through a single medium. This latter condition may be practically brought about by placing between the objective and the cover-glass a drop of some fluid having about the same refractive index as the glass. The lens is then lowered into the fluid. As this invention has proved useful, so-called **immersion lenses** have been made during recent years.

7. There are thus two kinds of lens systems—the dry and the immersion lenses. The latter are divided into two groups—lenses with water and those with oil immersion. As oil has a greater index of refraction than water, and one more nearly approaching that of glass, the oil-immersion lenses are at present the best objectives that we possess. Karl Zeiss, of Jena, and other microscope makers, have in late years made lenses from a special sort of glass which reduces to a minimum the chromatic and spheric aberration of the rays of light in their passage through the objective (**apochromatic lenses**).

8. The rays of light reflected from the mirror and passing through the object are refracted by the objective system in such a way that they are focused in a so-called *real image* at a point about half-way up the tube. This picture is an inverted one, the right side of the microscopic field being at the left of the real image, and the upper portion below. The picture is, in other words, rotated 180 degrees. By means of the ocular the real image is again magnified—*virtual image*—but no longer inverted, although to the eye of the microscopist the field actually appears inverted. To shut out the rays of light, which cause a diffused picture, diaphragms are sometimes introduced into the tube as well as into the ocular.

9. The objects to be examined are placed upon a glass plate

called a **slide**. Microscopic slides are of different sizes, and are usually oblong in shape. Those in most common use are three inches long and an inch wide. The object is covered by a very much smaller and thinner glass plate—the **cover-slip**. The whole preparation is then placed upon the stage in such a way that the cover-slip is upward and immediately beneath the end of the tube. The mirror of the microscope is now so adjusted as to concentrate the rays of light on the preparation, illuminating it as much as is necessary. By means of the rack and pinion, or coarse adjustment, the whole tube is now slowly lowered toward the cover-slip until the bare outlines of the object are dimly seen in the white field. From this point on, the micrometer screw, or fine adjustment, is used in bringing the front lens down to its proper focal distance from the preparation. The object is now seen to be clear and well defined. By turning the screw to the right or the left, different parts of the specimen are brought more clearly into view, this result being due to the fact that not all points in the preparation are in the same plane.

10. In studying objects it is always well to draw them, using a sharpened pencil and smooth paper. The beginner soon finds that with constant practice he can sketch the different parts of the field in nearly their proper relationship. This by no means easy work is facilitated by the use of a drawing apparatus called the **camera lucida**. The best of these is that devised by Abbé. It is fastened to the upper end of the tube, above the ocular. The apparatus is so made that both the preparation and the drawing surface are seen by the same eye. The microscopic field is seen directly, while the drawing surface is made visible by means of a mirror. When the apparatus is in place and the drawing commenced, it appears to the one sketching as if his pencil were moving over the preparation itself. Outlines are reproduced on paper with great exactness both as to form and size; finer details must of course be sketched in free hand.

Every preparation should first be examined with a low power, and only after the student has studied the specimen as a whole and found instructive areas should the higher powers be used.

## II. THE MICROSCOPIC PREPARATION.

11. In many cases the making of a microscopic preparation is a very simple procedure, especially when fresh objects are to be examined. A drop of blood, for instance, may simply be placed upon a slide, covered with a cover-slip, and examined. Other objects, as the mesentery, thin transparent nerves, detached epithelia, spermatozoa, etc., need no further preparation, but may be examined at once.

12. Portions of larger organs are often studied after having been **teased**, which may be done by means of two needles fastened in handles. If the objects be composed of fibers running in parallel directions, one

needle is thrust into the substance to hold it in place, while the other is used to tear the fibers apart. This method is used in examining muscles, nerves, tendons, etc.

Some tissues are so constituted that they can only be investigated by means of **sections**, which permit a study of their elements and the relationship of the same to each other. In this method an ordinary razor, moistened in some fluid, may be employed. As a rule, it is not the size of the section, but the thinness, which is important. This latter is obtained only by practice. Every microscopist ought to become accustomed to making *free-hand sections* with the razor. It is the simplest of all methods, is very rapid, and is especially useful in the quick identification of a tissue. In cutting fresh so-called parenchymatous tissues, such as liver and kidney, an ordinary razor is not sufficient. Here a **double knife** is necessary. This consists of two blades, which are so placed one above the other that their distal ends touch, while their proximal ends are slightly separated. The distance of the blades from each other is regulated by a screw. If this be removed the knives may be separated for cleaning. In making sections, only those portions of the blades are of importance which are very close together but do not actually touch. Sections are cut by drawing the moistened instrument quickly through an organ, as, for instance, a fresh liver. As the organ is cut in two, a very thin section of the tissue remains between the blades. This is removed by taking out the screw and separating the blades in normal salt solution. Organs of a similar consistence can be frozen and then cut with an ordinary razor the blade of which has been cooled. Sometimes good results may be obtained by drying small pieces of tissue, as, for instance, tendon.

13. As sections or small pieces of fresh tissue would soon become dry when placed on the slide, they must be kept moist during examination. They are therefore **mounted** in so-called **indifferent fluids** (placed on the slide and immersed in a few drops of the indifferent fluid and covered with a cover-slip). These have the power of preserving even living organs for some time without change. Such fluids, for instance, are the lymph, the aqueous humor, serous fluids, amniotic fluid, etc. Artificial indifferent fluids are much used and should always be kept in stock. Of this class, the following are useful:

1. Physiologic saline solution: A 0.75% solution of sodium chlorid in distilled water.
2. Schultze's iodized serum: A saturated solution of iodine or tincture of iodine in amniotic fluid.
3. Ranvier's solution of iodine and potassium iodid: A saturated solution of iodine in a 2% solution of potassium iodid.
4. Kronecker's fluid: Distilled water, 100 c.c.; sodium chlorid, 6 gm.; sodium carbonate, 0.06 gm.
5. Solution of Ripart and Petit: Copper chlorid, 0.3 gm.; copper acetate, 0.3 gm.; aqua camphoræ, 75 c.c.; distilled water, 75 c.c.; and glacial acetic acid, 1 c.c. After mixing, this solution is yellow, but clears up within a few hours, and should then be filtered.

14. The examination of fresh tissues comes far from revealing all the finer details of their structure. This is partly due to the fact that the indices of refraction of the different elements of the tissues are too nearly

alike, in consequence of which the outlines are somewhat dimmed; and also, that changes occur, even during the most careful manipulation of the tissues, which result in pictures somewhat different from the normal.

These difficulties may be lessened by the use of **fixing fluids**. By these we mean those reagents which we know by experience possess the power of preserving entirely fresh (living) tissues or organs in such a way that accurate conclusions as to their condition and qualities during life may be obtained. Even this can be attained only after a careful series of control observations. In general, fixing fluids act differently on different tissues, some preserving better one set of elements, while others give better results with another set. It is therefore always advisable to fix in different fluids pieces of the tissues or organs to be examined.

### A. FIXING METHODS.

The fixing fluids most used for general purposes are the following:

**15. Alcohol.**—The most common fixing fluid is alcohol. It is at the same time a hardening fluid, as the water of the tissues is withdrawn and their albumin coagulated. Small or thin pieces are put immediately into absolute alcohol, in which they remain for from twelve to twenty-four hours. The period required for fixation may be greatly shortened by changing the absolute alcohol at the end of one or two hours. In the case of larger pieces, a successive immersion in gradually increasing strengths of alcohol (50%, 70%, 90%) is the method chosen. Pieces 1 c.c. in size remain for twenty-four hours in each grade of alcohol, larger pieces for a proportionately longer time. Alcohol used in this way is a hardening fluid rather than a fixing fluid.

**16. Osmic acid** is a reagent that kills quickly, fixes exceedingly well, and even colors certain tissues. Only small pieces can be fixed in this fluid, as it does not easily penetrate the tissues. It is ordinarily used in a 1% aqueous solution, the objects remaining immersed twenty-four hours. They are then washed in running water for the same length of time, after which they are transferred to 90% alcohol. Very small objects may be treated with osmic acid in the form of vapor (vaporization). This is done as follows: A very small quantity of osmic acid solution is put in a small dish. The object is then suspended by a thread in such a way that it does not come in contact with the fluid. The dish should be covered with a well-fitting lid.

**17. Flemming's Solution.**—A solution with a similar action, but fixing nuclear structures even better than osmic acid, is the chromic-osmic-acetic acid solution of Flemming (82):

Osmic acid, 1% aqueous solution	10 parts.
Chromic acid, 1% aqueous solution	25 "
Glacial acetic acid, 1% aqueous solution	10 "
Distilled water	55 "

Small pieces are fixed in a small quantity of the fluid for at least twenty-four hours, sometimes for a longer period, extending even to weeks. They are then washed for twenty-four hours in running water and passed through 70% and 80%, each twenty-four hours, into 90% alcohol.

Flemming (84) also recommends a stronger solution, which is made as follows:

Osmic acid, 2% aqueous solution . . .	4 parts.
Chromic acid, 1% aqueous solution . . .	15 "
Glacial acetic acid . . . . .	1 part.

**Fol's Solution.**—Fol has recommended the following modification of Flemming's solution :

Osmic acid, 1% aqueous solution . . .	2 parts.
Chromic acid, 1% aqueous solution . . .	25 "
Glacial acetic acid, 2% aqueous solution . . .	5 "
Distilled water . . . . .	68 "

In fixing with osmic acid and its mixtures it is always advisable to transfer the objects from water into a weak alcohol (50%), as by this means the shrinking and tearing of the tissues which sometimes occur on account of the too rapid diffusion between the water and alcohol are avoided.

**18. Hermann's Solution.**—Very good results sometimes follow the use of the platinum-acetic-osmic acid solution of Hermann (89, 1). It is employed as is Flemming's solution :

Osmic acid, 2% aqueous solution . . .	4 parts.
Platinum chlorid, 1% aqueous solution . . .	15 "
Glacial acetic acid . . . . .	1 part.

After fixing with this solution, Flemming's solution, or any other osmic mixture, the subsequent treatment with alcohol may be followed by crude pyroligneous acid. The objects are placed for from twelve to twenty-four hours in the latter and then again immersed in alcohol. The result is a peculiar coloring of the specimen which often makes subsequent staining (see below) unnecessary (Hermann).

**19. Corrosive Sublimate.**—An excellent fixing fluid is made by saturating distilled water or a physiologic saline solution (see p. 21) with corrosive sublimate; saline solutions keep better. Small pieces, about 0.5 cm. in diameter, are immersed in this fluid for from three to twenty-four hours, are then washed in running water for twenty-four hours, and then transferred into 70% alcohol. After twenty-four hours the tissues are placed in 80% for the same length of time, and then preserved in 90% alcohol. It often occurs that after changes in temperature crystals of sublimate are formed on the surface or in the interior of the object. For their removal a few drops of a solution of iodine and potassium iodide are added to the alcohol (P. Mayer, 87). It is a matter of indifference whether the 70%, 80% or 90% alcohol is thus iodized. In the further treatment of the object, as well as in sectioning, any such crystals of sublimate will not be found to be a hindrance. Indeed, in the case of very delicate objects it is often more advantageous to undertake their removal *after* sectioning by adding iodine to the absolute alcohol then used.

**20. Picric Acid.**—Small and medium-sized objects (up to 1 c.c.) are fixed in twenty-four hours in a saturated aqueous solution of picric acid (about 0.75%), although an immersion lasting for weeks is not detrimental, especially if the objects be of considerable size. The tissues are transferred to 70% or 80% alcohol, in which they remain until the alcohol is not colored by the picric acid. They are then preserved in 90% alcohol.

**21.** Instead of a pure solution of picric acid, the **picrosulphuric acid** of Kleinenberg or the **picric-nitric acid** of P. Mayer (81) may be used.

The first is made thus: 1 c.c. of concentrated sulphuric acid is added to 100 c.c. of a saturated aqueous picric acid solution. This is allowed to stand for twenty-four hours, then filtered, and diluted with double its volume of distilled water. The picric-nitric acid solution is made by adding 2 c.c. of pure nitric acid to 100 c.c. of a saturated picric acid solution. Filter after standing for twenty-four hours.

**22. Rabl's Solutions.**—C. Rabl (94) recommends the following mixtures, especially for embryos: (1) Concentrated aqueous solution of corrosive sublimate, 1 vol.; concentrated aqueous solution of picric acid, 1 vol.; distilled water, 2 vols. (2) 1 per cent. aqueous solution of platinum chlorid, 1 vol.; concentrated aqueous solution of corrosive sublimate, 1 vol.; distilled water, 2 vols. In both cases, after being washed twelve hours in water (in the first preferably in alcohol) the specimens are transferred to gradually increased strengths of alcohol.

**23. Acetic Sublimate Solution.**—This is an excellent fluid, and at present much used for embryonic tissues and for organs containing only a small quantity of connective tissue. To a saturated aqueous solution of sublimate, 5% to 10% of glacial acetic acid is added. After remaining two or three hours or more in this solution, the objects are transferred to 35% alcohol, after which they are passed through the higher grades.

**24.** O. vom Rath (95) recommends, among others, the following two solutions: (1) **Picric-osmic-acetic acid solution.** Add to 1000 c.c. of a cold saturated picric acid solution 1 gm. of osmic acid, and after several hours 4 c.c. of glacial acetic acid. Objects are fixed, according to their size, in four, fourteen, and forty-eight hours, and then transferred to 75% alcohol. (2) **Picric-sublimate-osmic acid solution.** A mixture of 100 c.c. of a cold saturated aqueous picric acid solution with 100 c.c. of saturated sublimate solution is made, into which is poured 20 c.c. of a 2% osmic acid solution. 2 c.c. of glacial acetic acid may also be added. Tissues fixed by either of these fluids may be treated with pyroligneous acid or tannin. The crystals of sublimate must be removed by iodized alcohol.

**25. Nitric Acid.**—Small objects may be fixed in about six hours in 3% to 5% nitric acid (sp. gr. 1.4). A longer immersion is injurious, as certain nuclear structures are affected. After washing thoroughly in running water, the tissues are treated as usual with alcohols of increasing concentration.

**26. Chromic acid** is used in a  $\frac{1}{3}$ % to 1% aqueous solution. Small pieces are fixed for twenty-four hours, larger ones for a longer time, even weeks. The quantity of the fixing fluid should be at least more than fifty times the volume of the tissues to be fixed. The objects are subsequently washed in running water and run through the ascending alcohols. This last should be done in the dark.

Two or 3 drops of formic acid may be advantageously added to each 100 c.c. of chromic acid solution (C. Rabl, 85).

**27. Müller's Fluid.**—

Potassium bichromate . . . . .	2 to 2.5 gm.
Sodium sulphate . . . . .	1 "
Water . . . . .	100 c.c.

With this solution it requires several weeks for proper fixation, and the process must be conducted in the dark. During the first few weeks the solution should be changed every few days, and later once a week.

According to the results desired, the pieces are either washed out in running water and subsequently treated in the usual manner with alcohol, or they are placed directly in 70%, which is later replaced by 80% and 90% alcohol. It is important that all these procedures should take place in the dark.

### 28. Zenker's Fluid.—

Potassium bichromate . . . . .	2.5 gm.
Sodium sulphate . . . . .	1 "
Corrosive sublimate . . . . .	5 "
Glacial acetic acid . . . . .	5 c.c.
Water . . . . .	100 "

It is advisable to add the glacial acetic acid in proper proportion to the quantity of the solution to be used, and not to add it to the stock solution. The tissues are allowed to remain for from six to twenty-four hours in this mixture, in which they float for a short time. They are then washed in running water for from twelve to twenty-four hours, and transferred to gradually concentrated alcohols. Crystals of sublimate which may be present are removed with iodized alcohol. Zenker's fluid penetrates easily, and fixes nuclear and protoplasmic structures equally well without decreasing the staining qualities of the elements.

29. The use of **Erlick's fluid** (potassium bichromate, 2½ gm.; cupric sulphate, 0.5 gm., and water, 100 c.c.) is quite similar to that of Müller's, except that it acts much more quickly. A temperature of 30° C. to 40° C. shortens the process in both cases considerably, Müller's fluid fixing in eight and Erlick's in three days.

30. **Formalin (Formol)**.—Of recent years formalin, which is a 40% solution of the gas formaldehyd in water, has been much used as a fixing fluid. It is best employed in the form of a solution made by adding 10 parts of formalin to 90 parts of water or normal saline solution. Small pieces of tissue remain in this solution for from twelve to twenty-four hours, larger pieces or organs a number of days or weeks, and are then transferred to 90% alcohol.

We have attempted to give only the fixing and hardening fluids commonly employed for general purposes. There are numerous other fluids used for special purposes; these will be noticed under the headings of the corresponding tissues and organs.

## B. INFILTRATION AND IMBEDDING.

31. To obtain sections from objects already fixed, it is above all necessary that they should have a certain consistency, which they obtain in 90% alcohol. It is not advisable to attempt the free-hand sectioning of objects that have not previously been especially prepared for this treatment, as crumbling of the sections and falling apart of the loosely connected tissues are the results. To avoid this, infiltration masses are used. The tissue is placed in a fluid medium which penetrates it throughout and then hardens into a solid mass on cooling or on the evaporation of the solvent. The object thus infiltrated and imbedded can then be cut, the natural position of its different elements being preserved in the section.

The commonest infiltration masses are paraffin and celloidin (colloidion or photoxylin).

## 1. PARAFFIN.

32. In describing the method of paraffin infiltration and imbedding it is assumed that the tissues have been previously fixed and hardened and are in alcohol ready for further manipulation. From the hardened tissues small flat pieces are cut with a sharp knife or razor. If possible, they should be square, rectangular, or triangular in shape, their surfaces not exceeding  $\frac{1}{2}$  square inch, and their thickness from  $\frac{1}{8}$  to  $\frac{1}{4}$  of an inch. Pieces of larger size may be imbedded, if desired, provided the requisite care be exercised. The pieces selected are placed in absolute alcohol, in which they remain until thoroughly dehydrated. From the latter they can not be passed directly into paraffin, as alcohol is not a solvent of that substance, and, consequently, the preparation would not be infiltrated with the imbedding mass. The pieces of tissue are therefore first placed in some fluid which mixes with absolute alcohol and at the same time dissolves the paraffin. There are many such reagents, as xylol, toluol, chloroform, and a number of oils (oil of turpentine, oil of cedar, oil of origanum, etc.). Of these reagents xylol may be recommended for general use. In the xylol the tissues remain for from two to twelve hours, the time depending somewhat on the size of the pieces and on the density of the tissue. When thoroughly permeated by the xylol, they are transparent. From the xylol (toluol, chloroform, or oils) the tissues are placed in melted paraffin. Two kinds of paraffin are used, one having a melting point of  $38^{\circ}$  to  $40^{\circ}$  C.—soft paraffin—and another with a melting point of  $50^{\circ}$  to  $54^{\circ}$  C.—so-called hard paraffin. The paraffin should always be filtered before using. It is essential that melted paraffin have a constant temperature while the tissues are being infiltrated. This is attained by placing the receptacle containing the paraffin in a paraffin oven regulated by means of a thermostat to a temperature about two degrees above the melting point of the hard paraffin.

Filtered hard and soft paraffin may be kept in suitable glass beakers in respective compartments in the paraffin oven. After the tissues are thoroughly permeated with the xylol, this is poured off and melted soft paraffin added, and the dish replaced in the paraffin oven. In the soft paraffin the tissues remain from one to four hours, at the end of which time the soft paraffin is poured off and hard paraffin added, and the dish again placed in the oven. In the hard paraffin the tissues remain from two to twelve hours, depending on the size of the pieces. They are now

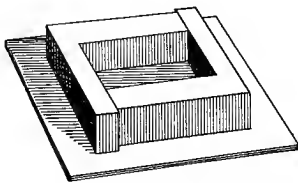


Fig. 2.—Box for imbedding tissues.

ready to be imbedded. Two metallic L's are placed together on a glass or metal plate in such a way as to make a rectangular box. (Fig. 2.) This is filled with melted hard paraffin taken from the oven. Before the paraffin cools, the piece of tissue to be imbedded is taken from the hard paraffin in the oven and placed with one of its flat surfaces against one end of the box. If several pieces of tissue are to be imbedded, a piece may thus be placed in each end of the box. While transferring the tissues from the hard paraffin to the imbedding box they should be handled with forceps, the blades of

which have been warmed in a flame. As soon as the paraffin in which the tissues are imbedded has cooled sufficiently to allow the formation of a film over the melted paraffin, the imbedding box is placed in a dish of cold water. This cools the paraffin quickly and prevents its becoming brittle. A stay of from five to ten minutes in the cold water hardens the paraffin so that the L's may be removed, and the paraffin block containing the imbedded tissue may be taken from the plate. It is well to place the paraffin block thus obtained back into the cold water for a short time, so that it may become hard all the way through. As the paraffin often adheres closely to the glass or metal plate and the L's, it is advisable to cover these parts with a very thin layer of glycerin before imbedding. There is then no difficulty in separating them from the paraffin block.

33. If a large number of small pieces of tissue are to be imbedded, it is often advantageous to carry on their infiltration with hard paraffin in a flat dish of suitable size. This may then be taken from the paraffin oven after thorough infiltration has been attained and the several pieces of tissue arranged on the bottom of the dish. As soon as a film forms over the paraffin the dish is placed carefully in cold water and the paraffin allowed to harden. The large piece of paraffin thus obtained may then be cut into several smaller pieces, each containing a piece of the imbedded tissue. The dish used for this purpose should be coated on the inside with a thin layer of glycerin.

34. On transferring an object from one fluid into another, so-called *currents of diffusion* occur, which produce, especially in such tissues as contain cavities, shrinkage and tearing. This often results in totally changing the finer structure of the tissues. It is therefore necessary to proceed with greater caution than in the method above indicated.


Mixtures containing different percentages of alcohol and the intermediate fluid (xylol, toluol, chloroform) may be prepared, and the object, according to its delicacy, passed through a greater or smaller number of such solutions. In ordinary cases a single mixture of alcohol and the intermediate fluid is sufficient, the object remaining in the solution for a length of time varying with its size before being passed into the pure intermediate fluid. This part of the treatment may of course be slowed or hastened according to the number of such mixtures, each succeeding one containing more and more of the intermediate fluid.

35. After the object has been passed into the pure intermediate fluid it should be just as carefully passed into the infiltrating fluid. If paraffin is to be used and the object be delicate, the following method is advisable: The object is placed in a glass vessel half filled with the intermediate fluid, into which a few pieces of soft paraffin are dropped. The vessel is then covered and allowed to remain at the temperature of the room. When the paraffin is dissolved the cover is removed and the vessel placed in a paraffin oven kept at a temperature corresponding to the melting point of the paraffin. The volatile intermediate fluid evaporates gradually, and in a few hours the object is infiltrated with an almost pure soft paraffin. It may now be transferred into pure melted hard paraffin. In this the tissue remains for a longer or shorter time, according to its size.

36. High temperatures are, as a rule, injurious to tissues. This should always be borne in mind, and the student should aim to keep his specimens at the lowest possible temperature conducive to proper infiltration. If for any reason higher temperatures become necessary, the ex-

posure of the tissues to their action should be as brief as possible. The paraffins most used have a melting point of  $40^{\circ}$  to  $60^{\circ}$  C. The kind of paraffin used should depend upon the temperature of the room in which the sectioning is to be done. It is even well to have different mixtures of hard and soft paraffins at hand, so that, if the temperature of the room be low, tissues may be imbedded in a softer mixture, and vice versa.

37. The process of infiltrating and imbedding in paraffin is represented by the following diagram (instead of xylol, other intermediate fluids may be used) :



38. The size and density of the tissues must necessarily regulate the length of time necessary for their proper infiltration. It is therefore hardly possible to give any definite figures. In presenting the following table we have taken as a standard any tissue that has the general consistency of liver fixed in alcohol. The time is given in hours, and should in each case be regarded as a minimum. A longer stay in any one fluid will, under favorable circumstances, do no harm.

	SMALL OBJECTS UNDER 1 MM. IN DIAMETER.	MIDDLE-SIZED OBJECTS UP TO 5 MM. IN DIAMETER.	LARGE OBJECTS UP TO 10 MM. IN DIAMETER.	VERY LARGE OBJECTS, ALTHOUGH NOT MORE THAN A FEW CM. IN DIAMETER.
Absolute alcohol	2	6	24	For a longer or shorter time in the fluids, according to the size of the object.
Xylol	$\frac{1}{2}$	3	6	
From now on in paraffin oven :				
Soft paraffin	$\frac{1}{2}$	3	6	
Hard paraffin	1	3	6	

## 2. CELLOIDIN.

The best and most convenient celloidin to use in microscopic work is Schering's granular celloidin, put up in 1-ounce bottles. Of this a stock or thick solution is prepared by dissolving 6 gm. of the celloidin in 100 c.c. of equal parts of absolute alcohol and ether. Of this, when required, a thin solution is prepared by diluting a quantity of the stock solution with an equal quantity of the ether and alcohol solution.

39. The hardened tissues are cut into small pieces, which should not be much more than  $\frac{1}{8}$  of an inch in thickness and not have a surface area of more than  $\frac{3}{4}$  of a square inch. Much larger pieces of tissue may be imbedded in celloidin. This is not advised, however, unless it is necessary to show the whole of the structure to be studied. The pieces to be imbedded are placed for twenty-four hours in absolute alcohol, and are then transferred for twenty-four hours to a mixture of equal parts of absolute alcohol and ether. Then they go into the thin celloidin solution, where they remain for from twenty-four hours to several days, depending on the size and density of the pieces to be imbedded. The pieces of tissue are then transferred to the thick celloidin solution, where they again remain for from twenty-four hours to several days. If it is desired to imbed large pieces, especially if these be of the medulla or brain, the stay in the celloidin solutions should be lengthened to several weeks. The hardening of the celloidin may now be obtained by one of several methods.

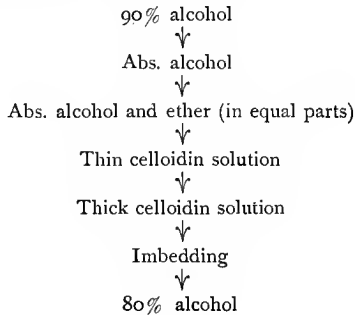
40. A sufficient quantity of the stock or thick celloidin solution to cover well the tissues to be imbedded is poured into a flat dish large enough to allow the pieces to be imbedded to be arranged on its bottom and leave a space of about  $\frac{1}{4}$  of an inch between adjacent pieces. The dish is then covered, not too tightly, and set aside to allow the ether and alcohol to evaporate. In one or two days the celloidin is usually hard enough to cut into small blocks, each block containing a piece of the imbedded tissue. The blocks of celloidin are now further hardened by placing them in 80% alcohol. A stay of several hours in this alcohol is usually sufficient to give them the hardness required for section cutting. After the celloidin pieces have obtained the right degree of hardness they are to be stuck to small pieces of pine wood or vulcanized fiber so that they may be clamped into the microtome. This is done in the following way: A piece of celloidin containing a piece of tissue is trimmed with sharp knife so that only a rim of celloidin about  $\frac{1}{2}$  of an inch in thickness surrounds the piece of tissue. It is now placed for a few moments in the ether and alcohol solution. This is to soften the surfaces of the celloidin. One end of a small pine-wood or vulcanized-fiber block about one inch long, the cut end of which has a surface area slightly larger than the celloidin block, is dipped for a few moments into the ether and alcohol solution and then into the thick celloidin. The celloidin block is now taken from the ether and alcohol solution, dipped into the celloidin, and pressed against the end of the wooden or vulcanized-fiber block, which has been coated with the celloidin. The whole is now set aside for a little while to allow the celloidin to harden slightly, and is then placed in 80% alcohol. In the alcohol it may remain indefinitely; it may, however, be used for cutting as soon as it again becomes hard.

41. The piece of tissue to be imbedded may be mounted at once on pine-wood or vulcanized-fiber blocks from the thick celloidin solution by pouring a small amount of thick celloidin over one end of the block and placing the piece of tissue from the thick celloidin solution onto the layer of celloidin on the block. In three to four minutes a layer of the thick celloidin solution is poured over the piece of tissue and the end of the block. It may be necessary to do this several times if the piece of tissue is large or of irregular shape. The block is now set aside for about five minutes, and is then placed in 80% alcohol, where it remains until the celloidin is hard, or until it is desired to cut sections.

42. The tissues may be imbedded by pouring the thick celloidin, together with the objects, into a small box made of paper. The surface of the celloidin hardens in about an hour (preliminary hardening), after which the whole is transferred to 80% alcohol, in which the final hardening takes place. The paper is then removed, the block of celloidin trimmed to a convenient size and fastened on a block.

While being cut, celloidin preparations are kept moistened with 80% alcohol. Organs consisting of tissues of varying consistency, as well as very dense objects, can be cut with better results in celloidin than in paraffin. On the other hand, celloidin sections can never be cut as thin as paraffin sections, and the after-treatment (see below), fixation on the slide, etc., are much more complicated than in the case of paraffin sections.

43. The following is a diagram showing the process of infiltration and imbedding in celloidin.



### 3. CELLOIDIN-PARAFFIN.

44. To combine the advantages which infiltration in celloidin and in paraffin offer, a method of celloidin-paraffin infiltration is recommended. Preparations that have been imbedded in celloidin and hardened in 80% alcohol are placed for about twelve hours in 90% alcohol, from which they are transferred to a mixture of equal parts of oil of origanum and 90% alcohol. They are then immersed for a short time in pure origanum oil, then in a mixture of equal parts of origanum oil and xylol, and finally in pure xylol. From this point the regular method of infiltrating with paraffin is followed, care being taken that the pieces remain for as short a time as possible in the different fluids, in order that the celloidin may not become brittle.

Very thin sections may be obtained by painting the cut surface with a thin layer of a very dilute celloidin solution. This hardens and gives the tissue a greater consistency. This treatment is useful in the combined celloidin-paraffin method, as well as when paraffin alone is used.

## C. THE MICROTOME AND SECTIONING.

Instruments known as microtomes have been devised in order that section cutting may be rendered as independent as possible of the skill of the individual, but more especially to obtain series of sections of uniform thickness. Their construction varies greatly. Some of these in-

struments, as the so-called **rocking** microtomes, are so specialized that they only cut paraffin objects when the knife is transversely placed. Others have a more general function, celloidin as well as paraffin objects being sectioned with the knife in any position. To the latter class belong the **sliding** microtomes. Of these, two types are in general use in this country, and may therefore be more thoroughly discussed.

45. In figure 3 is shown an instrument which may be recommended for general laboratory work. This instrument consists of a horizontal base which rests on the table, and a vertical plate (*a*), and a slide (*b*) which supports a block (*c*), to which is fastened a knife by means of a thumb-screw (*d*). On the other side of the vertical plate is a metal frame (*e*), into which are fastened the paraffin and celloidin blocks; this frame is attached to a slide (*f*), which may be elevated or lowered by a feed (*g*). This feed consists of a micrometer screw acting on the lower surface of the slide. The micrometer screw is provided with a milled head, divided into a definite number of parts which bear a definite rela-

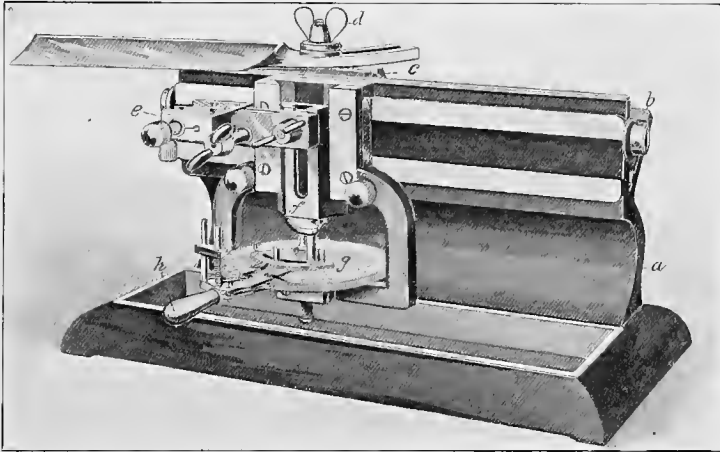


Fig. 3.—Laboratory microtome.

tion to the pitch of the micrometer screw. The instrument shown in the figure is further provided with a lever (*h*), which may be so adjusted as to move the milled head on the micrometer screw 1 or any given number of notches at each movement of the lever; and as each notch on the milled head has a value of 5 microns ( $\frac{1}{3000}$  of an inch), every time the milled head is moved 1 notch (toward the manipulator) the slide carrying the clamp holding the tissue is elevated 5 microns; 2 notches would elevate the tissue 10 microns ( $\frac{1}{2500}$  of an inch); 4 notches, 20 microns ( $\frac{1}{2500}$  of an inch), etc. It is not essential to have a lever attached to the instrument as above described, although this is very convenient; if not present, the milled head is moved the desired number of notches with the hand.

46. In cutting **paraffin sections** with the sliding microtome the knife is placed at an angle of about  $35^\circ$  to  $40^\circ$  to the horizontal plate of the microtome. Sections are cut more easily with the knife in this posi-

tion than when the knife is placed at right angles to the microtome, as is often recommended, and it does not seem that the tissues suffer materially from distortion when they are cut with the knife at an angle, as is sometimes claimed.

Before fastening the paraffin blocks into the clamp on the microtome, preparatory to cutting sections, the paraffin is trimmed with a sharp knife from the end of the paraffin block until the tissue is nearly exposed, care being taken, however, to leave a flat surface. The top of the paraffin block is then beveled off on three sides to within a very short distance of the tissue. The fourth side, that which faces the knife when the block is clamped in the microtome, should be trimmed only to within about  $\frac{1}{8}$  of an inch of the tissue. This edge of paraffin is made use of, as will be seen in a moment, for preventing the sections from curling while they are being cut. The paraffin block is now ready to be clamped in the microtome. This is done in such a way that the paraffin block just escapes the knife when drawn over it. A number of rather thick sections (20 to 40 microns) are cut by moving the micrometer screw from right to left 4 to 8 notches every time the knife has been drawn over the paraffin block and has been brought back again, until it is noticed that the knife touches all parts of the top of the paraffin block, or until the tissue is fairly exposed. The succeeding sections may now be kept. It may perhaps be well to state that it is better not to try to cut very thin sections at the beginning; sections 20 to 15 microns in thickness will answer very well. To begin with, then, the milled head of the micrometer screw is turned 4 notches from left to right, and the knife is drawn over the block with a steady, even pull, and without using undue pressure. Usually the sections will curl up as they are being severed from the paraffin block. This may very readily be prevented by holding the tip of a camel's-hair brush, which has been pointed by drawing it between the lips, against the edge of the section as soon as it begins to curl. A little practice will enable one to do this almost automatically. The sections are transferred to paper by means of the camel's-hair brush, which process is facilitated if the brush has been slightly moistened with saliva, as the section will then adhere lightly to the brush.

47. If the tissues are well imbedded and not too hard, and if the knife is sharp and properly adjusted, paraffin sections may be cut in such a way that each succeeding section adheres to the preceding one, so that actual ribbons of paraffin sections may be made. In order to do this, the knife should be at right angles to the microtome. The paraffin block should be trimmed in such a way that when clamped in the microtome ready for cutting sections, the surface of the paraffin block facing the knife should be exactly parallel to its edge, also to the opposite side of the block. In other words, 2 sides of the paraffin block should be parallel to each other and to the knife; then if the paraffin is of the right consistency, which must be ascertained by trying, the sections as they are cut will adhere to each other and form a ribbon. If the sections do not adhere to each other it is quite probable that the paraffin is a little too hard. This may often be remedied by holding an old knife or other metallic instrument which has been heated in a flame near the two parallel surfaces for a few moments. Care should be taken not to allow this instrument to touch the paraffin. This is a very convenient and rapid way of cutting paraffin sections. To facilitate the cutting of a paraffin possessing a rela-

tively low melting point in a room with a high temperature, the cooled knife of Stoss may be used. This is so made that a stream of ice-water may be passed through a tube running through the entire length of the back of the blade.

**48. Celloidin Sections.**—Before fastening the block of wood or vulcanized fiber to which the celloidin blocks have been fixed in the clamp on the microtome, the celloidin should be trimmed with a sharp knife from the top of the block until the tissue is nearly exposed, care being taken to leave a flat surface. The sides of the celloidin block are then trimmed down, if necessary, to within about  $\frac{1}{16}$  of an inch of the tissue. The block is now clamped in the microtome at such a level that it just escapes the knife when drawn over it. The knife is placed at an angle of about  $45^\circ$ , or at even a greater angle. During the process of cutting, the knife, as also the tissue, must be kept constantly moistened with 80% alcohol. This is perhaps most easily accomplished by taking up the 80% alcohol with a rather large camel's-hair brush and dipping this on the




Fig. 4.—Sliding microtome of Jung. Medium-sized model No. IV.

The instrument is shown from the left. On the right side is the plate placed at an acute angle, as a carrier for the sliding block to which the knife is fastened. Both are partly visible. The screws *c* serve to fix the knife (absent in the figure) in place. The rod (*d*) serves to turn the screws. On the left side of the microtome is fastened the diagonally placed side plate. On this, behind, rests (in the figure to the right) the micrometer screw, and in front (in the figure to the left) the object carrier.

celloidin block and on the knife. A number of rather thick sections are cut until the knife touches the entire surface of the block or until the tissue is well exposed. The sections may now be kept. The block is raised 20 to 15 microns, and the knife, which should be well moistened with 80% alcohol, is drawn over the block with a steady pull, not with a jerk. The sections are transferred from the knife to distilled water. This is perhaps most conveniently done by placing the ball of one of the fingers of the left hand under the edge of the knife, in front of the section, and drawing the section down onto the finger with the camel's-hair brush. The finger is then dipped into the distilled water when the sec-

tion floats off. If the sections can not be stained within a few hours after they are cut, they are best transferred to a dish containing 80% alcohol, in which they may be left until it is desired to stain them.

49. The other type of sliding microtome to be specially mentioned is that suggested by Professor Thoma and made by R. Jung, of Heidelberg. (Fig. 4.) The immovable portions of this microtome consist of four plates, of which the lower rests as a horizontal base on a table. A second vertically placed plate rests along the middle of this base. The other two are fastened one on each side of the second plate in such a way that they are directed diagonally outward and upward, forming with the vertical plate acute angles whose apices are directed downward. One of these is attached horizontally to the vertical plate, the other obliquely, one end being attached lower than the other, thus forming an incline.

Into the angles formed by the side and vertical plates fit solid metal bodies, which can be easily slid backward and forward on the smooth surfaces arranged for this purpose. On these metal blocks the knife and the object are fastened, and they are therefore called the knife- and object-carriers. The former runs on the horizontal, the latter on the inclined plane. The several holes bored in the upper surface of the knife-carrier are for the screw which fastens the knife in whatever position is most convenient. The knife is clamped down by the screw-head. The object-holder consists of an arrangement for the fixation of the object. This may be a simple clamp, into which the block of wood is fastened. It is, however, often necessary to move the object to be cut in different directions to obtain proper orientation, especially in the sectioning of embryos. In such cases an object-carrier provided with an arrangement for orientation is used. In the carrier is fastened a rectangular frame of metal which, by means of screws, may be turned on two axes at right angles to each other and thus fixed in any given position. In the middle of this revolving frame of metal is an aperture into which a cylinder is fitted. In the case of paraffin preparations, this is filled with paraffin and the imbedded object attached to its upper end by heating. A special mechanism is provided for the raising and lowering of the cylinder. The newer instruments are made on the same principle except that they have a screw at one side by means of which the whole apparatus may be raised or lowered, an arrangement that is especially adapted for long objects. Instead of containing a cylinder, the clamp may be made to fit a block of wood; in this case the object is melted on to the upper surface of the block.

In sectioning, the microtome is so placed before the operator that the plate upon which the knife-carrier moves is to the right. The object-carrier should be at the end of the microtome nearest the worker. A forward motion of this carrier on its ascending path will cause the object to be raised. As the knife-carrier always moves in a horizontal direction, the blade will cut from the object a section the thickness of which will correspond to the distance which the object has been raised, and this is regulated by the distance that the object-carrier is moved forward. To measure this, the vertical plate of the microtome and the object-carrier are provided with a scale and nonius or vernier. To obtain a series of sections of exactly equal thickness, the arrangement by which the object-carrier is moved forward by hand is not sufficiently accurate. Very exact results are obtained with the help of a micrometer screw, which is attached behind the object-carrier and moves the object a certain distance at every turn. In the Thoma-Jung microtome a single

revolution of the screw raises the object 15  $\mu$ . A drum attached to the screw is marked off at its periphery into fifteen equal parts; the turning of the screw one degree, therefore, raises the object 1  $\mu$ . By means of a cog arrangement it is possible to regulate automatically the raising of the object and consequently the thickness of the sections in the series.

Before cutting, the paths upon which the knife- and object-carriers slide must be carefully cleaned and oiled; so-called machine oil (four parts of bone oil to one part of petroleum) is the best for this purpose. Enough oil should be used, and care should be taken that the knife-carrier moves easily from one end to the other of its pathway. The microtome knife should now be fastened into its holder, and the blade placed in such a position that it forms an acute angle with the upper edge of the vertical plate. The object is placed on the object-carrier, and fixed at the desired height, with the micrometer screw resting against the agate-plate of the object-carrier. The knife-carrier with its knife is now brought toward the operator, the slightest pressure being avoided, as otherwise the layer of oil disappears and the sections become irregular in thickness. The newest Jung microtomes have a rod pointing downward on the side of the knife-holder. The operator, resting a finger on the anterior surface of this rod, can pull the knife toward him, thus avoiding the possibility of any pressure on the apparatus.

The knife having brought with it a section, it is often seen that the latter is not flat on the blade, but rolled. This condition may be avoided, as has been stated, by holding down the free edge of the section with a camel's-hair brush held in the left hand. There are also so-called *section stretchers*, which consist of rollers of different diameters. They are so attached above the blade of the knife that between them and the knife is a very narrow space through which the section must pass. These section stretchers are very difficult to put into position, and their action is uncertain, so that it is advisable to accustom one's self to the brush method, which affords good results after a little practice.

After cutting the section the knife is pushed back to the opposite end of the instrument and again brought forward after turning the micrometer screw, thus producing a second section. After continued section-cutting the micrometer screw passes through its attachment to its full length and must then be screwed back and adjusted anew against the agate-plate. During this procedure the object-carrier should not be moved. R. Jung has recently produced a micrometer screw provided with a reversible arrangement by which the tedious process of turning backward is avoided. The knife may be fastened transversely to the long axis of the microtome, and if the paraffin and room temperature be favorable, ribbons can be cut. Celloidin sections may also be cut with this instrument.

50. The sliding microtomes may be provided with an arrangement for freezing tissues—a so-called **freezing apparatus**. This consists of a metal plate on which the tissue is laid; an ether-atomizer plays upon its lower surface, cooling and finally freezing the object, which is then cut. A drop of fluid (physiologic saline solution, water, etc.) is placed upon the knife, in which the section thaws out and spreads. A better and more rapid method of freezing tissues consists in the use of compressed carbon dioxide, as recommended by Mixer. Cylinders containing about twenty pounds of the liquid gas may be obtained from Bausch & Lomb, who also make a small microtome designed for this purpose. In figure 5 is shown the lower third of a cylinder for compressed carbon dioxide

firmly fastened to a thick board, and connected by means of a short piece of strong rubber tubing with the freezing box of the microtome. The handle of the escape valve is from 8 to 10 inches long, so that the quantity of escaping gas may be readily controlled. The pieces of tissue are placed on the freezing box of the microtome and the escape valve slowly opened until a small quantity of the gas escapes. Small pieces of tissue are frozen in about thirty seconds to a minute; tissues taken from alcohol should be washed for a short time in running water before freezing. A strong razor may be used for cutting sections; or better, a well-sharpened blade of a carpenter's plane, as suggested by Mallory and Wright. Sections are transferred to distilled water or normal salt solution, and if fixed may be stained at once. Sections of fresh tissue should be taken from the normal salt solution and transferred to a fixing fluid.

51. It is impossible to cut thin sections with a knife that is not sharp, or with one that is nicked. A few directions as to **sharpening a microtome knife** may therefore not be out of place. For this purpose a good

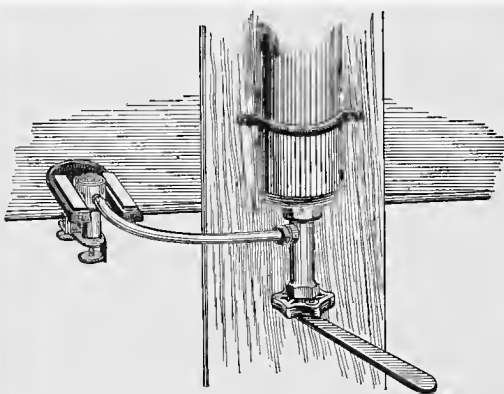


Fig. 5.—Apparatus for cutting tissues frozen by carbon dioxide.

Belgian hone is used, which should be moistened or lubricated with filtered kerosene oil as necessity demands. While sharpening the knife it is grasped with both hands—with one by the handle, with the other by the end. The hone is placed on a table with one end directed toward the person sharpening. If the knife is very dull, it is ground for some time on the concave side only (all microtome knives are practically plane on one side and concave on the other), with the knife at right angles to the stone. It is carried from one end of the stone to the other, edge foremost, giving it at the same time a diagonal movement, so that with each sweep the entire edge is touched (see Fig. 6). In drawing back the knife, the edge is slightly raised. The knife is ground on the concave side until a fine thread (feather edge) appears along the entire edge. It is then ground on both sides, care being taken to keep the knife at right angles to the stone, to keep it flat, and to use practically no pressure. It is a good plan to turn the knife on its back when the end of the stone is reached. On the return stroke, the knife is again held at right angles to the stone, the same diagonal sweep is used (see Fig. 6), so that the

whole edge of the knife is touched with each sweep. The grinding on both sides is continued until the thread above mentioned has disappeared. The knife should now be carefully cleaned and stropped, with the back of the knife drawn foremost. The strop should be flat and rest on a firm surface.

Very good microtomes are manufactured by August Becker in Göttingen. Of these, Model A (after Spengel) is constructed on the same principle as the Thoma-Jung microtome. The knife-carrier rests on thick plates of glass in place of metal. The knife is moved by means of a crank. Model B (after Schiefferdecker, 86) is peculiar in that the specimen to be cut is raised by a micrometer screw in a vertical rather than a horizontal plane. The knife-carrier runs mechanically on horizontal glass plates. This microtome also possesses an automatic arrangement for the cutting of sections of equal thickness, so that when the micrometer screw is once regulated the knife-holder needs only to be moved back and forth

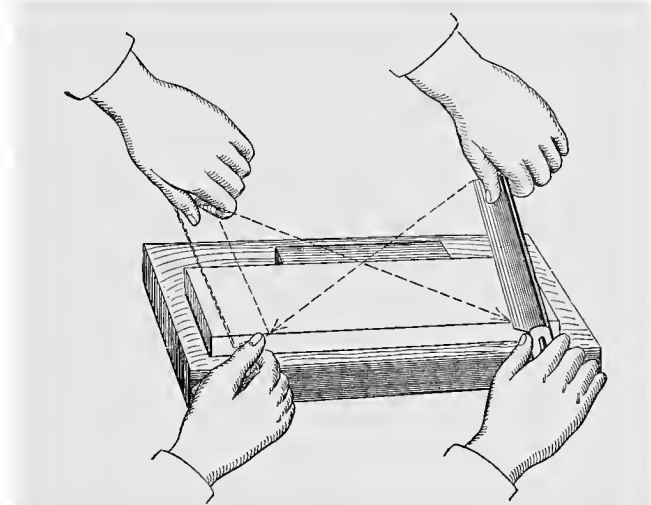


Fig. 6—Diagram showing direction of the movements in honing.

to make sections of a uniform thickness. With the help of both models (A and B), celloidin as well as paraffin objects can be cut. Instruments giving especially good results in the serial sectioning of paraffin objects are : (1) The Minot microtome, which can be obtained from Becker and from E. Zimmermann of Leipzig (Model D, Becker). Here the knife is stationary, with the edge of the blade upward, while the object is moved up and down by means of a crank, and at the same time pushed forward toward the blade. The thickness of the section is regulated automatically, and by merely turning the wheel a long series of sections may be made in a short time. (2) An ingenious and well-built instrument is the improved rocking microtome of R. Jung, in Heidelberg (Cambridge rocking microtome). The knife is stationary, with the edge upward. By means of a clever arrangement the object is advanced toward the knife. A lever causing a slight rotation of the axis upon which the object rests moves

the object up and down. As a result, every section has not a plane surface, as is the case with other microtomes, but appears as a peripheral section of a cylinder the radius of which corresponds to the distance of the blade from the axis bearing the object-holder. (This drawback limits the use of the instrument.) The mechanism has one advantage: excellent serial sections can be made, having a thickness of only  $1\ \mu$  (*vid.* Schieffer-decker, 92). Bausch & Lomb, of Rochester, N. Y., make excellent sliding microtomes. (Fig. 3.) They have recently constructed for Minot an instrument in which the knife is fixed at both ends. The object-carrier is elevated by a screw, and moves back and forth under the knife.

## D. THE FURTHER TREATMENT OF THE SECTION.

### 1. FIXATION TO THE SLIDE AND REMOVAL OF PARAFFIN.

Sections obtained by means of the microtome undergo further treatment either loose or, better, fixed to a slide or cover-glass, thus making further manipulation much easier.

52. The simplest, surest, and most convenient method of fixing paraffin sections to the slide is by means of the **glycerin-albumen** of P. Mayer (83, 2). Egg-albumen is filtered and an equal volume of glycerin added. To prevent decomposition of the fluid a little camphor or sodium salicylate is placed in the mixture. A drop of this fluid is smeared on the slide or cover-slip as evenly and thinly as possible. A section or a series of sections arranged in their proper sequence is then placed upon the slide so prepared. Any folds in the section are smoothed out with a brush, and the section or the whole series gently pressed down upon the glass. When the desired number of sections are on the slide or cover-slip, they are warmed over a small spirit or gas flame until the paraffin is melted. At the same time the albumen coagulates. The sections are now fixed, and are loosened from the glass only when agents are used which dissolve albumen, as, for instance, strong acids, alkalis, and certain staining fluids. If it is desired that a given space, say the size of a cover-slip, be filled up with sections as far as possible, an outline of the cover-slip to be used may be drawn upon a piece of paper and placed under the slide in the required position.

53. A second and in many respects better method is the fixation of the section with **distilled water** (Gaule). The paraffin sections are spread in proper sequence on a thin layer of water placed on the slide. There should be sufficient water to float the sections. The slide is then dried in a warm oven kept at  $30^{\circ}$  to  $35^{\circ}$  C., or gently heated by holding it at some distance from a spirit or gas flame (the paraffin should not melt). By this treatment the sections are entirely flattened out. The superfluous water is either drained off by tilting or drawn off with blotting-paper, the sections are definitely arranged with a brush, and the whole is placed for several hours in a warm oven at  $30^{\circ}$  to  $35^{\circ}$  C. The sections thus dried are exposed, over a flame, to a temperature higher than the melting point of the paraffin, and from now on can be subjected to almost any after-treatment. The slide or cover-slip should be thoroughly cleaned (preferably with alcohol and ether), as otherwise the water does not remain in a layer, but gathers in drops.

The advantage of this method lies in the fact that the evaporated water can have no possible influence on the subsequent staining of the

sections, while albumen, especially if it be in a thick layer, is sometimes stained, thus diminishing the transparency of the preparation. (For fixation with the stain *vid.* T. 79.)

This method, although trustworthy for alcohol and sublimate preparations, often fails with objects that have been treated with osmic acid, chromic acid and its mixtures, nitric acid, and picrosulphuric acid. In such cases advantage may be taken of the so-called **Japanese method**, which is a combination of the above fixation methods. A little Mayer's albumen is placed on the slide and so spread about that hardly a trace of the substance can be seen. The slide is then put in a warm oven heated to 70° C. This temperature soon coagulates the albumen, after which the sections are fixed to the slide by the water method (Rainke, 95). The procedure can be varied by adding to the distilled water one drop of glycerin-albumen or gum arabic to every 30 c.c. of water (*vid.* also Nussbaum).

When a large number of paraffin sections are to be fixed to cover-slips, the following method may be recommended: A small porcelain evaporating dish is nearly filled with distilled water and placed on a stand which elevates it 6 to 8 inches from the table. A number of sections are placed on the water, which is then heated by means of a gas flame until the sections become perfectly flat, care being taken not to raise the temperature of the water sufficiently to melt the paraffin. Each section is then taken up on a cover-slip coated with a very thin layer of Mayer's albumen fixative. During this procedure the cover-slips are held by forceps, and the sections are guided by means of a small camel's-hair brush. When all the sections have thus been placed on cover-slips they are placed for four to six hours in a warm oven maintained at 30° to 35° C.

54. Celloidin preparations can not be fixed to the slide with the same degree of certainty, although many sections may be treated at one time. The celloidin sections can be collected in their sequence on strips of paper by gently pressing such a strip, on the blade of a knife, onto the section floating in the alcohol. The sections adhere to the paper, and in this way the entire surface of the strip may be covered by series of sections. To prevent the drying of the sections, a number of such strips are laid in rows on a layer of blotting-paper moistened with 70% alcohol. A glass plate of corresponding size is painted with very fluid celloidin. After the layer of celloidin is dry, the strips of paper are laid, one by one, on the glass plate, with sections downward, and the fingers gently passed over the reverse side. This process is continued until the entire surface of the glass is covered. On carefully raising the strips it is seen that the sections will adhere to the layer of celloidin. (To prevent drying, sections must be kept moistened with 70% alcohol.) After first drying the sections with blotting-paper, a second layer of very thin celloidin is painted on the surface of the glass plate. When this layer is also dry, the plate with its adherent sections is placed in water. Here the double layer of celloidin containing the sections is separated from the glass, and is ready for further manipulation. Before mounting, the sheet of celloidin is cut with scissors into convenient portions.

These methods of fixation are of especial importance in the preparation of series of sections. By this we mean an arrangement of the sections in their natural sequence, thus making it possible to reconstruct the object from the sections. It is, however, advisable to fix all paraffin

sections to a slide or cover-slip before subjecting them to further manipulation, even though the regular sequence be of no importance.

**55. Removal of Paraffin.**—Before paraffin sections, either fixed or loose, are subjected to further manipulation, the paraffin surrounding the tissues must be removed. This may be done by means of several agents having a solvent action on paraffin, such as xylol, toluol, oil of turpentine, etc. After the paraffin has been dissolved, the sections are transferred to absolute alcohol and by this means prepared for further treatment with aqueous or weak alcoholic solutions.

In the case of celloidin sections, if it be desirable to preserve the surrounding celloidin, care should be taken that the preparations should not come in contact with any agents dissolving celloidin. These latter are alcohols from 95% upward, ether, several ethereal oils, especially oil of cloves, but not the oils of organum, cedar wood, lavender, etc.

## 2. STAINING.

It is in most cases necessary to stain tissues to bring clearly to view the tissue elements and their relation to each other. The purpose of staining is therefore to differentiate the tissue elements. The differential staining is due to the fact that certain parts of the tissue take up more stain than others. Staining of sections may be looked upon as a microchemic color reaction, and has therefore a value beyond the mere coloring of sections so that they may be seen more clearly.

Broadly speaking, stains used in microscopic work may be divided into basic stains, which show special affinity for the nuclei of cells and are therefore known as *nuclear stains*, and acid stains, which color more readily the protoplasm—*protoplasmic stains*. Certain stains, which we may know as *selective stains* (they may be either basic or acid), color one tissue element more vividly than others, or to the exclusion of others. Since the various tissue elements show affinity for different stains, preparations may be colored with more than one stain. Accordingly we have simple, double, triple, and multiple staining.

Certain stains are also especially adapted for staining in bulk or mass—that is, staining a piece of tissue before it is sectioned.

### SECTION STAINING.

**Carmin.**—**56. Aqueous Borax-carmin Solution.**—8 gm. of borax and 2 gm. of carmin are ground together and added to 150 c.c. of water. After twenty-four hours the fluid is poured off and filtered. The sections, previously freed from paraffin and treated with alcohol, are placed in this fluid for several hours (as long as twelve), and then washed out in a solution of 0.5 to 1% hydrochloric acid in 70% alcohol. They are then transferred to 70% alcohol.

**57. Alcoholic Borax-carmin Solution.**—3 gm. of carmin and 4 gm. of borax are placed in 93 c.c. of water, after which 100 c.c. of 70% alcohol is added. The mixture is stirred, then allowed to settle, and later filtered. Sections are treated as in § 56.

**58. Paracarmin** is the carmin stain containing the most alcohol, and is therefore of great value.

Carminic acid . . . . .	1	gm.
Aluminium chlorid . . . . .	0.5	“
Calcium chlorid . . . . .	4	“
Alcohol, 70% . . . . .	100	c.c.

Paracarmin stains quickly, is not liable to overstain, and is therefore peculiarly adapted to the staining of large objects. Specimens are washed in 70% alcohol, with the addition of 0.5% aluminium chlorid or 2.5% glacial acetic acid in case of overstaining (P. Mayer, 92).

**59. Czocor's Cochineal Solution.**—7 gm. of powdered cochineal and 7 gm. of roasted alum are kept suspended in 100 c.c. of water by stirring while the mixture is boiled down to half its volume. After cooling it is filtered and a little carbolic acid added. This fluid stains quite rapidly and does not overstain. Before the sections are placed in alcohol they should be washed with distilled water, as otherwise the alum is precipitated on the section by the alcohol.

Partsch recommends the following solution of cochineal: Finely powdered cochineal is boiled for some time in a 5% aqueous solution of alum, and filtered on cooling, after which a trace of hydrochloric acid is added. It stains sections in two to five minutes.

**60. Alum-carmin (Grenacher).**—100 c.c. of a 3% to 5% solution of ordinary alum, or preferably ammonia-alum, are mixed with 0.5 gm. to 1 gm. of carmin, boiled for one-fourth of an hour, and after cooling filtered and enough distilled water added to replace that lost by evaporation. This fluid stains quickly but does not overstain. Wash the sections in water.

**Hematoxylin.—61. Böhmer's Hematoxylin :**

Hematoxylin crystals . . . . .	1 gm.
Absolute alcohol . . . . .	10 c.c.
Potassium alum . . . . .	10 gm.
Distilled water . . . . .	200 c.c.

Dissolve the hematoxylin crystals in the alcohol, and the alum in the distilled water. While constantly stirring, add the first solution to the second.

The whole is then left for about fourteen days in an open jar or dish protected from the dust, during which time the color changes from violet to blue. After filtering, the stain is ready for use. Sections, either loose or fixed to the slide or cover-slip, are placed in this solution, and after about half an hour are washed with water. If the nuclei are well stained the further treatment with alcohol may be commenced. Should the sections be overstained, a condition showing itself in the staining of the cell-protoplasm as well as the nuclei, the sections are then washed in an acid alcohol wash (six to ten drops of hydrochloric acid to 100 c.c. of 70% alcohol) until the blue color has changed to a reddish-brown and very little stain comes from the section—usually about one to two minutes. They are then washed in tap-water, and passed into distilled water before placing in alcohol.

**62. Delafield's Hematoxylin :**

Hematoxylin crystals . . . . .	4 gm.
Absolute alcohol . . . . .	25 c.c.
Ammonia alum, saturated aqueous solution	400 "
Alcohol, 95% . . . . .	100 "
Glycerin . . . . .	100 "

Dissolve hematoxylin crystals in absolute alcohol and add to the alum solution, after which place in an open vessel for four days, filter, and add the 95% alcohol and glycerin.

After a few days it is again filtered. This fluid is either used pure or diluted with distilled water. Staining is the same as with Böhmer's hematoxylin.

**63. Friedländer's Glycerin-hematoxylin :**

Hematoxylin crystals . . . . .	2 gm.
Potassium alum . . . . .	2 "
Absolute alcohol . . . . .	100 c.c.
Distilled water . . . . .	100 "
Glycerin . . . . .	100 "

Dissolve the hematoxylin crystals in the absolute alcohol and the alum in the water ; mix the two solutions and add the glycerin.

The mixture is filtered and exposed for several weeks to the air and light, until the odor of alcohol has disappeared, and then again filtered. It stains very quickly. Sections are afterward washed in water and are placed for a short time in acid alcohol if the nuclei are to be especially brought out.

**Ehrlich's Hematoxylin :**

Hematoxylin crystals . . . . .	2 gm.
Absolute alcohol . . . . .	60 c.c.
Glycerin } saturated with . . . . .	60 "
Distilled water } ammonia alum . . . . .	60 "
Glacial acetic acid . . . . .	3 "

The solution is to be exposed to light for a long time. It is ready for use when it acquires a deep-red color.

Stain as above.

**64. Hemalum** (P. Mayer, 91).—1 gm. of hematein is dissolved by heating in 50 c.c. of absolute alcohol. This is poured into a solution of 50 gm. of alum in 1 liter of distilled water and the whole well stirred. A thymol crystal is added to prevent the growth of fungus. The advantages of hemalum are as follows: The stain may be used immediately after its preparation, it stains quickly, never overstains, especially when diluted with water, and penetrates deeply, making it useful for staining in bulk. After staining, sections or tissues are washed in distilled water.

**65. Heidenhain's Iron Hematoxylin.**—Good results, particularly in emphasizing certain structures of the cell (centrosome), are obtained by the use of M. Heidenhain's iron hematoxylin (92. 2). Tissues are fixed in saline sublimate solutions in twelve to twenty-four hours (*vid.* T. 19), after which they are washed for the same length of time in running water and then placed in the ascending alcohols. Very thin sections (in case of amniota not over 4  $\mu$ ) are fixed to the slide with water and put into a 2.5% aqueous solution of ammonium sulphate of iron for four to eight hours (not longer). After careful rinsing in water, the sections are brought into a solution of hematoxylin prepared as follows: Hematoxylin crystals 1 gm., absolute alcohol 10 c.c., and distilled water 90 c.c. This solution should remain in an open vessel for about four weeks, and, before using, should be diluted with an equal volume of distilled water. Staining takes place in twelve to twenty-four hours, after which the sections are rinsed in water and again placed in a like solution of ammonium sulphate of iron, until black clouds cease to be given off from the sections. They are rinsed in distilled water, passed through alcohol into xylol, and mounted in balsam. Should a protoplasmic stain be desired, rubin in weak acid solution may be employed (*vid.* also M. Heidenhain, 96).

**Coal-tar or anilin stains.**—Ehrlich classifies all anilin stains as salts having basic or acid properties. The basic anilin stains, such as safra-

nin, methylene-blue, methyl-green, gentian violet, methyl-violet, Bismarck brown, thionin, and toluidin-blue are nuclear stains, while the acid anilin stains, such as eosin, erythrosin, benzopurpurin, acid fuchsin, lichtgrün, aurantia, orange G, and nigrosin stain diffusely and are used as protoplasmic stains.

#### 66. Safranin :

Safranin . . . . .	1 gm.
Absolute alcohol . . . . .	10 c.c.
Anilin water . . . . .	90 "

Anilin water is prepared by shaking up 5 c.c. to 8 c.c. of anilin oil in 100 c.c. of distilled water and filtering through a wet filter. Dissolve the safranin in the anilin water and add the alcohol. Filter before using.

Stain sections of tissues fixed in Flemming's or Hermann's solutions for twenty-four hours, and decolorize with a weak solution of hydrochloric acid in absolute alcohol (1 : 1000). After a varying period of time (usually only a few minutes) all the tissue elements will be found to have become bleached, only the chromatin of the nucleus retaining the color.

**67. Bismarck Brown.**—A very convenient color to handle is Bismarck brown. Of this, 1 gm. is boiled in 100 c.c. of water, filtered, and  $\frac{1}{3}$  of its volume of absolute alcohol added. Bismarck brown stains quickly without overstaining, and is also a purely nuclear stain. Wash in absolute alcohol.

**68. Methyl-green** stains very quickly (minutes). 1 gm. is dissolved in 100 c.c. of distilled water to which 25 c.c. of absolute alcohol is added. Rinse sections in water, then place for a few minutes in 70% alcohol, transfer to absolute alcohol for a minute, etc.

**69.** Other so-called basic anilin stains can be used in a similar manner. Thionin or toluidin-blue in dilute aqueous solutions are especially useful. Nuclei appear blue and mucus red.

**70. Double Staining.**—When certain stains are used in mixtures or in succession, all portions of the section are not stained alike, but certain elements take up one stain, others another. This elective affinity of tissues is taken advantage of in *plural staining*. If two stains are employed, one speaks of *double staining*.

**71. Picrocarmin of Ranvier.**—Two solutions are prepared, a saturated aqueous solution of picric acid and a solution of carmin in ammonia. The second is added to the first to the point of saturation. The whole is evaporated to one-fifth of its volume and filtered after cooling. The solution thus obtained is again evaporated until the picrocarmin remains in the form of a powder. A 1% solution of the latter in distilled water is the fluid used for staining.

To stain with this solution, one or two drops are placed on the slide over the object and the whole put in a moist chamber for twenty-four hours. A cover-slip is then placed over the preparation, the picrocarmin drained off with a piece of blotting-paper, and a drop of formic-glycerin (1 : 100) brought under the cover-slip by irrigation. Proper differentiation takes place only after a few days, and the acid-glycerin may then be replaced by the pure glycerin. In objects fixed with osmic acid, the nuclei appear red, connective tissue pink, elastic fibers canary yellow, muscle tissue straw color, keratohyalin red, etc.

**72. Weigert's Picrocarmin.**—The preparation of Weigert's picrocarmin is somewhat simpler. 2 gm. of carmin are stirred in 4 c.c.

of ammonia and allowed to remain standing in a well-corked bottle for twenty-four hours. This is mixed with 200 c.c. of a concentrated aqueous solution of picric acid to which a few drops of acetic acid are added after another twenty-four hours. The result is a slight precipitate that does not dissolve on stirring. Filter after twenty-four hours. Should the precipitate also pass through the filter, a little ammonia is added to dissolve it. Both picrocarmin solutions dissolve off sections fixed to the slide with albumen.

### 73. P. Mayer's Picric-magnesia-carmin.

#### 1. Magnesia-carmin ;

Carmin . . . . .	1	gm.
Magnesia usta . . . . .	0.1	"
Distilled water . . . . .	20	c.c.

#### 2. Picrate of magnesia ;

Carbonate of magnesia . . . . .	0.25	gm.
Picric acid, 0.5% in distilled water . . . . .	200	c.c.

Heat to boiling, cool and filter.

One volume of the first solution is mixed with 9 volumes of the second.

Another formula is magnesia-carmin solution 1 volume, magnesia-picrate solution 4 volumes, weak magnesia-carmin solution 5 volumes, magnesia water 100 c.c. The latter is made by allowing 0.1 gm. of magnesia usta to remain for one week in 100 c.c. of water, shaking from time to time. Sections are washed in either distilled or magnesia water. Staining takes place quickly ; the solution may be used for staining in bulk.

74. **Carmin-bleu de Lyon** (of Röse).—Sections or pieces of tissue are first stained with carmin (alum- or borax-carmin). Bleu de Lyon is dissolved in absolute alcohol and diluted with the latter until the solution is of a light bluish color. In this the sections or pieces of tissue are after-stained for twenty-four hours (developing bone stains, for instance, blue).

75. **Picric acid** is often used as a secondary stain, either in aqueous (saturated solution diluted 1 to 3 times in water) or in alcoholic solution (weak solutions in 70%, 80%, and absolute alcohol). Sections previously treated with carmin or hematoxylin are stained for two to five minutes, washed in water or alcohol, and transferred to absolute alcohol, etc. Sections stained in safranin can be exposed to the action of an alcoholic picric acid solution. A solution of picric acid in 70% alcohol may be used to wash sections stained in borax-carmin. This often gives a good double stain. Sections can also be first treated with picric acid and afterward stained with alum-carmin.

76. **Hematoxylin-eosin**.—Sections already stained in hematoxylin are placed for two to five minutes in a 1% to 2% aqueous solution of eosin or in a 1% solution of eosin in 60% alcohol. They are then washed in water until no more stain comes away, after which they remain for only a short time in absolute alcohol.

77. **Hematoxylin-safranin** of Rabl (85).—Sections of preparations fixed with chromic-formic acid or with a solution of platinum chlorid are stained for a short time with Delafield's hematoxylin (*vid.* T. 62), then counterstained for twelve to twenty-four hours with safranin and washed with absolute alcohol until no more color is given off.

**78. Ehrlich-Biondi Triple Stain.**—Of the many triple stains in use we mention only the most important, the rubin S—orange G—methyl-green mixture of Ehrlich and Biondi, employed according to the modification of M. Heidenhain (92. 2). The best results are obtained with objects fixed in saline sublimate solution. The three stains just mentioned are prepared in concentrated aqueous solutions (rubin S dissolves in the proportion of 1:5, orange G and methyl-green about 1:8). These concentrated solutions are combined in the following volumes: rubin S 4, orange G 7, methyl-green 8. The stock solution thus obtained is diluted with 50 to 100 times its volume of distilled water before using. The sections should be as thin as possible and fixed to the slide by the water method. They remain for twenty-four hours in the stain, and are then washed either in pure 90% alcohol or in such with the addition of a little acetic acid (1 to 2 drops to 50 c.c.), until the rinsing fluid is no longer colored. Before staining it is occasionally of advantage to treat the sections with acetic acid (2 : 1000) for one to two hours.

**79.** P. Mayer (96) advises fixation of the sections to the slide with the staining solution instead of water. On heating the slide the sections stain very energetically, and results are obtained which would otherwise be difficult to produce. Before the sections are placed in xylol to remove the paraffin, they must be thoroughly dried.

#### STAINING IN BULK.

Instead of staining in sections, entire objects can be stained before cutting. This method is in general much slower, and demands, therefore, special staining solutions, as, for instance:

**80.** Alcoholic borax-carmin solution (*vid.* T. 57).—Pieces  $\frac{1}{2}$  cm. in diameter remain in the stain at least twenty-four hours, are then decolorized for the same length of time in acid alcohol (0.5% to 1% hydrochloric acid in 70% alcohol), and after washing in 70% alcohol are transferred to 90% alcohol. Larger objects require a correspondingly longer time.

**81.** Paracarmin.—Treatment as in section staining, length of time according to size of object (*vid.* T. 58).

**82.** Alum-carmin of Grenacher (*vid.* T. 60). This never overstains. Time of staining according to size of object. Wash in water, then transfer to 70% and 90% alcohol.

**83.** Hemalum (*vide* T. 64), when diluted with water, is very useful for staining in bulk. After staining, objects should be washed with distilled water.

**84.** Böhmer's hematoxylin (*vid.* T. 61) stains small pieces very sharply. Use the same as hemalum.

**85.** Hematoxylin staining according to R. Heidenhain's method is especially recommended for staining in bulk.

Stain objects fixed in alcohol or picric acid twenty-four hours in a 0.33% aqueous solution of hematoxylin; transfer for an equal length of time to a 0.5% aqueous solution of potassium chromate, changing often until the color ceases to run. Wash with water and pass into strong alcohol. This stain also colors the protoplasm, and is so powerful that very thin sections are an absolute condition to the clearness of the preparation.

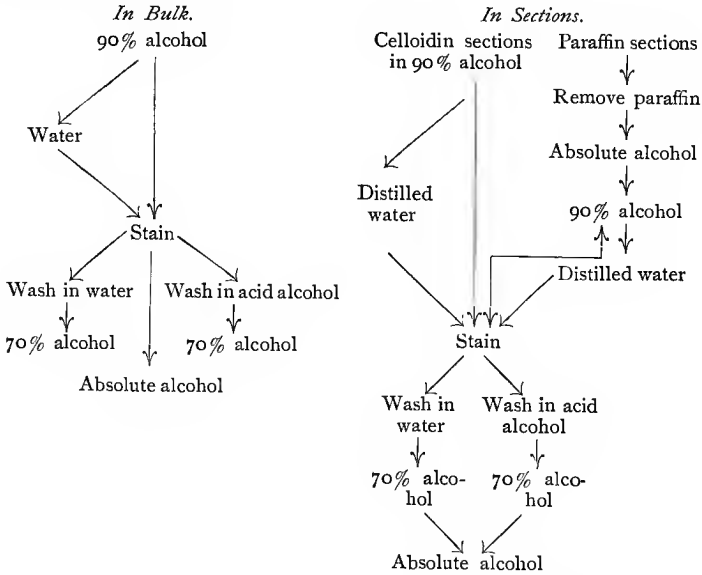
86. If the objects have been fixed with picric acid and the latter has not been entirely washed out, staining in bulk by the above methods produces very striking differentiation.

87. Pieces of tissue stained in bulk may be infiltrated, imbedded, and cut according to the ordinary methods. Under these circumstances, section staining is not necessary unless a still further differentiation be desired.

88. In general, then, the treatment of the object is somewhat as follows: First, it is fixed in some one of the fixing fluids already described, then carefully washed, and in certain cases stained in bulk before infiltrating with paraffin or celloidin; or the staining may be postponed until the tissue has been cut. In the latter case, the sections are subjected to the stain either loose or fastened to the slide or cover-slip.

89. In all cases it is absolutely essential that the paraffin be entirely removed. After the sections have been stained and washed, they are transferred to absolute alcohol in case it be desired to mount them in some resinous medium. They may also be mounted in glycerin or acetate of potash, into which they may be passed directly from distilled water.

90. The method of staining tissues in sections or in bulk is shown in the following diagrams:



**E. PREPARATION OF PERMANENT SPECIMENS.**

The resinous media used in the final mounting of preparations are Canada balsam and damar.

91. Commercial Canada balsam is usually dissolved in turpentine; it should be slowly evaporated in casserole and then dissolved in xylol, toluol, or chloroform, etc. The proper concentration of the solution is found with a little experience. A thick solution penetrates the in-

terstices of the section with difficulty, and usually contains air-bubbles which often hide the best areas of the preparation, and can only be removed with difficulty by heating over a flame. Thin solutions, on the other hand, have also their disadvantages; they evaporate very quickly, and the empty space thus created between the cover-slip and slide must again be filled with Canada balsam. This is best done by dipping a glass rod into the solution and placing one drop at the edge of the cover-slip, whereupon the fluid spreads out between the cover-slip and slide as a result of capillary attraction. Canada balsam dries rather slowly, the rapidity of the process depending upon the temperature of the room. To dry quickly, the slides may be held for a few moments over a gas or alcohol flame, or they may be placed in a warm oven, where the preparations become so dry in twenty-four hours that they can be examined with an oil-immersion lens. The oil used for this purpose should be wiped away from the cover-slip after examination. This can only be done, without moving the cover-slip, when the balsam is thoroughly dry and holds the cover-slip firmly in place.

92. Damar is dissolved preferably in equal parts of oil of turpentine and benzin. It has the advantage of not rendering the preparation as translucent as does Canada balsam. Otherwise it is used as the latter.

93. Since alcohol does not mix with Canada balsam and damar, an intermediate or clearing fluid is used in transferring objects from the former into the latter. Xylol, toluol, carbol-xylol (xylol, 3 parts; carbolic acid, 1 part), oil of bergamot, oil of cloves, and oil of origanum are ordinarily used.

94. The process is somewhat simpler where sections are fixed to the slide. Xylol is dropped onto the surface of the slide, or better, the whole preparation is placed for a few minutes in a vessel containing xylol until the diffusion currents have ceased (which may be seen with the naked eye). The slide is then taken out, tilted to allow the xylol to run off, wiped dry around the object with a cloth, and placed upon the table with the specimen upward. A drop of Canada balsam is now placed on the section (usually on its left side), and a clean cover-slip grasped with a small forceps. It is then gently lowered in such a way that the Canada balsam spreads out evenly and no air-bubbles are imprisoned under the glass. When this is done the preparation is finished.

95. If one is dealing with loose sections, a spatula or section-lifter is very useful in transferring them from absolute alcohol into the clearing fluid—carbol-xylol or bergamot oil (xylol evaporates very rapidly)—and from this onto the slide. In doing this it is necessary that the section should lie well spread out on the section-lifter, wrinkles being removed with a needle or small camel's-hair brush. In sliding the section off the spatula (with a needle or brush) a small quantity of the clearing fluid is also brought onto the slide. This must be removed as far as possible by tilting or with blotting-paper. The section can now be mounted in Canada balsam as before. For esthetic and practical reasons the student should see that during the spreading of the drop of Canada balsam the section remains under the middle of the cover-slip. Should it float to the edge, it is best to raise the cover-slip and lower it into place again. The cover-slip should never be slid over the specimen.

97. To mount in glycerin or acetate of potash (33% solution in distilled water), the sections are transferred from water to the slide, covered

with a drop of glycerin or acetate of potash, and the cover-slip applied. These methods are employed in mounting sections colored with a stain that would be injured by contact with alcohol, and where clearing is not especially necessary.

### 98. Farrant's Gum Glycerin.

In place of pure glycerin the following mixture may be used :

Glycerin . . . . .	50 c.c.
Water . . . . .	50 "
Gum-arabic (powder) . . . . .	50 gm.
Arsenious acid . . . . .	1 "

Dissolve the arsenious acid in water. Place the gum-arabic in a glass mortar and mix it with the water; then add the glycerin. Filter through a wet filter-paper or through fine muslin.

99. To preserve such preparations for any length of time the cover-glasses must be so fixed as to shut off the glycerin or acetate of potash from the air. For this purpose cements or varnishes are employed which are painted over the edges of the cover-slip. These masses adhere to the glass, harden, and fasten the cover-slip firmly to the slide, hermetically sealing the object. The best of these is probably Krönig's varnish, prepared as follows: 2 parts of wax are melted and 7 to 9 parts of colophonium stirred in, and the mass filtered hot. Before employing an oil-immersion lens it is advisable to paint the edge with an alcoholic solution of shellac.

## F. INTRODUCTION TO METHODS OF INJECTION.

100. A few remarks on the injection of the vascular system will not here be amiss, as it is only by this method that the relations of the blood-vessels to the neighboring tissue elements can be clearly brought out. The process consists in filling the vessels with a mass that can be injected in a fluid state but hardens readily, and is at the same time suitable for microscopic purposes and for sectioning methods. Of such substances there are a large number, and the technic of injection has been developed to such a degree that it has become a very important part of anatomic technic in general. Gelatin masses of different composition have come into general use for injecting the vascular system; of these, we shall here mention a red and a blue mass.

101. **Gelatin-carmin.**—The first is a gelatin-carmin mass, and is prepared as follows: (1) 4 gm. of carmin are stirred into 8 c.c. of water and thoroughly ground. Into this a sufficient quantity of ammonia is poured to produce a dark cherry color and render the whole transparent. (2) 50 gm. of finest quality gelatin is placed in distilled water for twelve hours until well soaked. It is then pressed out by hand and melted at a temperature of 70° C. in a porcelain evaporating dish. The two solutions are now slowly mixed, the whole being constantly stirred until a complete and homogeneous mixture is obtained. To this mass is added, drop by drop, a 25% acetic acid solution until the color begins to change to a brick red and the mass becomes slightly opaque. This should be very carefully done, as a single drop too much may spoil the whole. During this procedure the substance should be kept at 70° C. and constantly stirred. The change in color indicates that the reaction of the mass has become neutral or even slightly acid (an ammoniac solution should not be used, since the stain diffuses through the wall of the

vessel and colors the surrounding tissues) ; the whole is filtered through flannel while still warm.

**102.** The blue mass is prepared from an aqueous solution of Berlin blue. A saturated solution is made and poured (as above) into a solution of gelatin warmed to 70° C. until the desired intensity of color is obtained.

**103.** Injection masses already prepared are to be had in commerce. Besides those already mentioned, still others colored with China ink, etc., are in general use.

**104.** Small animals are injected as a whole by passing the cannula of a syringe into the left ventricle or aorta. In the case of large animals, or where very delicate injections are to be made, the cannula is inserted into one of the vessels of the respective organs. The proper ligation of the remaining vessels should not be omitted.

**105.** Before injecting, the animals or organs are kept warm in water heated to about 38° C. in order to prevent the injection mass from hardening before passing into the smaller vessels.

**106.** Before injecting, it is always desirable to thoroughly bleed the animal, or press out as carefully as possible all the blood contained in the organ.

**107.** Organs injected with carmin are fixed in alcohol and should not be brought in contact with acids or alkalis. Such parts as are injected with Berlin blue are less sensitive in their after-treatment. Pieces or sections that have become pale regain their blue color in oil of cloves.

**108.** If objects or sections injected with Berlin blue be treated with a solution of palladium chlorid, the bluish color changes to a dark brown which afterward remains unchanged (Kupffer).

**109.** In thin membranes and sections the vessel-walls can be rendered distinct by silver-impregnation, which brings out the outlines of their endothelial cells. This may be done either by injecting the vessel with a 1% solution of silver nitrate, or, according to the process of Chrzonszczewsky, with a 0.25% solution of silver nitrate in gelatin. This method is of advantage, since, after hardening, the capillaries of the injected tissue appear slightly distended. Organs thus treated can be sectioned, but the endothelial mosaic of the vessels does not appear definitely until the sections have been exposed to sunlight.

**110.** By means of the above injection methods other lumina can be filled, as, for instance, those of the glands. As a rule, these are only partially filled, since they end blindly, and their walls are less resistant and may be damaged by the pressure produced by the injection.

**111.** The injecting of lymph-channels, lymph-vessels, and lymph-spaces is usually done by puncture. A pointed cannula is thrust into the tissue and the syringe emptied by a slight but constant pressure. The injected fluid spreads by means of the channels offering the least resistance. For this purpose it is best to employ aqueous solutions of Berlin blue or silver nitrate, as the thicker gelatin solutions cause tearing of the tissues.

**112.** To bring out the blood capillaries and the lymphatic channels, Altman's process (79), in which the vessels are injected with olive oil, is useful. The objects are then treated with osmic acid, sectioned by means of a freezing microtome, and finally treated with eau de Javelle

(a concentrated solution of hypochlorite of potassium). By this process all the tissues are eaten away, the casts of the blood-vessels remaining as a dark framework (corrosion). The manipulation of these preparations is extremely difficult on account of the brittleness of the oil casts. For lymph-channels Altman (*ibid.*) used the so-called oil-impregnation. Fresh pieces of tissues, thin lamellæ of organs, cornea, etc., are placed for five to eight days in a mixture containing olive oil 1 part, absolute alcohol  $\frac{1}{2}$  part, sulphuric ether  $\frac{1}{2}$  part (or castor oil 2, absolute alcohol 1, etc.). The pieces are then laid for several hours in water, where the externally adherent globules of oil are mechanically removed and those in the lymph-canalicular system are precipitated. The objects are now treated with osmic acid, cut by means of a freezing microtome, and corroded. In this case, the corrosive fluid (eau de Javelle) should be diluted two or three times.

# GENERAL HISTOLOGY.

## I. THE CELL.

DURING the latter part of the seventeenth century, Hooke, Malpighi, and Grew, making observations with the simple and imperfect microscopes of their day, saw in plants small compartment-like spaces, surrounded by a distinct wall and filled with air or a liquid; to these the name *cell* was applied. These earlier observations were extended in various directions during the latter part of the seventeenth and the eighteenth century. Little advance was made, however, until Robert Brown (1831) directed attention to a small body found in the cell, previously mentioned by Fontana, and known as the *nucleus*. In the nucleus Valentin observed (1836) a small body known as the *nucleolus*. In 1838 Schleiden brought forward proof to show that plants were made up wholly of cells, and especially emphasized the importance of the nuclei of cells. In 1839 Schwann originated the theory that the animal body was built up of cells resembling those described for plants. Both Schleiden and Schwann defined a cell as a small vesicle, surrounded by a firm membrane inclosing a fluid in which floats a nucleus. This conception of the structure of the cell was destined, however, to undergo important modification. In 1846 v. Mohl recognized in the cell a semifluid, granular substance which he named *protoplasm*. Other investigators (Kölliker and Bischoff) observed animal cells devoid of a distinct cell membrane. Max Schultze (1861) attacked vigorously the older conception of the structure of cells, proclaiming the identity of the protoplasm in all forms of life, both plant and animal, and the cell was defined as a *nucleated mass of protoplasm endowed with the attributes of life*. In this sense the term cell is now used.

The simplest forms of animal life are organisms consisting of only one cell (*protozoa*). Even in the development of the higher animals, the first stage of development, the fertilized egg, is a single cell. This by repeated division gives rise to a mass of similar cells, which, owing to their likeness in shape and structure, are said to be undifferentiated. As development proceeds, the cells of this mass arrange themselves into three layers, the *germ layers*, the outer one of which is the *ectoderm*, the middle one the *mesoderm*, and the inner one the *entoderm*. In the further development, the cells of the germ layers change their form, assume new qualities, adapting

themselves to perform certain definite functions ; a division of labor ensues,—the cells become differentiated. Cells having similar shape and similar function are grouped to form *tissues*, and tissues are grouped to form *organs*.

We shall now consider the structure of the cell. Every cell consists of a cell-body and a nucleus.

### A. THE CELL-BODY.

The body of the cell consists of a substance known as protoplasm or cytoplasm. This is not a substance having uniform

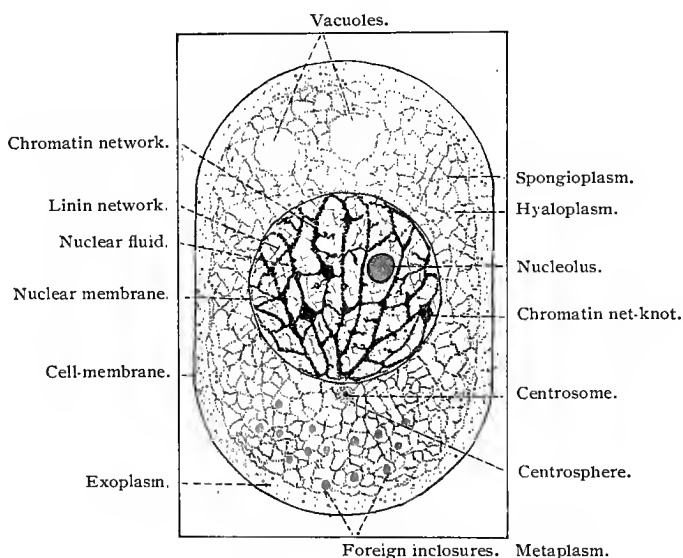


Fig. 7.—Diagram of a cell.

physical and chemic qualities, but a mixture of various organic compounds concerning which knowledge is not as yet conclusive, but which in general are proteid bodies or albumins in the widest sense.

In spite of the manifold differences in its composition, protoplasm exhibits certain general fundamental properties which are always present wherever it is found. Ordinarily, protoplasm exhibits certain structural characteristics. In it are observed two constituents,—threads or plates, which are straight or winding, which branch, anastomose, or interlace, and which are generally arranged in a regular framework, network, or reticulum. These threads probably consist of small particles arranged in rows, called cell-microsomes (*vid.* van Beneden, 83 ; M. Heidenhain, 94 ; and others). This sub-

stance is known as protoplasm in the stricter sense (Kupffer, 75); also as *spongioplasm*, or the fibrillar mass of Flemming (82). The other constituent of the cytoplasm is a more fluid substance lying between the threads in the meshes of the spongioplasmic network, and is known as *paraplasm* (Kupffer), hyaloplasm, cytolymph, or the interfibrillar substance of Flemming.

According to most investigators, the more important vital processes of the cell are to be identified with the spongioplasm, and are controlled by the nucleus, while the paraplasm assumes an inferior or passive rôle.

Protoplasm displays phenomena of motion, shown on the one hand by contraction, and on the other by the formation of processes that take the form either of blunt projections or lobes, or of long, pointed, and even branched threads or processes known as *pseudopodia*. The extension and withdrawal of the pseudopodia enable the cell to change its position. The point of such a process fastens to some object and the rest of the cell is drawn forward, thus giving the cell a creeping motion—*wandering cells*. Certain cells take up and surround foreign bodies by means of their pseudopodia. If these

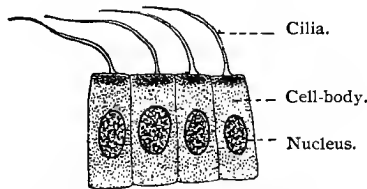


Fig. 8.—Cylindric ciliated cells from the primitive kidney of *Petromyzon planeri*;  
 × 1200.

bodies are suitable for nutrition, they are assimilated; if not, they can, under certain circumstances, be deposited by the cell in certain localities (Metschnikoff's phagocytes). Similar thread-like processes which, however, can not be drawn into the cell, occur in some cells in the shape of cilia, which are in constant and energetic motion—*ciliated cells*. Certain cells possess only a single long process, by means of which unattached cells are capable of direct or rotating motion—*flagellate cells*, *spermatozoa*.

Inside of the cell-body the protoplasm also shows phenomena of motion, the streaming of the protoplasm. In plant cells there is often a noticeable regularity in the direction of the current. Mention should not be omitted of the so-called *molecular* or *Brownian* movement in the cells, which consists in a rapid whirling motion of particles or granules suspended in the protoplasm (Brown).

Living protoplasm is irritable in the highest degree, and reacts very strongly to chemic and physical agents. It is very sensitive to changes in temperature. All the phenomena of life occur in greater intensity and more rapidly in a warm than in a cold temperature,

this fact being very strikingly shown by the phenomena of motion in the cell, as also in its propagation. By subjecting protoplasm to different temperatures, its various movements can be slowed or quickened. It dies in too high or too low a temperature.

Certain substances coming in contact with the cell from a given direction have on it an attracting or repelling action. These phenomena are known as positive and negative *chemotropism* (*chemotaxis*). The action of chemic agents on the different wandering cells of the body and on certain free-swimming unicellular organisms naturally varies to a great degree. Among these phenomena must be included those produced by water (hydrotropism) and light (heliotropism). It is very probable that all these phenomena are of importance to the proper appreciation of some of the processes going on in the vertebrate body (as, for instance, in the origin of diseases caused by micro-organisms).

Protoplasm may contain various structures. Of these, the *vacuoles* deserve special mention. They are more or less sharply defined cavities filled with fluid, and vary considerably in number and size. The fluids that they contain differ somewhat, but are always secreted by the protoplasm, and are, as a rule, finally emptied out of the cell. As a consequence, vacuoles are best studied where the function of the cell is a secretory one. Here they are often large, and sometimes fill up the whole cell, the contents of which are then emptied out (*glandular cells*).

Contents of a solid nature, such as fat, pigment, glycogen, and crystals, are peculiar to certain cells. By these deposits the cell is more or less changed, the greatest variation in form taking place in the production of fat. The latter, as a rule, takes the shape of a globule, and greatly modifies the position of the normal constituents of the cell. Deposits of pigment alter the cells to a less degree. This substance occurs in the protoplasm either in solution or in the form of fine crystalline bodies. Glycogen is more generally diffused, occurring very generally in embryonal cells and in the liver- and cartilage-cells of the adult. Occasionally we find larger crystals in animal cells, as, for instance, in the red blood-corpuses of the teleosts. So-called margaric crystals sometimes occur in large numbers as stellate figures in dead fatty tissues kept at low temperatures.

By employing certain methods the existence of granules can generally be demonstrated in protoplasm. Some authors even refer the vital qualities of protoplasm to these particular bodies (Altmann's bioblasts, 94).

In some cases the outer layer of the cell-protoplasm shows differentiation, leading to the formation of a distinct cell-membrane (as in fat-cells, cartilage-cells, goblet-cells, etc.). F. E. Schulze has given it the name *pellicula* in cases where the entire cell is surrounded by a homogeneous layer, and *cuticula* or cuticle where only one side of the cell is supplied with the membrane (as in the intestinal epithe-

lium). It is assumed that both spongioplasm and paraplast are concerned in the formation of this membrane.

In the protoplasm of many cells there is found a small body known as the *centrosome*. This is usually situated near the nucleus of the cell, occasionally in the nucleus. Generally, it has the appearance of a minute granule, sometimes scarcely larger than a microsome. It is often surrounded by a small area of a granular or finely reticular or radially striated cytoplasm, known as the *attraction-sphere* or *centrosphere*.

## B. THE NUCLEUS.

The second constant element of the cell is the nucleus. As a rule, it is sharply defined, and in its simplest form consists of a round vesicle of a complicated structure composed of several substances. The form of the nucleus corresponds in general to the shape of the cell; in an elongated cell, it is correspondingly long, and flattened where the cell is plate-like in shape. The nucleus of a wandering cell that is in the act of passing through a narrow intercellular cleft adapts itself to the changes of form in the cell without being permanently altered in shape. In other words, the nucleus is soft, and can be easily distorted by any solid substances within or without the protoplasm, only to resume its original form when the pressure is removed. It possesses, then, a certain amount of elasticity. Movements of certain nuclei, entirely independent of the surrounding protoplasm, have often been observed. It is only rarely that the form of the nucleus differs materially from that of the cell. This, however, occurs in the nuclei of leucocytes, which are often irregular, and may even be ring-shaped. In certain arthrozoa, branching forms of nuclei occur, as also in the skin glands of turtles. The proportionate size of nucleus to cell-body varies greatly in different cells. Especially large nuclei are found in immature ova, in certain epithelial cells, etc.

The contents of the nucleus consist of a framework or reticulum, in the meshes of which there is found a semifluid substance. In treating the nuclei with certain stains, the nuclear reticulum will be seen to consist of two constituents, a substance appearing in the form of variously shaped, minute granules, which stains deeply, and is, therefore, known as *chromatin*. This is imbedded in and deposited on a less stainable network, the *linin*. The meshes of this network are occupied by a transparent, semifluid substance, which does not stain easily, and is known as the *achromatic* portion of the nucleus. It is also known as paralinin, nuclear sap, karyolymph, or nucleoplasm. Chemically, chromatin belongs to those albuminous substances known as nucleins.

In well-stained nuclei of considerable size the chromatin granules are seen closely placed in a continuous row throughout the network of linin, which penetrates the nuclei in all directions. In

every resting nucleus one or more small round bodies are found imbedded in the nucleoplasm. These are known as true *nucleoli*, and do not stain quite so deeply as the chromatin. The fact that certain reagents dissolve the chromatin, but not the true nucleoli, proves that the substance of which the latter are composed is not identical with chromatin,—and is, therefore, known as *paranuclein* (F. Schwartz).

In many cases we find in the linin, granules of a substance known as lanthanin, which displays a marked affinity for the so-called acid anilin stains, in contradistinction to chromatin, which stains principally with the basic anilin colors. These are known as oxychromatin granules in contradistinction to the basichromatin granules of the chromatin (M. Heidenhain, 94).

The true nucleoli should not be confused with the slight swellings of the chromatin network found at the junction of the threads, and known as net-knots, or karyosomes.

Surrounding the resting nucleus is usually a *nuclear membrane* resembling in many respects chromatin. As a rule, it does not form a continuous layer, but is perforated, having openings that contain nuclear fluid. We have, then, both substances, chromatin and nucleoplasm, as elements of the nuclear membrane. Besides this, the nuclear membrane receives an outer layer, differentiated from the protoplasm. Newer investigations have shown that even during a period of rest the relationship of the nucleus to the protoplasm of the cell is much more intimate than was heretofore believed (*vid.* B. Reinke, 94).

A resting nucleus—*i.e.*, one not in process of division—usually consists, therefore, of a sharply defined membrane, which has in its interior a chromatic (nuclein) and an achromatic (linin) network, a nuclear fluid (paralinin), and nucleoli (paranuclein).

The chromatin of the nucleus is not always in the form of a network. In some cases—as, for instance, in the premature ova of certain animals (O. Hertwig, 93. II) and in spermatozoa—it is collected in compact bodies. In the ova it may often be mistaken for a true nucleolus (germinal spot). In this case, however, it consists of nuclein, and not of paranuclein.

### C. NUCLEAR AND CELL-DIVISION.

The founders of the cell theory believed in what may be known as a modification of the theory of spontaneous generation, stating that cells might originate from a structureless substance known as *kyto-blastema* or *blastema*, in which a nucleus was formed by precipitation. Henle (1841) drew attention to the fact that cells might multiply by the separation of small portions of the cell-body, a process known as *budding*; and Barry (1841) stated that during the multiplication of cells the nuclei divided. The same year Rcmak

observed division of cells in the blood of embryos. Goodsir (1845) originated the theory that all cells were developed from preexisting cells. This was first clearly stated as a general law by Virchow (1855), and his saying, "*Omnis cellula a cellula*," is constantly being verified. Our more accurate knowledge of cell-division dates, however, from more recent times (1873-80), when Schneider, Fol, Strasburger, Flemming, and many others demonstrated that during the division of the cell the nucleus passed through a series of complicated changes which resulted in an exact division of the chromatin.

The phenomena which usher in cell-division are especially noticeable in the nucleus, the elements of which are arranged and transformed in a typic manner. During the division of the nucleus the nuclear membrane is lost, and the relationship of the substances of the nucleus to the protoplasm of the cell is a very intimate one. As a consequence, during the middle phases of division there is no well-defined demarcation between the nucleus and the cell-body. As a rule, the mother cell and nucleus divide into two daughter cells, each having a nucleus, alike in every particular. It was early observed, however, that occasionally cells divided by a much simpler process, in which case the nucleus did not pass through such complicated changes. Accordingly, two distinct types of cell-division are recognized, which are distinguished as *mitosis*, *karyokinesis*, or *indirect* cell-division, and *amitosis*, or *direct* cell-division. Both lead to the formation of two nuclei, which are known as daughter nuclei as distinguished from the original mother nucleus.

### 1. MITOSIS OR KARYOKINESIS (INDIRECT CELL-DIVISION).

The description of the process of mitotic cell-division is complicated by the fact that structural changes are observed which occur simultaneously in the nucleus, centrosome, and cytoplasm. This fact should be borne in mind, as, for the sake of clearness, a separate description of the changes involving each of these structures seems demanded. The process of mitotic cell-division may be divided into four periods or phases, which follow one another without clearly defined limits:

The *prophases*, in which the nuclear membrane disappears, the chromatin is transformed into definite threads, and the centrosome and centrosphere undergo important changes. This is the preparatory stage.

The *metaphases*, in which the division and the separation of the chromatin take place.

The *anaphases*, in which the daughter nuclei are formed and the cell-protoplasm begins to divide.

The *telophases*, in which the division of the cell is completed.

To give a better understanding of this process, we have inserted a series of diagrammatic figures (9-19), giving the cells the shape of an ellipsoid. We can then distinguish a long axis, two polar

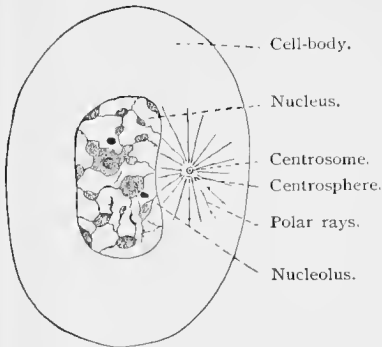


Fig. 9.

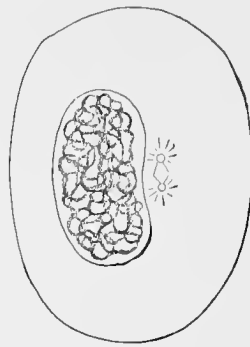


Fig. 10.

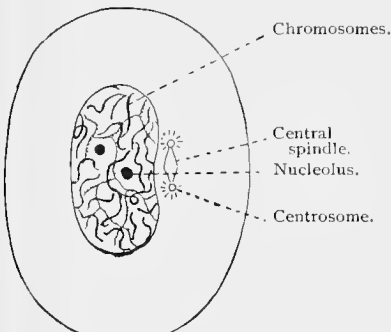


Fig. 11.

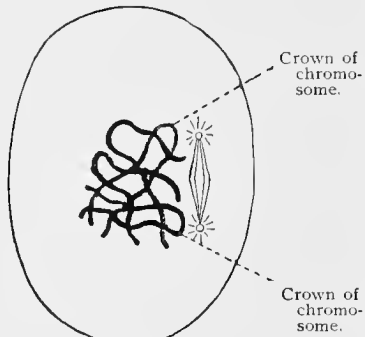


Fig. 12.

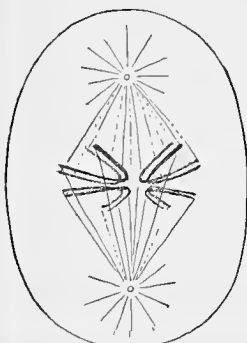


Fig. 13.

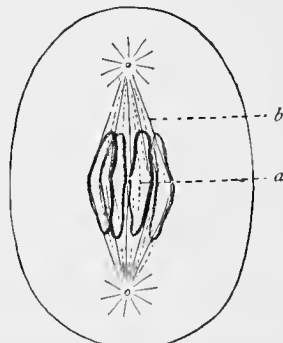


Fig. 14.

Figs. 9-14.—Diagrammatic representation of the processes of mitotic cell- and nuclear division.

Figs. 9-12, Prophases; Figs. 13, 14, metaphases.

Fig. 9, Resting nucleus; Fig. 10, coarse skein or spirem; Fig. 11, fine skein or spirem; Fig. 12, segmentation of the spirem into single chromosomes; Fig. 13, longitudinal division of the chromosomes; Fig. 14, bipolar arrangement of the separated chromosomes.

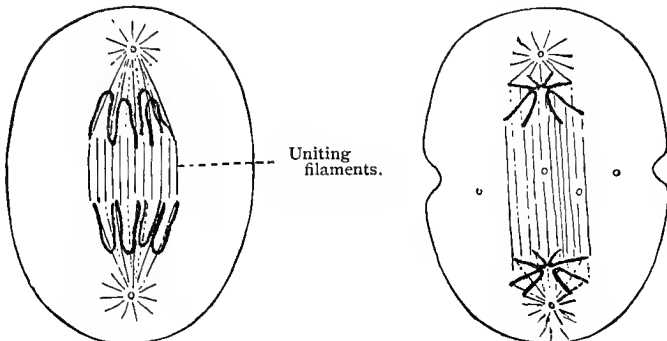


Fig. 15.

Fig. 16.

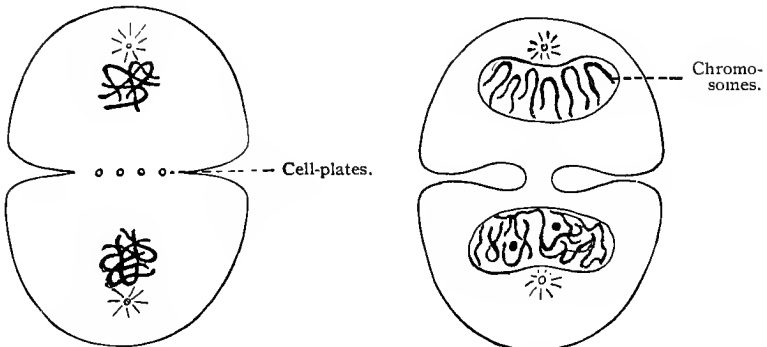


Fig. 17.

Fig. 18.

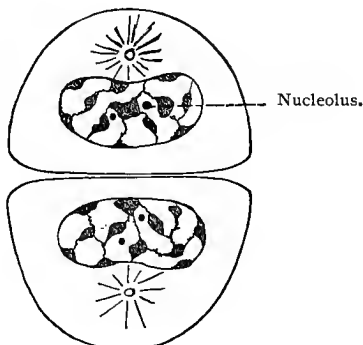
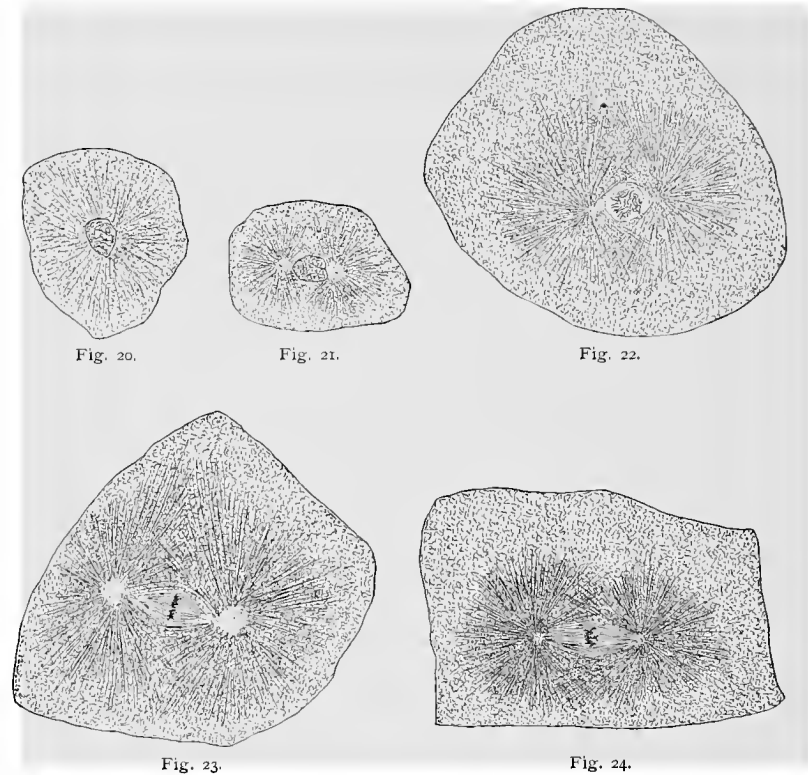


Fig. 19.

Figs. 15-19.—Diagrammatic representation of the processes of mitotic cell- and nuclear division.

Figs. 15-18, Anaphases; Fig. 19, telophases.

Fig. 15, wandering of the chromosomes toward the poles; Fig. 16, diastase; Figs. 17 and 18, formation of the dispirem; Fig. 19, two daughter cells with resting nuclei. To simplify the figures 12-17, we have sketched in only a few chromosomes. In Fig. 16 it is seen that the cell-body is also beginning to divide.



Figs. 20-24.—Mitotic cell-division of fertilized whitefish eggs—*Coregonus albus*.

Fig. 20, Cell with resting nucleus, centrosome, and centrosphere to the right of the nucleus; Fig. 21, cell with two centrospheres, with polar rays at opposite poles of nucleus; Fig. 22, spirem; Fig. 23, monaster; Fig. 24, metakinesis stage.

regions corresponding to the ends of the axis, and an equatorial plane. The latter is horizontal to the axis, equally distant from both poles, and passes through the middle of the nucleus. The division of the cell takes place in this plane. A series of figures (20-27), showing the different phases of mitotic cell-division of the fertilized eggs of the whitefish (*Coregonus albus*), is given; the changes involving the centrosome, centrosphere, and cytoplasm are clearly illustrated. Figure 28, showing a small portion of a section through the testis of the salamander, the object in which Flemming first observed this complicated series of changes, presents the appearance more generally seen during mitotic cell-division of the tissue cells of the higher vertebrates.

(a) **Prophases.**—The changes occurring in the nucleus will be considered first. At the beginning of the process of mitosis, the chromatin network, consisting of chromatin granules, is transformed into a twisted skein of threads, beginning at the periphery of the

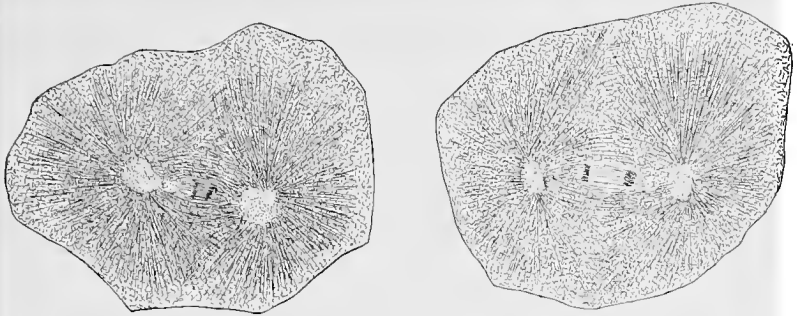


Fig. 25.

Fig. 26.

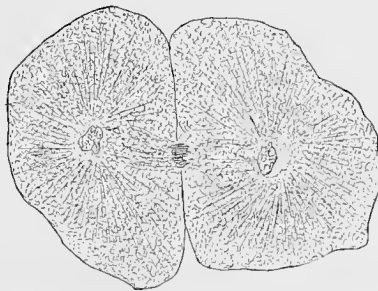


Fig. 27.

Figs. 25-27.—Mitotic cell-division of fertilized whitefish eggs—*Coregonus albus*.

Fig. 25; Metakinesis stage; Fig. 26, diaster; Fig. 27, late stage of dispirem, the cell-protoplasm almost divided.

nucleus. This skein of threads is known as the *spirem* or *mother skein*, and may appear as a single thread, which breaks up into a definite number of segments, or the segments may appear as such when the skein is forming. At first the threads are coarse and often somewhat irregular, staining much more deeply than the linin network. The separate segments of chromatin are known as *chromosomes* (Waldeyer, 88). They appear, as a rule, in the form of rods varying in length and thickness, and staining very deeply, and often bent into characteristic U-shaped loops. The bent portion of each loop is called its crown. "Every species of plant or animal has a fixed and characteristic number of chromosomes, which regularly recurs in the division of all its cells; and in all forms arising by sexual reproduction the number is even" (Wilson, 96). In man the number of chromosomes is given as sixteen by Bardeleben (92) and Wilson (96), and as twenty-four by Flemming (98).

During the formation of the spirem the nuclear membrane, as a rule, disappears. The nucleolus is also lost sight of, although the manner of its disappearance can not be definitely stated. The net-knots are no doubt taken up by the chromosomes. The chromo-

somes are now free in the protoplasm ; gradually the crown of each chromosome approaches the center of the space occupied by the nucleus, and the chromosomes form a characteristic, radially arranged stellate figure, known as the *monaster*, in the equatorial plane of the cell. During the progress of the changes affecting the chromatin of the nucleus and resulting in the formation of the chromosomes, important phenomena are observed, connected partly with the achromatic substance of the nucleus, more especially with the centrosome, centrosphere, and cytoplasm of the cell. These phenomena result in the formation of a complicated structure known as the *achromatic spindle* or *amphiaster*. Its development is as follows: The centrosome and centrosphere, as has been stated, usually lie in the protoplasm to one side of the nucleus. If, at the beginning of the division, the centrosome be single, it divides, and the two centrosomes begin to separate, causing a division of the centrosphere. Between the centrosomes are usually seen finely drawn-out connecting threads. The centrosomes, each of which is surrounded by a centrosphere, now move apart, and a structure known as the *central spindle*, and consisting of fine threads arranged in the form of a spindle, develops between them. At each end of the central spindle is found a centrosome surrounded by a centrosphere from which radiate into the cytoplasm fine fibers known as *polar rays*. During the formation of the achromatic spindle the nuclear membrane disappears and the chromosomes develop, as above described. Some fibers, which seem to have their origin from the centrosphere, grow into the spirem formed of chromosomes, which they appear to pull into the equatorial plane of the cell, which is also the equator of the central spindle. Thus, the nuclear figure above described as the monaster is formed. In other cases the centrosomes and centrospheres continue moving apart until opposite each other and separated by the nucleus (Figs. 21, 22). As the nuclear membrane disappears and the spirems and chromosomes are forming, the central spindle develops, its fibers running from centrosphere to centrosphere. The polar rays also develop in the cytoplasm at the same time. As the central spindle develops, the chromosomes arrange themselves or are arranged about its equator—monaster.

(*b*) **Metaphases.**—Usually, during the formation of the monaster, or immediately after its formation (sometimes in the spirem stage or even earlier), the most important process of cell-division takes place. Each chromosome divides longitudinally into two *daughter chromosomes*. The loops first divide at the crown, the cleft extending up either limb until the free ends are reached. The smallest particle of chromatin divides, retaining the exact relative position in the twin chromosomes that it possessed in the mother chromosome. The daughter chromosomes now wander over the central spindle, their crowns presenting, in opposite directions toward the poles of the cell. This process is known as *metakinesis*. Two stel-

late figures are developed about the respective poles of the central spindle. The appearance presented is known as a *diaster*. Our knowledge of the part taken by the amphiaster or achromatic spindle in metakinesis is not above controversy. It would appear, however, that certain cytoplasmic fibers, which arise from the centrosphere and hang over the central spindle and chromosomes, designated as *mantle fibers*, assist in drawing the daughter chromosomes toward the poles of the central spindle.

(c) **Anaphases.**—After the formation of the diaster, the loops belonging to each stellate figure are joined together to form a skein, thus forming the *dispirem*. The chromatin threads of the two skeins gradually assume the disposition found in the resting nucleus. This process takes place in such a way that the threads of the

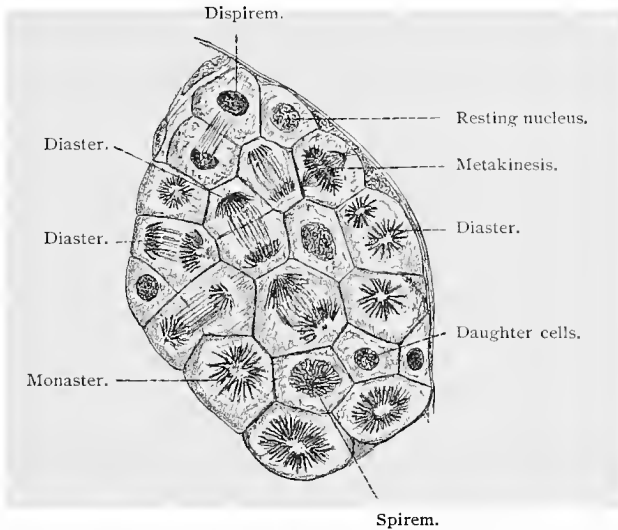


Fig. 28.—Mitotic division of cells in testis of salamander (Benda and Guenther).

skeins (or the single thread) send out lateral processes. These interlace, and little by little reproduce the network of the resting nucleus; at the same time the nuclear membrane and the nucleolus reappear. In this stage the changes that lead to the division of the cell-body are observed. In some cases the division of the cell-body is ushered in by an equatorial differentiation of the connecting threads of the central spindle. Chains of granules, arranged in double rows, are seen to appear in this region. The cell now begins to contract at its equator, the contraction extending between the two chains of granules until the cell is completely divided. At this time, also, the threads of the amphiaster disappear or are drawn into the nucleus. The centrosomes, with centrospheres, again lie by the side of the daughter nuclei.

According to the opinion of C. Rabl (85), there remains in the nucleus, even after it has fully returned to a state of rest, a polar arrangement of the chromatin loops—that is, an arrangement of the axis of the loops in the direction of the centrosphere. The area toward which the crowns of the loops point is known as the *polar field*.

The equatorial differentiation of the connecting threads of the central spindle, above mentioned, was first observed in vegetable tissue, and is known as the *cell-plate*. (Fig. 27.) In animal cells such a plate is relatively rare, and, when seen, is found developed in a rudimentary form (v. Kostanecki 92, I).

(d) **Telophases** (M. Heidenhain 94).—In these phases of mitosis the cell divides completely. The daughter nuclei and centrospheres, which do not yet occupy their normal position in the daughter cells, show movements that result in their assuming their normal positions.

From our description it is seen that the anaphases represent the same stages as the prophase, only in an inverted sequence. In the latter case, the result is the resting nucleus, while the prophase leads to the metaphases.

The fertilized ovum also divides by indirect nuclear division. (Figs. 20–27.) From it are derived, by this process, the segmentation cells, or *blastomeres*, from which the whole embryo is developed.

(c) **The Heterotypic Form of Mitosis**.—The above-described type of indirect or mitotic nuclear division (*homeotypic mitosis*) is the usual one. Variations, however, occur, as, for instance, in the so-called *heterotypic* form of division (Flemming 87), which occurs in certain cells of the testes (spermatocytes). In this form the first stages are lacking, the nucleus possessing from the beginning a skein-like structure. The longitudinal splitting and division of the chromatin threads take place during the first spirem stage, after which there is a phase in which the figure may be compared with an aster of ordinary mitosis, although the free ends of the threads in this case are seldom observed. The latter is due to the fact that after the longitudinal splitting, the ends of the chromosomes remain united, or, if entire separation occurs, they are again joined. In this way closed loops are formed extending from pole to pole. Later the threads break at the equator and move toward the poles, again dividing to form the daughter stars.

## 2. AMITOSIS.

Very different from the indirect form of nuclear division is the *direct* or *amitotic*. It appears to occur seldom as a normal process, and is only exceptionally followed by a subsequent cell-division (vid. Flemming, 91, III). As a consequence, this process, in most cases, results in the formation of *polynuclear cells* (polynuclear leucocytes, giant-cells, etc.). The complicated nuclear figures of

indirect division are here entirely absent. The nucleus merely contracts at a certain point and separates into two or more fragments (*direct fragmentation*, Arnold); often the nucleus first assumes an annular form and then breaks up into several fragments, which remain loosely connected (polynuclear cells). Centrospheres are also present, and appear to take a prominent part in the whole process, although the exact relationship between the achromatin and chromatin has not as yet been determined.

Arnold (83) gives the following comparison of indirect and direct nuclear division: (1) Segmentation. Division of the nuclei in the equatorial plane into two or more equal parts; (*a*) direct segmentation *without*, (*b*) indirect segmentation *with*, increase and changed arrangement of the chromatic substance (mitosis). (2) Fragmentation. Contraction of the nucleus at some point, forming two or more equal, but oftener unequal, nuclear fragments; (*c*) direct fragmentation *without*, (*d*) indirect fragmentation *with*, increase and changed arrangement of the chromatin substance.

#### D. PROCESS OF FERTILIZATION.

The sexual cells form a special group among cells in general. Before the division of the egg-cell leading to the development of the embryo can take place, the ovum must be impregnated (the so-called parthenogenetic ova are an exception to this rule). Fertilization is produced by the male sexual cell, the spermatozoon.

The process of fertilization consists in a conjugation of two sexual cells, and in this process certain peculiarities in the behavior of both cells must be mentioned.

The cell forming the ovum and the one forming the spermatozoon must pass through certain stages before fertilization can be accomplished. These consist in the loss of half their chromosomes by the nuclei of both sexual cells. In this way are produced the *matured* sexual cells (ova and spermatozoa), which retain only half of the number of chromosomes of a *somatic* (body-) cell. In the conjugation of the male and female sexual cells their nuclei unite to form a single nucleus, known as the *segmentation nucleus*. Consequently, this nucleus contains the same number of chromosomes as does that of a somatic cell.

In its earlier developmental stages the ovum is an indifferent cell, the nucleus of which is known as the *germinal vesicle*. As the ovum matures the germinal vesicle approaches the periphery, and a peculiar metamorphosis, which may be regarded as a double, unequal division of the egg-cell, takes place. One portion, in the case of both divisions, is much smaller than the other, and is known as a *polar body*. At the close of these divisions, during which the chromosomes have been reduced to half the original number, there are, therefore, two polar bodies and the matured ovum, which is now ready for impregnation.

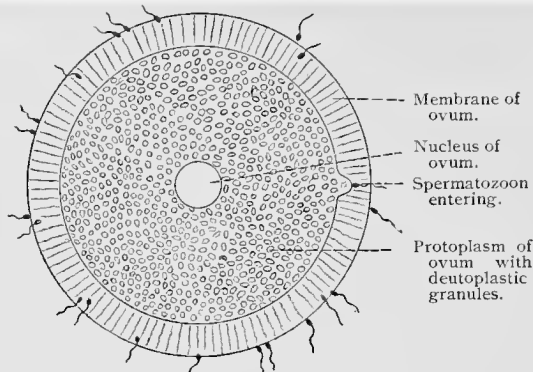


Fig. 29.

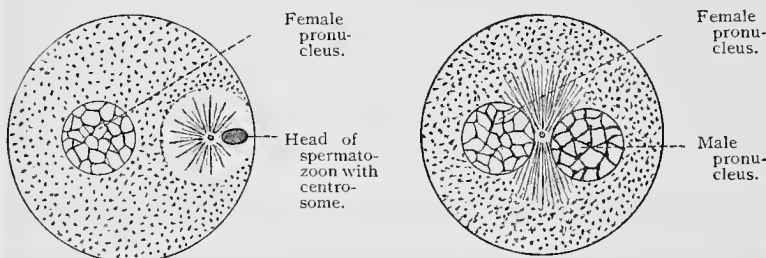


Fig. 30.

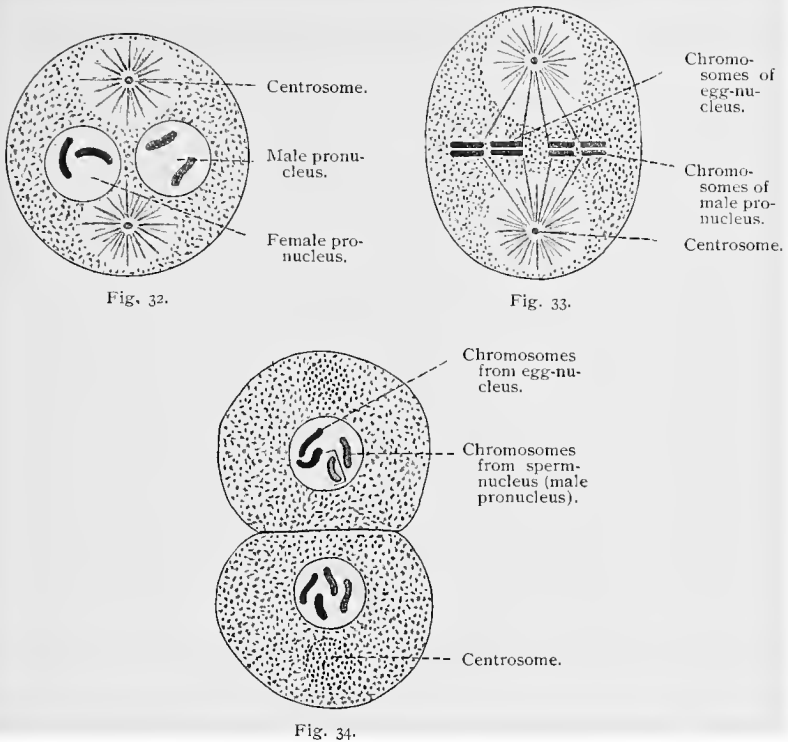
Fig. 31.

Figs. 29-31.—Diagrams of the process of fertilization, after Boveri (88).

Figure 29, the ovum is surrounded by spermatozoa, one of which is in the act of penetration. Toward it the yolk is pushed forward in a short, rounded process. Figure 30, the tail of the spermatozoon has disappeared. Beside the head is a centrosome with polar radiation. Figure 31, the pronuclei approach each other.

The development of the male sexual cell in its earlier stages is similar to that of the ovum. They are derived from cells known as *spermatogones*. These divide into equal parts, forming the cells of a second generation, the *spermatocytes*. From a further division of the spermatocytes, during which division the chromosomes are reduced to half the number, the *spermatids* are produced. These latter are then changed directly into spermatozoa. The reduction division of the egg-cell and that of the spermatocytes is in principle the same, except that in spermatogenesis *all* cells become matured sexual cells (spermatozoa). In short, there is here an absence of structures analogous to the polar bodies, which degenerate after maturation of the ovum.

The spermatozoa are flagellate cells. The head consists principally of nuclear substance, to which is added a smaller middle-piece containing, according to the investigations of Fick, the centrosome. These two portions of the male sexual cell, the head- and



Figs. 32-34.—Diagrams of the process of fertilization, after Boveri (88).

Figure 32, from the spirems in the pronuclei, chromosomes have been formed. The centrosphere has divided. Figure 33, the double chromosomes of the two pronuclei lie in the equatorial plane of the ovum. Figure 34, the ovum has divided. Chromosomes from the male and female elements are seen in equal numbers in both daughter nuclei.

middle-piece, are the most important, and are exclusively concerned in fertilization, the flagellum or tail playing no part in this process.

The spermatozoon usually penetrates the ovum after the first polar body has been extruded. The tail disappears during this process, being either left at the periphery of the egg or dissolved in the protoplasm. From this time the head represents the so-called *male pronucleus*, and the middle-piece the centrosome. From this stage the male pronucleus undergoes changes, the first of which consists of a loosening of the chromatin. Chromatin granules are formed, which later arrange themselves in the form of chromosomes.

After the second polar body has been extruded, the chromatin remaining in the ovum is transformed into the *female pronucleus*. The latter then approaches the male pronucleus, the membranes of both nuclei disappearing. The chromosomes of

the two nuclei thus formed are of equal number, and now come to lie together. After a longitudinal division of the chromosomes, the daughter chromosomes glide along the filaments of the achromatic spindle, developed from the centrosome of the male pronucleus, toward its two poles, as in ordinary mitosis. This they do in such a manner that an equal distribution of the male and female daughter chromosomes results. Then follow the stages of the anaphase.

From the above description of the process of fertilization it is seen that it consists, in the end, of a union of the nuclei of both sexual cells.

If paternal qualities are inherited by the offspring, this can only take place through the nucleus, or through the centrosome of the male sexual cell. In other words, it can be safely said that these structures, or the nucleus alone, are the principal means of transmitting inherited qualities. The same may also be said of the female pronucleus. There is no doubt that the first two segmentation cells of the ovum are equally provided with male and female nuclear elements. Since all future cells are derivatives of these two, it is possible that the nucleus of every somatic cell (body-cell) is hermaphroditic.

## E. CHROMATOLYSIS.

In the living organism many cells are destroyed during the various physiologic processes and replaced by new ones. On the death of a cell, changes take place in its nucleus which result in its gradual disappearance. These processes, which seem to follow certain definite but as yet unfamiliar laws, have been known since their study by Flemming (85, I) by the name of *chromatolysis* (karyolysis). The nuclei during the course of these changes show many varied pictures.

### TECHNIC.

**113.** In a fresh condition, cells do not show much of their internal structure. Epithelial cells of the oral cavity, which can easily be obtained and examined in the saliva, show really nothing except the cell outlines and the nuclei. More, however, can be seen in young ova isolated from the Graafian follicles of mammalia; or the examination may be facilitated by using the ovary of a young frog. Tissues that are especially adapted for the observation of cells in a fresh condition are small ova, blood-corpuscles, and epithelia of certain invertebrate animals (shellfish, etc.). Unicellular organisms such as amebæ, infusoria, and many low forms of vegetable life make also good material for this purpose.

**Protoplasmic currents** are best seen in the tactile hairs of the nettle. Should fresh animal cells be desired, amebæ can occasionally be found in muddy or marshy water. The same phenomena may be observed in the leucocytes of the frog or, better still, in the blood of the crab.

**114.** In order to make a detailed study of the minute relationship of the different cellular structures, it is necessary to fix the cells; the same is true of nuclear division and cell proliferation. Although this process has been observed in living cells, it was not until it had been thoroughly worked out in preserved preparations. The best results in the study of the cell are obtained by methods that will be subsequently described. Fresh tissues are absolutely essential.

According to Hammer, mitosis in man does not cease immediately after death. The nuclei suffer chromatolytic destruction, and the achromatic spindle is the last element to disappear.

**115. Flemming's solution** (*vid.* T. 17) here deserves first mention as a fixative. The tissues are imbedded, sectioned, and stained with safranin (*vid.* T. 66). An equally good fixative is Hermann's solution, which may be combined with a subsequent treatment with pyroligneous acid (*vid.* T. 18). Rabl fixes with a 0.1-0.12% solution of chlorid of platinum, washes with water, passes into gradually stronger alcohols, then stains with Delafield's hematoxylin (*vid.* T. 62), and finally examines the preparation in methyl alcohol.

**116.** Mitoses can also be seen by fixing in **corrosive sublimate, picric acid, chromic acid, etc.**, and staining in bulk with hematoxylin or carmin, although perhaps not so well as by the preceding method. The objects to be examined are best when obtained from young and growing animals, especially those possessing large cells. Above all are to be recommended the larvæ of amphibia, like the frog, triton, and salamander. If examination by means of sections be undesirable, thin structures should be procured, such as the mesentery, alveoli of the lungs, epithelium of the pharynx, urinary bladder, etc. These have the advantage of enabling one to observe the whole cell instead of parts or fragments of cellular structures. In sections of a larva that has been fixed *in toto*, mitotic figures can be seen in almost all the organs, and are particularly numerous in the epithelium of the epidermis, gills, central canal of the brain and spinal cord, etc. Other organs, such as the blood, liver, and muscle, also show mitoses.

**117.** Certain vegetable cells are peculiarly adapted to the study of mitosis, as, for instance, those in the ends of young roots of the onion. The onion should be placed in a hyacinth glass filled with water and kept in a warm place. After two or three days numbers of small roots will be found to have developed. Beginning at the points, pieces 5 millimeters in length are cut, which are treated in the same manner as animal tissues. These are then cut, either transversely or longitudinally, into very thin sections (not over 5  $\mu$  in thickness). In one plane, polar views of the mitoses are obtained; in the other, lateral views.

**118.** The methods used for demonstrating the remaining parts of the cell and its nucleus (except the chromatin) are, as a rule, more complicated, and consequently less reliable. In order to see the centrosome, the spindle fibrils, the linin threads, and the polar rays, one of the methods already described may be used; viz., the treatment with pyroligneous acid of objects previously fixed in osmic acid mixtures.

**119.** According to Hermann (93, II), sections from such preparations can be **double-stained** as well as those that have not been treated with pyroligneous acid. They are accordingly stained with safranin in the usual manner, and afterward treated from three to five minutes with

the following solution of gentian violet: 5 c.c. of a saturated alcoholic solution of the stain is dissolved in 100 c.c. of anilin water. The latter is composed of 4 c.c. of anilin oil in 100 c.c. of distilled water. This is shaken in a test-tube and then filtered through a wet filter. The sections are then placed in a solution of iodine and iodide of potassium (iodine 1 gm., iodide of potassium 2 gm., water 300 c.c.) until they have become entirely black, after which they are immersed in alcohol until they receive a violet tinge with a slight dash of brown. By this means the chromatin network, the resting nuclei, and the chromosomes in both of the spirem stages appear bluish-violet, while the true nucleoli are pink. The chromosomes of the aster and diaster are colored red.

120. Flemming (91, III) recommends the following method: Fixation by his mixture (T. 17); the specimens or thin sections are then placed in safranin from two to six days (T. 66), washed for a short time in distilled water, and then immersed in absolute alcohol weakly acidulated with hydrochloric acid (1:1000), until no more color is given off. They are then washed again with distilled water and placed in a concentrated solution of anilin-water-gentian-violet from one to three hours. After a third rinsing in distilled water, they come into a concentrated aqueous solution of orange G, until they begin to assume a violet color. Then wash with absolute alcohol, clear in clove or bergamot oil, and mount in Canada balsam.

121. A comparatively simple method showing the different structures of the cell and its nucleus with great clearness consists in staining with Heidenhain's hematoxylin (*vid.* T. 65).

122. Solger (89, I and 91) has discovered that both chromosomes and polar rays are shown in an exquisite manner in the pigment cells of the skin (corium) of the frontal and ethmoidal regions of the common pike (*vid.* Fig. 35). The preliminary treatment is optional, Flemming's solution or corrosive sublimate being the best. These cells illustrate the stability of the radiate structures of protoplasm, the polar rays showing as parallel rows of pigment granules.

123. The various structures of resting and dividing nuclei and cells are of such a complicated nature that they can be observed only with great difficulty in ordinary objects, because of the crowding of so many elements into a comparatively small space. For example, salamandra maculosa, which has become a classic histologic object through the researches of Flemming, possesses somatic cells whose nuclei have no less than twenty-four chromosomes. (It may here be remarked that, curiously enough, salamandra atra has only half this number.) Consequently, van Beneden's discovery (83), that the somatic cells of ascaris megaloccephala have only four primary chromosomes, is a fact of considerable importance. Boveri (87, II and 88) has even found an ascaris showing only two chromosomes. As these animals also show distinct achromatic figures in the protoplasm of their ova and sperm cells, they are certainly worthy of being regarded as typical specimens for laboratory purposes. The processes of cell-proliferation are almost diagrammatic in their distinctness.

After opening the abdominal wall of the animal, the ovisacs are removed, their numerous convolutions separated as much as possible, and then fixed for twenty-four hours in a picric-acetic acid solution

(a concentrated aqueous solution of picric acid diluted with 2 vols. of water to which 1 per cent. glacial acetic acid is added). Then follows washing for twenty-four hours with water, after which the specimen is transferred to increasing strengths of alcohol (Boveri, *ibid.*). Different regions of the ovisacs contain ova in various stages of development, those nearest the head containing cells ripe and ready for fecundation, while in the more posterior regions are ova in varying stages of segmentation showing mitoses. Specimens fixed in the manner above described can be stained with a borax-carmin solution. After staining, the ova are gently pressed out with needles upon a slide, separated, covered with a cover-glass, and cleared by gradual irrigation with glycerin. The ova, especially the segmentation spheres, are very small, and can be examined only under high magnification. In spite of the minuteness of the object and the fact that the yolk does not take the stain, and, on account of

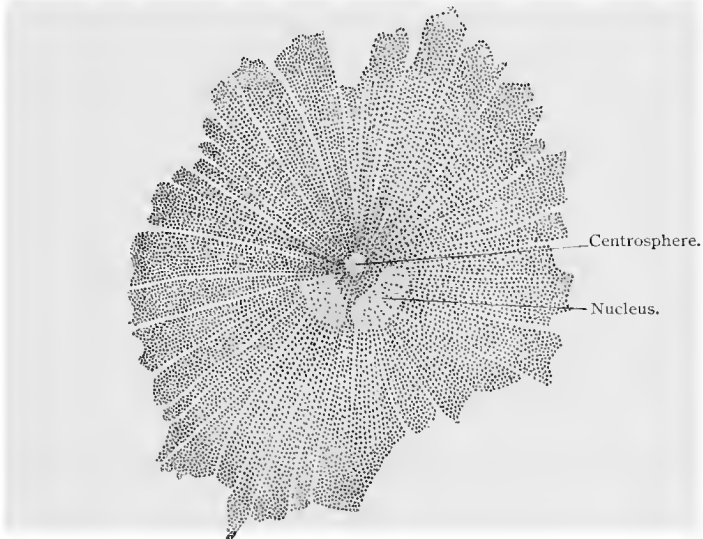


Fig. 35.—Pigment cell from the skin of the head of a pike ;  $\times$  650. T. No. 122.

its high refractive index, distorts the picture to a considerable extent, the mitotic figures are beautifully distinct.

**124.** Certain methods of treatment bring out in both cells and nuclei the presence of peculiar granules. The latter have been especially studied and described by v. Altmann (94, 2d ed.). The methods that he applies are as follows: The specimens of organs of recently killed animals are fixed in a mixture consisting of equal volumes of a 5% aqueous solution of potassium bichromate and a 2% solution of osmic acid, remaining in the mixture for twenty-four hours. They are then washed for several hours in water and treated with ascending strengths of alcohol; viz., 70, 90, and 100%. The specimens are now placed in a solution of 3 parts of xylol and 1 part of absolute alcohol, then in pure xylol, and finally in paraffin. The tissues imbedded in paraffin must not be cut thicker than 1 to 2  $\mu$ .

Altmann mounts according to the following method: A rather thick

solution of caoutchouc in chloroform (the so-called traumaticin of the Pharmacopeia—1 vol. guttapercha dissolved in 6 vols. chloroform) is diluted before use with 25 vols. of chloroform and the resulting mixture poured upon a slide. The latter is tilted, and after evaporation of the chloroform, heated over a gas flame. The paraffin sections are mounted upon the slides so prepared and then painted with a solution of guncotton in acetone and alcohol (2 gm. guncotton dissolved in 50 c.c. of acetone, 5 c.c. of which is diluted with 20 c.c. of absolute alcohol). After painting with this solution, the sections are firmly pressed upon the slide with tissue paper, and after drying are made to adhere more closely by slight warming. Fixation to the slide with water is equally good. The sections can now be treated with various staining solutions without becoming detached from the slides. The paraffin is gotten rid of by immersing in xylol, after which the specimens are placed in absolute alcohol. Fuchsin S. can be used as a stain (20 gm. fuchsin S. dissolved in 100 c.c. anilin water). A small quantity of this solution is placed upon the section, and the slide warmed over a flame until its lower surface becomes quite perceptibly warm and the staining solution begins to evaporate. The slide is then allowed to cool, washed with picric acid (concentrated alcoholic solution of picric acid diluted with 2 vols. of water), after which it is covered with a fresh quantity of picric acid, and again, but this time vigorously, heated (one-half to one minute). Occasionally the same results can be obtained by covering the section for five minutes with a cold solution of picric acid of the above strength. This last procedure has a decided influence upon the granula, and gives rise to a distinct differentiation between them and the remaining portions of the cell, the latter appearing grayish-yellow, while the granula themselves appear bright red. In some cases where the granula can not be sharply differentiated from the remaining structures, it may be necessary to repeat the staining process. Xylol-Canada balsam should not be used for mounting, as it has a bleaching effect upon the osmic acid in the specimen. Mount either in liquid paraffin (Altmann) or in undiluted Canada balsam, which is easily reduced to a fluid state, whenever needed, by heating.

There is another method used by Altmann which deserves mention, but practical application of which must be improved upon in the future; this consists in freezing the specimens and drying them for a few days in the frozen condition in a vacuum over sulphuric acid at a temperature of about  $-30^{\circ}$  C.

According to Fischer, dilute solutions of pepton when treated with various reagents (especially with a potassium bichromate-osmium mixture) form precipitates and granules which are remarkable in that they react to stains exactly as do Altmann's granula. It is, therefore, doubtful whether Altmann's granules should be regarded as vital structures.

125. Altmann (92) has also devised a simpler negative method for demonstrating the granula. Fresh specimens are placed for twenty-four hours in a solution consisting of molybdate of ammonium 2.5 gm., chromic acid 0.35 gm., and water 100 c.c.; then treated for several days with absolute alcohol, sectioned in paraffin, and colored with a nuclear stain such as hematoxylin or gentian. The intergranular network is colored, while the granula remain colorless. The amount of chromic acid used (0.25 to 1%) varies according to the object treated; if molybdate of ammonium alone be used, the nuclei will appear homogeneous,

while if an excess of chromic acid be employed, the nuclei will appear coarsely reticulated. This method leads to the formation of granula in the cells as well as in the nucleus.

126. By fixing and staining cells of widely different vegetable and animal types Bütschli believes he has demonstrated the existence of protoplasmic structures having the form of bubbles and termed by him microscopic *foam-structures*. Fixing is done either in picric acid solution or in weakly iodized alcohol. The specimens are then stained with iron-hematoxylin—*i. e.*, first treated with acetate of iron, rinsed in water, and transferred to a 0.5% aqueous solution of hematoxylin (similar to the method of R. Heidenhain (*vid.* T. 85)). Very thin sections are required ( $\frac{1}{2}$  to  $1 \mu$ ). Mounting is done, when the lighting is good, in media having low refractive indices, which emphasize the alveolar or foam-like structure of the protoplasm. Of various animal objects, Bütschli especially recommends young ovarian eggs of teleosts, and blood-cells and intestinal epithelium of the frog, etc. It is still a matter of uncertainty whether or not the structures are actually present in living protoplasm.

## II. THE TISSUES.

The first few generations of cells which result from the segmentation of the fertilized ovum have no pronounced characteristics. They are embryonic cells of rounded form, and are known as *blastomeres*. As they increase in number they become smaller and of polygonal shape, owing to the pressure to which they are subjected. From the mass of blastomeres, known as the *morula mass*, there are formed, under various processes described under the name of *gastrulation*, two layers of cells, the so-called *primary germ layers*, of which the outer is the *ectoderm*, the inner the *entoderm*. To the primary germ layers is added still a third layer, called the *mesoderm*; it is derived from both the ectoderm and entoderm, but principally from the latter. From these three layers of cells, known as the *primary blastodermic layers*, are developed all the tissues, each layer developing into certain tissues that are distinct for this layer. In their further development and differentiation the cells of the blastodermic layers undergo a change in shape and structure characteristic for each tissue, and there is developed an *intercellular substance* varying greatly in amount and character in the several tissues. In the tissues developed from the ectoderm and entoderm the cellular elements give character to the tissue, while the intercellular substance is present in small quantity; in the majority of the tissues developed from the mesoderm, the intercellular substance is abundant, while the cellular elements form a less conspicuous portion.

The tissues derived from the **ectoderm** are :

The epidermis of the skin, with the epidermal appendages and glands; the epithelium lining the mouth, with the salivary glands and the enamel of the teeth; the epithelium and glands of the nasal tract and the cavities opening into it; the lens of the eye and retina,

and the epithelium of the membranous labyrinth of the ear ; and finally, the entire nervous system, central and peripheral.

From the **entoderm** :

The epithelium lining the digestive tract, and all glands in connection with it, including the liver and pancreas ; the epithelium of the respiratory tract and its glands ; the epithelium of the bladder and urethra (in the male, only the prostatic portion, the remainder being of ectodermal origin).

The cells of the **mesoderm** are early differentiated into three groups (Minot, 99) :

(a) *Mesothelium*.—The mesothelial cells retain the character of epithelial cells. They form the lining of the pleural, pericardial, and peritoneal cavities, and give origin to the epithelium of the urogenital organs (with the exception of the bladder and urethra), and striated and heart muscle tissue.

(b) *Mesenchyme*, from which are derived all the fibrous connective tissues, cartilage, and bone, involuntary muscle tissue, the spleen, lymph-glands, and bone-marrow ; and cells of an epithelioid character, lining the blood and lymph-vessels and lymph-spaces, known as *endothelial cells*.

(c) *Mesameboid cells*, comprising all red and white blood-cells.

It would be extremely difficult to attempt a classification of tissues according to their histogenesis, as identical tissue elements owe their origin to different germinal layers. The classification adopted by us is based rather on the structure of the tissues in their adult stage.

We distinguish :

- A. Epithelial tissues with their derivatives.
- B. Connective tissues ; adipose tissue ; supporting tissues (cartilage, bone).
- C. Muscular tissue.
- D. Nervous tissue.
- E. Blood and lymph.

## A. EPITHELIAL TISSUES.

Epithelial tissues are nonvascular, and composed almost wholly of epithelial cells, united into continuous membranes by a substance known as intercellular cement. They serve to protect exposed surfaces, and perform the functions of absorption, secretion, and excretion.

The epithelia are developed from all of the three layers of the blastoderm.

They secrete the cement-substance found between their contiguous surfaces. This takes the form of thin lamellæ between the cells, gluing them firmly together. In certain regions the epithelial cells develop short lateral processes (prickles), which meet like structures

from neighboring cells, thus forming *intercellular bridges*. Between these bridges are *intercellular spaces* filled with lymph-plasma for the nourishment of the cells. Epithelia do not, as a rule, possess processes of any length. However, it would appear that the *basement membranes*, situated beneath the epithelia, consist chiefly of processes from the basal portion of the cells. Some authors ascribe to them a connective-tissue origin, a theory which conflicts with the fact that such membranes are present in the embryo before connective tissue, as such, has been developed (*membrana prima*, Hensen, 76).

The free surfaces of epithelia often support *cuticular structures* which are to be regarded as the products of the cells. The cuticulæ of neighboring cells fuse to form a *cuticular membrane* or *marginal zone* which can be detached in pieces of considerable size (cuticula). In longitudinal sections the cuticula show, in many cases, a striation which would seem to indicate that they are composed of a large number of rod-like processes cemented together by a substance possessing a different refractive index. The cell-body is also striated for more than half its length, corresponding to the rods of the marginal zone. In the region of the nucleus at the basal portion the striation disappears, the cell here consisting of granular protoplasm of a more indifferent character.

Since one surface of each epithelial layer lies free, and is consequently exposed to other conditions than the inner surface, certain differences are noticed between the two ends of each cell. The cells may develop cuticular structures as above stated. In other cases motile processes (cilia) are developed on their exposed surface, which move in a definite direction in the medium surrounding them, and by means of this motion sweep away foreign bodies. It is not strange that the free surface of the epithelia, exposed as it is to stimulation from without, should develop special structures for the reception of sensations (sense cells).

On the other hand, the inner or basal surfaces of the cells usually retain a more indifferent character, and serve for the attachment of the cells and the conveyance of their nourishment. For this reason the nuclei of such cells are usually situated near the basal surface.

From the above it is seen that the two ends of the epithelial cell undergo varying processes of differentiation, the outer being adapted more to the animal, the inner more to the vegetative functions. This differentiation has recently been known as the *polarity* of the cell. This polarity appears to be retained even when the cell loses its epithelial character and assumes other functions (Rabl, 90).

With few exceptions, blood- and lymph-vessels do not penetrate into the epithelia, but the latter are richly supplied with nerves. The finer morphology of the epithelia will be described in the chapters on the different organs in Part II.

Epithelia are classified according to the shape and relation of the epithelial cells.

We give the following classification :

1. Simple epithelia (with or without cilia).
  - (a) Squamous epithelium.
  - (b) Cubic epithelium.
  - (c) Columnar epithelium.
  - (d) Pseudostratified columnar epithelium.
2. Stratified epithelia (with or without cilia).
  - (a) Stratified squamous epithelium, with superficial flattened cells (without cilia).
  - (b) Transitional epithelium.
  - (c) Stratified columnar epithelium, with superficial columnar cells (with or without cilia).
3. Glandular epithelium.
4. Neuro-epithelium.

### 1. SIMPLE EPITHELIUM.

In simple epithelia the cells lie in a single continuous layer.

Simple epithelia are very widely distributed. They line almost the entire alimentary tract, the smaller respiratory passages and air

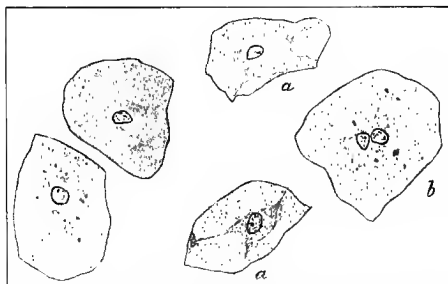


Fig. 36.—Isolated cells of squamous epithelium (surface cells of the stratified squamous epithelium lining the mouth) : *a, a*, Cells presenting under surface ; *b*, cell with two nuclei.

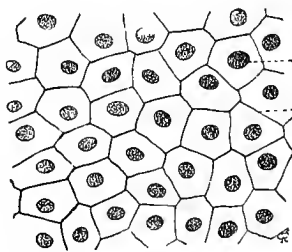


Fig. 37.—Surface view of squamous epithelium from skin of a frog ;  $\times 400$ . Technic No. 124.

sacs, the majority of the gland ducts, the oviducts and uterus, and the central canal of the spinal cord and ventricles of the brain.

(a) **Simple Squamous Epithelium.**—In simple squamous epithelium the cells are flattened. Their contiguous surfaces appear regular, forming, when seen from above, a mosaic. The nuclei lie, as a rule, in the middle of the cell, and if the latter be very much flattened, the position of the nucleus is made prominent by a bulging of the cell at this point. It occurs in the alveoli of the lung.

(b) **Simple Cubic Epithelium.**—Epithelial cells of this type differ from the above only in that they are somewhat higher. They appear as short polygonal prisms. Their outlines are, as a rule, not irregular, but form straight lines. Cubic epithelium occurs in the

smaller and smallest bronchioles of the lungs, in certain portions of the uriniferous tubules and their collecting ducts, in the smaller ducts of salivary and mucous glands, liver, pancreas, etc.

(c) **Simple Columnar Epithelium.**—In this type the cells take the form of prisms or pyramids of varying length. Cuticular structures are especially well developed. Columnar epithelium occurs in the entire intestinal tract from the cardiac end of the stomach to the anus, in certain portions of the kidney, etc.

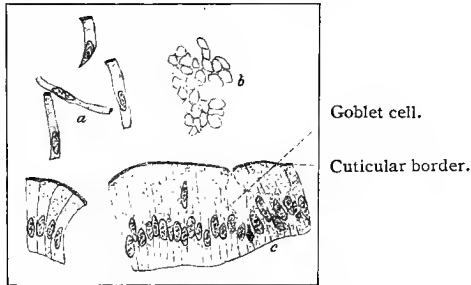


Fig. 38.—Simple columnar epithelium from the small intestine of man : *a*, Isolated cells ; *b*, surface view ; *c*, longitudinal section.

Simple ciliated columnar epithelium is found in the oviduct and uterus, central canal of the spinal cord, and smaller bronchi.

(d) **Pseudostratified Columnar Epithelium.**—This type is one in which all the cells rest on a basement membrane, but they are so placed that the nuclei come to lie in different planes. Thus, in a longitudinal section the nuclei are seen to be placed in several rows.

The development of this type from the simpler forms occurs when the cells are too crowded to retain their normal breadth. As a result, they become pyramidal, alternate cells resting their bases or apices on the basement membrane. As the nucleus is usually situated at the broader portion of the cell, the result is that there are two rows of nuclei simulating a stratified epithelium. Occasionally there are spindle-shaped cells wedged in between the pyramidal cells, and as the broad portion of these cells is midway between the basement membrane and external surface, a third row of nuclei is seen midway between the other two. Such epithelia usually possess cilia (portions of the respiratory passages).

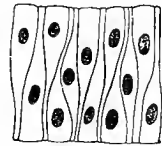


Fig. 39.—Diagram of pseudostratified columnar epithelium.

## 2. STRATIFIED EPITHELIUM.

Should the increase of the cells forming the last type of simple epithelium proceed to such an extent that all the cells no longer rest on the basement membrane, an epithelium is formed having dis-

tinct layers of cells—a stratified epithelium. It is clear that all the cells of a stratified epithelium can not be equally well nourished by the blood-supply from the vessels in the highly vascular connective tissue beneath. The middle and outer layers of cells accordingly suffer. The deeper layers are much better nourished, and as a consequence their cells increase much more rapidly than those above; they push outward, replacing the superficial cells as fast as they die or are thrown off. The proliferation of cells in a stratified epithelium occurs, therefore, chiefly in its basal layers.

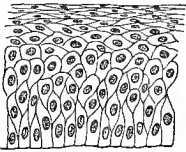


Fig. 40.—Schematic diagram of stratified pavement epithelium.

(a) **Stratified Squamous Epithelium.**—Stratified squamous epithelium with superficial flattened cells forms the epidermis with its continuations into the body, as, for instance, the walls of the oral cavity and the esophagus, the epithelium of the conjunctiva, the vagina, the external auditory canal, and the external sheath of the hair follicles.

The cells of the basal layer are here mostly cubic-cylindric. Then follow, according to the situation of the epithelium, one or more layers of polyhedral cells, which become gradually flattened toward the surface, the outermost layers consisting of thin plate-like cells.

In stratified squamous epithelia, where the outer cells become horny (as in the skin), the stratification is still more specialized. Here layers are inserted in which the horny or chitinous substance is gradually formed, although the cells do not become chitinous until the superficial layers are reached.

Especially characteristic of stratified squamous epithelium is the arrangement of the connective tissue on which this epithelium rests. There are cone-like projections, known as *papillæ*, arising from the connective tissue beneath the epithelium, projecting into the latter in such a way that on cross-section the junction of the two tissues appears as a wave-like line. These papillæ not only serve to fasten the epithelium more firmly to the connective tissue below, but influence very favorably the nourishment of the former by allowing a greater number of its basal cells to approximate the under-

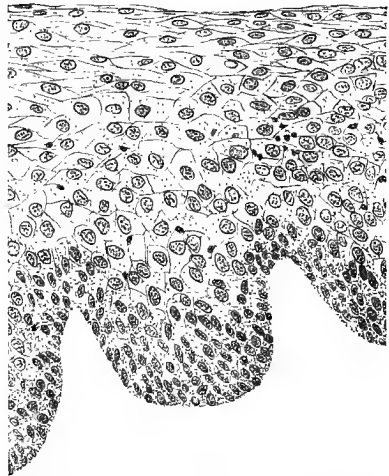


Fig. 41.—Cross-section of stratified squamous epithelium from the esophagus of man.

lying blood-capillaries. The pyramidal extensions of the epithelium between the papillæ are designated *interpapillary epithelial processes*. In regions where the stratified squamous epithelium consists of many layers, the prickle cells, intercellular bridges, and the intercellular spaces are especially well developed. These spaces facilitate the passage of the lymph-plasma to the more superficial layers of cells.

(b) **Transitional Epithelium.**—Transitional epithelium is a stratified epithelium occurring in the pelvis of the kidney, the ureters, bladder, and the posterior portion of the male urethra. It is composed of four to six layers of cells and rests on a connective tissue free from papillæ. In sections the cells of the deeper layers appear to be of irregularly columnar, cubic or triangular shape. The

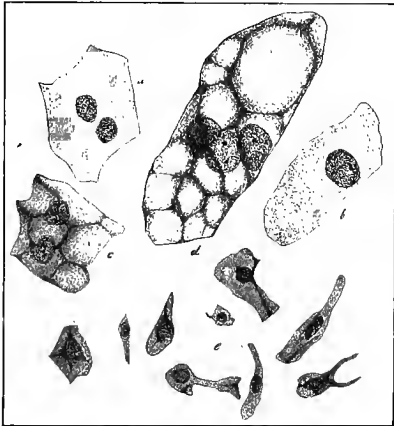


Fig. 42.—Isolated transitional epithelial cells from the bladder of man: *a*, *b*, *c*, *d*, Large surface cells, *c* and *d* presenting the pitted undersurface; *e*, variously shaped cells from the deeper layers.

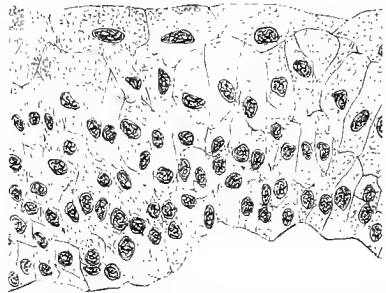

Fig. 43.—Cross-section of transitional epithelium from the bladder of a young child.

cells forming the superficial layer are large, somewhat flattened cells, with convex free surfaces, often possessing two, sometimes three, nuclei. They cover a number of the cells of the layer just beneath them, their under surfaces being pitted to receive the upper ends of the deeper cells. In teased preparations the cells of the deeper layers appear very irregular, often showing ridges or variously shaped processes. (See Fig. 42.)

(c) **Stratified Columnar Epithelium.**—In this type the superficial layer consists of columnar cells, the basal ends of which are usually somewhat pointed, or may branch. The deeper cells, which may be arranged in one or more layers, are of irregular, triangular, polyhedral, or spindle shape. It is found in the larger gland ducts, olfactory mucous membrane, palpebral conjunctiva, portions of the

male urethra and the vas deferens, and in certain regions of the larynx.

The ciliated variety of this epithelium differs from the foregoing in that the superficial columnar cells are provided with cilia. Stratified ciliated columnar epithelium is found in the respiratory portion

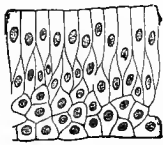


Fig. 44.—Schematic diagram of stratified columnar epithelium.

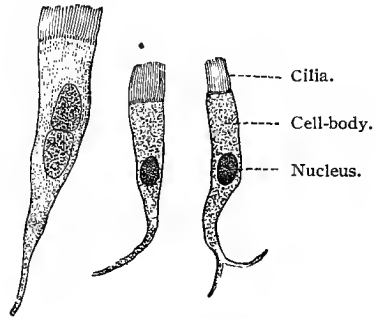


Fig. 45.—Ciliated cells from the bronchus of the dog, the left cell with two nuclei;  $\times 600$ . Technic No. 126.

of the nose, larynx, trachea, and larger bronchi, in the Eustachian tube, epididymis, and a portion of the vas deferens.

All epithelial cells are probably joined together by short processes forming intercellular bridges, the lymph supplying them with nourishment circulating in the intercellular spaces thus formed. Toward the surface, these intercellular spaces are roofed over, thus preventing the escape of the fluid. When seen from the surface, epithelia treated by certain methods (iron-hematoxylin) show the cells joined together by very minute, clearly defined and continuous

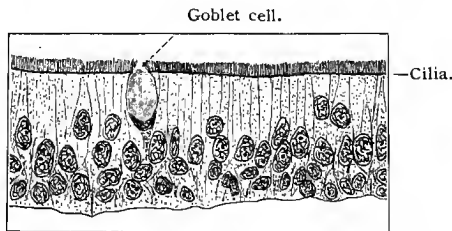


Fig. 46.—Cross-section of stratified ciliated columnar epithelium from the trachea of a rabbit.

cement-lines. Bonnet has called them *terminal ledges* or *bars* (Schlussleisten). The function of this structure would seem to consist in its power to prevent the escape of lymph from the surface, and the penetration of micro-organisms (M. Heidenhain, 92; Bonnet, 95).

### 3. GLANDULAR EPITHELIUM.

(a) **The Gland-cell.**—Certain cells lying scattered among other epithelial cells produce substances that are extruded and utilized in the body economy. The protoplasm of such a cell elaborates in its interior a substance that takes the form of vacuoles or granules, which gradually distend the cell; the substance thus produced is finally given off as the secretion. All these phases of the activity of a gland-cell are included under the term secretion.

Isolated glandular cells are frequently met with in epithelia, and are known in general as unicellular glands. They occur especially in the intestinal and respiratory epithelium, where, owing to their shape, they are termed *goblet cells*. All the intestinal epithelial cells and many of the cells of respiratory epithelium, have the power of changing into goblet cells. These are distinguished from the neighboring cells by the fact that their free ends are clearer and more

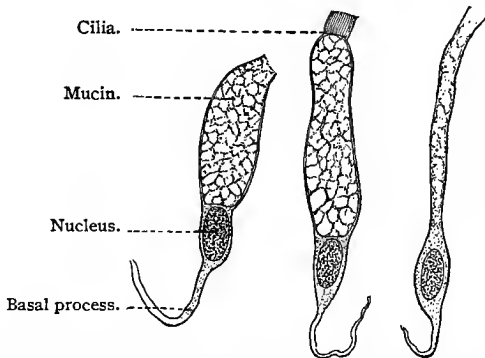


Fig. 47.—Goblet cells from the bronchus of a dog. The middle cell still possesses its cilia; that to the right has already emptied its mucous contents (collapsed goblet cell);  $\times 600$ . Technic No. 128.

vesicular, while their basal portions, containing the nuclei, are narrow and pointed. The clear substance elaborated by the protoplasm of the cell, but not yet extruded, is mucin. On closer examination it is seen that this substance fills the interspaces of a very fine protoplasmic network continuous with the protoplasm surrounding the nucleus.

Thus we have, during the phases of secretion, two distinct substances in the cell-body: the one the original protoplasm of the cell—*protoplasm* (Kupffer); the other its product, in this case mucin—*paraplasm* (Kupffer). When the secretion is extruded the goblet cell collapses and then appears as a thin cord between the neighboring cells. There is as yet some question as to whether a collapsed goblet cell dies after the expulsion of its contents, or whether it may again become stored with mucin. Should it be destroyed, its place is soon occupied by the closing in of contiguous cells.

Multicellular glands originate by the metamorphosis of a number of adjacent cells into glandular cells. This is usually accompanied by a more or less marked dipping down of the epithelial layer into the underlying connective tissue. The simplest form of such an invagination is a cylindrical tube lined entirely by glandular cells. A further differentiation may take place in that all the invaginated cells do not assume a secretory function, those at the upper portion of the tube forming the lining membrane of an *excretory duct*. The originally uniform tube is thus differentiated into an excretory and a secretory portion.

Multicellular glands may lie entirely within the epithelium, and are then known as intra-epithelial glands, in contrast to the extra-epithelial or ordinary type, the greater part of which lies imbedded in the under-

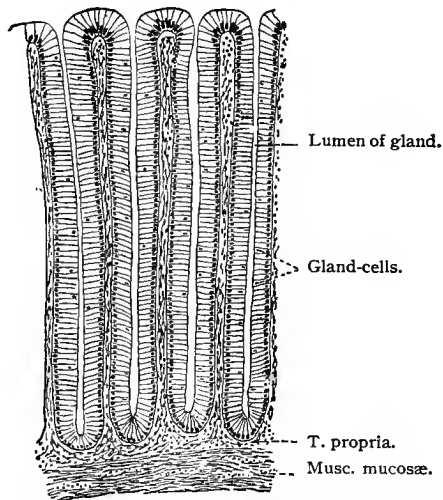


Fig. 48.—Simple tubular glands. Lieberkühn's glands from the large intestine of man. Sublimate fixation;  $\times 90$ .

lying connective tissue. Glands of the former type have been studied in amphibian larvæ, and, according to Sigmund Mayer, occur also in the epididymis, conjunctiva, etc., of mammals.

(*b*) **General Consideration of the Structure and Classification of Glands.**—Variations in glandular types affect principally the secretory portions of glands, while the excretory ducts are more or less uniform. Glands are classified, according to their shape, into tubular and saccular glands; each of these types is further divided into simple and compound tubular, and simple and compound saccular (racemose) glands.

*Tubular Glands.*—The simplest form is a tubule of uniform diameter, as in the simple tubular glands of the cardiac region of

the stomach and in the crypts of Lieberkühn in the intestine. Without losing the shape of a tubule, the glands of this type may be more or less coiled (pyloric glands, sweat glands, and the ceru-



Fig. 49.—Excretory ducts and lumina of the secretory portion of a compound tubular gland. Lingual gland of the rabbit. Chrome-silver preparation;  $\times 215$ .

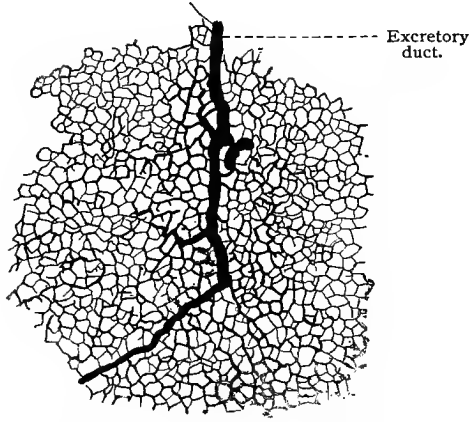


Fig. 50.—Lumina of the secreting portion of a reticulated tubular gland; from the human liver. Chrome-silver preparation;  $\times 120$ .

minous glands of the external ear). Again, the secretory portions of the glands may divide, forming *branched tubular glands* (pyloric glands, uterine glands).

A *compound tubular gland* is one in which two or more secretory tubules empty into each branch of a system of excretory

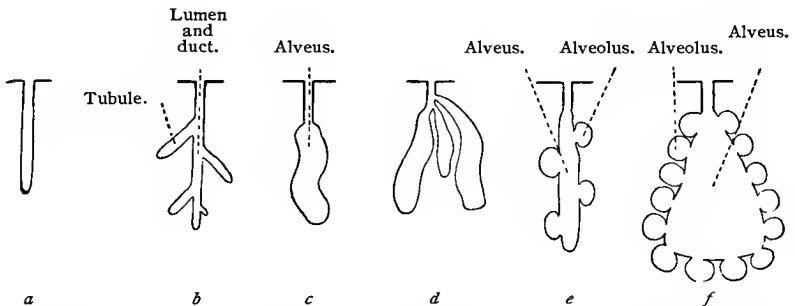


Fig. 51.—Schematic diagram of glandular classification: *a*, Simple tubular; *b*, branched tubular; *c*, simple alveolar; *d*, compound alveolar (without alveoli); *e* and *f*, alveolar (with alveoli).

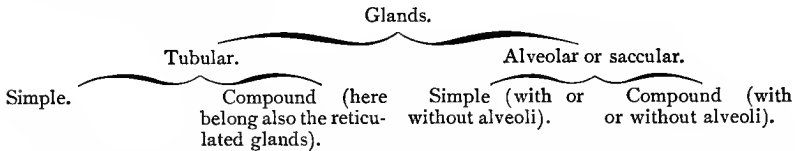
ducts, as the result of repeated division of the primary duct (kidney). The secretory tubules may anastomose with each other, forming a *reticulated tubular gland* (liver).

In *alveolar* or *saccular glands* the secretory portion usually takes the form of a winding tube, the caliber of which is somewhat enlarged at its extremity (alveus).

Glands of this class are divided into simple and compound types, as in the case of the tubular glands. To the former belong Ebner's glands of the tongue and Brunner's glands of the duodenum; to the latter, the salivary and the larger mucous glands.

Certain glands have the shape of a flask, the neck representing the excretory duct of the gland (integumentary glands of salamandra). To these the term *saccular* is often restricted. Still more complicated forms of alveolar or saccular glands are produced by the bulging here and there of the walls of the tube or alveus. The protrusions thus formed are known as *alveoli*.

According to the above description, multicellular glands may be classified as follows :



The secretory and excretory epithelia rest upon a thin membrane (*membrana propria*), which has, according to some authors, a connective-tissue origin, while, according to others, it is the product of the glandular cells themselves. In some cases it appears structureless, in others a cellular structure can be distinguished; in the latter case the cells are flattened, with very much flattened nuclei, and show irregular outlines.

Macroscopically, compound glands present a more or less lobular structure, the separate lobules being held together by connective tissue. In the immediate neighborhood of the gland and its larger lobes, the connective tissue is thickened to form the so-called *tunica albuginea* or capsule. In this fibrous-tissue sheath are found numerous blood-vessels which penetrate between the lobes and lobules of the gland and form a dense capillary network about the tubules and alveoli immediately beneath the *membrana propria*. Nerve-fibers are also plentiful.

(c) **Remarks on the Process of Secretion.**—The gland-cell varies in its microscopic appearance according to its functional condition. In its phases of activity it shows vacuoles filled with secretion (as in the liver-cell), or a granulation (pancreas), or even a distinct striation of its protoplasm (kidney).

The secretory process varies. In one case the cell remains intact throughout the process (salivary glands); in another a portion of its own substance is used up in the production of the secretion, only the basal portion containing the nucleus being preserved. When this occurs, the upper part of the cell is reconstructed from the remaining basal portion, and the cell is ready to renew the

process (mammary glands). In a third type the whole cell is destroyed, and is replaced by an entirely new cell (sebaceous glands).

#### 4. NEURO-EPITHELIUM.

In certain of the organs of special sense (inner ear and taste-buds) the epithelial cells about which the nerves terminate undergo a high degree of specialization. This differentiation is more apparent in the outer portions of these cells, resulting in the formation of one or several stiff, hair-like processes, which appear especially receptive to stimuli. Such cells are known as *neuro-epithelial cells*. In the epithelia in which they occur they are surrounded by supporting or *sustentacular cells*.

#### 5. MESOTHELIUM AND ENDOTHELIUM.

The pleural, pericardial, and peritoneal cavities are lined by a single layer of flattened epithelioid cells which develop from the mesothelium lining the primitive body cavity (celom). For this reason, as has been suggested by Minot (90), the term mesothelium may with propriety be applied to this layer in its developed condition. A mesothelial cell is a very much flattened cell, resembling those of squamous epithelium, with faintly granular protoplasm, possessing a flattened, oval, or nearly round nucleus. These cells are of polyhedral shape, and are united into a single layer by a small amount of intercellular cement substance. The borders of these cells may be quite regular or slightly wavy (Fig. 52); more often they are serrated (Figs. 53, 54). The quantity of intercellular cement substance is so small in amount, and the cell boundary so indistinct, that it is necessary to resort to special staining methods to bring out clearly their outline (silver nitrate or *intra vitam* methylene-blue method).

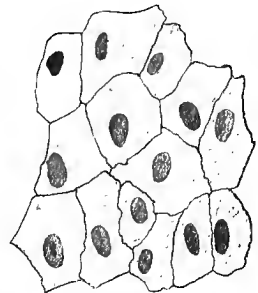

Fig. 52.—Mesothelium from pericardium of rabbit. Silver nitrate preparation, stained in hematoxylin.

The cavities lined by mesothelium communicate directly with lymph-vessels or -spaces beneath the lining membrane by means of small openings known as *stomata*. The stomata are surrounded by a layer of cubical cells with granular protoplasm, spoken of as *germinal cells*. They are numerous in the diaphragm, and may be readily demonstrated in the frog in the membrane separating the abdominal lymph-space from the peritoneal cavity (in the region of the kidneys). Small accumulations of the intercellular cement substance, found at the place of union of several mesothelial cells, are described as pseudostomata or stigmata.

*Endothelial cells* are differentiated mesenchymal cells. They line the blood- and lymph-vessels and lymph-spaces (arachnoidal and

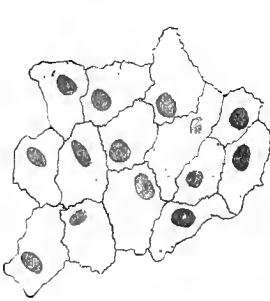

Fig. 53.—Mesothelium from mesentery of rabbit.

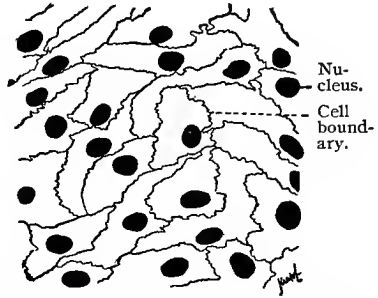


Fig. 54.—Mesothelium from peritoneum of frog;  $\times 400$ . Technic No. 123.

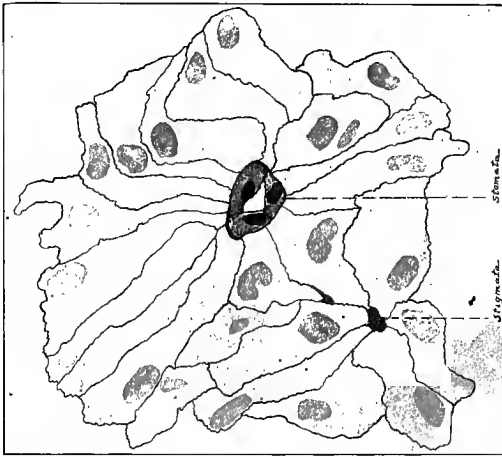


Fig. 55.—Mesothelium covering posterior abdominal wall of frog. Stained with silver nitrate and hematoxylin.

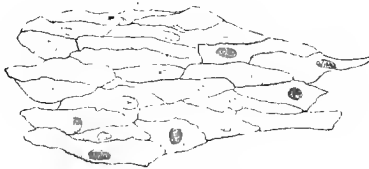


Fig. 56.—Endothelial cells from small artery of the mesentery of a rabbit. Stained with silver nitrate and hematoxylin.

synovial spaces, anterior chamber of the eye, bursæ, and tendon sheaths). Endothelial cells are in structure like those of the meso-

thelium. In blood- and lymph-vessels they are of irregular, oblong shape, with serrated borders. The boundaries of these cells are clearly brought out by silver nitrate.

### TECHNIC.

**127. Epithelium** may be examined in a fresh condition. The simplest method consists in placing some saliva under a cover-glass and examining it with a moderate power. In it will be found a number of isolated squamous epithelial cells, suspended in the saliva singly and in groups. The cells that are cornified still show the nucleus and a small granular area of protoplasm.

**128.** In order to examine **isolated epithelial cells** of organs, it is necessary to treat the epithelial shreds or whole epithelial layers with the so-called isolating or maceration fluids. These are: (1) Iodized serum; (2) very dilute osmic acid (0.1% to 0.5%); (3) very weak chromic acid solution (about 1:5000 of water); (4) 0.5% or 1% solution of ammonium or potassium bichromate; and, above all, the one-third alcohol recommended by Ranvier (28 vols. absolute alcohol, 72 vols. distilled water). The mixture recommended by Soulier (91), consisting of sulphocyanid of potassium or ammonium, and the mixture of Ripart and Petit (*vid.* T. 13) serve the same purpose. All these solutions are used by allowing a quantity of the isolation fluid to act upon a small fresh piece of epithelium for from twelve to twenty-four hours, according to the temperature of the medium and quality of the tissue. As soon as the isolation fluid has done its work, it is easy to complete the isolation of the cells by shaking the specimen or teasing it with needles. Separation of the elements may be accomplished either in the isolation solution itself or in a so-called indifferent fluid (*vid.* T. 13), or in gum-glycerin (*vid.* T. 98). The macerated preparation may be stained in a hematoxylin or carmin solution before teasing and mounting in gum-glycerin.

**129.** The movement of **the cilia** can be observed in mammalian tissues by scraping the epithelium from the trachea with a scalpel and examining it in an indifferent fluid. As the ciliated epithelium of mammals is very delicate and sensitive, specimens with a longer duration of ciliary movement are more desirable. They can be obtained by using the mucous membrane from the palate of a frog (examine in normal salt solution, *vid.* T. 13). Particularly large epithelial cells, as well as very long cilia, are found on the gill-plates of mussels or oysters.

**130.** In order to study **the relations of mesothelial and endothelial cells**, the silver method is the most satisfactory. The outlines of the mesothelial cells may be clearly brought out by placing pieces of the pericardium, central tendon of the diaphragm, or the mesentery in a 0.75% to 1% solution of silver nitrate. Before placing in this solution, they should be rinsed in distilled water in order to remove any adherent foreign bodies, such as blood-corpuses, etc. In this solution they remain until opaque, which occurs in from ten to fifteen minutes. They are then again rinsed with distilled water, in which they are exposed to sunlight until they begin to assume a brownish-red color. Once again they are washed with distilled water, and either placed in glycerin, in which they may be mounted, or dehydrated and mounted in Canada balsam, according to the

usual methods. The margins of the cells subjected to this treatment will appear black.

**Endothelial cells** may be demonstrated after the following method: A small mammal (rat, Guinea-pig, rabbit, or cat) is narcotized. Before the heart's action is completely arrested, the thorax is opened and the heart incised. As soon as the blood stops flowing, a cannula is inserted and tied in the thoracic aorta a short distance above the diaphragm, and 50 to 80 c.c. of a 1% aqueous solution of silver nitrate injected through the cannula. About fifteen minutes after the injection of the silver nitrate solution, there is injected through the same cannula 100 to 150 c.c. of a 4% solution of formalin (formalin 10 parts, distilled water 90 parts). The abdominal cavity is then opened, loops of the intestine with the attached mesentery removed and placed in a 4% solution of formalin, in which the tissue is exposed to the sunlight. As soon as the reduction of the silver nitrate has taken place, which is easily recognized by the reddish-brown color assumed by the tissues, the mesentery is divided into small pieces, dehydrated first in 95%, then in absolute alcohol, cleared in oil of bergamot, and mounted in balsam. As a rule, the mesothelial cells covering the two surfaces of the mesentery, and the endothelial cells lining the arteries, veins, and capillaries are clearly outlined by the reduced silver nitrate.

If desired, the tissue may be further stained in hematoxylin (we have used Böhmer's hematoxylin solution) or in a carmin solution after dehydration in 95% alcohol, after which they are dehydrated, cleared, and mounted in balsam. In preparations made after this method the endothelial cells are outlined by fine lines of dark brown or black color.

Silver nitrate may also be dissolved in a 2% to 3% solution of nitric acid, in osmic acid, and various other fluids. Stratified epithelia can also be impregnated with silver nitrate, but only after prolonged immersion. They are exposed to sunlight after sectioning on the freezing microtome, or after hardening and imbedding, followed by sectioning. After the reduction of the silver the sections are dehydrated and mounted in balsam.

131. Kolosow has devised the following excellent method for demonstrating **intercellular bridges**: Fine membranes, or even minute fragments of previously fixed tissues, are placed for about a quarter of an hour in a 0.5% to 1% osmic acid (or in a mixture composed of 50 c.c. absolute alcohol, 50 c.c. distilled water, 2 c.c. concentrated nitric acid, and 1 to 2 gm. osmic acid) and then into a 10% aqueous solution of tannin for five minutes, or into a developer consisting of the following: water, 450 c.c.; 85% alcohol, 100 c.c.; glycerin, 50 c.c.; purified tannin, 30 gm., and pyrogalllic acid, 30 gm. In the latter case they are subsequently rinsed in a weak solution of osmic acid, washed with distilled water, and then carried over into alcohol.

132. There are, of course, special methods of fixing and subsequently examining epithelial structures; these, and the methods of examining gland tissue, will be discussed in the chapters devoted to the various organs.

## B. THE CONNECTIVE TISSUES.

In the connective tissues, the intercellular substance gives character to the tissue, the cellular elements forming a less conspicuous portion. All the members of this group are developed from the mesenchyme, an embryonic tissue differentiated early in embryonic life from the mesoderm, and consisting of variously branched cells, possessing a small amount of protoplasm and relatively large nuclei. The branches of neighboring cells are united by threads of protoplasm; between the cells is found a homogeneous ground-substance or matrix.

In their fully developed condition some of the members of the connective-tissue group are only slightly altered from embryonic connective tissue. This is the case in mucous connective tissue, which

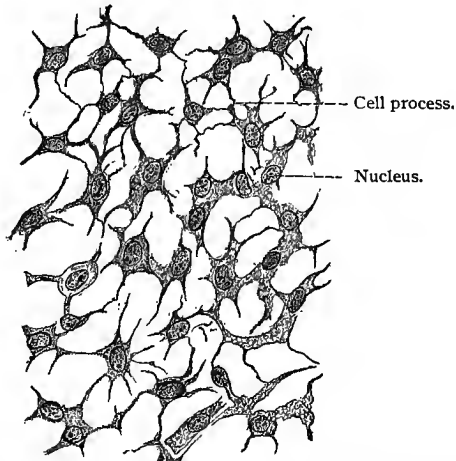


Fig. 57.—Mesenchymatous tissue from the subcutis of a duck embryo;  $\times 650$ .  
Technic No. 17.

resembles closely mesenchymal tissue. In other members there are developed in the ground-substance, in less or greater number, fibers, known as connective-tissue fibers, thus forming reticular connective tissue and the looser and denser forms of fibrous connective tissue. A more marked condensation of the intercellular substance is observed in cartilage; and in bone and dentin a still greater degree of density is obtained by the deposition of calcareous salts in the intercellular matrix.

The rôle played by the connective tissues in the economy of the body is largely passive, depending on their physical properties. Bone and cartilage serve as supporting tissues; the looser fibrous tissues for binding and holding the organs and parts of organs firmly in place. The denser fibrous connective tissues come into play

where strength and pliability are desired, as in ligaments, or else are used in the transmission of muscular force, as in tendons.

Another important characteristic of connective tissue is that its various members are capable of undergoing transformation into wholly different types; bone, for instance, being developed from fibrous connective tissue and from cartilage. Certain structures are represented by different members of the connective-tissue group in the different classes of vertebrates. In certain fishes the skeleton is cartilaginous, and in certain birds the leg tendons are formed of osseous tissue, etc.

In the different types of connective tissue the cellular elements are morphologically very similar, and do not differ materially from the mesenchymal cells from which they are developed.

The connective tissues receive their nutrition from the lymph. In the denser connective tissues this permeates the tissues through clefts or spaces in the ground-substance, in which the connective-tissue cells are found and which are united by means of fine canals into a canalicular system. In the looser fibrous tissues and in mucous connective tissue the system of lymph-channels is not present; here the lymph seems to pass through the ground-substance.

Certain connective-tissue cells have the function of producing fat. In various parts of the body, masses of fat tissue are formed as a protection to various organs and as a reserve material upon which the body can call when necessary. This type can hardly be considered a separate class of connective tissues, as it can be demonstrated that it is merely modified connective tissue, and can occur wherever the latter is found.

Finally, certain elements of the middle germinal layer are capable of producing colored substances known as *pigments*. To this class belong the pigment cells and the red blood-corpuscles.

From the above account it will be seen that we have to distinguish between the following kinds of connective tissue: (1) mucous connective tissue, (2) reticular connective tissue, (3) fibrous connective tissue, (4) adipose tissue, (5) cartilage, (6) bone.

The fibrous connective tissues are composed of a ground-substance or matrix in which are imbedded the cellular elements and two kinds of connective-tissue fibers, namely, white and elastic fibers. As the character of the fibrous connective tissue depends largely on the arrangement of the fibers and on the relative proportion of the white and elastic fibers, these will be considered prior to a description of the several types of fibrous connective tissue.

*White Fibers.*—White fibrous connective tissue consists of exceedingly fine homogeneous fibrillæ, cemented by a small amount of an interfibrillar cement substance into bundles varying in size. In the bundles these fibrillæ have a parallel course, although the bundles are often slightly wavy. The fibrillæ of white fibrous connective tissue vary in size from 0.25 to 1  $\mu$ , and neither branch nor anasto-

mose. They become transparent and swollen when treated with acetic acid, are not at all or only very slowly digested by pancreatin, and yield gelatin on boiling.

*Elastic Fibers.*—These are homogeneous, highly refractive, distinctly contoured fibers, varying in size from  $1\ \mu$  to  $6\ \mu$ , and in some animals are even larger. They branch and anastomose, and are not cemented into bundles. When extended, they appear straight; when relaxed, they show broad, bold curves, or are arranged in the form of a spiral. The broken ends of the fibers are bent in the form of a hook. Mall has shown that elastic fibers are composed of two distinct substances—an outer delicate sheath which does not stain in magenta, and an interior substance which is intensely colored in this stain. The interior substance is highly refractive. Elastic fibers are not affected by acetic acid, but are readily digested in pancreatin and less readily in pepsin. They yield elastin on boiling.

Our knowledge concerning the development of the connective-

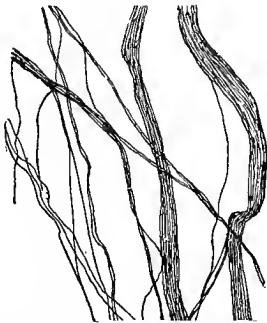


Fig. 58.—White fibrils and small bundles of white fibrils from teased preparation of a fresh tendon from the tail of a rat.




Fig. 59.—Elastic fibers from the ligamentum nuchæ of the ox, teased fresh;  $\times 500$ . At *a* the fiber is curved in a characteristic manner.

tissue fibers is not as yet conclusive; two distinct views are held at the present time. One group of observers maintains that the fibers are developed in the cells of the embryonic connective tissue. These cells are thought to change into fibrous connective tissue by the formation in their interior of thread-like structures—the connective-tissue fibrils—a process which is always accompanied by active nuclear division (Flemming, 91, II; Lwoff, Reinke). The cells thus become polynuclear and considerably lengthened, and the fibrils gradually increase in number at the expense of the cell-bodies, so that on examining the tissue the fibrils appear to predominate, and give the impression of forming the ground-substance. According to the other view, the fibers are at all times intercellular, developing in the ground-substance. Mall believes their development to be due to a kind of coagulation, certain cells being held

responsible for the formation of special fluids or ferments which bring about this coagulation. The formation of the ground-substance in which the fibers develop is also attributed to the cellular elements. The intercellular mode of formation of connective-tissue fibers would appear to be the more usual, although some of them may have an intracellular origin. We shall now discuss the several types of fibrous connective tissue.

### 1. MUCOUS CONNECTIVE TISSUE.

Mucous connective tissue is a purely embryonal type, and scarcely represented in the adult human body. It consists of branched, anastomosing cells imbedded in a gelatinous ground-substance, containing here and there white fibers. The latter as well as the mucous matrix are, directly or indirectly, the products of the cells. During the development of the embryo this tissue is found in large quantities in the umbilical cord, and is here known as *Wharton's jelly*. It also occurs in the embryo in the cutis, in the region of the semicircular canals of the cochlea, in the vitreous humor, etc.

### 2. RETICULAR CONNECTIVE TISSUE.

Reticular connective tissue is a fibrous connective tissue in which the intercellular substance has disappeared. The tissue is often described as being composed of anastomosing branched cells, arranged in the form of a network with open spaces. The observations of Ranvier and Bizzozero, and more recently those of Mall, have shown that the framework of reticular tissue is composed of very fine fibrils or bundles of fibrils. These interlace in all planes to form a most intricate network, surrounding spaces of varying size and shape. According to Mall, the fibrils of reticular tissue differ chemically from both the white and elastic fibers, although their composition has not been fully determined. Like white fibrous tissue, reticular tissue is not digested by pancreatin, but, unlike white fibrous tissue, it does not appear to yield gelatin upon boiling in water.

The cells of reticular connective tissue, which are flattened and often variously branched, lie on the reticular network, being often wrapped about the bundles of fibrils. Unless they are removed, the reticulum has the appearance of a network composed of branched and anastomosing cells.

Reticular connective tissue is found in adenoid tissue and lymph-glands, in the spleen, and in the mucous membrane of the intestinal canal, and in these locations the meshes of the reticulum are filled with lymph-cells and other cellular elements, which, unless removed, obscure the reticulum. Connective-tissue fibrils giving the same reaction as those found in the adenoid reticulum are found associated with white and elastic fibers in the liver, kidneys, and

lung. In bone-marrow a reticulum is found, in the meshes of which are the cellular elements of this tissue.

### 3. FIBROUS CONNECTIVE TISSUE.

Fibrous connective tissue can be divided morphologically into two groups: In one the bundles of fibers cross and interlace in all directions, forming a network with meshes of varying size—formless or areolar connective tissue. In the other the bundles of fibers are parallel to each other, as in tendon and many of the aponeuroses and ligaments, or less regularly arranged, yet very densely

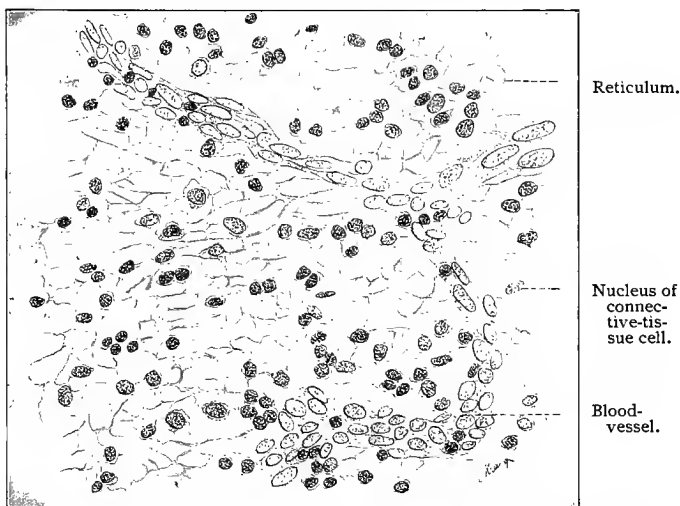


Fig. 60.—Reticular connective tissue from lymph-gland of man ;  $\times 280$ . Brush preparation.

woven, as in fascias, the dura mater, and the firm, fibrous capsules of some of the organs.

(a) In **areolar connective tissue** the bundles of white fibers, which vary greatly in size and which often divide and anastomose with portions of other branching bundles, intercross and interlace in all directions. If the bundles of fibers are numerous, the interlacement is more compact, thus forming a dense areolar connective tissue; if less numerous, the network is more open, as in loose areolar connective tissue. Elastic fibers are always found in areolar connective tissue, though in varying quantity. They anastomose to form a network with large, irregular meshes, and run on or between the bundles of white fibers. The meshes between the bundles of fibers, and the minute spaces between the fibrils in these bundles, are occupied by a semifluid, homogeneous substance known as the *ground-substance*, or *matrix*. The fibrous elements of areolar connective tissue are,

therefore, imbedded in this ground-substance, in which they develop. In dense areolar connective tissue the fibrous elements appear to have nearly displaced the ground-substance. In the ground-substance are found irregular, branched spaces,—*cell-spaces*,—in which lie the cellular elements of this connective tissue. These spaces

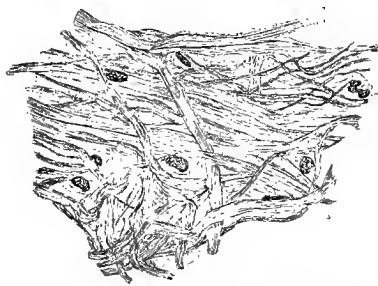

Fig. 61.—Areolar connective tissue from the subcutaneous tissue of a rat. Elastic fibers not shown.

anastomose by means of their branches, thus forming part of a system of spaces and small channels, known as the *lymph canalicular system*. These spaces and channels permeate the ground-substance in all directions, and serve to convey lymph to the tissue elements. The cell-spaces and their anastomosing branches can be demonstrated by immersing areolar connective tissue (preferably from a young animal), spread out in a thin layer, in a solution of silver nitrate (1%) until the tissue becomes opaque.

If then the tissue is exposed to sunlight, the silver is reduced in the ground-substance, giving it a brown color, while the cell-spaces remain unstained. The ground-substance of areolar connective tissue contains mucin.

The **cellular elements** of areolar connective tissue, which, as above stated, are imbedded in the cell-spaces, are either *fixed con-*

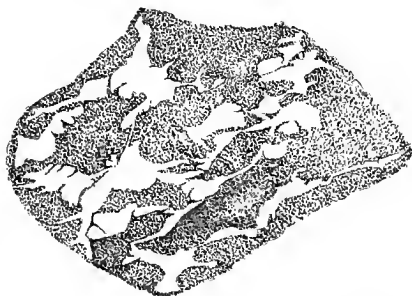

Fig. 62.—Cell-spaces in the ground-substance of areolar connective tissue (subcutaneous) of a young rat. Stained in silver nitrate.

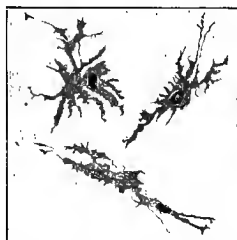


Fig. 63.—Three connective-tissue cells from the pia mater of a dog. Stained in methylene-blue (*intra vitam*).

*nective-tissue* cells or *wandering* or *migratory* cells. The former are again divided, according to their shape and structure, into true connective-tissue cells or corpuscles, granular cells, plasma cells, and pigment cells.

The *connective-tissue cells* or *corpuscles* are flattened, variously shaped cells of irregular form, usually having many branches. The

protoplasm is free from granules ; the nucleus, situated in the thicker portion of the cell-body and of oval shape, shows a nuclear network and one or several nucleoli. The cells assume the shape of

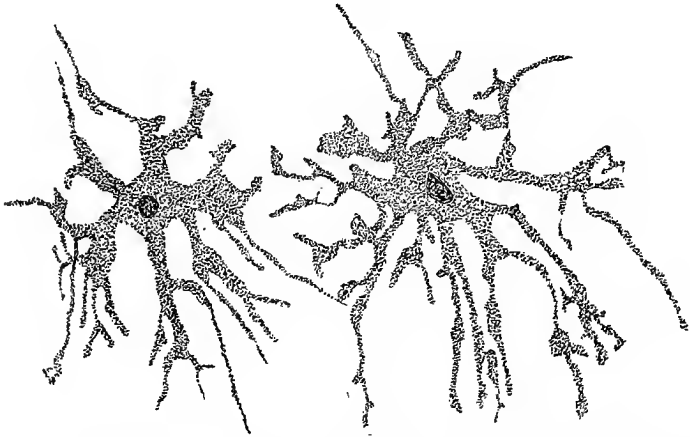


Fig. 64. —Two pigment cells found on the capsule of a sympathetic ganglion of a frog.

the space that they occupy and nearly fill. The branches of neighboring cells often anastomose through the fine channels uniting the cell-spaces.

*Granular cells* are thus named because in their protoplasm are found rather coarse granules of an albuminous nature which stain

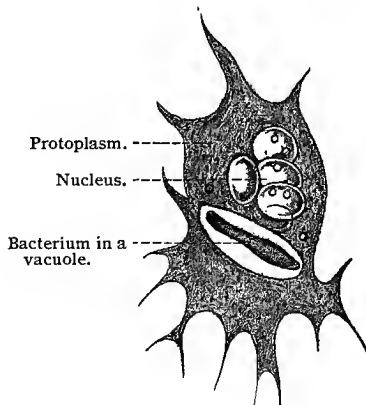


Fig. 65.—Leucocyte of a frog with pseudopodia. The cell has included a bacterium which is in process of digestion. (After Metschnikoff, from O. Hertwig, 93, II).

readily in many anilin stains, notably eosin. They are of irregular form, and are generally found in the neighborhood of blood-vessels. The nucleus is relatively large and of round or oval form.

*Plasma cells*, first described by Waldeyer, show large vacuoles in their protoplasm.

*Pigment cells* are branched connective-tissue cells, in the protoplasm of which are found brown or nearly black granules. In man they occur in the choroid and iris and in the dermis. In the lower animals they have, however, a much wider distribution, and in the frog and other amphibia they are very large and irregular. These cells have the power of withdrawing their processes and, to a limited degree, of changing their location (dermis).

The *wandering* or *migratory cells* are described in this connection not because they form one of the structural elements of areolar connective tissue, but because they are always associated with it. They are lymph- or white blood-cells, which have left the lymph- or blood-vessels and have migrated into the lymph canalicular system. They possess ameboid movement, and wander from place to place,

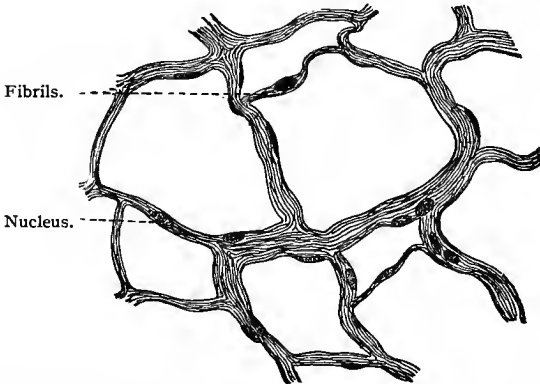


Fig. 66.—Fibrous connective tissue (areolar) from the great omentum of the rabbit ;  
 × 400. Technic No. 17.

and are the phagocytes of Metschnikoff. They seem to be intrusted with the removal of substances either superfluous or detrimental to the body (as bacteria). These are either digested or rendered harmless. The wandering cells even transport substances thus taken up to some other region of the body, where they are deposited.

In the peritoneum and other serous membranes the network formed by the fibrous tissue lies in one plane, and does not branch and intercross in all directions, as where areolar tissue is found in larger quantity. (Fig. 66.)

(b) **Tendons, aponeuroses, and ligaments** represent the densest variety of fibrous connective tissue, and are composed almost wholly of white fibrous tissue. This is found in the form of relatively large bundles of white fibrils, having a parallel or nearly parallel course. In tendons these bundles are known as *primary tendon bundles* or *tendon fasciculi*. The fibrils of white fibrous con-

nective tissue forming the fasciculi are cemented together by an interfibrillar cement substance. Here and there the fasciculi branch at very acute angles and anastomose with other fasciculi. The fasciculi are grouped into larger or smaller bundles, the *secondary tendon bundles*, which are surrounded by a thin layer of areolar connective tissue, and in part covered by endothelial cells. Between the tendon fasciculi there is found a ground-substance, *interfascicular ground-substance*, identical with the ground-substance in areolar connective tissue. In this there are cell-spaces occupied by the tendon cells, morphologically similar to the branched cells of areolar connective tissue. The tendon cells are arranged in rows between the tendon fasciculi. They have an irregular, oblong body, containing a nearly round or oval nucleus. Two, three, or even more wing-

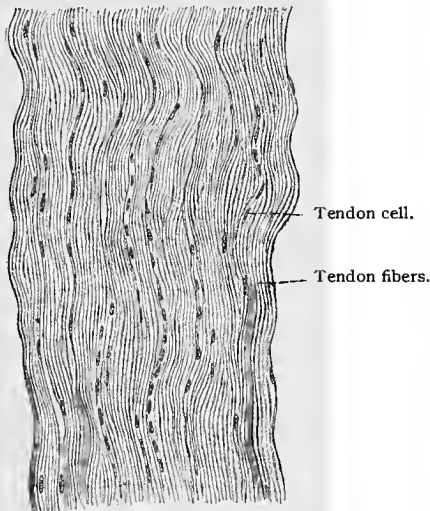


Fig. 67.—Longitudinal section of tendon;  
 $\times 270$ .

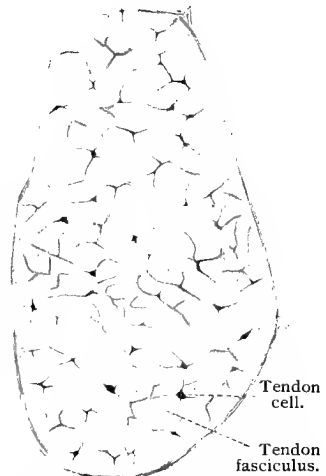


Fig. 68.—Cross-section of secondary tendon bundle from tail of a rat.

like processes (lamellæ) come from the cell-body and pass between the tendon fasciculi. In cross-section the tendon cells have a stellate shape.

The secondary tendon bundles are grouped to form the tendon, and the whole is surrounded and held together by a layer of areolar connective tissue, called the *peritendineum*. From this, septa pass in between the secondary tendon bundles, forming the internal peritendineum. The blood- and lymph-vessels and the nerve-fibers reach the interior of the tendon through the external and internal peritendineum.

The structure of an aponeurosis and a ligament is like that of a tendon.

The structure of a fascia, the dura mater, and the more fully

developed gland capsules, differs from that of the formed connective tissues above described, in that the fasciculi are not so regularly arranged, but branch and anastomose and intercross in several planes.

(c) **Elastic Fibrous Tissue.**—In certain connective tissues the elastic fibers predominate greatly over the fibers of white fibrous connective tissue. These are spoken of as elastic fibrous tissues and their structural peculiarities warrant the making of a special sub-group.

The ligamentum nuchæ of the ox consists almost exclusively of elastic fibers, many of which attain a size of about  $10\ \mu$ . The elastic fibers branch and anastomose, retaining, however, a generally parallel course. They are separated by a small amount of areolar connective tissue, in which a connective-tissue cell is here and there found, and are grouped into bundles surrounded by thin layers of areolar connective tissue; the whole ligament receives an



Fig. 69.—Tendon cells from the tail of a rat. Stained in methylene-blue (*intra vitam*).




Fig. 70.—Cross-section of ligamentum nuchæ of ox.

investment of this tissue. In cross-sections of the ligamentum nuchæ, the larger elastic fibers have an angular outline; the smaller ones are more regularly round or oval. (Fig. 70.) In man the ligamenta subflava, between the laminæ of adjacent vertebræ, are elastic ligaments.

In certain structures (arteries and veins), the elastic tissue is arranged in the form of membranes. It is generally stated that such membranes are composed of flat, ribbon-like fibers or bands of elastic tissue arranged in the form of a network, with larger or smaller openings; thus the term *fenestrated membranes*. Mall has reached the conclusion that such membranes are composed of three layers—an upper and a lower thin transparent layer in which no openings are found and which are identical with the sheaths of elastic fibers described by this observer, and a central layer, containing openings, and staining deeply in magenta. This substance is identical with the central substance of elastic fibers.

#### 4. ADIPOSE TISSUE.

In certain well-defined regions of the body occur typical groups of fixed connective-tissue cells which always change into fat-cells (fat organs, Toldt). Connective-tissue cells in various other portions of the body may also change into fat-cells, but in this case the fat, as such, sometimes disappears, allowing the cells to resume their original connective-tissue type, only again to appear and a second time change the character of the tissue. The formation of fat is very gradual. Very fine fat globules are deposited in the cell; these coalesce to form larger ones, until finally the cell is almost entirely filled with a large globule (*vid.* also H. Rabl, 96).

As the fat globule grows larger and larger, the protoplasm of the cell, together with its nucleus, is crowded to the periphery. The protoplasm then appears as a thin layer just within the clear cellular membrane. The nucleus becomes flattened by pressure, until in profile view it has the appearance of a long, flat body.

In regions in which large masses of fat-cells are developed, they are seen to be gathered into rounded groups of various sizes (fat lobules) separated by strands of connective tissue. Numerous blood-vessels are imbedded in this connective tissue, penetrating into the lobules and there breaking up into a rich capillary network.

Microscopically, fat is easily recognized by its peculiar glistening appearance (by direct light). It has a specific reaction to certain reagents. It becomes black on treatment with osmic acid, and is stained red by Sudan III.

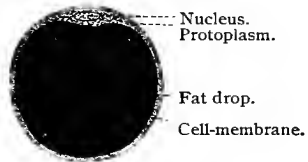


Fig. 71.—Scheme of a fat-cell.

#### 5. CARTILAGE.

The simplest type is *hyaline* cartilage, so named because of its homogeneous and transparent ground-substance. Cartilage cells, as such, are of various shapes, and have no typical appearance. They are usually scattered irregularly throughout the matrix, but are often arranged in groups of two, three, four, or even more cells. At the periphery of cartilage, either where it borders upon a cavity (articular cavity) or where it joins the perichondrium, the cells are arranged in several rows parallel to the surface of the tissue. Cartilage cells often contain glycogen, either in the form of drops or diffused throughout their protoplasm.

The matrix of cartilage is the product of the cell. It is not present in the so-called *precartilage* (embryonal cartilage), in which the cells lie close together with their membranes touching. The ground-substance is gradually formed as follows: The membranes of the cells thicken, pressing the cells apart. Inside of the membranes the cells divide, and each resulting cell again forms a mem-

brane. Membranes of the mother cells fuse to form the ground-substance or matrix. The newly created membranes of the daughter cells pass through the same process, and fuse not only with each

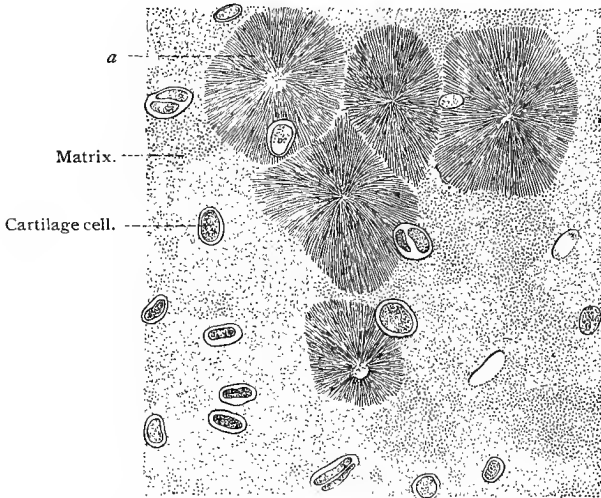


Fig. 72.—Hyaline cartilage (costal cartilage of the ox). Alcohol preparation;  $\times 300$ . The cells are seen inclosed in their capsules. In the figure *a* are represented frequent but by no means characteristic radiate structures.

other, but also with the matrix. The cartilage thus gradually assumes the appearance of its adult stage. The youngest cells also possess membranes which separate them from the ground-substance. These are known as the *capsules*. The spaces occupied by the cells are called *lacunæ*.

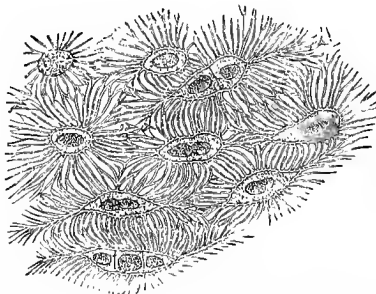


Fig. 73.—From a section through the cranial cartilage of a squid (after M. Fürbringer, from Bergh).

From the description just given it would seem that cartilage grows only by intussusception, but as a matter of fact an appositional growth, although in a lesser degree, also takes place. It

occurs where the cartilage borders upon its connective-tissue sheath or *perichondrium*, a vascular, fibrous-tissue membrane composed of white and elastic fibers, which covers the cartilage except where it forms a joint surface. The relations of the cartilage and perichondrium are extremely intimate. Fibers are seen passing from the perichondrium into the cartilaginous matrix, and the connective-tissue cells appear to change directly into cartilage-cells.

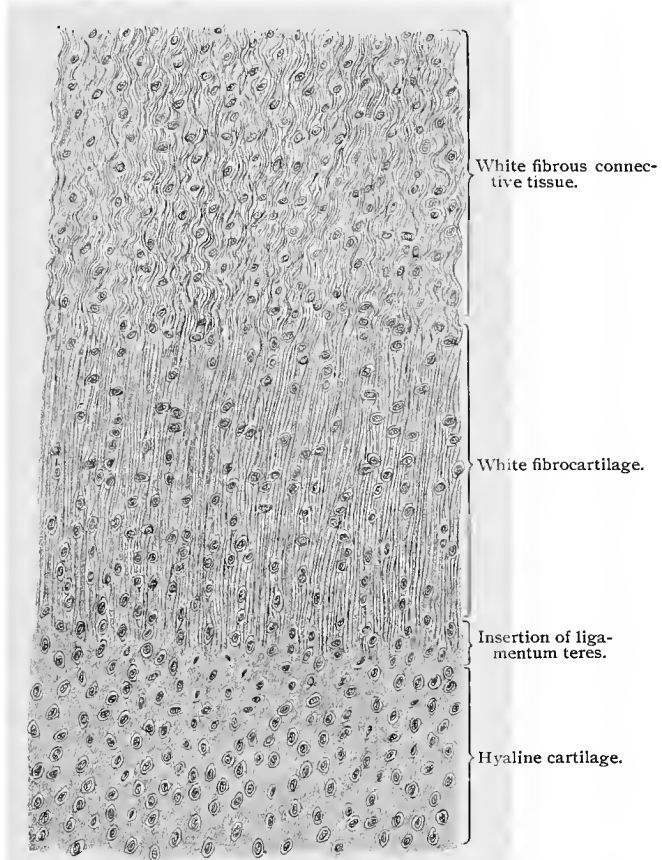


Fig. 74.—Insertion of the ligamentum teres into the head of the femur. Longitudinal section;  $\times 650$ .

It is an interesting fact that the cartilage of certain invertebrate animals, the cephalopoda, shows cells with anastomosing processes. (Fig. 73.) In this case the cartilage-cell is similar to a bone-cell, thus theoretically allowing of the possibility of the metamorphosis of the elements of cartilage into those of bone (M. Fürbringer).

Hyaline cartilage occurs as articular cartilage, covering joint surfaces, as costal cartilage and in the nose, larynx, trachea, and

bronchi. All bones except those of the vault of the skull and the majority of the bones of the face are preformed in hyaline cartilage.

In *white fibrocartilage* (Fig. 74) there are from the beginning, even in precartilage, fibrous strands in the ground-substance. They preponderate over the matrix and, as a rule, have a parallel direction. White fibrocartilage is found in the intervertebral and inter-articular disks, the symphysis pubis, and in the insertion of the ligamentum teres; it deepens the cavity of ball-and-socket joints, and lines the tendon grooves.

In some places elastic fibers are found imbedded in hyaline cartilage—*fibro-elastic cartilage*. The elastic fibers send off at acute angles finer or coarser threads which interlace to form a delicate or

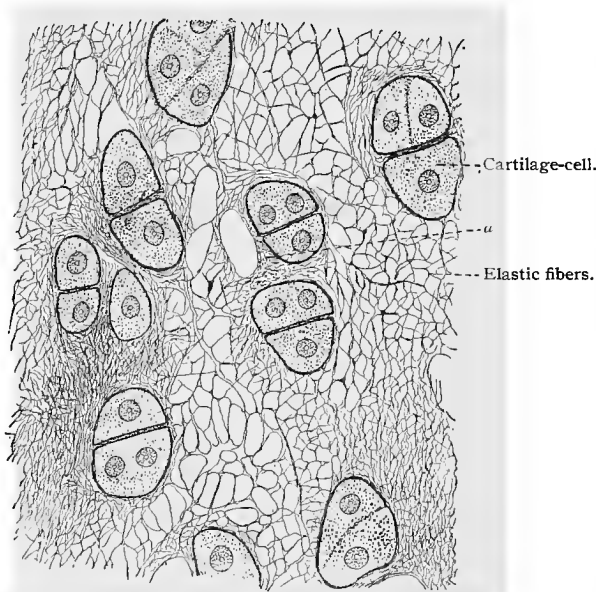


Fig. 75.—Elastic cartilage from the external ear of man;  $\times 760$ . Technic No. 149.  
u, Fine elastic network in the immediate neighborhood of a capsule.

dense network which permeates the hyaline matrix (Fig. 75), passing over into the corresponding elements of the perichondrium. Elastic cartilage is found in the external ear, the cartilage of the Eustachian tube, the epiglottis, a portion of the arytenoid cartilages, and the cartilages of Wrisberg and Santorini.

The hyaline ground-substance of all three forms of cartilage, together with the contained fibers, may undergo calcification, especially in old age. This renders the tissue brittle and easily broken.

The nutrition of cartilage is partially supplied by blood-vessels in the matrix, which, however, are not numerous. Very fine lymph-

canals are probably also present in the matrix, uniting the lacunæ, through which lymph plasma circulates (*vid.* researches of Flesch, Budge, Solger (88, II), van der Stricht (87), etc.).

To obtain *chondrin*, a piece of cartilage matrix is placed in a tube containing water. This is hermetically closed and heated to 120° C., after which it is opened and the fluid filtered and treated with alcohol. A precipitate of chondrin is the result. This substance is insoluble in cold water, alcohol, and ether, but soluble in hot water, although, on cooling, it gelatinizes. In contrast to gelatin, chondrin is precipitated by acetic acid. This precipitate does not redissolve in an excess of this acid but disappears in an excess of certain mineral acids.

## 6. BONE.

(a) **Structure of Bone.**—Bone nearly always develops from a connective-tissue foundation, even where it occurs in places formerly occupied by cartilage.

The inorganic substance of bone is deposited in or between the fibers of connective tissue, while the cells of the latter are transformed into bone-cells.

As in connective tissue, so also in bone, the ground-substance is fibrous. Between the fibers remain uncalcified cells, *bone-cells*, each of which rests in a cavity of the matrix—*lacuna*.

Primarily, bone consists of a single thin lamella, its later complicated structure being produced by the formation of new lamellæ in apposition to the first. During its development the bone becomes vascularized, and the vessels are inclosed in especially formed canals known as *vascular* or *Haversian* canals.

The bone-cells have processes that probably anastomose, and that lie in special canals known as *bone canaliculi*. Whether, in man, all the processes of bone-cells anastomose is still an open question.

The appearance presented by a transverse section of the shaft of a long bone is as follows: In the center is a large marrow cavity, and at the periphery the bone is covered by a dense connective-tissue membrane, the *periosteum*. In the new-born and in young individuals the periosteum is composed of three layers—an outer layer, consisting mainly of rather coarse, white fibrous-tissue bundles that blend with the surrounding connective tissue; a middle fibro-elastic layer, in which the elastic tissue greatly predominates; and an inner layer, the osteogenetic layer, vascular and rich in cellular elements, containing only a few smaller bundles of white fibrous tissue. In the adult the osteogenetic layer has practically disappeared, leaving only here and there a few of the cells of the layer, while the fibro-elastic layer is correspondingly thicker (Schulz, 96). A large number of Haversian canals containing blood-vessels, seen mostly in transverse section, are found in compact bone-substance.

Lamellæ of bone are plainly visible throughout the ground-substance, and are arranged in the following general systems :

First, there is a set of bone lamellæ running parallel to the external surface of the bone, while another set is similarly arranged around the marrow cavity. These are the so-called *fundamental*, or *outer* and *inner circumferential lamellæ* (known also as *periosteal* and *marrow lamellæ*). Around the Haversian canals are the concentrically arranged lamellæ, forming systems of Haversian or *concentric lamellæ*. Besides the systems already mentioned, there are found *interstitial* or *ground lamellæ* wedged in between the Haversian




Fig. 76.—Longitudinal section through a lamellar system. Figs. 77 and 78.—Lamellæ seen from the surface;  $\times 460$  (after v. Ebner 75).

*a*, Primitive fibrils and fibril-bundles; *c*, bone-corpuscles with bone-cells; *d*, bone canaliculi.

or concentric systems of lamellæ. Some authors group the interstitial lamellæ with the systems of fundamental lamellæ.

Lying scattered between the lamellæ are found spaces known as *bone corpuscles* (Virchow) or *lacunæ*. These are present in all the lamellar systems. It is very probable that all the lacunæ are in more or less direct communication with each other by means of fine canals called *canaliculi* ( $1.1 \mu$  to  $1.8 \mu$  in diameter). It can be demonstrated without difficulty that the lacunæ of a single lamellar system communicate not only with each other, but also with those of

adjacent systems. In the lamellæ adjoining the periosteum and marrow cavity the canaliculi end respectively in the subperiosteal tissue and in the marrow cavity. The canaliculi of the Haversian lamellæ empty into the Haversian canals.

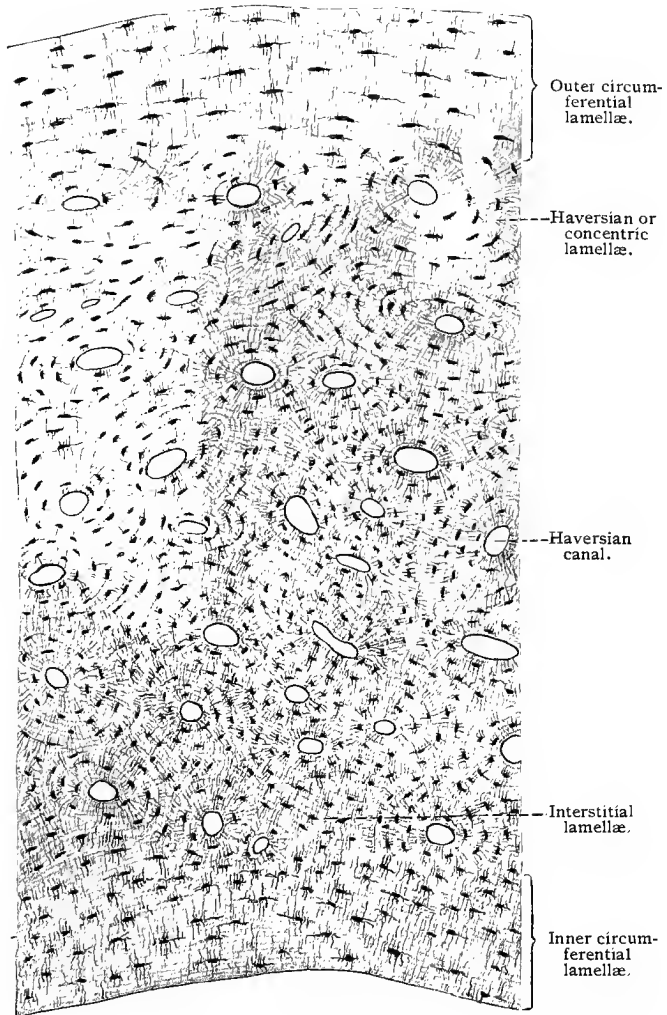


Fig. 79.—Segment of a transversely ground section from the shaft of a long bone, showing all the lamellar systems. Metacarpus of man;  $\times 56$ . Technic No. 152.

The lamellæ of bone are composed of fine white fibrous-tissue fibrils, embedded in a ground-substance, in which they are arranged in layers, superimposed in such a way that the fibrils in the several layers cross at about a right angle, forming an angle of  $45^\circ$  with

the long axis of the Haversian canal. It is as yet undecided whether the mineral salts (phosphate and carbonate of lime, sodium chlorid, magnesium salts, etc.) are deposited in the ground-substance (v. Ebner) or in the fibrillæ (Kölliker). The lacunæ ( $13\ \mu$  to  $31\ \mu$  long,  $6\ \mu$  to  $15\ \mu$  wide, and  $4\ \mu$  to  $9\ \mu$  thick) have, in common with the canaliculi, walls which present a greater resistance to the action of strong acids than the rest of the solid bone-substance. In each lacuna there is found a *bone-cell*, the nucleated body of which practically fills the lacuna, while its processes extend out into the canaliculi.

The Haversian canals contain blood-vessels, either an artery or a vein or both. Between the vessels and the walls of the canals are perivascular spaces bounded by endothelial cells, resting on the adventitious coats of the vessels and the sides of the canals. Into these spaces empty the canaliculi of the Haversian system. Lymph-spaces beneath the periosteum and at the periphery of the marrow

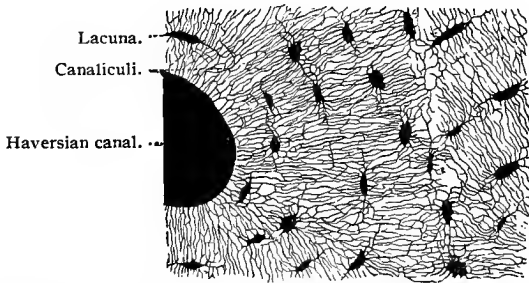


Fig. 80.—Portion of a transversely ground disc from the shaft of a human femur ;  
 $\times 400$ . Technic No. 154.

cavity communicate directly with the canaliculi of the circumferential systems.

All the lacunæ and canaliculi should be thought of as filled by lymph plasma which circulates throughout, bathing the bone-cells and their processes. The formed elements of the lymph are probably too large to force their way through the very small canaliculi. The plasma current probably flows from the periosteal and marrow regions toward the Haversian canals.

Between the lamellæ are bundles of fibers (some of which are calcified), which can be demonstrated by heating the bone, or in decalcified preparations on staining by certain methods. These are the so-called *fibers of Sharpey*; in the adult they contain elastic fibers.

In the circumferential lamellæ are found canals, not surrounded by concentric lamellæ, which convey blood-vessels from the periosteum to the Haversian canals. These are called *Volkman's canals*.

The structure of bone-marrow will be discussed with the blood-forming organs.

(b) **Development of Bone.**—Nearly all the bones of the adult body are, in the earlier stages of embryonic life, preformed in embryonic cartilage. As development proceeds, this embryonic cartilage assumes the character of hyaline cartilage, its cells becoming vesicular, and probably disappearing. In the matrix, however, there are formed spaces that are soon occupied by cells and vessels which grow in from a fibrous-tissue membrane (the future periosteum) surrounding the cartilage fundaments of the bones. These cells deposit a bone matrix in the cartilage spaces. Bone developed in this manner is known as *endochondral* or *intracartilaginous* bone. In certain bones—namely, those of the vault of the skull and nearly all the bones of the face—there is no preformation in cartilage, these bones being developed from a connective-tissue foundation. They are known as *intramembranous* bones. As will become evident upon further discussion of the subject, the formation of fibrous-tissue bone (intramembranous) is not confined to bones *not* preformed in cartilage. In bones preformed in cartilage, fibrous-tissue bone develops from the connective-tissue membrane surrounding the cartilage fundaments, the two types of bone-development going on simultaneously in such bones. Attention may further be drawn to the fact that nearly all endochondral bone is absorbed, so that the greater portion of all adult bone, even that preformed in cartilage, is developed from a foundation of fibrous tissue. The two modes of ossification—endochondral or intracartilaginous and intramembranous—even though appearing simultaneously in the majority of bones, will, for the sake of clearness, be discussed separately.

1. **Endochondral Bone-development.**—The cartilage that forms the fundaments of the bones preformed in cartilage has at first the appearance of embryonic cartilage, consisting largely of cells with a small amount of intercellular matrix. These fundaments are surrounded by a fibrocellular membrane—the perichondrium. Ossification is initiated by certain structural changes in the embryonic cartilage, in one or several circumscribed areas, known as *centers of ossification*. In the long bones a center of ossification appears in the middle of the future diaphysis. In this region the intercellular matrix increases in amount and the cells in size; thus the embryonic cartilage assumes the character of hyaline cartilage. This is followed by a further increase in the size of the cartilage-cells, at the expense of the thinner partitions of matrix separating neighboring cells, while at the same time lime granules are deposited in the matrix remaining. During this stage the cells appear first vesicular, distending their capsules, then shrunken, only partly filling the enlarged lacunæ. They stain less deeply, and their nuclei show degenerative changes. The center of ossification, in the middle of which these changes are most pronounced, is surrounded by a zone in which these structural changes are not so far advanced and which has the appearance at its periphery of hyaline cartilage.

Simultaneously with these changes in the cartilage, a thin layer

of bone is deposited by the perichondrium (in a manner to be described under the head of intramembranous bone-development) and the perichondrium becomes the periosteum. This in the meantime has differentiated into two layers—an outer, consisting largely of fibrous tissue with few cellular elements, and an inner, the osteogenetic layer, vascular and rich in cellular elements and containing few fibrous-tissue fibers.

Ossification in the cartilage begins after the above-described

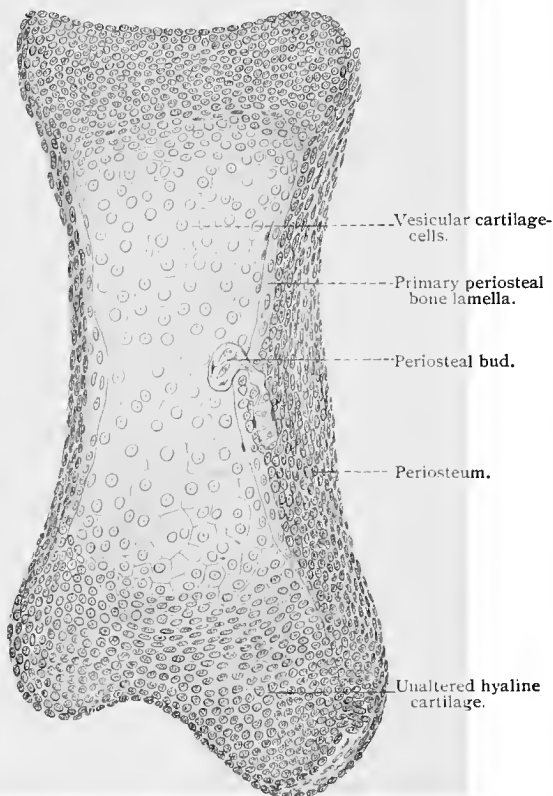


Fig. 81.—Longitudinal section through a long bone (phalanx) of a lizard embryo. The primary bone lamella originating from the periosteum is broken through by the periosteal bud. Connected with the bud is a periosteal blood-vessel containing red blood-corpules.

structural changes have taken place at the center of ossification. Its commencement is marked by a growing into the cartilage of one or several buds or tufts of tissue derived principally from the osteogenetic layer of the periosteum. As the periosteal buds grow into the cartilage, some of the septa of matrix separating the altered cartilage-cells disappear, and the cells become free and probably degenerate. In this way the cartilage at the center of ossi-

fication becomes hollowed out, and there are formed irregular anastomosing spaces, *primary marrow spaces*, separated by partitions or trabeculæ of calcified cartilage matrix. Into these primary marrow spaces grow the periosteal buds, consisting of small blood-vessels, cells, and some few connective-tissue fibers, forming embryonic marrow tissue. Some of the cells which have thus grown into

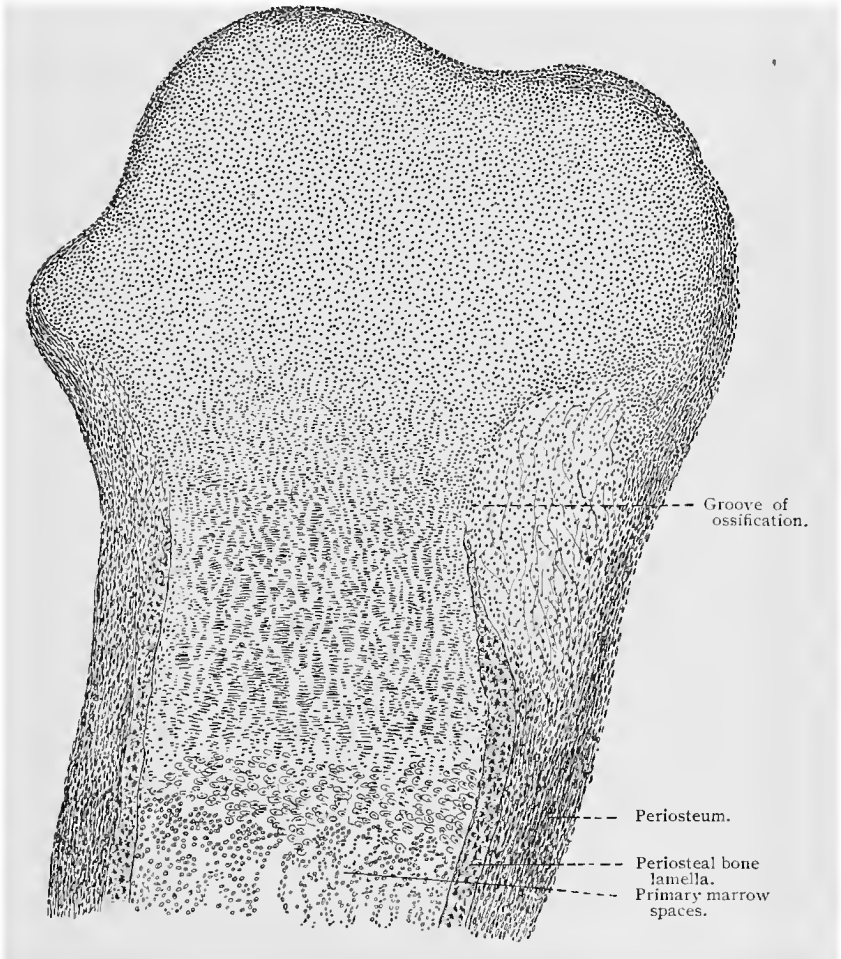


Fig. 82.—Longitudinal section of the proximal end of a long bone (sheep embryo);  
 × 30.

the primary marrow spaces arrange themselves in layers on the trabeculæ of calcified matrix, which they envelop with a layer of osseous matrix formed by them. The cells thus engaged in the formation of osseous tissue are known as *osteoblasts*.

Ossification proceeds from the center of ossification toward the

extremities of the diaphysis (in a long bone), and is always preceded, as at the center of ossification, by the characteristic structural changes above described. Beginning at the center of ossification and proceeding toward either extremity of the diaphysis, the enlarged and vesicular cartilage-cells will be observed to be arranged in quite regular columns, separated by septa or trabeculae of calcified cartilage matrix. The cells thus arranged in columns show the degenerative changes above described. They are shrunken and flattened, and their nuclei, when seen, stain less deeply than the nuclei of normal cartilage-cells. Beyond this zone of columns of altered cartilage-cells are found smaller or larger groups of less changed cartilage-cells, and beyond this zone, hyaline cartilage.

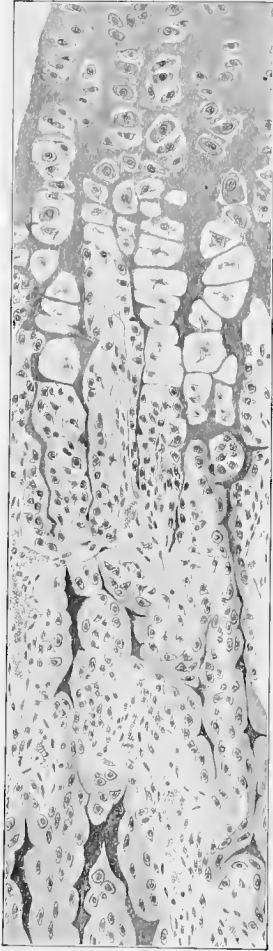

Fig. 83.—Longitudinal section through area of ossification from long bone of human embryo.

The arrangement of the cartilage-cells in the columns above mentioned is, according to Schiefferdecker, mainly due to two factors—the current of lymph plasma which flows from the center of ossification toward the two extremities of the cartilage fundament, and the mutual pressure exerted by the groups of cartilage-cells in their growth and proliferation. Ossification proceeds from the center of the diaphysis toward its two extremities by a growth of osteoblasts and small vessels into the columns of cartilage-cells. Here, also, these degenerate, leaving in their stead irregular, oblong, anastomosing spaces, separated by septa and trabeculae of calcified cartilage matrix on which the osteoblasts arrange themselves in layers, and which they envelop in osseous tissue. In a longitudinal section of a long bone, preformed in cartilage, the various steps of endochondral bone-development may, therefore, be observed by viewing the preparation from either end to the center of the diaphysis, as may be seen in figures 82, 83. The former represents the appearance

as seen under low magnification, the latter a small portion of such a section from the area of ossification, more highly magnified.

Adjoining the primary marrow spaces is vesicular cartilage and columns and groups of cartilage-cells and finally hyaline cartilage.

In the upper portion of figure 83 is observed a zone composed of groups of cartilage-cells, adjoining this a zone composed of columns of vesicular and shrunken cartilage-cells, the nuclei of which are indistinctly seen. These columns are separated by septa and trabeculæ of calcified matrix. This zone is followed by one in which the cartilage-cells have disappeared, leaving spaces into which the osteoblasts and small blood-vessels have grown. In certain parts of the figure, the osteoblasts are arranged in a layer on the trabeculæ of calcified cartilage, some of which are enveloped in a layer of osseous matrix, less deeply shaded than the darker cartilage remnants.

As the development of endochondral bone proceeds from the center of ossification toward the extremities of the diaphysis in the manner described, the primary marrow spaces at the center of ossification are enlarged, a result of an absorption of many of the smaller osseous trabeculæ and the remnants of calcified cartilage matrix enclosed by them. In this process are concerned certain large and, for the most part, polynuclear cells, which are differentiated from the embryonic marrow. These are the *osteoclasts* (bone breakers) of Kölliker (73). They are  $43\ \mu$  to  $91\ \mu$  long and  $30\ \mu$  to  $40\ \mu$  broad, and have the function of absorbing the bone. The spaces which they hollow out during the beginning of the process appear as small cavities or indentations, containing osteoclasts either single or in groups, and are known as *Howship's lacunæ*. All bone absorption goes hand in hand with their appearance. At the same time, the osseous trabeculæ not absorbed become thickened by a deposition of new layers of osseous tissue (by osteoblasts), during which process some of the osteoblasts are enclosed in the newly formed bone and are thus converted into bone-cells. In this way there is formed at the center of ossification a primary or embryonic spongy or cancellous bone, surrounding *secondary marrow spaces* or *Haversian spaces*, filled with embryonic marrow. This process of the formation of embryonic cancellous bone follows the primary ossification from the center of ossification toward the extremities of the diaphysis. It should be further stated, that long before the developing bone has attained its full size—indeed, before the end of embryonic life—the embryonic cancellous bone is also absorbed through the agency of osteoclasts. The Haversian spaces are thus converted into one large cavity, which forms a portion of the future marrow cavity of the shaft of the fully developed bone. The absorption of the embryonic cancellous bone begins at the center of ossification and extends toward the ends of the diaphysis.

Some time after the beginning of the process of bone development at the center of ossification of the diaphysis, centers of ossification appear in the epiphyses, the manner of the development of bone being here the same as in the diaphysis. Several periosteal buds grow into each center of ossification, filling the irregular spaces formed by the breaking down of the degener-

ated cartilage-cells. Osteoblasts are arranged in rows on the trabeculæ of cartilage thus formed, which they envelop in osseous tissue. As development proceeds, the primary osseous tissue is converted into embryonic cancellous bone as above described.

In the development of the epiphyses, as in the development of the smaller irregular bones, the formation of bone proceeds from the center or centers of ossification in all directions, and not only in a direction parallel to the long axis of the bone as described for the diaphysis. The epiphyses grow, therefore, in thickness as well as in length, by endochondral bone-development.

There remains between the osseous tissue developed in the diaphysis and that in the epiphyses, at each end of the diaphysis, a zone of hyaline cartilage in which ossification is for a long time delayed; this is to permit the longitudinal growth of the bone. These layers of cartilage constitute the epiphyseal cartilages. Here the periosteum (perichondrium) is thickened and forms a raised ring around the cartilage. As it penetrates some distance into the substance of the cartilage, the latter is correspondingly indented. (Fig. 82.) The impression thus formed appears in a longitudinal section of the bone as an indentation,—the *ossification groove* (*cncoche d'ossification*, Ranvier, 89). That portion of the perichondrium filling the latter is called the *ossification ridge*. The relation of the elements of the perichondrium to the cartilage in the region of the groove just described is an extremely intimate one, both tissues, perichondrium and cartilage, merging into each other almost imperceptibly. It is a generally accepted theory that so long as the longitudinal growth of the bone persists, new cartilage is constantly formed at these points by the perichondrium. In the further production of bone this newly developed cartilage passes through the preliminary changes necessary before the actual commencement of ossification—*i. e.*, it goes through the stages of vesicular cartilage and the formation of columns of cartilage-cells, in place of which, later, the osteoblasts and primary marrow cavities develop.

By the development of new cartilage elements from the *cncoche* the longitudinal growth of the bone is made possible; at the same time, those portions of the cartilage thus used up in the process of ossification are immediately replaced. (Fig. 84.)

The following brief summary of the several stages of endochondral bone-development may be of service to the student:

1. The embryonic cartilage develops into hyaline cartilage, beginning at the centers of ossification.
2. The cartilage-cells enlarge and become vesicular. In the diaphysis of long bones such cells are arranged in quite regular columns, while in the epiphyses and irregular bones this arrangement is not so apparent.
3. Calcification of the matrix ensues; the cartilage-cells disappear (degenerate); primary marrow spaces develop.
4. Ingrowth of periosteal buds. The osteoblasts are arranged

in layers on the trabeculæ of calcified cartilage, which they envelop with osseous tissue.

5. Osteoclasts cause the absorption of many of the smaller osseous trabeculæ; others become thickened by a deposition of new layers of osseous tissue. Osteoblasts are enclosed in bone-tissue and become bone-cells. In this way there is formed embryonic cancellous bone, bounding Haversian spaces inclosing embryonic marrow.

6. In the diaphysis, the greater portion of the embryonic cancellous bone is also absorbed (by osteoclasts); the Haversian spaces unite to form a part of the marrow space of the shaft of the bone.

2. **Intramembranous Bone.**—This, the simpler type of ossification, occurs in bone developed from a connective-tissue foundation, and is exemplified in the formation of the bones of the

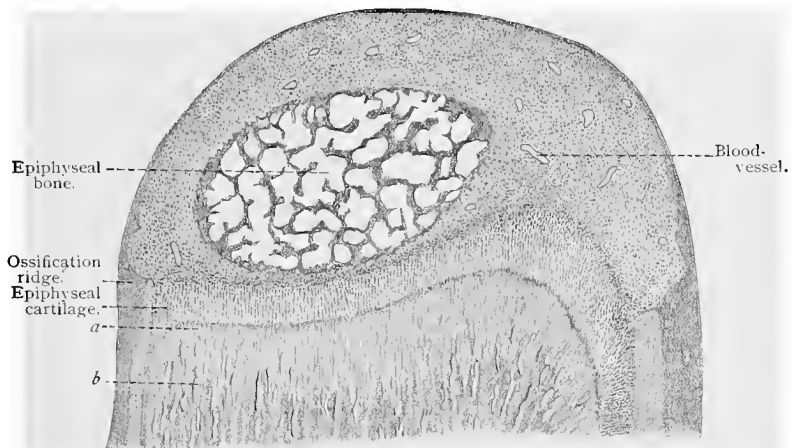


Fig. 84.—Longitudinal section through epiphysis of arm bone of sheep embryo;  $\times 12$ .  
*a, b*, Primary marrow spaces and bone lamellæ of the diaphysis.

cranial vault and the greater number of the bones of the face, and also in bone developed from the periosteum (perichondrium) surrounding the cartilage fundaments of endochondral bone. All fibrous-tissue bone is developed in the same way.

The intramembranous bone-development begins by an approximation and more regular arrangement of the osteoblasts of the osteogenetic layer of the periosteum about small fibrous-tissue bundles. The osteoblasts then become engaged in the formation of the osseous tissue which envelops the fibrous-tissue bundles. In this way a spongy bone with large meshes is formed, consisting of irregular osseous trabeculæ, surrounding primary marrow spaces. These latter are filled by embryonic marrow and blood-vessels developed from the tissue elements of the periosteum not engaged in the formation of bone.

Intramembranous bone first appears in the form of a thin lamella of bone, which increases in size and thickness by the formation of trabeculæ about the edges and surfaces of that previously formed and in the manner above described. A layer of intramembranous bone thus surrounds the endochondral bone in bones preformed in hyaline cartilage. The two modes of ossification may, therefore, be observed in either a cross or a longitudinal section of a developing bone preformed in hyaline cartilage. In such preparations the endochondral bone can be readily distinguished from the intra-

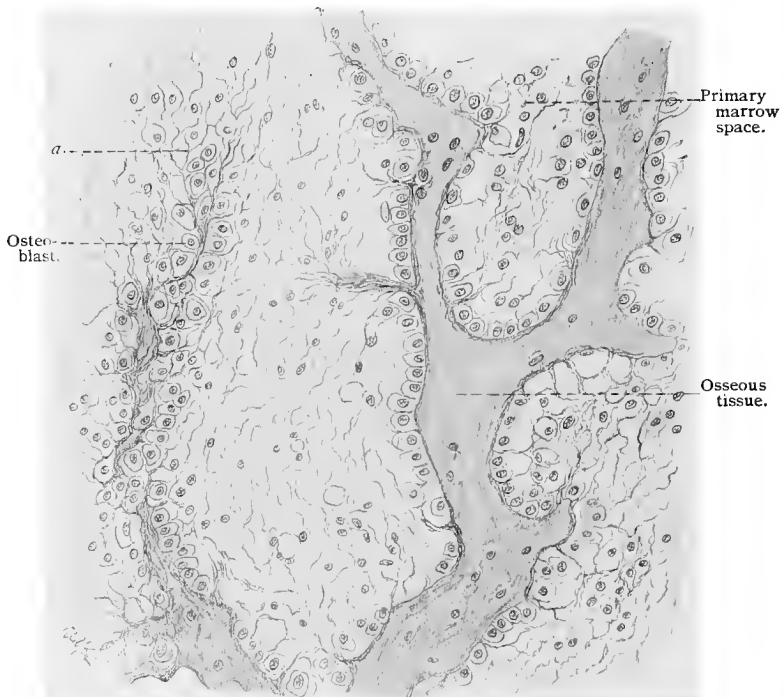


Fig. 85.—Section through the lower jaw of an embryo sheep (decalcified with picric acid);  $\times 300$ . At *a* and immediately below are seen the fibers of a primitive marrow cavity lying close together and engaged in the formation of the ground-substance of the bone, while the cells of the marrow cavity, with their processes, arrange themselves on either side of the newly formed lamella and functionate as osteoblasts.

membranous bone by reason of the fact that remnants of calcified cartilage matrix may be observed in the osseous trabeculæ of the former. It will be remembered that these osseous trabeculæ develop about the calcified cartilage matrix remaining after the disappearance of the cartilage-cells. In figure 86, which shows a cross-section of a bone from the leg of a human embryo, these facts are clearly shown. A study of this figure shows the endochondral bone, with the remnants of the cartilage matrix (shaded more

deeply) inclosed in osseous tissue, making up the greater portion of the section and surrounded by the intramembranous bone.

In figure 87, more highly magnified, the relations of endochondral to intramembranous bone and the details of their mode of development are shown; also the structure of the periosteum.

As was stated in the previous section, soon after the formation of the endochondral bone, this is again absorbed; the process of endochondral bone-formation and absorption extending from the center of ossification toward the ends of the diaphysis. Before the absorption of the endochondral bone, the intramembranous bone has attained an appreciable thickness and surrounds the marrow cavity formed on the absorption of the endochondral bone. Before,

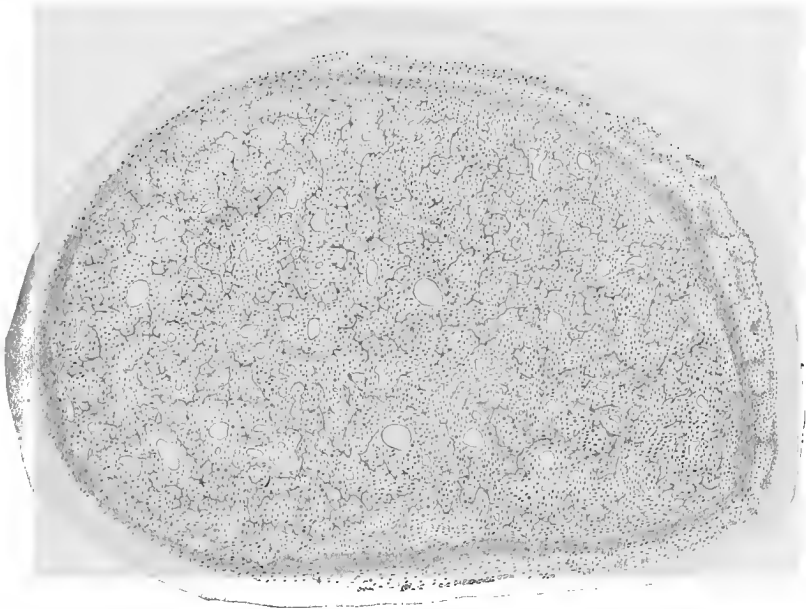


Fig. 86.—Cross-section of developing bone from leg of human embryo, showing endochondral and intramembranous bone-development.

however, the marrow cavity can attain its full dimensions, much of the intramembranous bone must also undergo absorption. While intramembranous bone is being developed from the periosteum and thus added to the outer surface of that already formed, osteoclasts are constantly engaged in its removal from the inner surface of the intramembranous bone. The marrow cavity is thus enlarged, the process continuing until the shaft attains its full size.

The compact bone of the shaft is developed from the primary spongy intramembranous bone after the following manner: The primary marrow spaces are enlarged by an absorption, through the agency of osteoclasts, of many of the smaller trabeculæ of osse-

ous tissue and by a partial absorption of the larger ones, the primary marrow spaces thus becoming secondary marrow spaces, or Haversian spaces. The osteoblasts now arrange themselves in layers

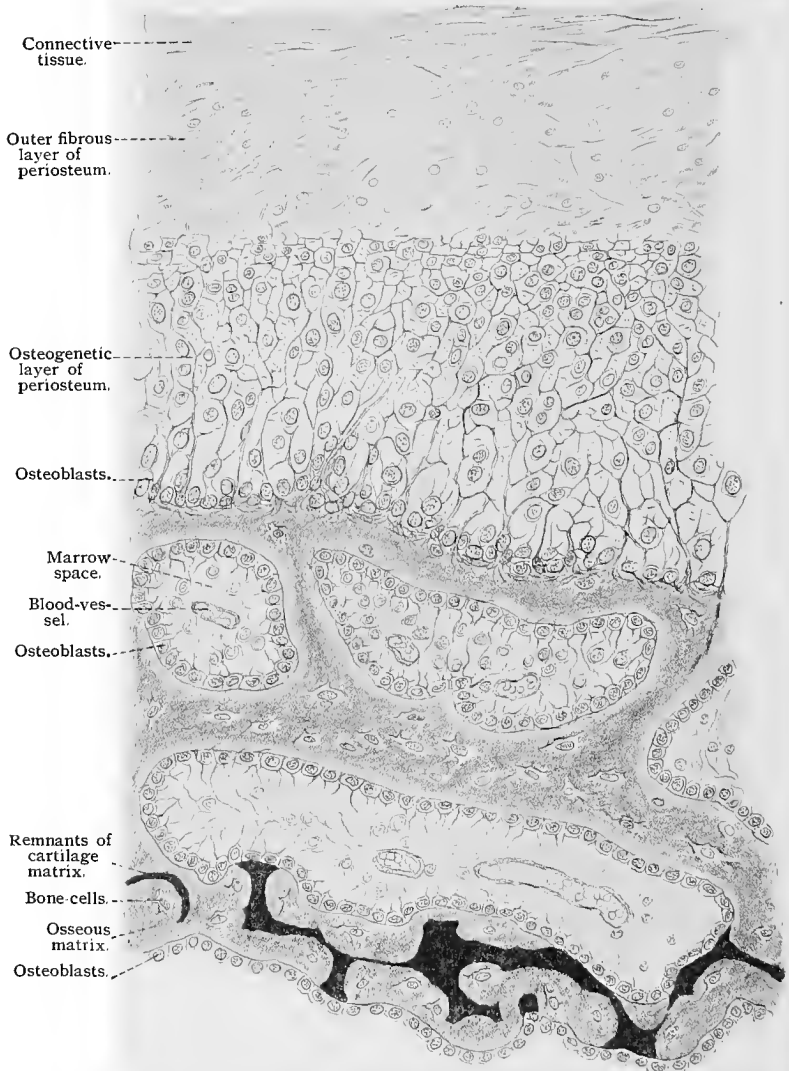


Fig. 87.—From a cross-section of a shaft (tibia of a sheep);  $\times 550$ . In the lower part of the figure is endochondral bone-formation (the black cords are the remains of the cartilaginous matrix); in the upper portion is bone developed from the periosteum.

about the walls of the Haversian spaces and deposit lamella after lamella of bone matrix, concentrically arranged, until the large Haversian spaces have been reduced to Haversian canals. During

this process many of the osteoblasts become inclosed in bone matrix, forming bone-cells and the blood-vessels of the Haversian spaces remain as the vessels found in the Haversian canals. The spongy intramembranous bone not absorbed at the commencement of the formation of the system of concentric lamellæ, remains between the concentric systems as interstitial lamellæ. The circumferential lamellæ are those last formed by the periosteum. Calcification of the osseous matrix takes place after its formation by the osteoblasts.

From what has been stated it may be seen that the shafts of the long bones and bones not preformed in cartilage develop by the process of intramembranous bone-formation, while the cancellous bone in the ends of the diaphysis and in the epiphyses is endochondral bone. Further, that long bones grow in length by endochondral bone-development, and in thickness by the formation of intramembranous bone. In the development of the smaller irregular bones, both processes may be engaged; the resulting bone can not, however, be so clearly defined.

#### TECHNIC.

**133.** One of the methods for examining connective-tissue cells and fibers is that recommended by Ranvier (89); it is as follows: The skin of a recently killed dog or rabbit is carefully raised, and a 0.1% aqueous solution of nitrate of silver injected subcutaneously by means of a glass syringe. The result is an edematous swelling in which the connective-tissue cells and fibers (the latter somewhat stretched) come into immediate contact with the fixing fluid and are consequently preserved in their original condition. In about three-quarters of an hour the whole elevation should be cut out (it will not now collapse) and small fragments placed upon a slide and carefully teased. Isolated connective-tissue cells with processes of different shapes, having the most varied relations to those from adjacent cells, are seen. The fibers themselves either consist of several fibrils, or, if thicker, are often surrounded by a spirally encircling fibril. By this method numerous elastic fibers and fat-cells are also brought out. If a drop of picrocarmin be added to such a teased preparation and the whole allowed to remain for twelve hours in a moist chamber, and formic glycerin (a solution of 1 part formic acid in 100 parts glycerin) be then substituted for twenty-four hours, the following instructive picture is obtained: All nuclei are colored red, the white fibrous connective-tissue fibers pink, the fibrils encircling the latter brownish-red, and the elastic fibers canary yellow. The peripheral protoplasm of the fat-cells is particularly well preserved, a condition hardly obtainable by any other method.

**134.** Connective tissue with a parallel arrangement of its fibers is best studied in tendon, those in the tails of rats and mice being particularly well adapted to this purpose. If one of the distal vertebræ of the tail be loosened and pulled away from its neighbor, the attached tendons will become separated from the muscles at the root of the tail and appear as thin glistening threads. These are easily teased on a slide into fibers and

fibrils. Such preparations are also useful in studying the action of reagents (see below).

The substance resembling mucin which cements the fibrillæ together is soluble in lime-water and baryta-water—a circumstance made use of and recommended by Rollet (72, II) as a method for the isolation of connective-tissue fibrils. In necrotic tissue the fibers show a degeneration into fibrils (Ranvier, 89).

If connective tissue be heated in water or dilute acids to 120° C., and the fluid then filtered, a solution is obtained from which collagen can be precipitated by means of alcohol. This is insoluble in cold water, alcohol, and ether, but is soluble in hot water and when dissolved in the latter and cooled, becomes transformed into a gelatinous substance. Unlike mucin and chondrin this substance does not precipitate on the addition of acetic and mineral acids. Tannic acid and corrosive sublimate will cause precipitation, as also in the case of chondrin, but *not* with mucin (*vid.* also Hoppe-Seyler).

**135.** Elastic tissue may be obtained by treating connective tissue with potassium hydrate solution, and if the alveoli of the lungs be treated for some time with this reagent, very small elastic fibers can be obtained. By this means the connective-tissue fibers are dissolved, but not the elastic fibers. Particularly coarse fibers are found in the ligamenta subflava.

**136.** According to Kühne, connective and elastic tissues are differently affected by **trypsin digestion**—*i. e.*, alkaline glycerin-pancreas extract at 35° C.—white fibrous connective tissue being resolved into fibrils, while elastic tissue is entirely dissolved.

**137.** Elastic fibers remain unchanged in **acetic acid**, and even when boiled in a 20% solution they only become slightly brittle. They are, however, rapidly destroyed by concentrated hydrochloric acid, although in a 10% solution at ordinary temperature no change is seen. In a 50% solution the fiber is dissolved in seven days, and in a concentrated solution in two days. The inner substance of the fiber is first attacked, then the membrane. To demonstrate this membrane, the fibers are boiled several times in concentrated hydrochloric acid and the whole then poured into cold water. Occasionally, a longitudinal striation of the membrane is seen, indicating a fibrillar structure. Concentrated solutions of potassium hydrate disintegrate the fibers in a few days; weak solutions, more slowly. A 1% solution of potassium hydrate requires months to produce the effect; a 2% solution, one month; a 5%, three days; a 10%, one day; and 20% to 40%, only a few hours. A weak solution of potassium hydrate, even when brought to the boiling-point, does not dissolve elastic fibers, nor does it cause them to become brittle. If, however, they be boiled in a 5% or 10% solution of potassium hydrate, the membranes of the fibers will be isolated. A cold 20% solution has the same effect in one or two days. Pepsin induces a disintegration of the contents of the fiber, leaving the membranes intact (F. P. Mall).

**138. Orcein**, if correctly applied, colors elastic fibers a dark brown, and can be used to demonstrate them in sections (Unna, 91). The solution is made as follows:  $\frac{1}{10}$  gm. of orcein is dissolved in 20 c.c. 95% alcohol and 5 c.c. distilled water. This is then diluted one-half by adding a solution composed of 0.1 c.c. hydrochloric acid, 20 c.c. 95% alcohol, and 5 c.c. distilled water. The sections are stained for twenty-four hours and differentiated in acid alcohol for about a

minute. Then the nuclei may be stained either with hematoxylin or methylene-blue, and the specimens carried over into absolute alcohol, next into xylol, and finally mounted in Canada balsam.

**139. Trypsin** quickly dissolves elastic fibers, but not tendon and reticulated tissue, the latter remaining unchanged for days. Putrefaction disintegrates the ligamentum nuchæ in a few days, the internal structure of the fibers suffering first, the membranes last.

**140.** To demonstrate the inner substance of elastic fibers and their membranes, **magenta red** has been recommended (a small granule is added to 50 c.c. glycerin and 50 c.c. water). By this method the internal substance is colored red while the enveloping sheath remains colorless.

**141.** To F. P. Mall also belongs the credit for a few data, which we insert, as to the different reactions which various connective-tissue substances show when treated by the same reagents.

When a tendon is boiled it becomes shorter, but if it be fixed before boiling, there is no change. Adenoid reticulum shrinks when boiled, but after a short time swells, and finally dissolves. Both tendon and adenoid reticulum shrink at 70° C. If, however, they be first treated with a 0.5% solution of osmic acid, the shrinkage will not take place until 95° C. is reached. If the reticulum or the tendon has become shrunken through heat, they are easily digested with pancreatin, and putrefy very readily. Tendon fibers do not become swollen in glacial acetic acid, either concentrated or in strengths of 0.05% or less, but in strengths of 0.5% to 25% they swell, and if placed in a 25% solution they will dissolve in twenty-four hours. They also swell in hydrochloric acid in strengths of 0.1% to 6%. In strengths of 6% to 25% the fibers remain unchanged for some time, and only dissolve in a concentrated solution of this acid. Reticulated tissue, on the other hand, swells in a 3% hydrochloric acid solution, but remains unchanged in strengths of 3% to 10%. It dissolves in twenty-four hours in solutions of 25% and over. After treatment with a dilute solution of acid, tendon dissolves more rapidly on boiling than does reticular tissue.

Tendon exposed to the action of the gastric juice of a dog does not dissolve more rapidly than elastic tissue; but if placed in an artificial solution of gastric juice, tendon dissolves first, then reticular tissue, and finally elastic fibers. Pancreatin affects neither tendon nor reticulated tissue, but if boiled, both tissues are easily digested by its action. If taken out of the body, neither tendon nor reticulum will become affected by putrefaction. In the body, however, and especially at high temperatures (37° C.), both tissues are decomposed within a few days.

**142.** Fresh adipose tissues can be obtained in lobules and in small groups of cells from the mesenteries of small animals. As a rule, the highly refractive fat globule hides from view the nucleus and protoplasm of the cell. The latter structures can be brought out by the subcutaneous injection of silver nitrate solution, this forming the edematous elevation previously described (*vid. T. 133*). Fresh fat is soluble in ether and chloroform, especially if the latter be heated. Strong sulphuric acid does not dissolve fat. The stains made from the root of the henna plant color fat red (the color disappearing in ethereal oils). Quinolin-blue, dissolved in dilute alcohol, stains fat a dark blue. If a 40% potassium hydrate solution be then added, everything will become decolorized except

the fat. The most important reagent for demonstrating adipose tissue is osmic acid (and its mixtures). Small pieces of adipose tissue are treated for twenty-four hours with a 0.5% to 1% osmic acid solution; if mixtures containing osmic acid be used, the specimens are generally immersed for a somewhat longer period. The pieces are then washed with water, and should not be placed directly into alcohol of full strength, as all the structures would then become intensely black (Flemming, 89), but carried into alcohols of ascending strength. When treated in this way the globules of fat take a more intense stain than the other tissues, which, nevertheless, are blackened to some extent.

143. Fat that has been subjected to **osmic acid treatment** dissolves readily in turpentine, xylol, toluol, ether, and creosote, with difficulty in oil of cloves, and not at all in chloroform. Such preparations are best carried from chloroform into paraffin. Fat that has been stained with osmic acid can be decolorized by nascent chlorin. The specimens are placed in a jar of alcohol in which crystals of potassium chlorid have been previously placed. Hydrochloric acid is then added (to 1%) and the vessel tightly sealed (P. Mayer, 81).

144. L. Daddi has recently recommended **Sudan III** as a stain for fat. This reagent can be applied in two ways: (1) Either the animals are fed with the coloring matter for some days, in which case all the fat will be colored red, or (2) either fresh or fixed pieces of tissue or sections are stained. Fixation before staining must be done in media that do not dissolve fat, as, for instance, Müller's fluid. A saturated alcoholic solution of the stain is used and allowed to act from five to ten minutes. The specimen is then washed with alcohol and mounted in glycerin. The author's experiments with Sudan have been very satisfactory.

145. Thin lamellæ of fresh cartilage are examined after separating them from the soft parts and placing them in indifferent fluids. Cartilage removed from the hyposternum or episternum or scapula of a frog is especially adapted for examination. Larger pieces of uncalcified cartilage may be used if cut into sufficiently thin sections with a razor moistened with an indifferent fluid. Under the microscope such sections show a finely punctated background with capsules containing cartilage-cells, provided the latter have not fallen out in the process of cutting, in which case lacunæ will be observed.

146. **Osmic acid and corrosive sublimate** are by far the best fixing agents for cartilage. If the cartilage be calcified, it is fixed for some time in picric acid, which at the same time acts as a decalcifying agent. Although alcohol fixes cartilage fairly well, it causes shrinkage of the cells. The ground substance may be specifically colored by certain reagents, safranin producing an orange and hematoxylin a blue stain.

147. On treating cartilage by certain methods, systems of lines appear in its ground substance, possibly indicating a **canalicular system** in the cartilage. In order to make these structures visible, Wolters recommends staining thin sections for twenty-four hours in a dilute solution of Delafield's hematoxylin (violet blue) (*vid.* T. 62). They are then treated with a concentrated alcoholic solution of picric acid.

148. The capsules are seen to best advantage if small pieces of cartilage are treated with a 1% solution of **gold chlorid**.

149. Connective-tissue and elastic fibers in cartilage are easily

demonstrated by staining the specimens with **picrocarmin**. The connective-tissue fibers are colored a pale pink, the elastic fibers yellow. The latter may also be stained with a 1% aqueous solution of acid fuchsin.

**150.** If a section of fresh cartilage be placed in a weak solution of **iodo-iodid of potassium** (Lugol's solution), glycogen can sometimes be seen in the cartilage-cells, stained a peculiar mahogany brown. If elastic fibers be present, they also are stained brown, but of a different shade.

**151.** Thin bone lamellæ, such as occur in the walls of the ethmoidal cells, can be cleaned of all the soft parts and examined without further manipulation. If larger bones are scraped with a sharp knife, pieces suitable for microscopic examination are sometimes obtained.

**152.** If, however, the denser structure of the large bones is to be more closely examined, the following is the best procedure: A long bone is thoroughly freed from fat and other soft parts by allowing it to macerate, after which it is thoroughly washed and dried, thus freeing it from its organic material. Then, by means of two parallel cuts with a saw, as thin a disc as possible is cut out. The section is now ground still thinner, either between two hones or upon a piece of glass covered with emery. One surface of the bone is then polished and fastened by means of heated Canada balsam to a thick square plate of glass with the polished side toward the glass. Care should be taken that no air-bubbles are inclosed between the section and the glass. As soon as the specimen is firmly adherent, the other side is ground upon the emery plate or hone, during which manipulation the glass to which the bone has been fastened is held between the fingers. As soon as the section is sufficiently thin and transparent, it is polished. In order to remove the Canada balsam and powdered bone from the section, the glass and bone are dried and placed in some solvent of Canada balsam, such as xylol. This loosens the specimen from the glass, after which it is immersed in absolute alcohol, thoroughly washed, and dried in the air. On examining the bone through the microscope, its lacunæ will appear black on a colorless background. The reason is, that the air has taken the place of the evaporated alcohol and the spaces appear black by direct light.

**153.** Sections thus prepared may be permanently mounted as follows: Small pieces of dry Canada balsam are placed both upon a slide and a cover-glass and warmed until they have become fluid, then allowed to cool until a thin film forms over the balsam; the bone disc is then placed upon the balsam on the slide and quickly covered with the cover-glass. A firm pressure will evenly distribute the balsam, and if the whole has been done with sufficient rapidity the air will have been caught in the open spaces of the bone before the Canada balsam has had a chance to enter these spaces.

**154.** Other substances may be used to demonstrate the spaces in bone. Ranvier (75) recommends the following method: A few c.c. of a concentrated alcoholic solution of anilin blue (which is soluble in alcohol and not soluble in water and sodium chlorid solution) are placed in an evaporating dish containing the dry bone. The solution is very carefully evaporated, as the alcohol may otherwise ignite. The specimen, which will soon be covered on both surfaces by a blue powder, is taken out and ground upon a rough glass plate until thoroughly clean. While being

polished the bone should be kept moist by a solution of sodium chlorid (*vid.* T. 13). On heating in the evaporating dish, the air is driven from the spaces and replaced by the anilin blue. As already stated, anilin blue is insoluble in sodium chlorid solution, and it therefore remains unaffected by the latter during the process of grinding and cleaning. Hence it remains in the lacunæ and canaliculi of the bone, which then appear blue. The specimen may either be mounted in glycerin-sodium chlorid and the edge of the cover-glass sealed with varnish (*vid.* T. 99), or the section may be washed for a short time in water (in order to remove the sodium chlorid), dried, and finally mounted in Canada balsam as directed.

**155.** In bone, as also in cartilage, there sometimes occur amorphous as well as crystalline deposits of lime-salts. Upon the addition of acetic acid the carbonate of calcium gives off bubbles; upon the addition of sulphuric acid, short, thin needles will be formed—crystals of gypsum. Hematoxylin stains the lime-salts blue, with the exception of the oxalate of lime. Alkaline solution of purpurin stains calcium carbonate red. Caustic potash does not affect lime.

**156.** In order to study the organic constituents of bone, it must first be decalcified and thus rendered suitable for sectioning—*i. e.*, the lime-salts must first be removed, and that without destroying the cellular elements of the bone. The process of decalcification consists in substituting the acids of the decalcifying fluids for those of the bone salts. As a consequence, new combinations are formed, soluble in water or in an excess of the decalcifying acids themselves.

**157.** The **decalcifying fluids** most frequently used are :

(a) *Hydrochloric acid* (1% aqueous solution), used in quantities amounting to about fifty times the volume of the specimen. The solution is changed daily, and the bone remains immersed until it is soft enough to be cut. This stage is reached when a needle can be introduced with no resistance.

(b) An *aqueous solution of nitric acid* in strengths of 3% to 10%, according to the delicacy of the specimen, and of a specific gravity of 1.4. Instead of water, 70% alcohol may be used as a solvent for the acid. Thoma has recommended for this purpose a solution consisting of 1 vol. nitric acid of a specific gravity of 1.3, and 5 vols. alcohol. This fluid is changed daily and decalcifies small objects in a few days. The specimens are then washed several times in 70% alcohol to remove as much as possible of the acid. 95% alcohol, with the addition of a little precipitated calcium carbonate, has been recommended for washing sections that have been treated by Thoma's method. After from eight to fourteen days the specimens are again washed with clear 95% alcohol.

(c) The process of decalcification recommended by v. Ebner (75) is of considerable value, as it also reveals the fibrillar structure of the bone lamellæ. A cold saturated solution of sodium chlorid is diluted with 2 vols. of water, and 2% of hydrochloric acid added. This fluid decalcifies very slowly, and must either be changed daily or a small quantity of hydrochloric acid occasionally added. As soon as the specimen is thoroughly decalcified, it is washed with a half-saturated solution of sodium chlorid. A little ammonia is now added from time to time until the reaction of the fluid and bone is neutral.

(*d*) Very small pieces that contain very little lime-salts, as, for instance, bones in an embryonal condition where calcification has only just begun, can be deprived of their lime-salts by means of acid fixing solutions like Flemming's fluid, chromic acid, picric acid, etc.

(*e*) Bone should be first fixed in some one of the fixing fluids and then decalcified.

**158.** A method adapted to the study of the hard and soft parts together is that first used by von Koch in studying corals. The specimen is first fixed, and if it be a long bone, the marrow cavity should first be opened to permit the fixing agent to come in contact with all parts of the tissue. After fixing, the bone is stained and then placed in absolute alcohol, and when completely dehydrated the pieces are placed in chloroform, then in a thin solution of Canada balsam in chloroform, and finally put into an oven kept at a temperature of about 50° C. for from three to four months. By this means the pieces are completely penetrated by the Canada balsam, and as the latter becomes very hard on cooling, the sections may be afterward ground without difficulty. Long as this procedure may seem, it is still the one which enables us to see the soft and hard parts of bone in a relationship the least changed by manipulation.

**159.** Sections treated by Ranvier's method (*vid.* T. 154) show the perforating fibers of Sharpey as bright, sharply defined ribbons, appearing as streaks or circles, according to the section made (longitudinal or transverse). If decalcified specimens be first rendered transparent by glacial acetic acid, and then immersed for a minute in a concentrated aqueous solution of indigocarmin, washed with water, and then mounted in glycerin or Canada balsam, the fibers of Sharpey will appear red and the remaining structures blue. Thin sections of bone can be deprived of their organic elements by bringing them for from one-half a minute to a minute into a platinum crucible at a red heat. In such preparations calcified Sharpey's fibers may be seen (Kölliker, 86).

**160.** Virchow's bone corpuscles may be isolated in the following manner: Very thin fragments or discs of bone are immersed for some hours in concentrated nitric acid. They are then placed on a slide and covered with a cover-glass; pressure with a needle upon the latter will isolate the lacunæ, and occasionally also their numerous processes, the canaliculi.

### C. MUSCULAR TISSUE.

Almost all the muscles of vertebrates have their origin from the middle germinal layer. In the simplest type the protoplasm of the formative cell changes into contractile muscle substance, the cell in the meantime undergoing a change in shape (unstriated muscle-cell). In other cases contractile fibrils are formed which are separated by the remains of the undifferentiated protoplasm (striped muscle-cells). In this case the cells either increase very little in length and possess only a single nucleus (heart muscle), or they grow considerably longer and develop many nuclei (voluntary skeletal and skin muscles).

A peculiarity of muscle-substance is that it contracts in only one direction, while undifferentiated protoplasm contracts in all directions.

### 1. NONSTRIATED MUSCLE-CELLS.

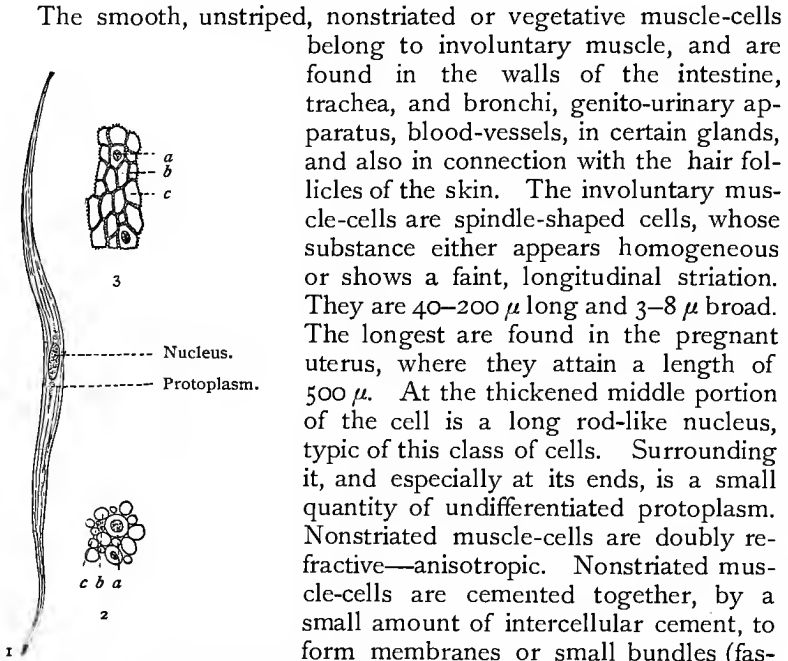


Fig. 88.—Smooth muscle-cells from the intestine of a cat: In 1, isolated; in 2 and 3, in cross-section;  $\times 300$ . Technic No. 172. At *a* the cell is cut in the plane of the nucleus; at *c*, in the neighborhood of the pointed end. In 3 (from Barfurth) is seen the manner in which neighboring cells are joined to each other by intercellular bridges.

The smooth, unstriated, nonstriated or vegetative muscle-cells belong to involuntary muscle, and are found in the walls of the intestine, trachea, and bronchi, genito-urinary apparatus, blood-vessels, in certain glands, and also in connection with the hair follicles of the skin. The involuntary muscle-cells are spindle-shaped cells, whose substance either appears homogeneous or shows a faint, longitudinal striation. They are  $40-200 \mu$  long and  $3-8 \mu$  broad. The longest are found in the pregnant uterus, where they attain a length of  $500 \mu$ . At the thickened middle portion of the cell is a long rod-like nucleus, typic of this class of cells. Surrounding it, and especially at its ends, is a small quantity of undifferentiated protoplasm. Nonstriated muscle-cells are doubly refractive—anisotropic. Nonstriated muscle-cells are cemented together, by a small amount of intercellular cement, to form membranes or small bundles (fasciculi) surrounded by a thin layer of fibrous connective tissue. They are often joined by longitudinal ridges similar to the prickles of epidermal cells. These fit edge to edge and form connecting bridges (Kultschitzky, Barfurth).

### 2. STRIPED MUSCLE-FIBERS.

Soon after the segmentation of the mesoderm begins, certain cells of the mesoblastic somites commence the formation of muscle-substance in their interior, a process which is accompanied by increase in the number of nuclei, the formation of a membrane, a lengthening of the cells, and the appearance of fibrils in the peripheral protoplasm of the cells.

Voluntary or striated muscle-cells are large, highly differentiated, polynuclear cells, which may attain a length of 12 cm., with a width of  $10-100 \mu$ . They are consequently known as muscle-fibers. Their free ends are usually pointed; the ends attached to tendon rounded (Fig. 90).

Each striated muscle-fiber consists of a delicate membrane, the *sarcolemma*, a muscle protoplasm, in which are recognized very fine

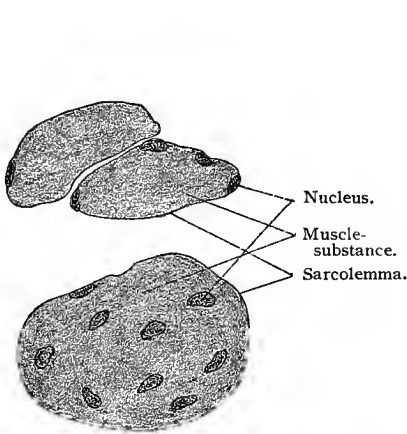


Fig. 89.—Cross-section of striated muscle-fibers : 1, Of man ; 2, of the frog. The relations of the nuclei to the muscle-substance and sarcolemma are clearly visible ;  $\times$  670.




Fig. 90.—Muscle-fiber from one of the ocular muscles of a rabbit, showing its free end ;  $\times$  175.

fibrils and a semifluid interfibrillar substance (the sarcoplasm) and the muscle nuclei. The sarcolemma is a very delicate, transparent, and apparently structureless membrane, which resists strong acetic acid, even after boiling for a long time. If we examine in an indifferent fluid fresh muscle-fibers, the contents of which have been

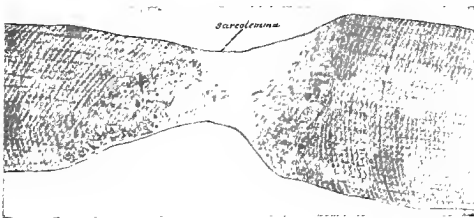


Fig. 91.—Striated muscle-fiber of frog, showing sarcolemma.




Fig. 92.—Diagram of the structure of the fibrils of a striated muscle-fiber. The light spaces between the fibrils may represent the sarcoplasm.

broken without rupturing the sarcolemma, we may see this sheath as a fine glistening line. (Fig. 91.)

The fibrils of the muscle-protoplasm constitute the contractile part of the muscle-fiber. They are exceedingly fine and extend the entire length of the muscle-fiber, and consist of a series of minute, rod-shaped segments with attenuated ends (*sarcous elements*), united by shorter and much thinner thread-like bridges, on each of which there is found a small granule or globule. Their structure may be expressed in the form of a diagram (Fig. 92) giving the view of Rollett, whose account has here been followed.

The ultimate fibrils are grouped into small bundles (0.3–0.5  $\mu$  in diameter), forming the *muscle-columns* of Kölliker. In the muscle-columns the fibrils are so placed that the larger segments fall respectively in the same plane. (See Fig. 92.)

The same disposition of the fibrils prevails in all the numerous muscle-columns forming a muscle-fiber, and all the muscle-columns bear such a relation to each other that the larger segments of the fibrils fall in the same plane. The semifluid, interfibrillar substance, the sarcoplasm, penetrates between the fibrils of the muscle-columns and separates these from each other and from the sarcolemma. In fresh preparations the substance forming the fibrils appears somewhat darker and dimmer, while the sarcoplasm appears clearer. Accordingly, the narrow zone formed by the larger segments of the fibrils appears slightly darker and dimmer than the zones in the regions of the uniting

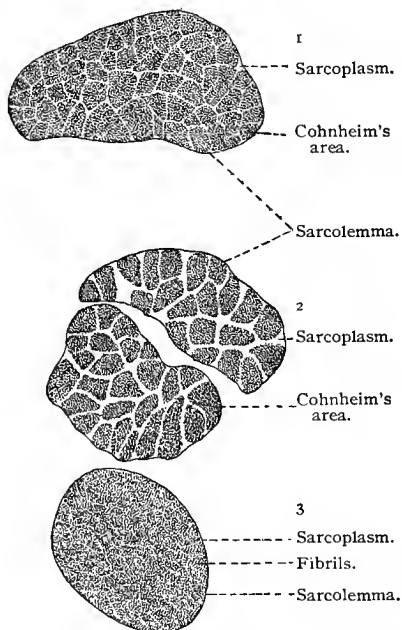


Fig. 93. — Transverse section through striated muscle-fibers of a rabbit. 1 and 3, from a muscle of the lower extremity; 2, from a lingual muscle;  $\times 900$ . Technic No. 163. In 2, Cohnheim's fields are distinct; in 1, less clearly shown; in 3, the muscle-fibrils are more evenly distributed.

bridges, where the sarcoplasm is more abundant (see Fig. 92), giving these zones a clearer appearance. This gives the striated muscle-fibers their characteristic cross-striation. The sarcoplasm is found in greater abundance between the muscle-columns than between the fibrils in the columns. The sarcoplasm between the muscle-columns appears in the form of narrower or broader lines, parallel to the long axis of the muscle-fibers, giving the cross-striated muscle-fiber also a longitudinal striation. The sarcoplasm between the muscle-columns is seen to best advantage in cross-sections

of the muscle-fiber. Here it appears in the form of a network inclosing the muscle-columns. Thus, we have in a cross-section slightly darker areas, the cross-sections of the muscle-columns, known as *Cohnheim's fields* or *areas*, separated by the network of sarcoplasm. (Fig. 93.)

In a striated muscle-fiber the darker and fainter bands (larger segments of the fibrils) are doubly refracting, *anisotropic*, while the clearer bands (sarcoplasm) are singly refracting, *isotropic*. The relative grouping of the two unequally refracting substances is, however, somewhat complicated, a condition which has given rise to much discussion as to the finer structure of the muscle-fiber. It should be remembered that the anisotropic and isotropic substances of the fiber are respectively placed in the same plane, so that the cross-striation of the entire fiber is fairly regular. The thickness of the bands varies considerably, often appearing as fine lines. In a definite segment the grouping is very regular, and the structure of such a segment is exactly repeated throughout the entire length of the fiber. A segment of this description contains in its center a broad disc of anisotropic substance—the *transverse disc* (*Q*) (Fig. 94); this is divided through its middle by a less refractive (isotropic) narrow band, known as the *median disc* of Hensen (*h*). Above and below the transverse disc (*Q*) is a disc of isotropic substance (*J*); these in turn border upon the *intermediate discs* of Krause (*Z*). There are consequently in each segment or *muscle-casket* four discs—the transverse disc (*Q*) divided into two parts by the median disc of Hensen (*h*), with above and below the two isotropic discs (*J*), outside of which lie the intermediate discs of Krause (*Z*).

One of the best objects for the study of transverse striation is the muscle of some of the arthropods (beetles). Here it will be noticed that the disc (*J*) is separated by an anisotropic disc through its center into three: (1) an isotropic disc (*J*); (2) an anisotropic disc (*N*), the "accessory disc" of Engelmann, Krause's "transverse membrane"; and (3) still another disc of anisotropic substance (*E*), Merkel's "terminal disc." In other words, the number of discs in a segmental unit is increased to six: *Q* divided by *h*, two *J*'s, two *E*'s, and *Z*. It should be remarked here that all the doubly refracting substances appear as light,




Fig. 94. — Diagrams of the transverse striation in the muscle of an arthropod; to the right with the objective above, to the left with the objective below its normal focal distance (after Rollett, 85): *Q*, Transverse disc; *h*, median disc (Hensen); *E*, terminal disc (Merkel); *N*, accessory disc (Engelmann); *J*, isotropic substance.

and the singly refracting as dark, bands when the objective is raised just a trifle above its focal distance. The contrary is the case on lowering the objective to a point just below its focal distance. (Fig. 94.)

In figure 95 is shown a portion of a striated muscle-fiber of man very highly magnified. The larger and darker transverse disc ( $Q$ ) formed by the larger segments of fibrils is divided by a light line ( $h$ ), Hensen's median disc; the clearer band, largely sarcoplasm, is divided by a dark line, the intermediate disc of Krause; this falls in the plane of the granules on the fine bridges uniting the larger segments of the fibrils.

After a prolonged treatment with 98% alcohol the muscle-fibers of the water beetle (*Hydrophilus piceus*) can be made to separate into transverse discs (Rollet, 85). One of these discs would correspond to the segment  $Q$ , and it is very probable that this is the portion which has long been known under the name of Bow-




Fig. 95.—From a striated muscle of man; obtained by teasing;  $\times 1200$ . Technic No. 166:  $h$ , A median disc lying in the transverse disc  $Q$ ;  $z$ , the intermediate disc borders above and below on the light isotropic discs.

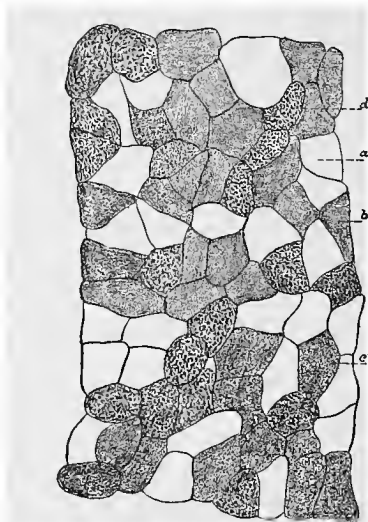


Fig. 96.—From a cross-section through the trapezius muscle of man, showing dark fibers rich in protoplasm, and light fibers containing very little protoplasm (after Schaffer, 93, II):  $d$ , Dark fibers;  $a$ , light fibers;  $b$  and  $c$ , transitional fibers from light to dark.

man's disc. Other reagents, as weak chromic acid, cause a separation of the muscle-substance into longitudinal fibrils. In this case the discs  $Q$  are split up longitudinally into a number of very small columns which were at one time regarded as the primary elements of the fiber and termed by Bowman *sarcous elements*.

In adult skeletal and skin muscle-fibers of mammalia the positions of the nuclei vary. There are muscles in which the nuclei are imbedded in the sarcoplasm between the muscle-columns (so-called red muscles, as the semitendinosus of the rabbit); in other muscles they lie immediately beneath the sarcolemma (white muscles, as the semimembranosus of the rabbit; Ranvier, 89). In the striated mus-

cle-fibers of the lower vertebrates and of mammalian embryos the nuclei lie between the fibrillæ, or muscle-columns. The red muscle-fibers are rich in sarcoplasm, and the fibrils are grouped in well-marked and large muscle-columns surrounded by sarcoplasm which often contains granules of various sizes, the *interstitial granules* of Kölliker, often especially abundant at the poles of the nuclei. The white muscle-fibers have a relatively small quantity of sarcoplasm. In cross-sections of the light fibers the fibrils show as fine points, not distinctly grouped, and surrounded by the homogeneous sarcoplasm. Both varieties occur in almost every human muscle, and the relative number of each varies greatly in the different muscles (Schaffer, 93, II, Fig. 96).

Muscles with transversely striated fibers are, with the exception of those of the heart, subject to the will of the individual, and are characterized by a rapid contraction in which the anisotropic substance increases in size at the cost of the isotropic discs; the former appears to play the chief rôle. Besides morphologic differences, the red and white muscle-fibers appear to possess differences of a physiologic character, in that the contraction in the red

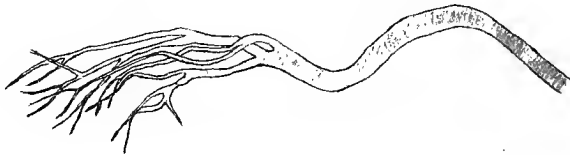


Fig. 97.—Branched, striated muscle-fiber from the tongue of a frog.

variety is slower than that in the white (Ranvier, 80). Only the striated muscles of the esophagus, the external cremaster, and a few others, as well as the somewhat differently constructed muscles of the heart, are involuntary.

Transversely striated muscle-fibers are usually unbranched. The muscle-fibers of the tongue and of the ocular muscles do, however, show occasionally communicating branches; the same are but very rarely seen in other muscles. In regions where striated muscle-fibers terminate under the epithelium, as in the tongue and in the skin of the face, the end of the fiber terminating under the epithelium is often very much branched; the cross-striation and nuclei may be observed in the finest branches. (Fig. 97.)

Each muscle-fiber is surrounded by a thin connective-tissue envelope, the *endomysium*, which binds them into primary and secondary bundles, the muscle-fasciculi. These are surrounded by a denser sheath of similar character, the *perimysium*. The muscle is made up of numerous fasciculi, all bound together by a thicker connective-tissue covering, the *epimysium*. (Fig 98.)

Blood-vessels are very numerous in transversely striated mus-




Fig. 98.—Cross-section of rectus abdominis of child, as seen under low magnification.

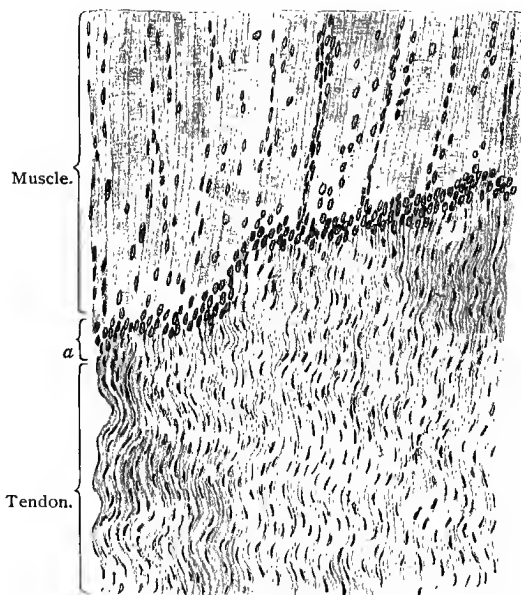


Fig. 99.—Part of a longitudinal section through the line of junction between muscle and tendon;  $\times 150$ . At the line where the tendon-fibrils join the sarcolemma (*a*), the nuclei of the muscle are very numerous. Sublimite preparation.

cular tissue. They form a capillary network with elongated meshes, the cross-branches of which sometimes show swellings in the red muscles (Ranvier, 80). The smallest veins are relatively large and possess numerous valves.

At its junction with tendon the muscle-fiber with its sarcolemma is rounded off into a blunt point, the fibrils of the tendon being cemented to the sarcolemma.

The longitudinal growth of muscle-fibers takes place principally at the distal ends of the fibers, at which point their nuclei are numerous. (Fig. 99, at *a*.) Schaffer (93, II) has recently suggested that there is a formative tissue between the tendon and muscle-substance, from which, on the one hand, muscle-fibers are developed, and, on the other hand, connective-tissue fibrils and cells are formed.

As recent investigations have shown, the development of muscle continues throughout the life of the individual. Muscular tissue is

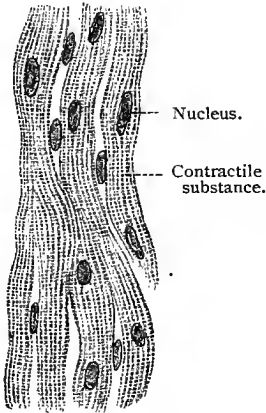


Fig. 100.

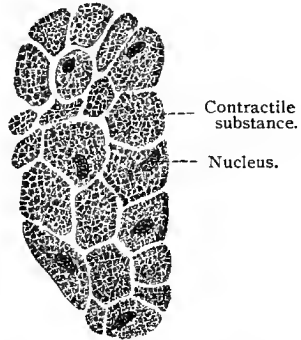


Fig. 101.

Longitudinal and cross-section of muscle-fibers from the human myocardium, hardened in alcohol;  $\times 640$ . The muscle-cells in the longitudinal section are not sharply defined from each other, and appear as polynuclear fibers blending with each other. Between them lie, here and there, connective-tissue nuclei.

consequently to be regarded as in a perpetual stage of transition, the destruction and compensatory reproduction of its elements going on hand in hand. Its destruction is ushered in by a process which can be compared to a physiologic contraction. Nodes or thickened rings are formed, and at these points the muscle-substance separates into fragments with or without nuclei (sarcolytes), which are then absorbed, in most cases without phagocytic aid. This loss of substance is replaced by new elements developed from the free sarcoplasm, which is characterized by rapid growth and increase in the number of its nuclei. The result is that new elements are formed which have been called *myoblasts*. The process by which myoblasts are changed into the finished muscle-fibers is exemplified in the embryonal type of development of the tissue.

### CARDIAC MUSCLE-CELLS.

The muscle-cells of the heart differ in structure from the ordinary type of transversely striated muscle-fibers. The heart muscle-cells are short, irregularly oblong cells, often branched, possess no sarcolemma, and have one, occasionally two, centrally placed nuclei. In the smaller muscle-cells a cross-section often shows an arrangement of the fibrils radiating from the axis. The heart muscle-cells are cemented end to end to form anastomosing heart muscle-fibers; these are arranged in bundles or in the form of a network.

The muscle-cells of the so-called *fibers of Purkinje* lie immediately beneath the endocardium, and are remarkable in that their protoplasm is only partially formed of transversely striated substance, and that only at their periphery. Such cells are found in great numbers in some animals (sheep), but rarely in man. Heart muscle has a rich blood supply, which will be considered more fully when the heart is discussed as an organ.

For the nerve-endings in smooth and striated muscle-fibers see the chapter on Nervous Tissues.

### TECHNIC.

**161.** Fresh, striated muscle-fibers may be isolated by teasing them in an indifferent fluid (*vid.* T. 13). After a short time the sarcolemma may separate as a very fine membrane. If a freshly teased muscle be placed in a cold saturated solution of ammonium carbonate, the sarcolemma will become detached in places within five minutes (Solger, 89, III).

**162.** Striated muscle-fibers may be examined in an extended condition by placing an extremity in such a position as to stretch certain groups of muscles. A subcutaneous injection of 0.25–0.5 c.c. of a 1% osmic acid solution is then made. The acid penetrates between the fibers and fixes them. Pieces of muscle are then cut out and washed in distilled water. Teased fibers, even if not stained, will show the striation plainly if mounted in glycerin. Muscles thrown into a state of tetanic contraction by electric stimulation may also be fixed in this state and later examined.

**163.** Cross-sections of muscles, extended and fixed in osmic acid, also show the relation of the fibrils to the sarcoplasm (Cohnheim's fields). A remarkable quantity of sarcoplasm in proportion to the number of fibrils is seen, for instance, in the muscles which move the dorsal fin of hippocampus; among the mammalia a similar condition is found in the pectoral muscles of the bat (Rollett, 89).

**164.** In the muscles of all adult vertebrates (except the mammalia) the nuclei lie between the fibrils. In young mammalia they also have this position, but in the adult animals only the nuclei of red muscles are found between the fibrillæ; in all other muscles the nuclei are under the sarcolemma.

**165.** The fibrillar structure of muscle-fibers can be seen by teasing old alcoholic preparations, or tissue treated with weak chromic acid (0.1%) or one of its salts.

166. In alcoholic preparations of mammalian muscle, the cross-striation is clearly seen, and is intensified by staining with hematoxylin. This stain colors everything anisotropic in the muscle, but does not affect the remaining structures. Similar results may be obtained with other stains, such as basic anilin dyes, but not with the same precision as with hematoxylin.

167. A certain species of beetle (*Hydrophilus*) is admirably adapted for the study of the finer details of striation. The beetle is first wiped dry and then immersed alive in 93% alcohol. On examining in dilute glycerin after from twenty-four to forty-eight hours, the substance of its muscles will show disintegration into Bowman's discs (*vid.* p. 128). The latter swell up in acids and are finally dissolved, as may be seen, by adding a drop of formic acid to a specimen prepared as above (Rollet, 85).

168. In order to study the relation of muscle to tendon, small muscles with their tendons are put into a 35% potassium hydrate solution for a quarter of an hour, after which the specimen is placed upon a slide and teased at the line of junction of the two tissues. This will separate the muscle-fibers from their respective tendon-fibrils (Weismann).

169. Similar results may be obtained by immersing a frog in water at a temperature of 55° C., in which the animal soon dies with muscles perfectly rigid. As soon as the water begins to cool (one-quarter hour) the frog is removed and a small piece of its muscle cut out and teased in water on a slide (Ranvier).

170. Cardiac muscle-cells are isolated by maceration for twenty-four hours in a 20% solution of fuming nitric acid (potassium hydrate with a specific gravity of 1.3 will do the same in one-half or one hour). The margins of the cells may be brought more clearly into view by placing pieces of heart muscle for twenty-four hours in a 0.5% aqueous solution of silver nitrate and then cutting into sections.

171. Isolated fibers of Purkinje are obtained by immersing pieces of endocardium (0.5 mm. in size) in 33% alcohol and then teasing them on a slide. The sheep's heart is especially well adapted for this purpose.

172. Nonstriated muscle-fibers are isolated in the same way as heart muscle. In thin cross-sections (under 5  $\mu$  in thickness) of intestinal muscle, preferably of a cat, fixed in osmic acid, the intercellular bridges may be seen here and there between the fibers.

## D. THE NERVOUS TISSUES.

The entire nervous system, peripheral as well as central, is composed of cells possessing one or many processes. These cells develop early in embryonic life from certain ectodermal cells (*neuroblasts*) of the neural canal, which is formed by a dorsal invagination of the ectoderm. The neuroblasts soon develop processes,—many of them *in loco*, others only after wandering from the neural canal.

The processes of the nerve-cells are of two kinds: (1) unbranched processes having a nearly uniform diameter throughout,

with lateral offshoots known as collateral branches ; these, as we shall see, generally form the central part of a nerve-fiber, and are known as *neuraxes* (Deiters' processes, axis-cylinder processes, neurites, neuraxones or axones); and (2) processes which branch soon after leaving the cell-body and break up into many smaller branches ; these are the *dendrites*, or protoplasmic branches. In the spinal ganglia and the homologous cranial ganglia these morphologic differences in the processes are not observed, the neuraxis and the dendrites of each presenting essentially the same structure.

To the entire nerve-cell, cell-body and processes the term *neurone* (Waldeyer, 91) has been applied ; *neura* (Rauber), or neurodendron (Kölliker, 93).

The neuraxes of many neurones attain great length. Those of some of the neurones, the cell-bodies of which are situated in the lower part of the spinal cord, extend to the foot. In other regions neuraxes nearly as long are to be found, and in the majority of neurones the neuraxes terminate some distance from the cell-body. It is therefore manifestly impossible in the majority of cases to see a neurone in its entirety. Usually, only a portion of one can be studied in any one preparation. Consequently, the more detailed description which follows will deal with the neurone in this fragmentary manner. The cell-bodies of the neurones, to which the term "nerve-cells" or "ganglion cells" is usually restricted, the dendrites and neuraxes, often forming parts of nerve-fibers, and their mode of terminating, will receive separate consideration.

#### NERVE-CELLS, OR GANGLION CELLS ; THE CELL-BODIES OF NEURONES.

The cell-bodies of nerve-cells are usually large. The bodies of the motor neurones of the human spinal cord measure 75 to 150  $\mu$ , their nuclei 45  $\mu$ , and their nucleoli 15  $\mu$ . The smallest nerve-cells, the neurones of the granular layer of the cerebellum, are 4 to 9  $\mu$  in diameter. The protoplasm of nerve-cells shows a distinct fibrillar structure and the fibrils may be followed into the processes. (Fig. 102.) Their nuclei are also large, with very little chromatin, but as a rule are supplied with a large nucleolus.

After treatment by certain special methods, the protoplasm of the ganglion cells shows granules or groups of granules which show special affinity to certain stains, consequently known as chromatophile granules ; these are densely grouped around the nucleus, so that the cell-body shows an inner darker and an outer lighter portion. These chromatophile granules, also spoken of as *tigroid* granules or as the *tigroid* substance, as a rule are not arranged in concentric layers, but lie mostly in groups, giving to the protoplasm a mottled or reticular appearance. In the cells of the anterior horns (man, ox, rabbit) the granules join to form flakes, which are also more numerous in the region of the nucleus. In all cases the

granules or flakes are continued into the dendrites of the cell. Here they change their shape into long pointed rods, with here and there nodules, which are probably the chief causes of the varicosities so often seen in dendrites (Golgi's method). The cell usually has a clear, nongranular peripheral border (not a membrane), and in the case of large cells there is a similar area around the nucleus, the inner border of which belongs to the nuclear membrane. H. Held has found that the chromatophile granules are brought out by treatment with alcohol and acid fixing fluids, but not in alkaline or neutral. They appear, according to the treatment, as fine or coarse granules. They can not be seen in fresh nerve-cells. He consequently regards them as artefacts—precipitations of the protoplasm due to reagents (*vid.* A. Fischer, T. 124). At its junction with the cell the neuraxis spreads out into a cone which is entirely free from granules, and apparently fitted into a depression in the granular substance of the cell (implantation cone).

The cellular substance between the chromatophile granules consists also of very fine, highly refractive granules, which appear to be arranged in a reticulum surrounding the chromatophile granules

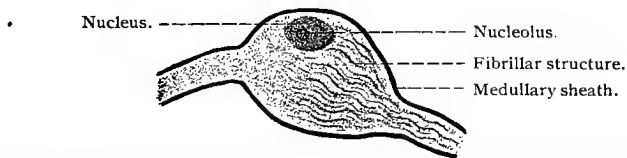


Fig. 102.—Bipolar ganglion cell from the ganglion acousticum of a teleost (longitudinal section). The medullary sheath of the neuraxis and dendrite is continued over the ganglion cell;  $\times 800$ . Technic No. 175.

(*vid.* Nissl, 94, and v. Lenhossék, 95), and the recent observations of Apáthy and Bethe make it very probable that in the intergranular substance of the protoplasm of the nerve-cell there exist very fine fibrils which may be traced into the processes of the cell. It requires, however, further observation before more positive statements may be made concerning them.

Besides the granules above mentioned, and which are revealed by special methods, there are found in the protoplasm of many of the larger nerve-cells pigment granules of a yellow or brown color which stain black with osmic acid.

The *dendrites* are usually relatively thick at their origin, but gradually, as a result of repeated divisions, taper until their widely distributed arborescent endings appear as minute threads of widely different shapes. When treated by certain methods, they present uneven surfaces studded with varicosities and nodules, in contradistinction to the neuraxes, which are smooth and straight. Their terminal branches end either in points or in small terminal thickenings. The groups of terminal end-branches of a dendrite (also of a neuraxis) are known as *telodendria* (Raubert), or end-branches. The

branches of the dendrites form a dense feltwork, which, together with the cell-bodies of the neurones and with other elements to be described later, constitute the gray substance (gray matter) of the brain and spinal cord.

All neurones, with possibly a few exceptions, possess only a single neuraxis. Neurones without a neuraxis have never been found in vertebrates. The neuraxis usually arises from a cone-shaped extension of the cell-body free from chromatophile granules, the implantation cone, more rarely from the base of one of its dendrites, or from a dendrite at some distance from the cell-body. Its most important characteristics are its smooth and regular contour and its uniform diameter. At some distance from the cell-body, usually near its termination, now and then in its course, a neuraxis may divide into two equal parts. Golgi (94) called attention to the fact that the neuraxes of certain neurones (Purkinje's cells in the cerebellum, pyramidal cells of the cerebral cortex, and certain cells of the spinal cord) give off lateral processes, the collateral branches.

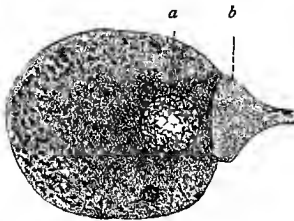


Fig. 103.—Chromatophile granules of a ganglion cell from the Gasserian ganglion of a teleost: *a*, Nucleus; *b*, implantation cone.

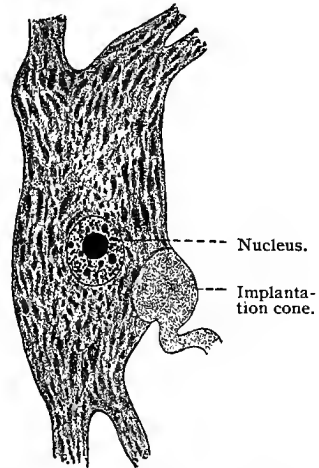


Fig. 104.—Nerve-cell from the anterior horn of the spinal cord of an ox, showing coarse chromatophile flakes.

Two types of cell are recognized according to the disposition of their neuraxes: In the first the neuraxis is continued as a nerve-fiber; in the second and rarer type it does not long preserve its independence, nor is it continued as a nerve-fiber, but soon breaks up into a complicated arborization, the *neuropodia* of Kölliker (93). The latter type of cell occurs in the cortex of the cerebrum and cerebellum and in the gray matter of the spinal cord. The cells of the two types can be simply described as having long (type I) or short, branched neuraxes (type II). The neuraxes of the cells of type I possess the collateral branches which end in small branching tufts.

In its simplest form, a neurone consists of a cell-body and a neuraxis with its telodendrion. In more complicated types one or several

dendrites may be present, as also collaterals from the neuraxis, and in rare cases even several neuraxes. According to the number of its processes, a ganglion cell is known as unipolar, bipolar, or multipolar.

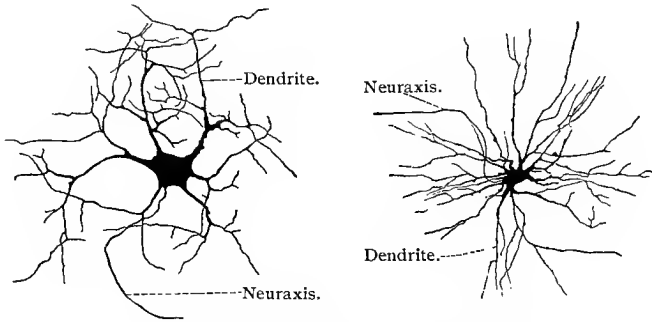


Fig. 105.—Motor neurones from the anterior horn of the spinal cord of a new-born cat. Chrome-silver method.

Although neurones present a great variety of morphologic differences,—large and variously shaped cell-bodies or small ones scarcely larger than the nucleus; large and numerous dendrites or

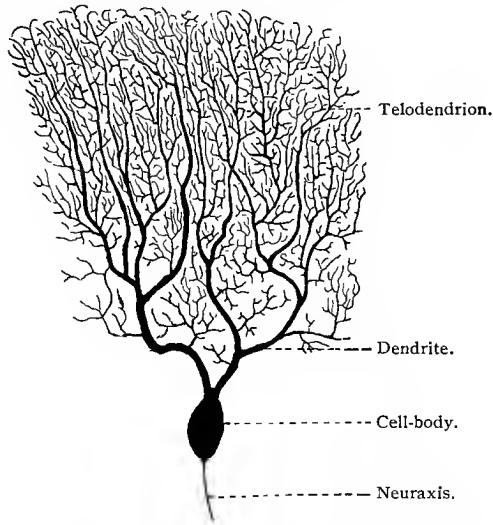


Fig. 106.—A nerve-cell with branched dendrites (Purkinje's cell), from the cerebellar cortex of a rabbit; chrome-silver method;  $\times 125$ .

few and less conspicuous ones,—and although these various forms are widely distributed and intermingled in the different parts of the nervous system, yet in many regions there are found nerve-cells of fixed and characteristic morphologic appearance, which would

enable a determination of their source. A few of the most characteristic types are here figured and may receive brief consideration. In the anterior horn of the spinal cord are found large multipolar neurones (motor neurones), with numerous dendrites, which terminate after repeated branching in the neighborhood of the cell-body, while the neuraxis with its collateral branches proceeds from the cell-body and becomes a part of a nerve-fiber. (Fig. 105.)

In the cerebellum are found large neurones, discovered by Purkinje, and known as Purkinje's cells, with flask-shaped cell-body, from the lower portion of which arises a neuraxis with collateral branches,

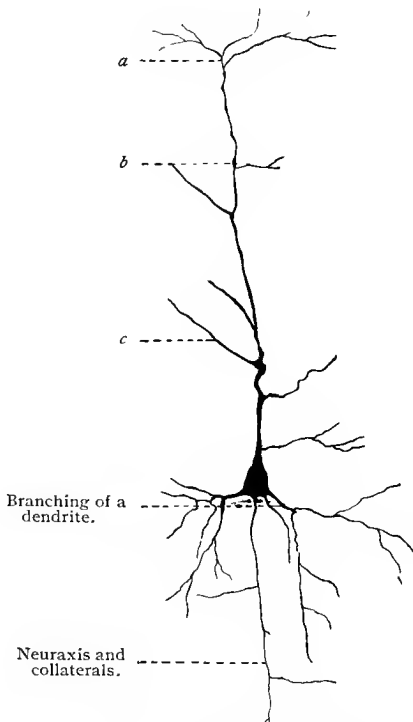


Fig. 107.—Pyramidal cell from the cerebral cortex of man; chrome-silver method :  
*a, b, c*, Branches of a dendrite.

from the upper portion one or two very large and typical dendrites the smaller branches of which are beset with irregular granules. (Fig. 106.)

In the cortex of the cerebrum occur large neurones, each with a cell-body the shape of a pyramid (pyramidal cell of the cerebral cortex), from the apex of which arises one large dendrite, and from angles at the base, or from the sides of the cell-body, several smaller dendrites. The neuraxis arises from the base directly or from one of the basal dendrites. (Fig. 107.)

In figure 108 is shown a neurone with relatively small cell-body and short dendrites, from the granular layer of the human cerebellum.

The function of the dendrites has given rise to considerable discussion. Golgi and his school regard them as the nutrient roots of the cell, a theory which is opposed by Ramon y Cajal (93, I), van Gehuchten (93, I), and Retzius (92, II). According to the latter, all the processes of the nerve-cell are analogous structures; they pass out from a sensitive element, and probably have a correspondingly uniform function.

In the spinal ganglia and the homologous cranial ganglia, are grouped the cell-bodies of neurones (peripheral sensory neurones, peripheral centripetal neurones) which differ in many respects from those above described. In the peripheral sensory neurones the

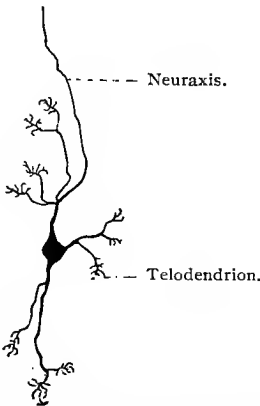


Fig. 108.—Nerve-cell with dendrites ending in claw-like telodendria; from the granular layer of the human cerebellum; chrome-silver method;  $\times 110$ .

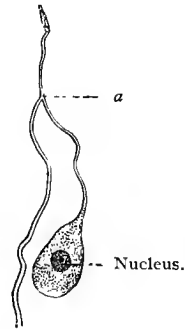


Fig. 109.—Ganglion cell with a process dividing at *a* (T-shaped process); from a spinal ganglion of the frog;  $\times 230$ . Technic No. 178.

neuraxes and dendrites have essentially the same structure, both forming part of a nerve-fiber. From a relatively large, nearly round, oval, or pear-shaped cell-body there arises a single process, which, at a variable distance from the cell-body, divides into two branches forming a right or obtuse angle with the single process (T-shaped or Y-shaped division of Ranvier, 78). Both of these branches form the central axis of a nerve-fiber; one of the branches passing as a nerve-fiber to the spinal cord or brain, as the case may be; the other forming a nerve-fiber which passes to the periphery. (Figs. 109 and 110.)

The ganglion cells of the spinal ganglia and homodynamic structures of the brain are therefore apparently unipolar cells, but, as Ranvier has shown, their processes are subject to a T-shaped or Y-shaped division. The branches going to the periphery are re-

garded as dendrites, the others as neuraxes. As to the significance to be attached to the single process, the theory of v. Lenhossék

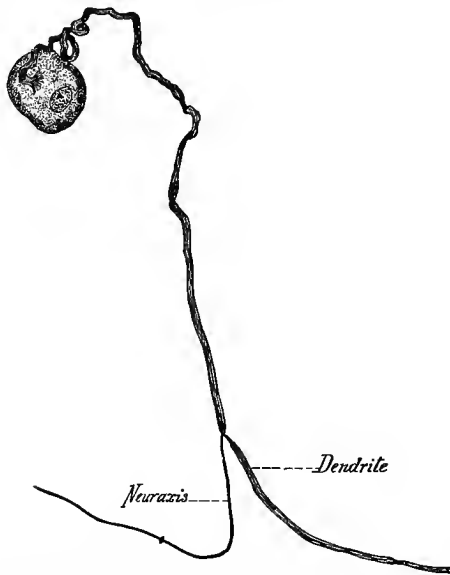


Fig. 110.—Ganglion cell from the Gasserian ganglion of a rabbit ; stained in methylene-blue (*intra vitam*).

(94, I) that it represents an elongated portion of the cell, and that therefore the origin of the dendrite and that of the neuraxis are in this case close together, is very plausible. In the embryo these ganglion cells are at first bipolar, a process arising from each end of a spindle-shaped cell ; as development proceeds, the two processes approach each other and ultimately arise from a drawn-out portion of the cell-body, the single process. (Fig. 111.)

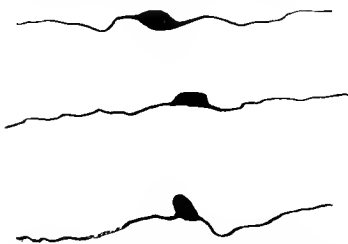


Fig. 111.—Three ganglion cells from a spinal ganglion of a rabbit embryo. The cells are still bipolar. Their processes come together in later stages, and finally form the T-shaped structure seen in the adult animal ; chrome-silver method ;  $\times 170$ .

The sympathetic ganglia are composed mainly of the cell-bodies and dendrites (also some structures to be mentioned later) of neurones of the sympathetic nervous system. In nearly all vertebrates, and with but few exceptions in any one ganglion, these neurones are multipolar and resemble morphologically the

multipolar ganglion cells of the anterior horn of the spinal cord, though they are somewhat smaller. In the cell-body there may be ob-

served fine chromatophile granules and a large nucleus and nucleolus. From the cell-body there proceed a varying number of dendrites which branch and rebranch and terminate, as a rule, near the cell-body, forming plexuses in the ganglia. The neuraxis arises either directly from the cell-body from an implantation cone, or from one of the dendrites at a variable distance from the cell-body. (Fig. 112.) In nearly all ganglia a few unipolar or bipolar cells are to be found. In the sympathetic nervous system of amphibia the sympathetic neurones are unipolar; the single process present is the neuraxis.

A most important result of the more recent investigations on the nervous system is the theory of the independence of the neurone. Each neurone develops from a single cell (neuroblast), and functions as an independent cell under physiologic and pathologic conditions. Only very rarely has any direct connection between two neighboring neurones been demonstrated, so rarely that the

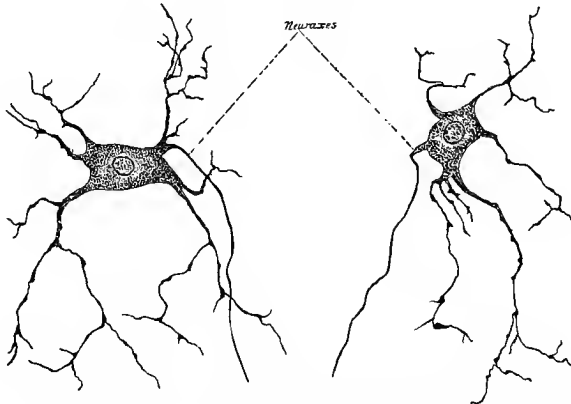


Fig. 112.—Neurone from inferior cervical sympathetic ganglion of a rabbit; methylene-blue stain.

scattered observations at hand do not vitiate the above statement. Recent investigations have, however, shown that, while a neurone is a distinct anatomic unit, it is always found associated with other neurones. Nowhere in the body of a vertebrate does one find a neurone completely disconnected from other neurones. This association of one neurone with one or several other neurones is always effected by a close contiguity existing between the telodendria (end-branches) of the neuraxis of one neurone with the cell-body or dendrites of one or several other neurones. The telodendrion of the neuraxis of one neurone may form a feltwork inclosing the cell-body of one or several neurones, forming structures known as terminal baskets or end-baskets, or the end ramifications of the neuraxis of a neurone may come in very close proximity to the end-branches of the dendrites of one or several neurones. By this contiguity of the telodendria of the neuraxis of one neurone with

the cell-bodies or the dendrites of other neurones, they are, without losing their identity, linked into chains, so that a physiologic continuity exists between them. In such neurone chains the dendrites are regarded as cellulipetal, transmitting the stimulus to the cell; the neuraxes as cellulifugal, transmitting the impulse imparted by the cell to the motor nerve-endings or central organs (Kölliker, 93). The entire nervous system may therefore be said to be made up of such neurone chains, the complexity of which varies greatly according to the number of neurones which enter into their construction. This subject will be considered more fully in a chapter on the nervous system.

### THE NERVE-FIBERS.

The neuraxes of the cells of type I, and the dendrites of the peripheral sensory neurones (spinal ganglia and homologous cranial ganglia), form the chief element in all the nerve-fibers. In the nerve-fibers they possess a distinctly fibrillar structure. The fibrils composing them, the *axis-fibrils*, are imbedded in a semifluid substance, the *neuroplasm* (Kupffer, 83, II) the whole being surrounded by a very delicate membrane, the *axolemma*. In the nerve-fibers, the axis-fibrils and the neuroplasm form *axial cords* which are surrounded by a special membrane or membranes, the presence or absence of which serves as a basis for a classification of nerve-fibers. Two kinds are distinguished, medullated and nonmedullated nerve-fibers.

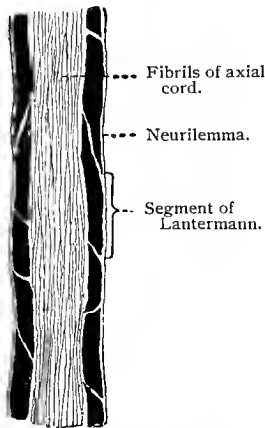


Fig. 113.—Longitudinal section through a nerve-fiber from the sciatic nerve of a frog;  $\times 830$ . Technic No. 175.

In medullated nerve-fibers, the axial cords (neuraxes of cells of type I, and dendrites of spinal ganglion cells) are surrounded by a highly refractive substance very similar to fat, which is blackened in osmic acid, the so-called *medullary* or *myelin sheath*. In a fresh condition this sheath is homogeneous, but soon changes and presents segments separated from each other by clear fissures. These segments vary in size and are known as "Schmidt-Lanternmann-Kuhnt's segments." On boiling in ether or alcohol the entire medullary sheath of a nerve-fiber does not dissolve, but a portion is left in the shape of a fine network which is not affected by exposure to the action of trypsin. From the latter circumstance it has been thought that this network consists of a substance very similar to horn, and is therefore known as *neurokeratin* (horn-sheath, Ewald and Kühne). On burning isolated neurokeratin, an odor exactly like that of burn-

ing horn is given off. It is thought that the meshes of this neurokeratin network contain the highly refractive substance similar to fat, composing the greater portion of the medullary sheath. The medullary sheath is interrupted at intervals of from 80 to 900  $\mu$ , the constrictions thus formed being known as the *nodes of Ranvier*. The smaller the fiber, the less the distance between the nodes. In a fiber with a diameter of 2  $\mu$  the internodal segments are usually about 90  $\mu$  in length.

In peripheral nerves the medullary sheath is in its turn surrounded by a clear, structureless membrane, the *neurilemma* or sheath of Schwann. Nerve-fibers contain here and there relatively long, oval nuclei (neurilemma-nuclei) which are surrounded by a small quantity of protoplasm, and are situated in small excavations between the neurilemma and the medullary sheath. In the higher vertebrates a single nucleus is found midway between each two

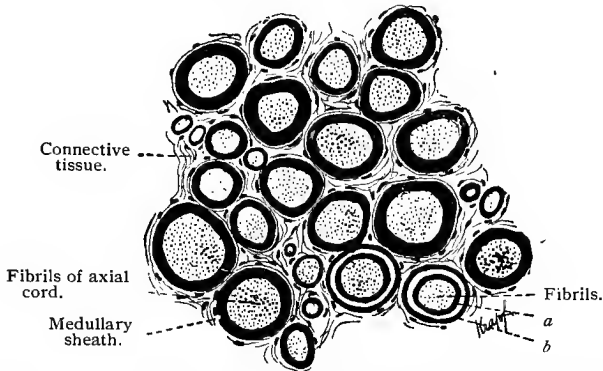


Fig. 114.—Transverse section through the sciatic nerve of a frog;  $\times 820$ . Technic No. 175: At *a* and *b* is a diagonal fissure between two *Lantermann's* segments; as a result, the medullary sheath here appears double. (Compare Fig. 113.)

nodes; in the lower vertebrates (fishes) several scattered nuclei (5–16) may be found in each internodal segment. At the nodes, where the medullary sheath is interrupted, the neurilemma is thickened and contracted down to the axial cord (contraction-ring).

Just beneath the contraction-ring, *Ranvier* found that the axis-cylinder presents a slight, biconic swelling (*renflement bicôniqne*). Thus the sheath of Schwann represents a continuous tube throughout the length of the fiber in contrast to the medullary sheath. In the nerve-fibers of the spinal cord and brain there is no neurilemma, although the medullary sheath is present.

In the fresh nerve-fiber the axial cord fills the space (axial space) within the medullary sheath, and appears transparent. After treatment with many fixing fluids the neuroplasm coagulates and shrinks, no longer filling the entire axial space, but appears in the latter as a wavy cord composed of an apparently homogeneous

mass, the fibrillæ of which are no longer recognizable. Such pictures, which formerly were supposed to represent the normal condition of the nerve-fibers, gave rise to the conception of an *axis-cylinder* (*vid.* Technic). That which is known as an axis-cylinder is therefore, in reality, the changed contents of the axial space. It may be stated, however, that the term axis-cylinder is still much used, since the methods commonly employed in the investigation of the

nervous system do not preserve the axial cord in its integrity, but nearly always result in the formation of an *axis-cylinder*. Consequently, although we shall make use of the term, its limitations are to be kept in mind.

Medullated nerve fibers vary greatly in di-

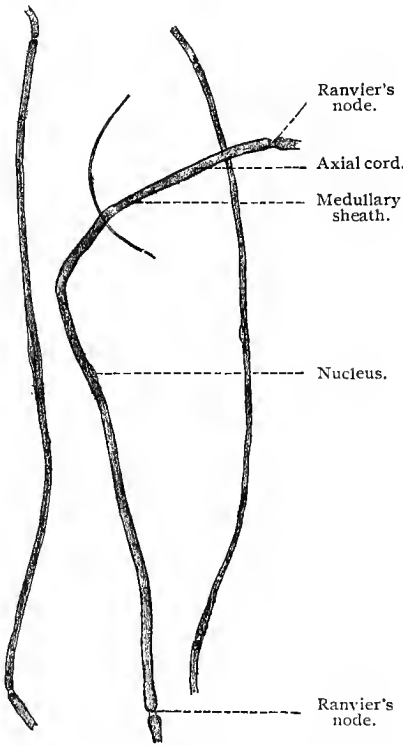


Fig. 115.—Medullated nerve-fibers from a rabbit, varying in thickness and showing internodal segments of different lengths. In the fiber at the left the neurilemma has become slightly separated from the underlying structures in the region of the nucleus;  $\times 140$ . Technic No. 173.

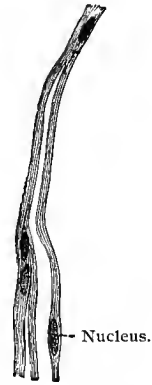

Fig. 116.—Remak's fibers (nonmedullated fibers) from the pneumogastric nerve of a rabbit;  $\times 360$ . Technic No. 179.

ameter, but whether this points to a corresponding variation in function has not been fully decided. Fine fibers possess a diameter of  $2-4 \mu$ , those of medium size  $4-9 \mu$ , and large fibers  $9-20 \mu$  (Kölliker, 93). A division of medullated fibers during their course through a nerve is relatively rare. The greater number of fibers pass unbranched from their central origin to the periphery, and only when in the neighborhood of their terminal arborization do they begin to divide. A point of division is always marked by a node of Ranvier.

The segmental structure of nerve-fibers would seem to give the impression that they are formed by a number of cells fused end to end. After what has been said with regard to ganglion cells and their processes, this can be the case only so far as the nerve-sheaths are concerned. According to this theory, the formative cells of the latter gather in chains along the neuraxes or dendrites, forming a mantle around them, and in the adult nerve-fibers taking the shape of the segments or internodes just described (His, 87 ; Boveri, 85). The points at which the sheath-cells are joined would then correspond to the nodes of Ranvier. Other investigators have concluded that the whole nerve-fiber is developed from a terminal apposition of ectodermal cells. In this case not only the sheaths of the fibers but also the corresponding portions of the nerve processes are formed by them (Kupffer, 90). In both theories the neurilemma corresponds to the cell-membrane ; in the former the neurilemma nucleus corresponds to that of the sheath-forming cell, in the latter to that of the formative cell of the whole nerve segment. It should be noticed that, according to the second theory, a fiber segment is the product of a single cell, while according to the first it is evolved from at least two cells (ganglion cell (process) and sheath-forming cell). The former theory is now very generally accepted.

The **nonmedullated** nerve-fibers, *Remak's fibers*, possess no medullary sheath ; the axial cord shows nuclei which can be regarded as belonging to a thin neurilemma. The majority of the neuraxes of the neurones of the sympathetic nervous system are of this structure, although small medullated nerve-fibers (the neuraxes of sympathetic neurones) are found in certain regions.

All nerve-fibers, medullated as well as nonmedullated, in the central and peripheral nervous system, lose the sheaths here described before terminating ; the axis-cylinders (axial cords) ending without special covering (naked axis-cylinders). These terminal branches are, in fixed and stained preparations, beset with small thickenings—varicosities—which vary greatly in size and shape. Nerve-fibers presenting such appearances are spoken of as varicose fibers. The varicose enlargements may be regarded as small masses of neuroplasm ; the fine uniting threads, as representing the axial fibrils.

In the peripheral nervous system the nerve-fibers are grouped to form nerve-trunks. The nerve-fibers, as has been stated and as will be seen from the diagram (Fig. 117) on the next page, are the neuraxes of neurones, the cell-bodies of which are situated in the spinal cord or brain and in the sympathetic ganglia, and the dendrites of peripheral sensory neurones, the cell-bodies of which are found in the spinal and homologous cranial ganglia.

In the nerve-trunks the nerve-fibers are gathered into bundles termed *funiculi*. The nerve-fibers constituting such a bundle are separated by a small amount of fibro-elastic tissue, containing here and there connective-tissue cells, the *endoneurium*. This is continu-

ous with a dense, lamellated fibrous sheath surrounding each funiculus, the *perineurium*. Between the lamellæ of this sheath are lymph-spaces, communicating with the lymph-clefts found between the

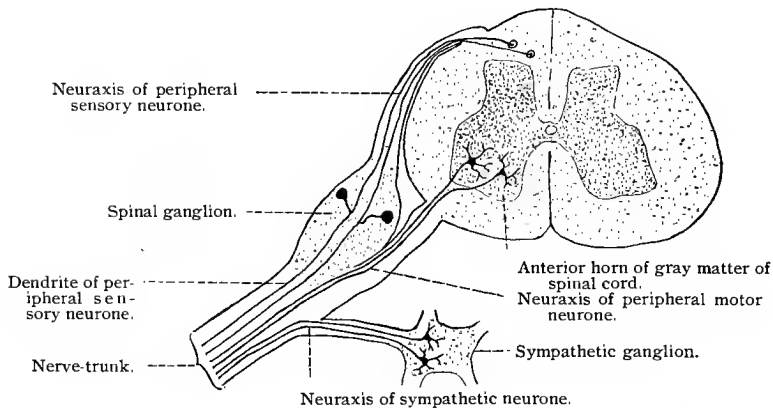


Fig. 117.—Diagram to show the composition of a peripheral nerve-trunk.

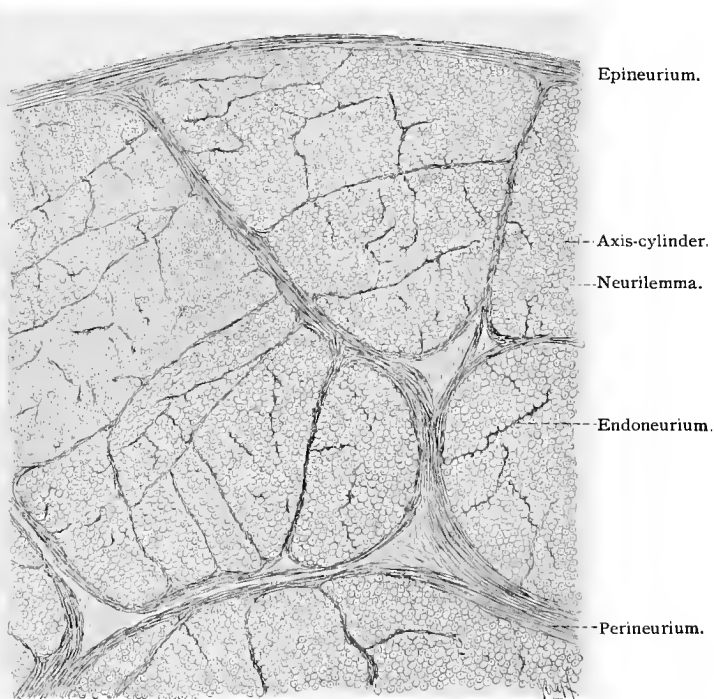


Fig. 118.—Part of a cross-section through a peripheral nerve treated with alcohol. The small circles represent the cross-sections of medullated nerve-fibers; the axis-cylinders show as points in their centers. The nerve is separated by connective tissue into large and small bundles—funiculi;  $\times 75$ .

nerve-fibers of the funiculi ; consequently, the lamellæ are covered by a layer of endothelial cells. In the larger funiculi, septa of fibrous connective tissue pass from the perineurial sheath into the funiculi, dividing them into compartments varying in shape and size ; these are spoken of as *compound funiculi*. The funiculi of a nerve-trunk are bound together by an investing sheath of loose fibro-elastic tissue, continuous with the perineurial sheaths, which penetrates between the funiculi, and which contains fat-cells, blood-vessels, and lymph-vessels ; the latter being in communication with the lymph-spaces of the perineurial sheaths.

When a nerve-trunk divides, the connective-tissue sheaths above mentioned are continued on to the branches, and this even to the smallest offshoots. Thus, single fibers even possess a connective-tissue sheath,—*Hentle's sheath*,—which consists of a few connective-tissue fibers and of flattened cells.

#### PERIPHERAL NERVE TERMINATIONS.

According to the character of the peripheral organs in which the telodendria of nerve-fibers (neuraxes of type I cells and dendrites of spinal ganglion cells) occur, the nerve-fibers are known as motor and sensory nerve-fibers, the terminations as motor and sensory nerve-endings.

**Motor Nerve-endings (the Telodendria of Nerve-fibers Ending in Muscle Tissue).**—The motor nerve-endings in striated, voluntary muscle tissue will first be considered. The motor nerve-endings in voluntary muscle tissues are the endings of neurones (peripheral motor neurones), the cell-bodies of which are situated in the ventral horns of the spinal cord and in the medulla. The neuraxes of these cells leave the cerebrospinal axis as medullated nerve-fibers (motor fibers) which, after branching, end in the muscle-fibers in the so-called motor endings. In figure 119 is represented, by way of diagram, a complete peripheral motor neurone. Each motor nerve-fiber branches repeatedly before terminating, although this branching does not often take place until near the termination of the nerve-fiber. Kölliker estimates that in the *sternoradialis* of the frog, each motor fiber innervates about twenty muscle-fibers ; but whether this number may be regarded as the average number of muscle-fibers receiving their motor nerve-supply from one motor neurone can not be stated with any degree of certainty at the present time.

Each motor ending represents the termination of one of the terminal medullated branches of a motor nerve-fiber. The neuraxis of this fiber passes under the sarcolemma and terminates in a telodendrion (end-brush) in an accumulation of sarcoplasm, in which are found numerous muscle nuclei, forming a more or less distinct elevation on the side of the muscle-fiber, *Doyère's elevation*. The medullary sheath accompanies the nerve-fiber until it passes under the sarcolemma, when it stops abruptly. The neurilemma of the

nerve-fiber becomes continuous with the sarcolemma of the muscle-fiber at the place where the neuraxis passes under the sarcolemma. Henle's sheath continues over the motor ending as a thin sheath, containing here and there flattened nuclei, the *telolemma nuclei*.

With the majority of the reagents used to bring to view the motor endings, notably chlorid of gold, the sarcoplasm, in which

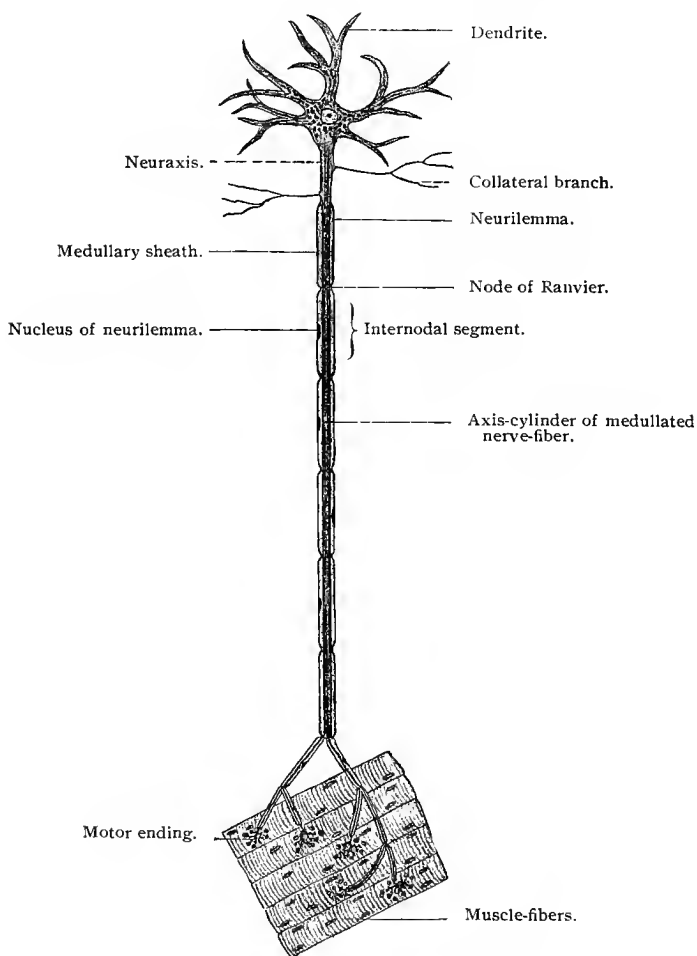


Fig. 119.—Diagram of peripheral motor neurone.

the telodendrion of the nerve-fiber is found, has a granular appearance, and is consequently differentiated from the remaining sarcoplasm of the muscle-fiber. To this the term *granular sole plate* has been applied, the nuclei contained therein being known as *sole nuclei*, the whole ending as the *motor end-plate*. If the above interpreta-

tion of the structure of the motor nerve-ending is correct, there would seem to be no reason why the sarcoplasm in which the telodendria occur should be considered other than the sarcoplasm of the muscle-fiber, the nuclei as muscle-nuclei; the terms motor end-plate, granular sole plate, and sole nuclei would therefore seem unnecessary and misleading. In figures 121 to 125 are shown motor nerve-endings from several vertebrates as seen when stained with gold chlorid.

The mass of sarcoplasm in which the neuraxes terminate as above described is about 40 to 60  $\mu$  long, 40  $\mu$  broad, and 6 to 10  $\mu$  thick; these dimensions vary greatly, however; they may be greater or less than the averages here given.

In amphibia the motor nerve-endings are not so localized as in the majority of vertebrates, as above described, but are spread over a relatively greater surface of the muscle-fiber, and there is no distinct accumulation of the sarcoplasm, and the muscle-nuclei are

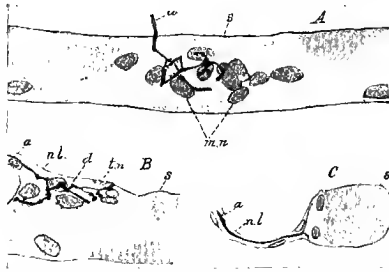


Fig. 120.—Motor nerve-ending in voluntary muscle of rabbit, stained in methylene-blue (*intra vitam*) (Huber, DeWitt, "Jour. Comp. Neurol.," vol. VII): *A*, Surface view; *B*, longitudinal section through motor ending; *C*, cross-section: *a*, *a*, *a*, neuraxes of nerve-fibers; *s*, *s*, *s*, sarcolemma; *nl*, *nl*, neurilemma; *d*, Doyère's elevation; *m*, *n*, muscle nuclei; *tn*, telolemma nucleus.

relatively less numerous. The telodendrion of the nerve-fiber is, however, under the sarcolemma, between it and the contractile substance of the muscle-fiber. (Fig. 126.)

The number of motor nerve-endings in a striated, voluntary muscle-fiber depends on its length, short fibers having, as a rule, one ending, longer fibers two, or even more.

*Heart muscle-cells* and *nonstriated muscle-cells* receive their motor nerve-supply from neurones of the sympathetic nervous system. The cell-bodies of these neurones are situated in sympathetic ganglia; the neuraxes, the majority of which form nonmedullated nerve-fibers, branch repeatedly, forming primary and secondary plexuses which surround the larger or smaller bundles of heart muscle-fibers or involuntary muscle-cells. From these plexuses, naked, varicosed axis-cylinders, or small bundles of such, penetrate between the muscle-cells, also forming plexuses. The fine fibers of this terminal plexus give off from place to place small, lateral

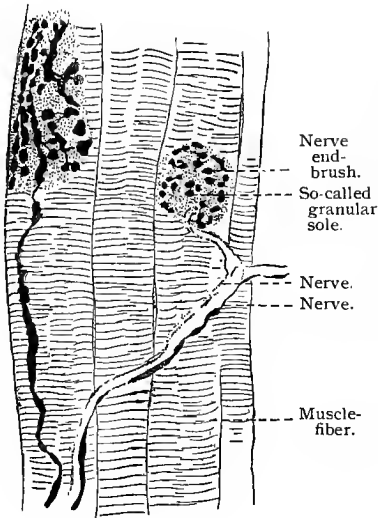


Fig. 121.

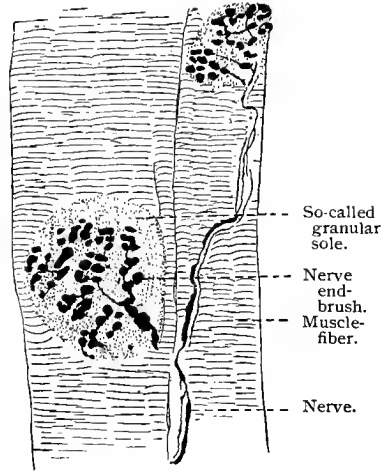
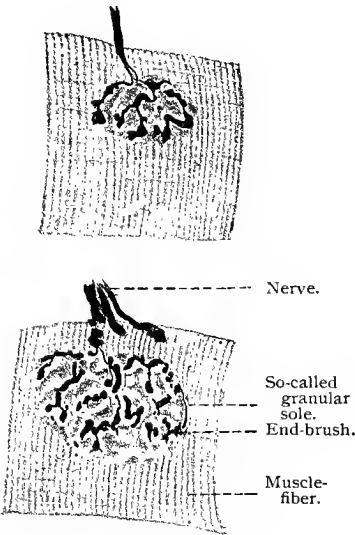


Fig. 122.



Figs. 123 and 124.

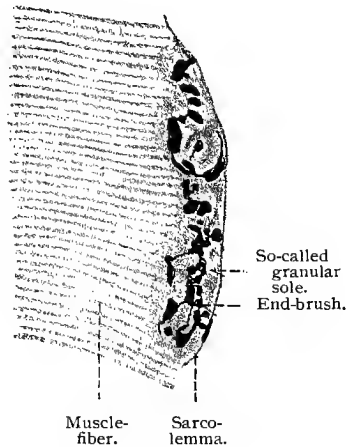


Fig. 125.

Figs. 121-125.—Motor endings in striated voluntary muscles.

Fig. 121, from *Pseudopus Pallasii*;  $\times 160$ . Fig 122, from *Lacerta viridis*;  $\times 160$ . Figs. 123 and 124, from a guinea-pig;  $\times 700$ . Fig. 125, from a hedge-hog;  $\times 1200$ . As a consequence of the treatment (T. 182, I) the arborescence is shrunken and interrupted in its continuity. In Figs. 121 and 122 the end-plate is considerably larger than in 123 and 124. In Fig. 121 it is in connection with two nerve-branches. Fig. 125 shows a section through an end-plate. The latter is bounded externally by a sharply defined line, which can be traced along the surface of the muscle-fiber. This is to be regarded as the sarcolemma.

twigs, which end on the muscle-cells. In heart muscle these lateral twigs may end in one or two small granules, or in a small cluster of such granules (Fig. 127); in involuntary, nonstriated muscle the ending is very simple, the small lateral twigs terminating in one or two small granules. (Fig. 128.)

**Sensory Nerve-endings.**—The sensory nerve-endings are, in their essentials, the peripheral telodendria of dendrites of peripheral sensory neurones. The cell-bodies of such neurones, as has been stated, are found in the spinal and homologous cranial ganglia.

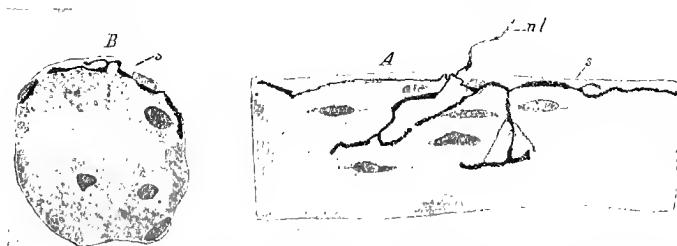


Fig. 126.—Motor nerve-ending in striated voluntary muscle of a frog; methylene-blue stain (*intra vitam*) (Huber, DeWitt): *A*, Surface view; *B*, cross-section; *s*, *s*, sarcolemma; *nl*, neurilemma.

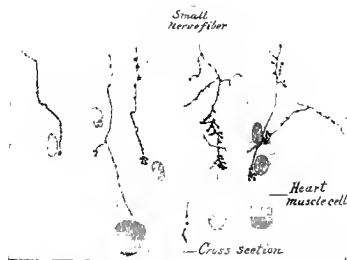


Fig. 127.—Motor nerve-ending on heart muscle-cells of cat; methylene-blue stain (Huber, De Witt).



Fig. 128.—Motor nerve-ending on involuntary nonstriated muscle-cell from intestine of cat; methylene-blue stain (Huber, De Witt).

Of the two branches arising from the single process possessed by each peripheral sensory neurone, the one going to the periphery is regarded as the dendrite and forms the axis-cylinder of a medullated nerve-fiber, such nerve-fibers constituting the sensory nerves of the peripheral nerve-trunks. A peripheral sensory neurone may therefore be diagramed as in figure 129. The statement was made above that the essential portion of a sensory nerve-ending is a telodendrion (end-brush) or several telodendria of the dendrite of a peripheral sensory neurone. The character of a sensory nerve-

ending depends, therefore, on the complexity of this end-brush and on its relation to the other tissue elements which take part in the formation of the sensory nerve-endings. Bearing this in mind, the following classification of such nerve-endings can be made :

1. *Free Sensory Nerve-endings*.—In these the telodendrion is not

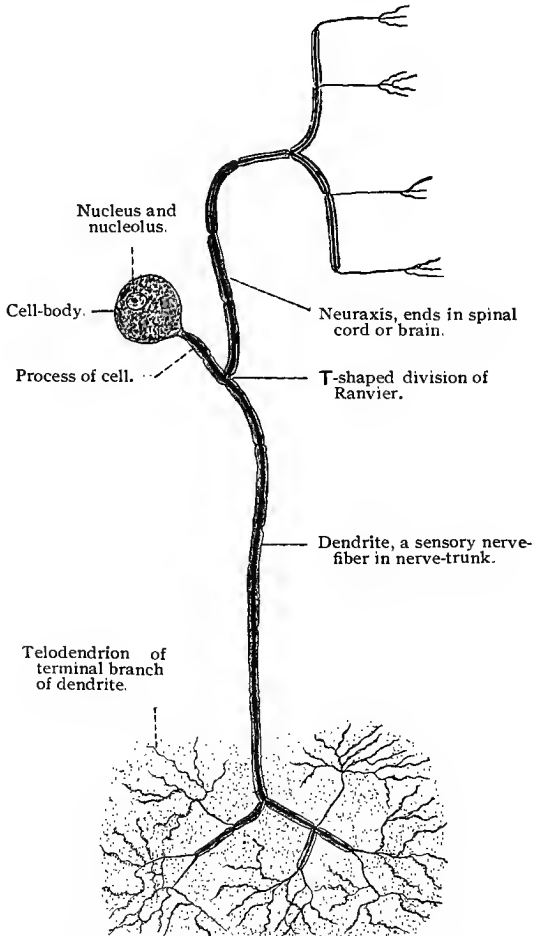


Fig. 129.—Diagram of a peripheral sensory neurone.

inclosed in an investing capsule which forms a structural part of the ending.

2. *Encapsulated Endings*.—In which the telodendrion or several telodendria are surrounded by an investing capsule which separates them more or less completely from the surrounding tissue.

1. **Free sensory nerve-endings** are found in all epithelial tissues and in fibrous connective tissue of certain regions. A sensory

nerve-fiber terminating in such an ending usually proceeds without branching to near its place of termination, where, while yet a medullated fiber, it branches and rebranches a number of times,

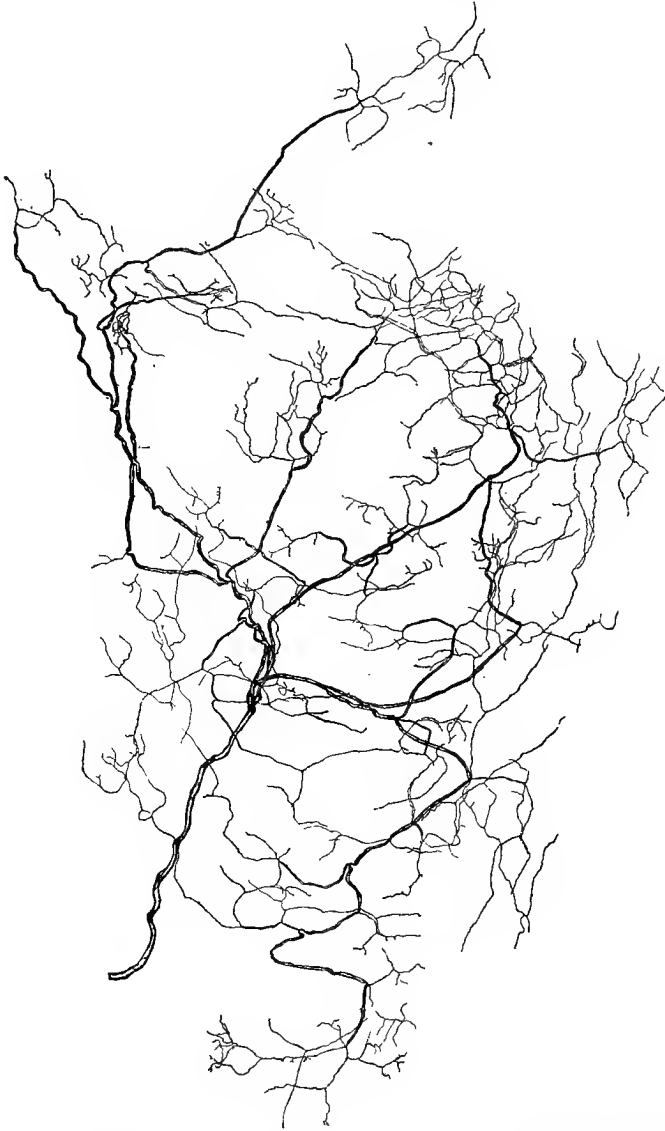


Fig. 130.—Termination of sensory nerve-fibers in the mucosa and epithelium of the urethra of cat; methylene-blue preparation (Huber, "Jour. Comp. Neurol.," vol. x).

always at the nodes of Ranvier, the resultant branches diverging at various angles. If the free sensory endings are in epithelial tissue,

these larger medullated branches are situated in the connective-tissue mucosa under the epithelium. From these larger medullated branches, are given off smaller ones, also medullated, which may divide further, and which pass up toward the epithelium, and near its under surface divide into nonmedullated branches. Nonmedullated branches are also given off from the medullated ones as they approach the epithelium, leaving the parent fibers at the nodes of Ranvier. Many of the nonmedullated branches thus formed, after coursing a variable distance under the epithelium, enter it and break up into numerous very small branches, which, after repeated division, terminate between the epithelial cells in small nodules or discs of variable size and configuration. The small branches resulting from a division of one of the larger nonmedullated branches constitute one of the terminal telodendria or end-branches of the dendrites of peripheral sensory neurones terminating in free sensory nerve-endings. In fibrous connective tissue the same general arrangement of the branches prevails. In figure 130 is shown the peripheral distribution of the dendrite of a peripheral sensory neurone terminating in a free sensory nerve-ending.

2. **Encapsulated Sensory Nerve-endings.**—These nerve-endings may be divided into two quite distinct groups,—such as have a

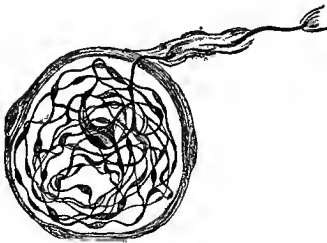


Fig. 131.—End-bulb of Krause from conjunctiva of man; methylene-blue stain (Dogiel, "Arch. f. mik. Anat.," vol. xxxvii).

relatively thin fibrous-tissue capsule, containing mainly telodendria of the nerve or nerves terminating therein, and such as have a distinctly lamellated, fibrous tissue capsule, usually investing, besides the nerve-termination, other tissue elements. To the former group belong three types of sensory nerve-endings, which, owing to their similarity of structure, may be described together. These are the end-bulbs of Krause, Meissner's tactile corpuscles, and the genital corpuscles. They have all been investigated recently by

Dogiel, and the account here given follows closely his description.

*End-bulbs of Krause.*—Under this designation there are described a variety of endings which vary slightly in size and shape. They are found in the conjunctiva and edge of the cornea, in the lips and lining of the oral cavity, in the glans penis and clitoris, and probably also in other parts of the dermis. In form they are round, oval, or pear-shaped. Their size varies from 0.02 to 0.03 mm. long and from 0.015 to 0.025 mm. broad for the smaller ones, and from 0.045 to 0.10 mm. long and from 0.02 to 0.08 mm. broad for the larger ones. They have a relatively thin capsule in which nuclei are quite numerous. One, two, or three medullated nerves go to each end-bulb. These may lose their medul-

lary sheath at the capsule or at a variable distance from it. The naked axis-cylinders, soon after entering the capsule, divide into two, three, or four branches, which form several circular or spiral turns in the same or in opposite directions. These fibers then divide into varicose branches, which undergo further division, the resulting branches interlacing to form a bundle of variously tangled fibers which may be loosely or tightly woven.

Between the nerve-fibers and their branches, within the capsule, there is found a semifluid substance, which is granular in fixed preparations.

*Meissner's Corpuscles.*—These corpuscles are found in man in the subepidermal connective tissue of the hand and foot and outer surface of the forearm, in the nipple, border of the eyelids, lips, glans penis and clitoris. They are most numerous in the palmar surface of the distal phalanx of the fingers. They are oval in shape, sometimes somewhat irregular, and vary in size, being from  $45 \mu$  to  $50 \mu$  broad and from  $110 \mu$  to  $180 \mu$  long. They possess a thin connective-tissue capsule, in which are found round or oval nuclei, some of which have an oblique position to the axis of the corpuscle. One medullated nerve ends in the smaller corpuscles, two or three or even more in the larger ones. After piercing the capsule, the medullated nerves lose their

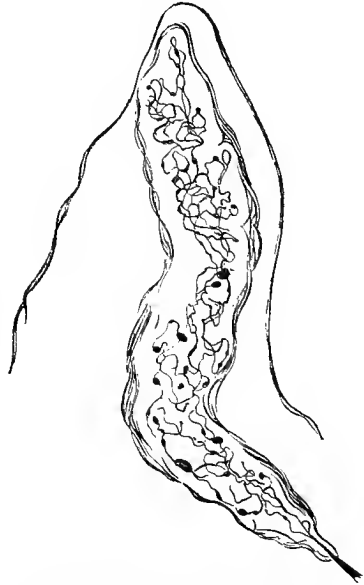


Fig. 132.—Meissner's tactile corpuscle; methylene-blue stain (Dogiel, "Internat. Monatsschr. f. Anat. u. Phys.," vol. IX).

medullary sheaths, the naked axis-cylinders making a variable number of circular or spiral turns, some of which are parallel, others crossing at various angles. These larger branches are all beset with large, spindle-shaped, round, or pear-shaped varicosities. The larger branches, after making the windings mentioned, break up into many varicose branches, which interlace and form a most complex network. One usually finds one or several larger naked axis-cylinders, which pass up through the axis of the spiral of fibers thus formed; these give off branches which contribute to the spiral formation.

*Genital Corpuscles.*—These corpuscles are found in the deeper part of the mucosa of the glans penis and the prepuce of the male and the clitoris and neighboring structures of the female. Their shape varies; they may be round, oval, egg- or pear-

shaped, or even slightly lobulated. Their size varies from 0.04 to 0.10 mm. in breadth and from 0.06 to 0.40 mm. in length. They are surrounded by a relatively thick fibrous capsule, consisting of from three to eight quite distinct lamellæ, between which irregular flattened cells with round or oval nuclei are found. Within this capsule, there is found a core, which seems to consist of a semifluid substance, slightly granular in fixed preparations, the nature of which is not fully known. The number of sensory nerves going to each corpuscle varies from one to two for the smaller ones, and from eight to ten for the larger corpuscles. The medullated nerves, after entering the corpuscle, divide dichotomously, the resultant branches assuming a circular or spiral course, and interlacing in various ways, within the capsule. After a few turns, the medullated

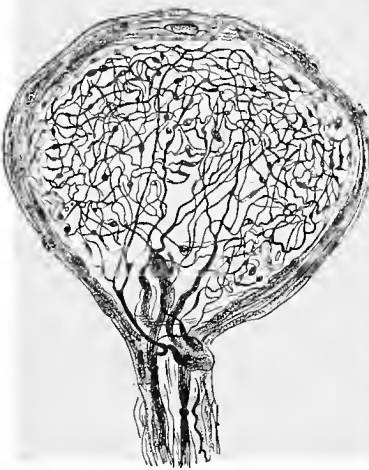


Fig. 133.—Genital corpuscle from the glans penis of man; methylene-blue stain (Dogiel, "Arch. f. mik. Anat.," vol. XLI).

branches lose their medullary sheaths and undergo further division, often dividing repeatedly. The nonmedullated nerves resulting from these divisions, the majority of which are varicose, form a most complicated network, the whole nerve network presenting a structure which resembles a tangle of fine threads. In the meshes of this network is found the semifluid substance of the core. Now and then some of the larger fibers of the network leave the corpuscle and terminate in neighboring corpuscles, or pass to the epithelium, where they end between the cells.

These three sensory nerve-endings—end-bulbs of Krause, Meissner's tactile corpuscles, genital corpuscles—are, as Dogiel has stated, very similar in structure. Each has a thin connective-tissue capsule, surrounding a core, consisting of a semifluid substance, concerning which our knowledge is as yet imperfect. One or several medullated nerves go to each corpuscle, which, after losing their medullary sheaths, divide and subdivide into numerous fine varicose branches, which are variously interwoven, forming a more or less dense plexus of interlacing and, according to Dogiel, anastomosing fibers. The chief differences are those of form and size, and of position with reference to the epithelium. Of the three forms of endings, the genital corpuscle is the largest, and occupies the deepest position in the subepithelial connective tissue; Meissner's corpuscle is intermediate in size, and is found immediately under the epithelium; while the end-bulbs of Krause are the smallest of these

three forms of sensory endings and may be found in the papillæ or in the deeper connective tissue.

A somewhat smaller nerve-ending of long, oval, or cylindrical form, known as the *cylindric end-bulb of Krause*, is found in various parts of the skin and oral mucous membrane, in striated muscle and in tendinous tissue. These corpuscles consist of a thin nucleated capsule, investing a semifluid core. The nerve-fiber, after losing its medullary sheath and fibrous sheath (the latter becomes continuous with the capsule), passes through the core, generally without branching, as a naked axis-cylinder, terminating at its end, usually in a small bulb. (Fig. 134.)

The majority of the sensory nerve-endings with well-developed lamellated capsules are relatively large structures. We shall consider especially the Vater-Pacinian corpuscles, the neuromuscular end-organs, and the neurotendinous end-organs.

*Vater-Pacinian Corpuscles.*—

These corpuscles are of oval shape and vary much in size, the largest being about 0.10 of an inch long and 0.04 of an inch broad. The greater portion of the corpuscle is made up of a series of concentric lamellæ, varying in number from twenty to sixty. These lamellæ are made up of white fibrous tissue fibers, rather loosely woven, between which is found a small amount of lymph, containing usually a few leucocytes. The lamellæ are covered on both surfaces by a layer of endothelial cells (Schwalbe). Between two consecutive lamellæ there is found an interlamellar space, also containing lymph. The axis of the corpuscle is occupied by a core, consisting of a semifluid, granular substance, in the periphery of which oval nuclei are said to be found. Usually one large medullated nerve-fiber goes to each corpuscle. The fibrous tissue sheath of this nerve-fiber becomes continuous with the outer lamellæ of the capsule. The medullary sheath accompanies the axis-cylinder through the concentric lamellæ until the core is reached, where it disappears. The naked axis-cylinder usually passes through the core to its distal end, where it divides into three, four, or five branches which terminate in large, irregular end-discs. The axis-cylinder may, however, divide soon after it enters the core into two or three or even four branches, these passing to the distal end of the core before terminating in the end-discs above mentioned. Both Retzius and Sala state that the naked axis-cylinders, after entering the core, give off numerous short side branches, terminating in small knobs, which remind these observers of the fine side branches or thorns seen on the dendrites of Purkinje's cells and of the pyramidal cells of the cortex, when stained



Fig. 134. — Cylindric end-bulb of Krause from intermuscular fibrous tissue septum of cat; methylene-blue stain.

after the Golgi method. In company with the large nerve-fibers here mentioned, Sala has described other nerve-fibers, quite independent of them and much finer, which after entering the corpuscle divide repeatedly, the resulting fibers forming a plexus around the central fiber. A small arteriole enters the corpuscle with the nerve-fiber, dividing into capillary branches found between the lamellæ of the capsule.

The Vater-Pacinian corpuscles have a wide distribution. They are numerous in the deeper parts of the dermis of the hand and foot, and also near the joints, especially on the flexor side. They have been found in the periosteum of certain bones and in tendons and intermuscular septa, and even in muscles. They are further found in the epineurial sheaths of certain nerve-trunks and near

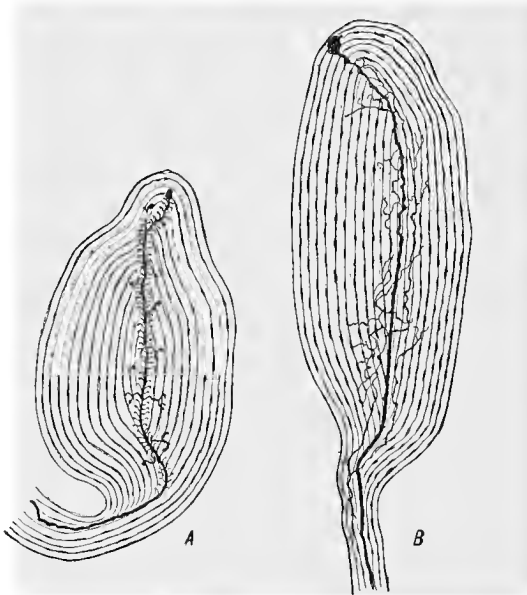


Fig. 135.—Pacinian corpuscles from mesorectum of kitten: *A*, Showing the fine branches on central nerve-fiber; *B*, the network of fine nerve-fibers about the central fiber; methylene-blue preparation (Sala, "Anat. Anzeiger," vol XVI).

large vessels. They are numerous in the peritoneum and mesentery, pleura and pericardium. In the mesentery of the cat, where these nerve-endings are large and numerous, they are readily seen with the unaided eye as small, pearly bodies.

In the bill and tongue of water birds, especially of the duck, are found nerve-endings, known as the *corpuscles of Herbst*, which resemble the Vater-Pacinian corpuscles; they differ from the latter in having cubic cells in the core. (Fig. 136.)

*Neuromuscular Nerve End-organs.*—These nerve end-organs consist of a small bundle of muscle-fibers, surrounded by an invest-

ing capsule, within which one or several sensory nerves terminate. They are spindle-shaped structures varying in length from 0.75 to 4 mm., and in breadth, where widest, from 80 to 200  $\mu$  (Sherrington, 94). In them there is recognized a *proximal polar region*, an *equatorial region*, and a *distal polar region*. The muscle-fibers of this nerve-ending, known as the *intrafusal fibers*, which may vary in number from 3 or 4 to 20 or even more, are much smaller than the ordinary voluntary muscle-fibers and differ from them structurally, and result from a division of one or several muscle-fibers of the red variety. In the proximal polar region the intrafusal fibers present an appearance which is similar to that of voluntary muscle-fibers of the red variety; in the equatorial region they possess rela-

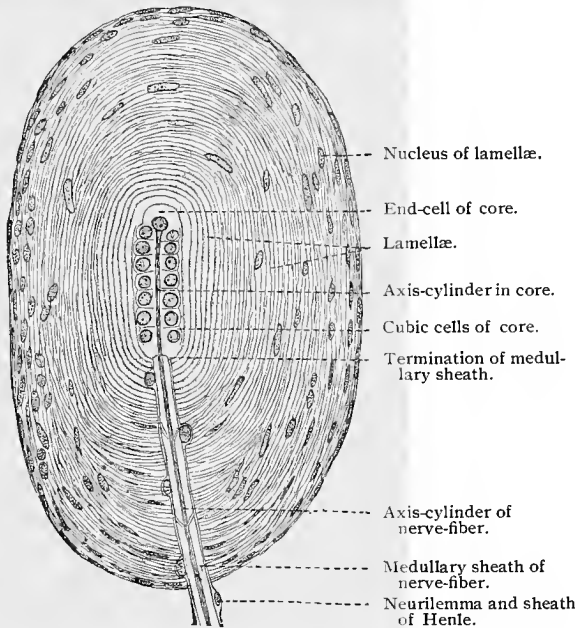


Fig. 136.—Corpuscle of Herbst from bill of duck;  $\times 600$ . Technic No. 296.

tively few muscle-fibrils and are rich in sarcoplasm and the muscle-nuclei are numerous; the striation is here indistinct. In the distal polar region the intrafusal fibers are again more distinctly striated and, a short distance beyond the end-organ, become greatly reduced in size, and terminate as very small fibers, still showing, however, a cross-striation. In figure 137 is shown a single intrafusal muscle-fiber. Owing to the length of such a fiber it was necessary to represent it in several segments.

The intrafusal muscle-fibers are surrounded by a capsule consisting of from four to eight concentric layers of white fibrous tissue. At the proximal end this capsule is continuous with the connective

tissue found between the muscle-fibers—endo- and perimysium. It attains its greatest diameter in the equatorial region of the nerve end-organ, and becomes narrower again at its distal end, where it may end in tendon or become continuous with the connective tissue




Fig. 137.—Intrafusal muscle-fiber from neuromuscular nerve end-organ of rabbit: *A*, From proximal polar region; *B*, equatorial region; *C*, distal polar region.

of the muscle. Immediately surrounding the intrafusal fibers is found another connective-tissue sheath known as the *axial sheath*, and between this and the capsule there is found a lymph-space bridged over by trabeculæ of fibrous tissue, to which the name *periaxial lymph-space* has been given. (Fig. 138.)

By degenerating the motor nerves going to a muscle, Sherrington

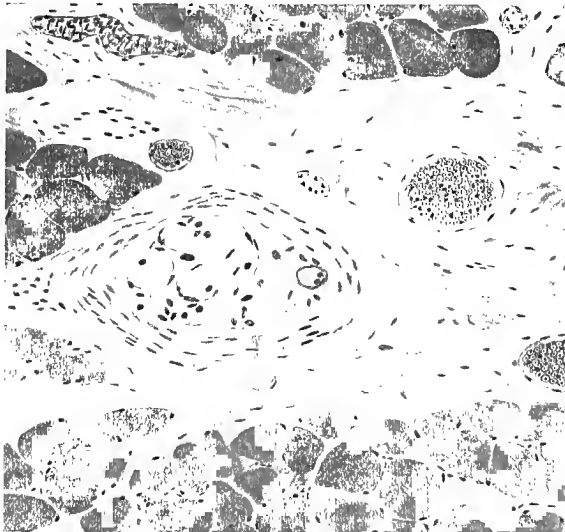


Fig. 138.—Cross-section of a neuromuscular nerve end-organ from interosseous (foot) muscle of man; fixed in formalin and stained in hematoxylin and eosin.

determined that the nerve-fibers ending in the neuromuscular nerve end-organs were sensory in character. The manner of termination in these end-organs of the nerve-fibers ending therein has been studied by Kerschner, Kölliker, Ruffini, Huber and DeWitt, and others.

One or several (three or four) large medullated nerves, surrounded by a sheath of Henle, terminate in each neuromuscular end-

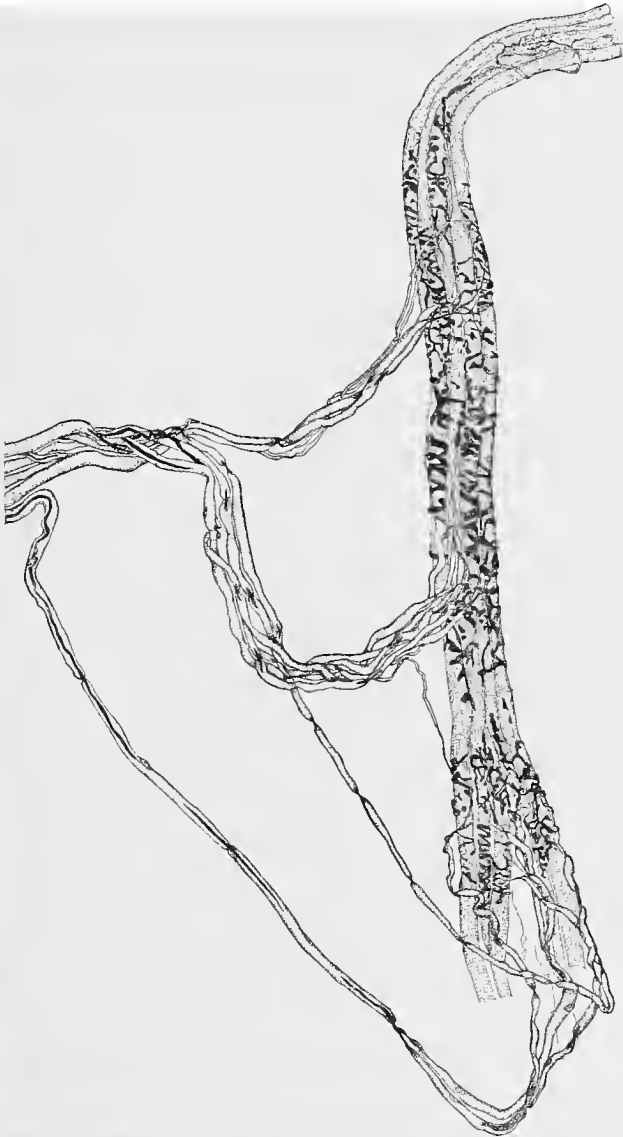


Fig. 139.—Neuromuscular nerve end-organ from the intrinsic plantar muscles of dog ; from teased preparation of tissue stained in methylene-blue. The figure shows the intrafusal muscle-fibers, the nerve-fibers and their terminations ; the capsule and the sheath of Henle are not shown (Huber and DeWitt, "Jour. Comp. Neurol.," vol. VII).

organ. As these nerves enter the capsule, the sheath of Henle blends with the capsule. The medullated nerve-fibers now and

then divide before reaching the nerve end-organs, and divide several times as they pass through the capsule, periaxial space, and axial sheath. Within the axial sheath, the medullary sheath is lost, and

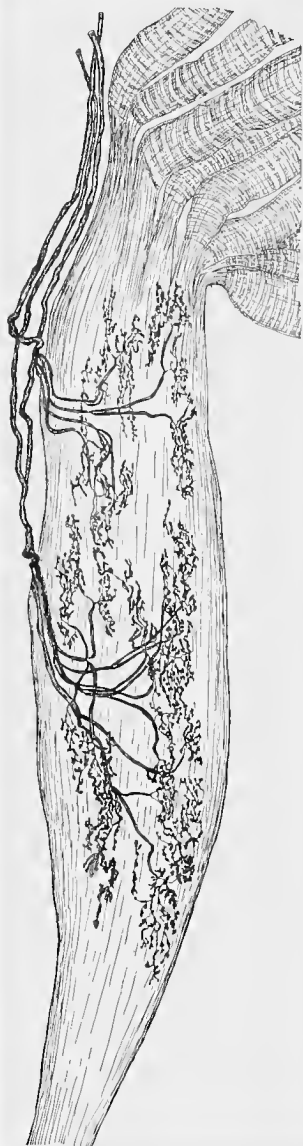


Fig. 140. — Neurotendinous nerve end-organ from rabbit; teased preparation of tissue stained in methylene-blue (Huber and DeWitt, "Jour. Comp. Neurol.," vol. x).

the naked axis-cylinders terminate in one or several ribbon-like branches which are wound circularly or spirally about the intrafusal fibers (*annulospiral ending*) or they may terminate in a number of larger branches which again divide, these ending in irregular, round, oval, or pear-shaped discs (*flower-like endings*), which are also on the intrafusal fibers. These flower-like endings are usually at the ends of the annulospiral fibers. In the smaller end-organs only one area of nerve-termination has been observed; in the larger, two, three, or even four such areas may be found.

Neuromuscular nerve end-organs are found in nearly all skeletal muscles (not in the extrinsic eye muscles nor in the intrinsic muscles of the tongue), but they are especially numerous in the small muscles of the hand and foot. They are found in amphibia, reptilia, birds, and mammalia, presenting the same general structure, although the ultimate termination of the nerve-fibers varies somewhat in the different classes of vertebrates.

*Neurotendinous Nerve End-organ* (Golgi Tendon Spindle). — In 1880 Golgi drew attention to a new nerve end-organ found in tendon, describing quite fully its general structure and less fully the nerve termination found therein. These nerve end-organs are spindle-shaped structures, which in man vary in length from 1.28 mm. to 1.42 mm., and in breadth from 0.17 mm. to 0.25 mm. (Kölliker). Ciaccio mentions a neurotendinous nerve end-organ found in a woman, which was 2 or 3 mm. long. A capsule consisting of from 2 to 6 fibrous, tissue lamellæ, and broadest at the equatorial part of the end-organ, surrounds a number of in-

trafusul tendon fasciculi. The capsule is continuous at the proximal and distal ends of the end-organ with the internal peritendineum of the tendon in which it is found. The number of the intrafusul tendon fasciculi varies from eight to fifteen or even more. They are smaller than the ordinary tendon fasciculi, from which they originate by division, and structurally resemble embryonic tendon, in that they stain more deeply and present many more nuclei than fully developed tendon. The intrafusul tendon fasciculi are surrounded by an axial sheath of fibrous tissue, between which and the capsule there is found a periaxial lymph-space.

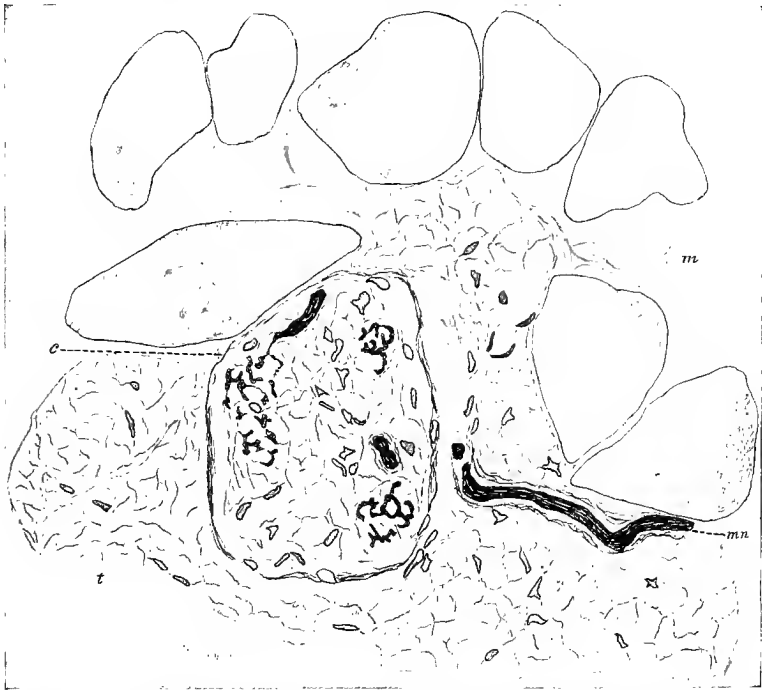


Fig. 141.—Cross-section of neurotendinous nerve end-organ of rabbit; from tissue stained in methylene-blue: *m*, Muscle-fibers; *t*, tendon; *c*, capsule of neurotendinous end-organ; *mn*, medullated nerve-fiber (Huber and DeWitt, "Jour. of Comp. Neurol.," vol. X).

The termination of the nerve-fibers ending in these end-organs has been studied by Golgi, Cattaneo, Kerschner, Kölliker, Pansini, Ciaccio, Huber and DeWitt. One, two, or three large medullated nerve-fibers, surrounded by a sheath of Henle, end in each end-organ; as they pass through the capsule, the sheath of Henle blends with the capsule. The medullated nerve-fibers before entering the capsule usually branch several times, branching further within the capsule and axial sheath. Before the resultant branches terminate on the intrafusul tendon fasciculi, the medullary sheath is

lost, the naked axis-cylinder further dividing into two, three, or four branches, each of which runs along on the intrafusal fasciculi, giving off numerous short, irregular side branches, which partly enclasp the tendon fasciculi and end in irregular end-discs. Some of the terminal branches pass between the smaller fibrous tissue bundles of the fasciculi, ending between them.

In these end-organs, the larger nerve-branches are found near the center of the bundle of intrafusal tendon fasciculi, the terminal branches and the end-discs nearer their periphery. The neurotendinous nerve end-organs are widely distributed, being found in all tendons although not equally numerous in all. Like the neuromuscular nerve end-organs, they are especially numerous in the small tendons of the hand and foot. Sensory nerve end-organs, which resemble in structure the neurotendinous end-organs here described, though somewhat smaller than these, have been found in the tendons of the extrinsic eye-muscles.

In this brief account of the mode of ending of the telodendria of the dendrites of peripheral sensory neurones (sensory nerve-fibers) it has not been possible to discuss any but the more typical varieties of sensory nerve-endings. Other nerve-endings will be considered in connection with the several organs to be treated later. For a fuller discussion of this subject, the reader is referred to special works and monographs.

### TECHNIC.

173. Fresh medullated nerve-fibers, when teased in an indifferent fluid (*vid.* T. 13), show the peculiar luster of the medullary sheath, and also the nodes of Ranvier, the neurilemma with its nuclei, and the segments of Lantermann. At the cut ends of the fibers, the typical coagulation of their medullary portions is seen in the form of drops of myelin. All these structures can also be seen after using 1% osmic acid. A nerve (not too thick) is placed in a 1% aqueous osmic acid solution, then washed for a few hours in distilled water, and finally carried over into absolute alcohol. After dehydration, small pieces are cleared with oil of cloves and the fibers teased apart upon a slide. The medullary sheath is stained black and hides the axial space, the nodes are clear, the neurilemma is sometimes seen as a light membrane, and the nuclei of the fibers are of a lenticular shape, and stained brown.

174. The nodes of Ranvier may also be demonstrated by means of silver nitrate solution. Fresh nerve-fibers are either teased in distilled water to which a trace of 1% silver nitrate solution has been added (the nodes of Ranvier appear after a short time as small crosses), or whole nerves are placed for twenty-four hours in a 0.5% aqueous solution of silver nitrate, washed for a short time with water, hardened in alcohol, after which they are imbedded in paraffin and cut longitudinally. Exposure to light will soon bring out the "crosses of Ranvier" at the nodes. The appearance of these crosses is due to the fact that the silver nitrate solution first penetrates at the nodes of Ranvier, and then passes by capillary attraction along the axial cord for some distance. After the reduction of the silver, the cruciform figures appear colored

black. Occasionally, a peculiar transverse striation is seen in the longitudinal portions of the crosses. These are known as Frommann's lines. Their origin and significance have not as yet been satisfactorily explained.

175. To demonstrate the fibrils of the axial cord a piece of a small nerve is stretched on a match or toothpick and fixed for four hours in a 0.5% osmic acid solution, after which it is washed in water for the same length of time and immersed in 90% alcohol for twenty-four hours. The preparation is now stained for another twenty-four hours in a saturated aqueous solution of fuchsin S and then placed for three days in absolute alcohol. Finally, the nerve is passed as rapidly as possible through toluol, toluol-paraffin, and then imbedded in paraffin. The proper orientation of the specimen is of the greatest importance, as is also the cutting of thin sections. In a longitudinal section red fibrils of almost uniform thickness and evenly distributed throughout the axial space are seen lying in the colorless neuro-

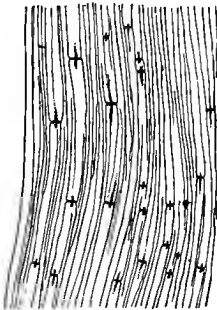


Fig. 142.—Ranvier's crosses from sciatic nerve of rabbit;  $\times 120$ . Technic No. 174. Frommann's lines can be seen in a few fibers.

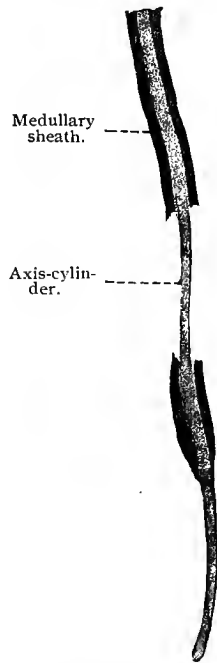


Fig. 143.—Medullated nerve-fiber from sciatic nerve of frog. In two places the medullary sheath has been pulled away by teasing, showing the "naked axis-cylinder";  $\times 212$ . Technic No. 176.

plasm, and parallel to the long axis of the nerve-fiber. In cross-section the axial fibrils appear as evenly distributed dots. Attention must be called to the fact that the fibrils are not equally well stained in all cases (Kupffer, 83, II; compare also Jacobi and Joseph).

176. When the fiber is less carefully treated, the fibrils fuse with the neuroplasm to form the "axis-cylinder" of authors. As the appearance of the latter is due to a shrinkage of the contents of the axial space, it is easy to understand that one reagent may have a greater effect in this respect than another. The thinnest axis-cylinders are produced by chromic acid and its salts, while thicker ones are seen in nerve-fibers fixed in alcohol. These variations are best seen in cross-sections, in which the

axis-cylinders sometimes appear as round dots and again as stellate figures. The latter are due to pressure on the shrinking axial cord by the unevenly coagulated medullary sheath.

As the medullary sheath in such preparations crumbles away in many places, large areas of the axis-cylinder may often be isolated by teasing (Fig. 143).

177. If freshly teased fibers be treated with glacial acetic acid, the axis-cylinders swell up and issue from the ends of the fibers in irregular masses showing fine longitudinal striation (Kölliker, 93). The structures of the axial space dissolve in 1% hydrochloric acid, as well as in a 10% solution of sodium chlorid (Halliburton).

178. For the isolation of ganglion cells, 33% alcohol, 0.1 to 0.5% chromic acid, or 1% solution of potassium bichromate may be used.

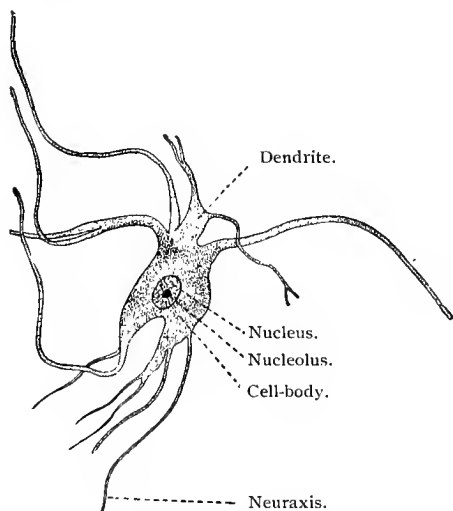


Fig. 144.—A ganglion cell from anterior horn of the spinal cord of calf; teased preparation;  $\times 140$ . Technic No. 178. By this method only the coarsest ramifications of the dendrites are preserved; the rest are torn off.

179. The nonmedullated or "Remak's fibers" are obtained by teasing a sympathetic nerve, or, better, a piece of the vagus previously treated with osmic acid. Between the blackened medullated fibers of the pneumogastric are seen numerous unstained fibers of Remak.

The fibers of the olfactory nerves are stained brown by osmic acid.

180. Short muscles (ocular muscles or intercostal muscles) are employed in demonstrating the motor nerve-endings in muscles, the fresh specimen being treated with 1% acetic acid.

181. Furthermore, the gold methods for the demonstration of the nerve-fibers in the cornea, first discovered by Cohnheim (67, II) and still used to-day, may be employed: Small pieces of muscle are placed in a 1% solution of gold chlorid acidulated by a trace of acetic acid.

In this they become yellow (in from a few minutes to half an hour). They are then rinsed in distilled water, placed in water slightly acidulated with acetic acid, and kept in the dark. As a rule, the pieces will change in color, becoming yellowish-gray, grayish-violet, and finally red, from one to three days generally being required for this process. The parts best adapted to examination are those in the transitional stage of violet to red.

**182.** This procedure has been subjected to innumerable modifications; of these, the most used are: (1) The method of Löwit: Small pieces are placed in a solution of 1 vol. formic acid and 2 vols. distilled water until they have become transparent (ten minutes). They are then placed in a 1% solution of gold chlorid, in which they become yellow (one-quarter hour). They are now again placed in formic acid, in which they pass through the same color changes as above. Finally, they are washed and teased, or subsequently treated with alcohol and cut. (2) Kühne (86) acidifies with 0.5% solution of acetic acid (especially in the case of muscle), then treats the specimens with a 1% solution of gold chlorid, and reduces the gold with 20 to 25% formic acid dissolved in equal parts of water and glycerin. (3) Ranvier (89) acidifies with fresh lemon juice filtered through flannel, then treats with a 1% solution of gold chlorid (quarter of an hour or longer), and finally either places the specimen in water acidulated with acetic acid (1 drop to 30 c.c. water) and subjects it to light for one or two days, or reduces it in the dark, as in Löwit's method, in a solution of 1 vol. formic acid and 2 vols. water. (4) Gerlach uses the double chlorid of gold and potassium, but in weaker concentrations than a 1% solution, otherwise he continues as in the method of Cohnheim. (5) Golgi (94) also uses the same double chlorid, but acidifies with 0.5% arsenious acid, and then reduces in 1% arsenious acid in the sunlight.

**183.** Gad recommends the method of Chr. Sihler for demonstrating the nerve-endings in striated muscle: Muscle bundles of the thickness of a goose quill are first placed for eighteen hours in a solution composed of acetic acid 1 vol., glycerin 1 vol., and 1% solution of chloral hydrate 6 vols., and then teased in pure glycerin. Afterward they are placed in a mixture of Ehrlich's hematoxylin 1 vol., glycerin 1 vol., and 1% chloral hydrate solution 6 vols., in which the specimens are allowed to remain for from three to ten days. The pieces are now placed in glycerin acidified with acetic acid (solution No. 1), in which the color becomes differentiated, the nerves and nerve-endings in the muscles and vessels being deeply stained, while the remaining portion of the specimen becomes decolorized. After having stained with No. 2, the pieces may be preserved in pure glycerin, to be treated later with acetic acid (solution No. 1).

These methods are most successful in reptilia and mammalia, more difficult in the other classes of vertebrate animals.

The gold-impregnation of the nerve-endings in nonstriated and heart muscle yields less reliable results, Golgi's chrome-silver method or the Ehrlich methylene-blue method being better (*vid.* Technic for Central Nervous System).

## SPECIAL HISTOLOGY.

---

### I. BLOOD AND BLOOD-FORMING ORGANS, HEART, BLOOD-VESSELS, AND LYMPH-VESSELS.

#### A. BLOOD AND LYMPH.

##### 1. FORMATION OF BLOOD.

EARLY in the development of the embryo there appear in a portion of the extra-embryonic area of the blastoderm, known as the *area vasculosa*, definite masses of cells, derived from the mesenchyme, and spoken of as *blood islands*, which are intimately connected with the formation of the blood. If these blood islands be examined at a certain stage, free cells are seen lying in their center, apparently derived from the central cells of the islands; the cells surrounding them represent the elements which later go to form the primitive vascular walls. The free elements are the first blood-cells of the embryo. The blood-cells thus developed enter the circulation by means of blood channels formed by the confluence of the blood islands. These grow toward the embryo and later join the large central vessels. The origin of these blood islands is still an open question. Some authors contend that they arise from the mesoblast (P. Mayer, 87, 93; K. Ziegler; van der Stricht, 92), others that they are of entodermic origin (Kupffer, 78; Gensch; Rückert, 88; C. K. Hoffmann, 93, I; 93, II; Mehnert, 96). At a certain period the embryonic blood consists principally of nucleated red cells, which proliferate in the circulation by indirect division. The colorless blood-cells, the development of which is not yet fully understood, appear later. It is possible that they also are elements of the blood islands, which do not contain any hemoglobin. In a later period of embryonic life the liver becomes a blood-forming organ. Recent investigations have, however, shown that it does not take a direct part in the formation of the blood, but only serves as an area in which the blood-corpuses proliferate during their slow passage through its vessels. The blind sac-like endings of the venous capillaries seem to be particularly adapted for this purpose, as in them the blood current stagnates, and it is here that the greater number of blood-cells reveal mitotic figures. The

newly formed elements are finally swept away by the blood stream and enter the general circulation (van der Stricht, 92; v. Kostan-ecki, 92, III). Many investigators believe that the red blood-cells have an entirely different origin in the liver—namely, from the large polynuclear, giant cells, which are thought to arise either from the cells of the capillaries or from the liver-cells (Kuborn, M. Schmidt).

Late in fetal life and in the adult, the red bone-marrow and the spleen are the organs which form the red blood-cells. The lymphatic glands and the spleen produce the white blood-cells. In addition to the nucleated red corpuscles which are present up to a certain stage of development, nonnucleated red blood-cells also appear. The number of the latter increases, until finally they are found almost exclusively in the blood of the new-born infant.

The blood of the adult consists of a clear, fluid, coagulable substance, the *blood plasma*, and of formed elements suspended in this intercellular substance. The formed elements are: (a) Red blood-corpuscles (erythrocytes); (b) white blood-corpuscles (leucocytes); and (c) the blood platelets of Bizzozero (82), Hayem. Besides these, there are present particles of fat, and, as H. F. Müller (96) has recently shown, also hemokonia.

## 2. RED BLOOD-CORPUSCLES.

In man and nearly all mammalia the great majority of the red blood-corpuscles are nonnucleated, biconcave circular discs with rounded edges. They have smooth surfaces, are transparent, pale yellow in color, and very elastic. No method has as yet been devised to demonstrate a nucleus in these cells, and there is no doubt that the red blood-discs of the human adult and of mammalia are devoid, in the histologic sense, of a nucleus capable of differentiation (compare Lavdowsky; Arnold, 96). They are therefore peculiarly modified cells.

If fresh blood be left for some time undisturbed, the blood-discs adhere to each other by their flattened surfaces, grouping themselves in *rouleaux*.

By certain reagents the clear and transparent contents of the blood-corpuscles can be separated into two substances—a staining and a nonstaining. The first consists of the blood pigment, or *hemoglobin*, which can be dissolved; the second of a colorless substance, the *stroma*, which presents itself in various forms (protoplasm of the cell).

Hemoglobin is a very complex proteid which may be decomposed into a globulin and a pigment *hematin*. The hemoglobin of the majority of animals crystallizes in the form of rhombic prisms; in the squirrel, however, in hexagonal plates, and in the guinea-pig in tetrahedra. Hematin combines with hydrochloric acid to form *hemin*, or *Teichmann's* crystals, of brownish color, rhombic shape, and microscopic size. They are of much value in lego-medical

work, since they may be obtained from blood, no matter how old, and are characteristic of hemoglobin. They may be obtained from very small quantities of blood pigment.

The stroma probably contains the hemoglobin in solution. The question as to whether the erythrocytes possess a membrane or not is difficult to answer, although in all probability they do (Lavdowsky).

If a small drop of blood pressed from a small puncture is placed on a slide and covered with a cover-glass, the red blood-cells soon become changed. This is due to the evaporation of water in the blood plasma, causing an increased concentration of the sodium chloride contained, which in turn draws water from the blood-cells. The shrinkage which follows produces a characteristic

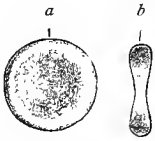


Fig. 145.—Human red blood-cells;  $\times 1500$ : *a*, As seen from the surface; *b*, as seen from the edge.

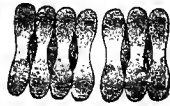

Fig. 146.—So-called "rouleau" formation of human erythrocytes;  $\times 1500$ .



Fig. 147.—Hemin, or Teichmann's crystals, from blood stains on a cloth.



Fig. 148.—"Crenated" human red blood-cells;  $\times 1500$ .

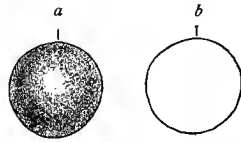


Fig. 149.—Red blood-corpuses subjected to the action of water;  $\times 1500$ : *a*, Spheric blood-cell; *b*, "blood shadow."

change in the form of the cells, which assume a crenated or stellate shape. The red blood-cells of blood mounted in normal salt become crenated in a short time for the same reason. Red blood-cells are variously affected by different fluids. In water they become spheric and lose their hemoglobin by solution. Their remains then appear as clear, spheric, indistinct *blood shadows*, which may, however, be again rendered distinct by staining with iodine. Dilute acetic acid has a similar but more rapid action, with this peculiarity, that before becoming paler the blood-cells momentarily assume a darker hue. Bile, even when taken from the animal furnishing the blood, exerts a peculiar influence upon the red blood-cells; they first become distended, and then suddenly appear to explode into

small fragments. Dilute solutions of tannic acid cause the hemoglobin to leave the blood-cells, and coagulate in the form of a small globule at the edge of the blood-cell. In alkalis of moderate strength the red blood-cells break down in a few moments.

Besides the disc-shaped red blood-cells, every well-made preparation shows a few small, spheric, nonnucleated cells containing hemoglobin. These, however, have received as yet but little attention.

M. Bethe makes the statement that human blood and the blood of mammalia contain corpuscles of different sizes, bearing a definite numerical relationship to each other. "If they be classified according to their size, and the percentage of each class be calculated, the result will show a nearly constant proportional graphic curve varying but slightly, according

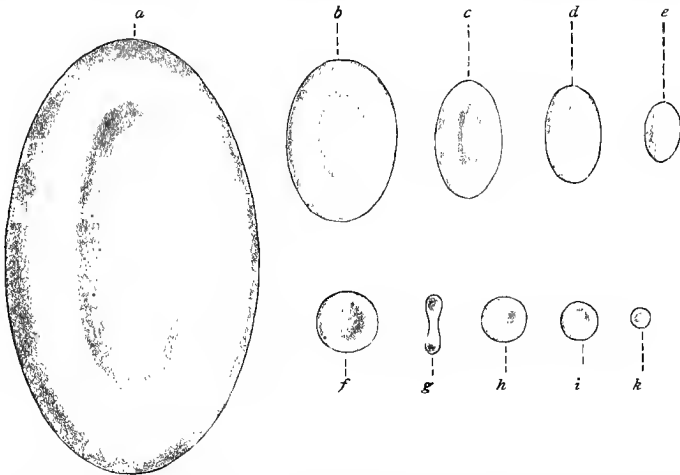


Fig. 150.—Red blood-corpuscles from various vertebrate animals;  $\times 1000$  (Welker's model): *a*, From proteus (Olm); *b*, from frog; *c*, from lizard; *d*, from sparrow; *e*, from camel; *f* and *g*, from man; *h*, from myoxus glis; *i*, from goat; *k*, from musk-deer.

to the animal species." According to M. Bethe, dry preparations of human and animal blood may be distinguished from each other, with the exception of the blood of the guinea-pig which presents a curve identical with that of human blood.

The red blood-cells of mammalia, excepting those of the llama and camel species, are in shape and structure similar to those of man. The red blood-cells of the llama and camel have the shape of an ellipsoid, flattened at its short axis, but also nonnucleated.

We have already made mention of the fact that the embryonal erythrocytes are nucleated; the question now arises as to how, in the course of their development, they lose their nuclei. Three possibilities confront us: First, either the embryonal blood-cells are destroyed and gradually replaced by previously existing nonnucle-

ated elements; or, second, the nonnucleated red cells are formed from the nucleated by an absorption of the nucleus (or what appears to be such to the eye of the observer, Arnold, 96); or, finally, the nucleus is extruded from the original nucleated cell. According to recent investigations (Howell) the third possibility represents the change as it actually takes place.

In all vertebrate animals except mammalia, the red blood-corpuscles are nucleated. They are elliptic discs with a biconvex center corresponding to the position of the nucleus. The blood-cells of the amphibia (frog) are well adapted for study on account of their size. They are long and, as a rule, contain an elongated nucleus with a coarse, dense chromatin framework, which gives them an almost homogeneous appearance. The cell-body may be divided, as in mammalia, into stroma and hemoglobin. When subjected to certain reagents, the contour of the cells appears double and sharply defined. This condition is, however, no proof of the existence of a membrane; yet, as modern observers have demonstrated, a membrane may be totally or partly isolated (Lavdowsky). The blood-cells of birds, reptiles and fishes are similarly constructed.

The diameter of the erythrocytes varies greatly in different vertebrate animals, but is constant in each species. We append a table of their number in a cubic millimeter and size in man and certain animals as compiled by Rollett (71, II) and M. Bethe:

SPECIES.	SIZE.	NO. IN CUBIC MILLIMETER.
Man . . . . . ( <i>Homo</i> ) . . . . .	7.2-7.8 $\mu$ . . . . .	5,000,000
Monkey . . . . . ( <i>Cercopith. ruber</i> ) . . . . .	7 $\mu$ . . . . .	6,355,000
Hare . . . . . ( <i>Lepus cuniculus</i> ) . . . . .	7.16 . . . . .	6,410,000
Guinea-pig . . . . . ( <i>Cavia cob.</i> ) . . . . .	7.48 . . . . .	5,859,500
Dog . . . . . ( <i>Canis fam.</i> ) . . . . .	7.2 . . . . .	6,650,000
Cat . . . . . ( <i>Felis dom.</i> ) . . . . .	6.2 . . . . .	9,900,000
Horse . . . . . ( <i>Equus cab.</i> ) . . . . .	5.58 . . . . .	7,403,500
Musk-deer . . . . . ( <i>Moschus jav.</i> ) . . . . .	2.5 . . . . .	
Spanish goat . . . . . ( <i>Capra his.</i> ) . . . . .	4.25 . . . . .	19,000,000
Domestic chaffinch . . . . . ( <i>Fringilla dom.</i> ) . . . . .	Length, 11.9 Breadth, 6.8	
Dove . . . . . ( <i>Columba</i> ) . . . . .	L. 14.7 . . . . . B. 6.5	2,010,000
Chicken . . . . . ( <i>Gallus dom.</i> ) . . . . .	L. 12.1 . . . . . B. 7.2	
Duck . . . . . ( <i>Anas bosch.</i> ) . . . . .	L. 12.9 . . . . . B. 8.0	
Tortoise . . . . . ( <i>Testudo græca</i> ) . . . . .	L. 21.2 . . . . . B. 12.45	629,000
Lizard . . . . . ( <i>Lacerta agil.</i> ) . . . . .	L. 15.75 . . . . . B. 9.1	1,292,000
Snake . . . . . ( <i>Coluber natr.</i> ) . . . . .	L. 22.0 . . . . . B. 13.0	829,400
Frog . . . . . ( <i>Rana temp.</i> ) . . . . .	L. 22.3 . . . . . B. 15.7	393,200
Toad . . . . . ( <i>Bufo vulg.</i> ) . . . . .	L. 21.8 . . . . . B. 15.9	389,000
Triton . . . . . ( <i>Triton crist.</i> ) . . . . .	L. 29.3 . . . . . B. 19.5	103,000

SPECIES.	SIZE.	NO. IN CUBIC MILLI-METER.
Salamander . . . . . ( <i>Salamandra mac.</i> ) . . . . .	Length, 37.8 Breadth, 23.8	. . . . . 80,000
	( <i>Proteus angu.</i> ) . . . . .	
	L. 58	. . . . . 35,000
	B. 35	
Sturgeon . . . . . ( <i>Acipenser St.</i> ) . . . . .	L. 13.4	
	B. 10.4	
Carp . . . . . ( <i>Cyprinus Gobio</i> ) . . . . .	L. 17.7	
	B. 10.1	

3. WHITE BLOOD-CORPUSCLES.

The white blood-cells contain no hemoglobin and are nucleated elements which, under certain conditions, possess ameboid movement. Their size varies from 5  $\mu$  to 10  $\mu$ , and they are less numerous than the red blood-corpuses, one white blood-cell to from three hundred to five hundred red cells being a normal proportion. In

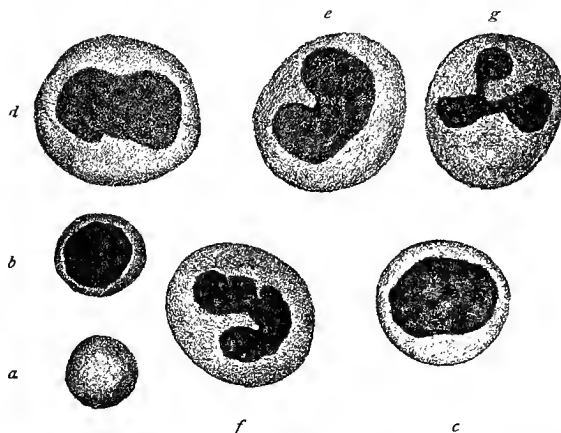


Fig. 151.—From the normal blood of man;  $\times 1200$  (from dry preparation of H. F. Müller): *a*, Red blood-cell; *b*, lymphocyte; *c* and *d*, mononuclear leucocytes; *e*, transitional leucocyte; *f* and *g*, leucocytes with polymorphous nuclei.

the normal blood the white blood-cells vary in shape, and the following varieties are distinguished: (1) Small and large lymphocytes; (2) mononuclear leucocytes; (3) transitional leucocytes; (4) leucocytes, either polymorphonuclear or polynuclear.

The lymphocytes form about 20% of the white blood-cells. They vary in size from 5  $\mu$  to 7.5  $\mu$  and possess a relatively large nucleus, which stains rather deeply, surrounded by a narrow zone of protoplasm.

The leucocytes vary in size from 7  $\mu$  to 10  $\mu$ . The mononuclear leucocytes, constituting about 2% to 4% of the white blood-cells, have a nearly round or oval nucleus, which usually does not stain very deeply, and which is relatively smaller than that of the lymphocytes. The transitional leucocytes, forming also about 2% to

4% of the white blood-cells, are developed from the mononuclear variety and represent transitional stages in the development of mononuclear leucocytes to those with polymorphous nuclei. The nucleus in the transitional form is similar in size and structure to that of the mononuclear variety, but of a more or less pronounced horse-shoe-shape. The leucocytes with polymorphous nuclei, developed from the transitional forms, are very numerous in the blood, forming about 70% of the entire number of white blood-cells. They are also the cells which show the most active ameboid movement when examined on the warm stage. They possess variously lobulated nuclei, the several nuclear masses often being united by delicate threads of nuclear substance. A leucocyte with a polymorphous nucleus becomes a polynuclear cell in case the bridges of nuclear substance uniting the several lobules of the nucleus break through. In the protoplasm of the transitional leucocytes, the polymorphonuclear, and the polynuclear forms are found fine and coarse granules. Our knowledge of these granules has, however,

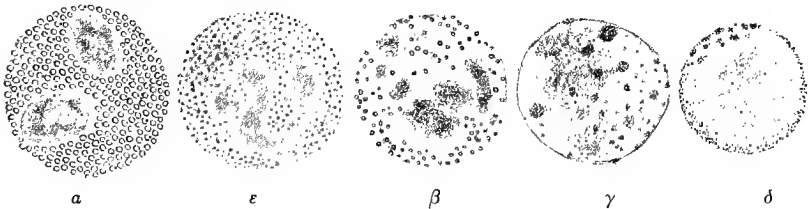


Fig. 152.—Ehrlich's leucocytic granules;  $\times 1800$  (from preparations of H. F. Müller):  $\alpha$ , Acidophile or eosinophile granules, relatively large and regularly distributed;  $\epsilon$ , neutrophile granules;  $\beta$ , amphophile granules, few in number and irregularly distributed;  $\gamma$ , mast cells with granules of various sizes;  $\delta$ , basophile granules. ( $\alpha$ ,  $\delta$ , and  $\epsilon$ , From the normal blood;  $\gamma$ , from human leukemic blood;  $\beta$ , from the blood of guinea-pig.)

been greatly extended since Ehrlich has shown that the granules of leucocytes show specific reactions toward certain anilin stains, or combinations of such stains. He divides the granules of the leucocytes into five classes which he terms respectively  $\alpha$ -,  $\beta$ -,  $\delta$ -,  $\gamma$ -, and  $\epsilon$ -granules. In human blood are found the  $\alpha$ -granules, which show an affinity for acid-anilin stains, are therefore known as acidophile granules, and, since they are most readily stained in eosin, are generally spoken of as *eosinophile* granules. In normal blood from 1% to 4% of the polymorphonuclear leucocytes and now and then a transitional cell have eosinophile granules. The granules are coarse and stain bright red in eosin. Nearly all the leucocytes with granules (from 65% to 68% of all white blood-cells) have  $\epsilon$ -granules or, since they are stained in color mixtures formed by a combination of acid and basic anilin stains, *neutrophile* granules. The neutrophile granules are much finer than the eosinophile and are not stained in acid stains. The  $\gamma$ - and  $\delta$ -granules are stained in basic anilin stains, and are known as *basophile* granules. They are coarse and

irregular, and the leucocytes containing them form from 0.5 % to 1 % of the white blood-cells.

The polymorphism of the leucocyte-nucleus has induced many investigators to advance the theory that a direct division takes place (fragmentation—Arnold, Löwit). Flemming (91, III), however, succeeded in demonstrating that true mitotic processes actually take place, so that in this respect there really exists no difference between leucocytes and other cells (compare also H. F. Müller, 89, 91). It is only in the formation of polynuclear leucocytes that the polymorphous nucleus sometimes undergoes a fragmentation process which results in several parts. But even in this case pluripolar mitoses have been observed. A division of the cell-body subsequent to that of the nucleus is lacking in the processes just described. As a result a single cell with several nuclei is formed (polykaryocyte). The fate of such cells is still in doubt.

The extraordinary motility which most leucocytes possess, is in great part responsible for their wide distribution, even outside of the vascular system. They have the power of creeping through the walls of the capillaries (diapedesis, Cohnheim 67, I), and of penetrating into the smallest connective-tissue clefts, between the cells of epithelia, etc., whence they either pass on (migratory cells) or remain stationary for a time. An important function falls to the lot of the leucocytes in the absorption of superfluous tissue particles or in the removal of foreign bodies from certain regions of the body. In the first case they take part in a process of tissue-disintegration; in the second, they take up the particles by means of their pseudopodia for the purpose either of assimilation or of removal (phagocytes). It may be readily understood that the latter function of the leucocytes is of the greatest importance in certain pathologic processes.

It is somewhat venturesome at the present state of our knowledge to make definite statements as to the origin in postembryonic life of the various forms of white blood-cells above described. The following statement, however, seems warranted from the evidence at hand.

The lymphocytes would seem to be developed in the meshes of adenoid tissue, especially in the so-called *germ centers* of Flemming, in the adenoid tissue of lymph-glands and lymph-follicles (see under these). Here the cells undergo active karyokinetic division, but where the cells which pass through the process originate is a matter concerning which there is a difference of opinion. Some investigators believe that they penetrate the germ centers with the lymph, and find there a suitable place for division. Again, others see in Flemming's germ centers permanent organs whose elements remain stationary and supply the blood with a continuous quota of lymphocytes. Be this as it may, the fact remains that the germ centers are the most important regions for the formation of lymphocytes. From these they pass out with the lymph current into the blood

circulation, there to enter upon the functions which they are called upon to perform. The leucocytes with neutrophile granules are probably developed in the blood and lymph from mononuclear leucocytes which have their origin in the spleen pulp, possibly also in the bone-marrow. The leucocytes of circulating blood with eosinophile granules in all probability come from mononuclear cells with such granules found in bone-marrow. Under certain conditions it would seem that they also develop in connective tissue. The leucocytes with the basophile granules probably enter the circulation from the connective tissue of certain regions. The lymphocytes and leucocytes found in the blood are also found in the lymph-vessels and lymph-spaces.

#### 4. BLOOD PLATELETS AND BLOOD PLASMA.

The third element of the blood is the "blood platelets." They are extremely delicate and transient structures, whose existence in the living blood was denied for a long time by many investigators, but whose presence in the wing vessels of the living bat was conclusively demonstrated by Bizzozero (84). They are colorless (free from hemoglobin), about  $3 \mu$  in diameter, round, and are separated by treatment with a 10% saline solution into a hyaline and a granular substance. No more can be said about the function of these structures than that they have to do with the coagulation of the blood. They are present in the blood to the extent of about two hundred thousand in every cubic millimeter—*i. e.*, their relation to the red blood-cells is as 1 to 25 or 40. The genetic relationship of the platelets to the other elements of the blood has not yet been determined. Hayem regards them as hematoblasts, while Arnold (96) gives to them an erythrocytic origin, and other authors consider them the remains of the nuclei of broken-down polynuclear leucocytes, which view seems most in accord with our present knowledge of their mode of development.

H. F. Müller (96) found in the blood of healthy and diseased individuals highly refractive, colorless, and round (seldom rod-like) bodies, which he terms "hemokonia." Their numbers vary, although they are normal constituents of the blood. Their nature and origin are obscure. They do not dissolve in acetic acid, nor are they blackened by osmic acid. The latter would seem to indicate that they do not consist of ordinary fat substance, although they are probably composed of a substance closely allied to fat. They are usually  $1 \mu$  in diameter.

The fluid medium of the blood, the blood plasma, coagulates on leaving the vessels. It may even undergo the same process within the vessels under certain abnormal conditions. As a result an insoluble proteid body, "fibrin," is formed, while the colorless elements of the blood are in part destroyed (Alexander Schmidt).

### 5. BEHAVIOR OF BLOOD-CELLS IN THE BLOOD CURRENT.

In the circulating blood the behavior of the formed elements varies. The more rapid axial current contains very nearly all the erythrocytes, and as a consequence very few are found adjacent to the walls of the vessels. In the peripheral current, on the other hand, are found most of the leucocytes, and in a retarded circulation they are seen to glide along the walls of the vessels. At the bifurcations of the vessels, especially of the capillaries, the erythrocytes are sometimes caught and elongated by the division of the current, the one-half of the cell extending into the one and the other half into the other branch of the vessel, while the corpuscle oscillates back and forth. When again free the cell immediately resumes its original shape. From this it is seen that erythrocytes are very elastic structures. In the smaller vessels and capillaries, especially when the latter are altered by pathologic conditions, the leucocytes may be seen passing out of the vessels, and it would seem that they are able to penetrate through the walls and even through the endothelial cells lining the blood-vessels (compare also Kolossow, 93). First, they send out a fine process, which is probably endowed with a solvent action. This penetrates the wall of the vessel, after which the remainder of the cell pushes its way through slowly.

## B. LYMPHOID TISSUE, LYMPH-NODULES, AND LYMPH-GLANDS.

As to the origin of lymphoid tissue, the lymph-glands, and the spleen, there is still considerable difference of opinion. Most authors believe that these structures are developed from the middle germinal layer (Stöhr, 89; Paneth; J. Schaffer, 91; Tomarkin). Others believe in an entodermic origin (Kupffer, 92; Retterer; Klaatsch; C. K. Hoffmann, 93, II).

The framework of lymphoid tissue is a reticular connective tissue (adenoid connective tissue—His, 61). This consists of a network of fine fibrils and of branched connective-tissue cells. Within its meshes the lymph-cells lie in such numbers and so densely arranged that on microscopic examination the network is entirely covered. Special methods are therefore necessary to bring out the structure of the latter. Lymph tissue may be diffuse, as in the mucous membrane of the air-passages and as in that of the intestinal tract, uterus, etc. (*vid.* Sauer, 96).

Lymphoid tissue may be also sharply defined in the form of round nodules, *simple follicles* or *nodules*. These are either single, *solitary lymph-follicles*, or gathered into groups, *agminated lymph-nodules*. They are found scattered in the mucous membrane of the mouth, pharynx, and intestine. In lymph-nodules also we find the characteristic lymph-cells and the adenoid reticulum. As a rule, the former

are arranged concentrically at the periphery; and in the center of the nodule the reticular tissue usually has wider meshes, and the lymph-cells are less densely placed. (Fig. 153.) In the center of the nodule the cells often show numerous mitoses, and it is here that an active proliferation of the cells takes place. The cells may either remain in the lymph-follicle or the newly formed cells are pushed to the periphery of the nodule, and are then swept into the circulation by the slow lymph current which circulates between the wide meshes of the reticular connective tissue. Flemming (85, II) has called that central part of the nodule containing the proliferating cells the *germ center* or *secondary nodule* (compare p. 175). The germ centers are transitory structures, and are consequently found in different stages of development. They may even be absent for a time.

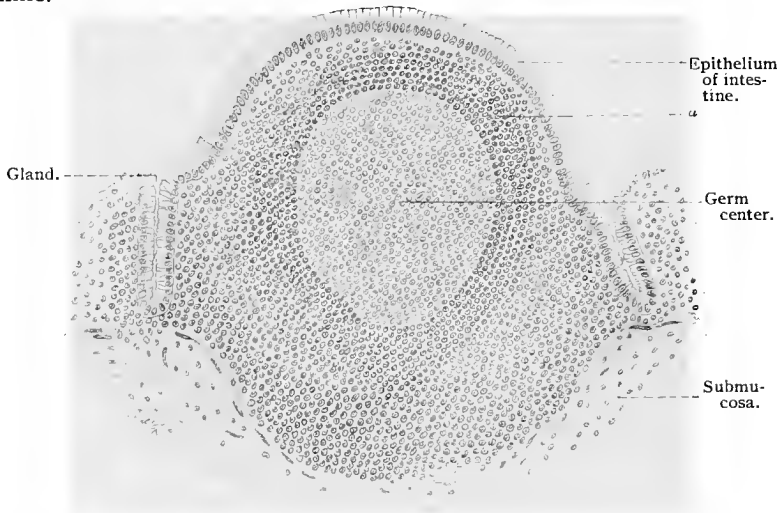


Fig. 153.—A solitary lymph-nodule from the human colon. At *a* is seen the pronounced concentric arrangement of the lymph-cells.

The *lymph-glands* are organs of a more complicated structure, but also consist of lymphoid tissue. They are situated here and there in the course of the lymph-vessel and are widely distributed. Their size varies greatly. In shape they are much like a bean or kidney, and the indentation on one side is known as the *hilum*. The afferent lymph-vessels, the *vasa afferentia*, enter at the convex surface of the organ, while the efferent vessels, the *vasa efferentia*, pass out at the hilum. The whole gland is surrounded by a *capsule* consisting of two layers: the outer is made up of a loose, and the inner of a more compact, connective tissue in which a few smooth muscle-fibers are imbedded. Portions of the inner layer pass into the substance of the gland to form *septa*, or *trabeculae*, by means of which the organ is divided into a number of imperfectly separated compart-

ments. The lymphoid substance of the gland is so distributed that at its periphery a large number of lymph-nodules are placed in dense masses separated from each other by the trabeculæ just described, the *cortical nodules*. The nodules are identical in structure with those mentioned above. They form a peripheral layer which is, however, not clearly defined in the neighborhood of the hilum. This layer is known as the cortex of the lymph-gland. (Fig. 154.) The lymphoid tissue of the interior of the gland, the medullary substance, is in the shape of cords—*medullary cords*. These connect with each other and form a network of lymphoid tissue, in the open spaces of which lie the trabeculæ. At their periphery the nodules and medullary cords gradually pass into a wide-meshed lymphatic tissue, the *lymph-sinus* of the gland, parts of which lie (1) between the capsule and the cortical substance, (2) between the nodules of the latter and the trabeculæ, (3) between the medullary cords and the trabeculæ, and (4) between the medul-

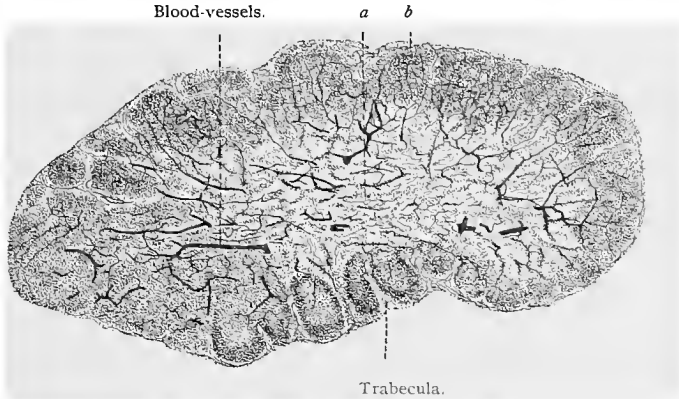


Fig. 154.—Section through a mesenteric lymph-gland of cat, with injected blood-vessels;  $\times 50$ : *a*, Medullary substance; *b*, cortical substance with cortical nodules.

lary substance and the capsule at the hilum. The sinus is therefore intimately connected not only with the capsule, but also with the trabeculæ. At the hilum the loose lymphoid tissue represents a terminal sinus (Toldt).

The inner wall of the capsule and the trabeculæ with their processes are covered by flattened endothelial cells which are continuous with those of the afferent and efferent lymph-vessels. The lymph flows into the gland through the afferent vessels, and passes along into the interior through the spaces offering the least resistance (sinuses). The latter represent those peripheral portions of the nodules and of the medullary cords in which the lymphoid tissue is present in loose arrangement. The lymph consequently envelops not only the lymph-nodules of the cortical substance, but also the medullary cords, and finally streams into the terminal sinus and

then into the efferent channels. As a result the lymph takes with it the newly formed cells of the lymph-nodules and the medullary cords, and passes out much richer in cellular elements than on its entrance.

A large number of arterial blood-vessels enter the lymph-gland through the hilum and penetrate into the interior of the organ through the trabeculæ. After passing through the sinuses they break up into capillaries in the medullary cords or in the lymph-nodules of the cortical substance. The sinuses, then, contain no

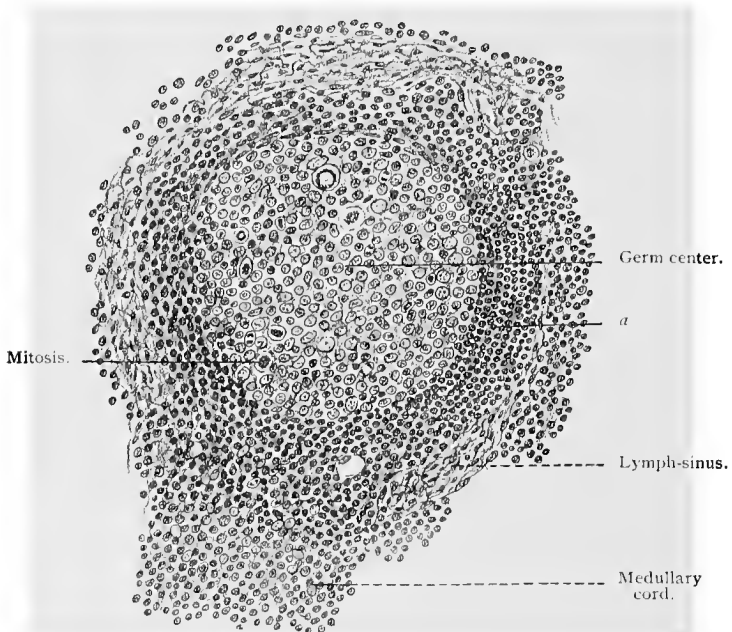


Fig. 155.—From a human lymph-gland;  $\times$  240. At *a* are seen the concentrically arranged cells of the lymph-nodules. (Fixation with Flemming's fluid.)

capillaries. The arterial capillaries pass over into the venous capillaries, and the veins resulting from the union of the latter pass to the periphery of the organ side by side with the arteries.

### C. THE SPLEEN.

The spleen is a blood-forming organ, in which white blood-cells and, in embryonic life and under certain conditions in adult life also, red blood-cells are formed—the former in the adenoid tissue (Malgighian corpuseles) and spleen pulp, the latter only in the spleen pulp.

The spleen is covered by peritoneum, and possesses a capsule

consisting of connective tissue, elastic fibers, and nonstriated muscle-cells. This capsule sends numerous processes or trabeculæ into the interior of the organ, which branch and form a framework in which the vessels, especially the veins, are imbedded. This connective-tissue framework breaks up to form the reticular tissue which constitutes the ground substance of the spleen.

On examining a section of the spleen with the low-power magnifying glass, sections of the trabeculæ, and round or oval masses of cells, having a diameter of about 0.5 mm., and in structure and

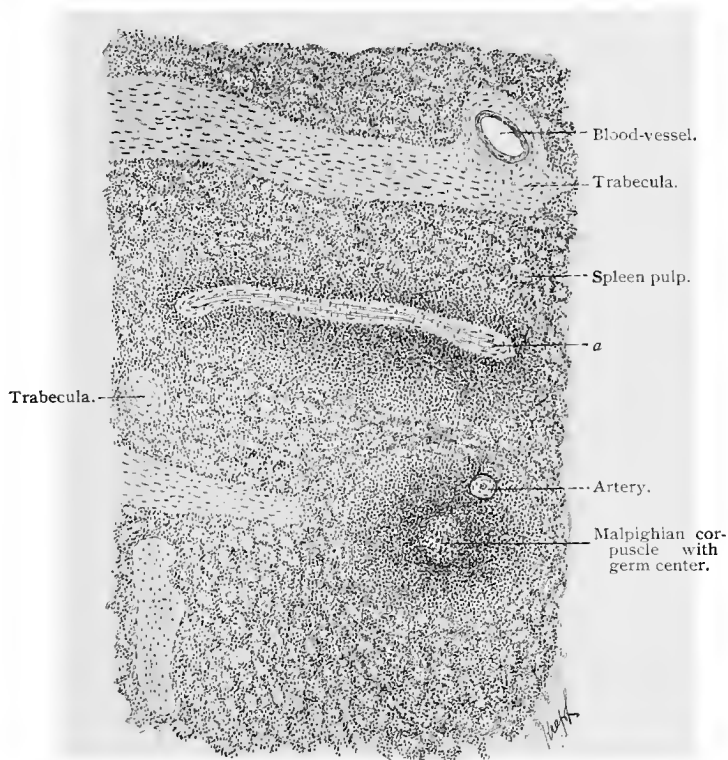


Fig. 156.—Part of a section through the human spleen;  $\times 75$ . (Sublimate fixation.)  
At *a* is an oblong Malpighian body with a blood-vessel.

appearance similar to the lymph-nodules (Malpighian corpuscles), are clearly defined; between and around these structures is a tissue rich in cells, blood-vessels and blood-corpuscles, known as the spleen pulp.

The organ has a very typical blood supply. Its arteries enter at the hilum, or indented surface, and its veins pass out at the same place. On the penetration of the vessels through the capsule, the latter forms sheaths around them (trabeculæ), but as soon as the arteries and veins separate, the trabeculæ envelop the veins alone.

The arteries break up into smaller branches, which in turn divide into a large number of tuft-like groups of arterioles. Soon after their separation from the veins, the adventitia (outer fibrous tissue coat) of the arteries begins to assume a lymphoid character. This lymphoid tissue increases here and there to form true lymphoid nodules, possessing all the characteristics already mentioned—reticular tissue, germ centers, etc. These are the *Malpighian bodies*, or *corpuscles*; they are not very plentifully represented in man. The Malpighian bodies with their germ centers are formative centers for the lymphocytes. The newly formed cells pass into the pulp and mix with its elements, which are then bathed by the blood emptying from the arterial capillaries into the channels of the pulp. The lymphoid sheaths and nodules derive their blood supply from arteries which arise from the lateral branches of the splenic vessels, and which divide into capillaries inside of the lymph sheaths or nodules, and only assume a venous character outside of the lymphoid substance. These vessels constitute the nutritive vascular system of the spleen.

The small arterial branches above mentioned break up into very fine arterioles which gradually lose their lymphoid sheath, so that branches with a diameter of 0.02 mm. no longer possess a lymphoid sheath, but again assume an adventitia of the usual type. The smallest arterioles now pass over into capillaries which are for a time accompanied by the adventitia (capillary sheath), while the terminal branches have the usual structure of the capillary wall and are gradually lost in the meshes of the pulp. (See below.) On the other hand, the beginnings of the venous capillaries may be distinctly seen in the pulp spaces. Groups of these capillaries combine to form larger vessels, which, however, still retain a capillary structure, and these again form small veins which unite to form the larger veins.

Mall, whose recent contributions on the structure of the spleen have greatly extended our knowledge of the microscopic anatomy of this organ, states that the trabecular and vascular systems together outline masses of spleen pulp about 1 mm. in diameter, which he has named *spleen lobules*. Each lobule is bounded by three main interlobular trabeculæ, each of which sends three intralobular trabeculæ into the lobule which communicate with each other in such a manner as to divide the lobule into about ten smaller compartments. An artery enters at one end of the lobule and, passing up through its center, gives off a branch to the spleen pulp found in each of the ten compartments formed by the intralobular trabeculæ. The spleen pulp in these compartments is arranged in the form of anastomosing columns, or cords, to which Mall has given the name of *pulp cords*. The branches of the main intralobular artery, going to each compartment, divide repeatedly; the terminal branches course in the spleen-pulp cords, and in their path give off numerous small side branches which end in small expansions known as the *ampullæ of Thoma*. "The first two-thirds of the ampulla are lined

with spindle-shaped cells lying on a delicate framework of reticulum. Through the last third, at the junction with the vein, no cell boundaries can be demonstrated. In fact, it appears as if this portion of the ampulla were cut up by fibrils of the reticulum passing across it" (Mall). The veins of the lobule enter in a system of venous spaces surrounding the pulp cords. These are in communication with intralobular veins, often associated with intralobular trabeculæ, and the latter empty into the interlobular veins found in some of the interlobular trabeculæ. Mall further states that "the ampullæ and venous plexus have very porous walls, which permit fluids to pass through with great ease and granules only with difficulty. In life the plasma constantly flows through the intercellular spaces of the pulp cords, while the blood-corpuscles keep within fixed channels." The accompanying diagram (Fig. 157), slightly, though immate-

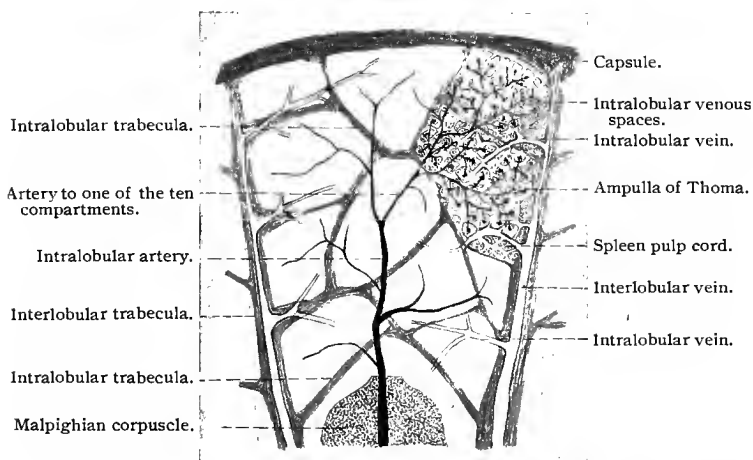


Fig. 157.—Diagram of lobule of the spleen (Mall, "Johns Hopkins Hospital Bulletin," Sept., Oct., 1898).

rially, modified from one given by Mall, shows clearly the trabecular and vascular systems of a spleen lobule.

In larger spleens there may be some two hundred thousand of these lobules. In a dog weighing 10 kg. there are on an average some eighty thousand (Mall).

The splenic pulp consists of a very delicate reticulum, in the meshes of which are found (1) fully developed red blood-cells; (2) now and then nucleated red blood-cells; (3) in many animals giant cells; (4) cells containing red blood-corpuscles and the remains of such, with or without pigment; (5) the different varieties of white blood-cells, especially a relatively large proportion of mononuclear leucocytes. Pigment granules, either extra- or intracellular, also occur in the splenic pulp. The pigment probably originates from disintegrating erythrocytes. Besides these are found, especially in

teased preparations, long, spindle-shaped and flat cells, which are probably derivatives of the connective-tissue cells of the pulp and of the endothelium and muscular fibers of the vessels.

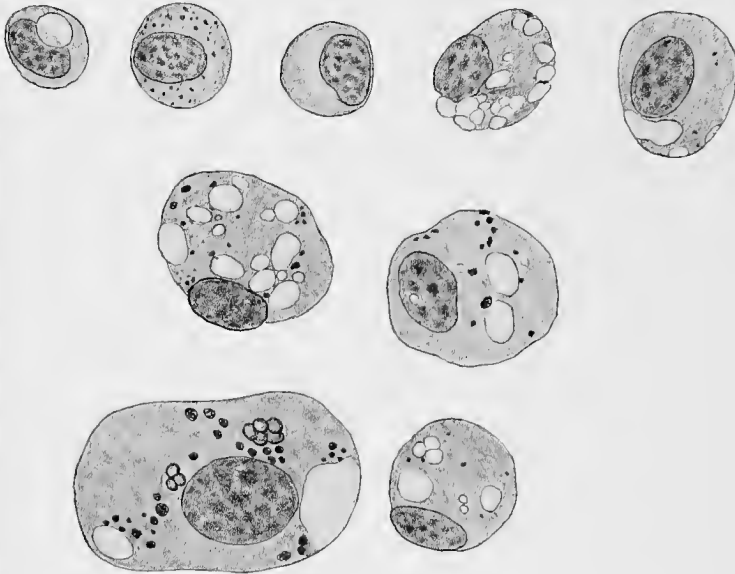


Fig. 158.—Cells containing pigment, blood-corpuscles, and hemic masses from the spleen of dog;  $\times 1800$  (from cover-glass of H. F. Müller).

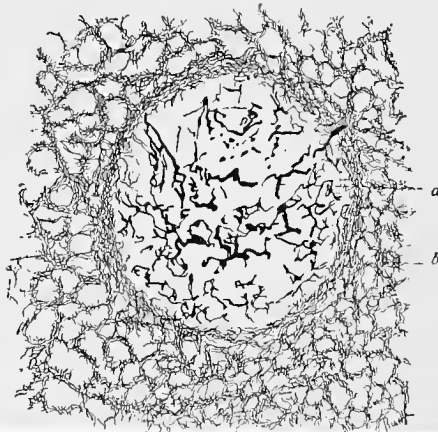


Fig. 159.—From the human spleen;  $\times 80$  (chrome-silver method): *a*, Larger fibers of a Malpighian body; *b*, reticular fibrils (Gitterfasern).

In embryonic life and under certain conditions in postembryonic life (after severe hemorrhage and in certain diseases) red blood-cells are developed in the spleen pulp. The nucleated red blood-cells

from which they develop may lose their nuclei in the spleen pulp or only after entering the circulation (compare Bone-marrow).

By means of certain methods, especially the chrome-silver method (Oppel, 91), a very delicate reticular network—*i. e.*, that surrounding the capillary walls—may be brought to view in the spleen. The fibers composing it have been called by Kupffer *reticular fibers*.

The spleen receives medullated and nonmedullated nerve-fibers; the latter are much more numerous. The medullated nerve-fibers are no doubt the dendrites of sensory neurones. Their mode of ending has, however, not been determined. It is probable that they will be found to terminate in the fibrous-tissue coat of the vessels, and in the trabeculæ and capsule. The nonmedullated nerve-fibers, no doubt the neuraxes of sympathetic neurones, are very numerous; they enter the spleen with the artery and mainly follow its branches. By means of the chrome-silver method, Retzius (92) has shown that in the rabbit and mouse these nerve-fibers follow the vessels, forming plexuses which surround them, the terminal branches of these plexuses terminating in free endings in the muscular coat of the arteries. Here and there a nerve-fiber could be traced into the spleen pulp. The mode of ending of such fibers could, however, not be determined. The nonstriated muscle-cells of the trabeculæ and capsule no doubt also receive their innervation from the nonmedullated nerves (neuraxes of sympathetic neurones).

#### D. THE BONE-MARROW.

The ingrowing periosteal bud which ushers in the process of endochondral ossification constitutes the first trace of an embryonal bone-marrow (compare p. 108). It consists mainly of elements from the periosteum which penetrate with the vascular bud and later form the entire adult bone-marrow. The *red bone-marrow* is formed first. This is present in embryos and young animals, and is developed from the above elements during the process of ossification. As Neumann (82) has shown, the red bone-marrow of the human embryo is first formed in the bones of the extremities and gradually replaced in a proximal direction, so that in the adult it is found only in the proximal epiphyses, in the flat bones and in the bodies of the vertebræ. In the remaining bones and parts of bones the red bone-marrow is replaced by the *yellow bone-marrow* (fat-marrow).

As a result of hunger and certain pathologic conditions the yellow bone-marrow changes into a gelatinous substance, which, however, may again assume its original character.

The red bone-marrow, surrounded by a delicate fibrous-tissue membrane, the *endosteum*, is a tissue consisting of various cellular elements imbedded in a matrix of reticular tissue, similar to the

adenoid reticulum. Aside from these cellular elements, the marrow contains numerous vessels (see below), fixed connective-tissue cells, etc.

The typical cellular elements of red bone-marrow are :

1. *The Marrow-cells, or Myelocytes.*—These are cells, slightly larger than the leucocytes, possessing a relatively large nucleus of round or oval shape, rarely lobular, containing a relatively small amount of chromatin. In the protoplasm of these cells are found (in man) neutrophile granules and now and again small vacuoles. They are said to contain various pigment granules. These cells are not found in normal blood, but are found in circulating blood in certain forms of leukemia, where they may be distinguished from the mononuclear leucocytes partly by their structure, more particu-

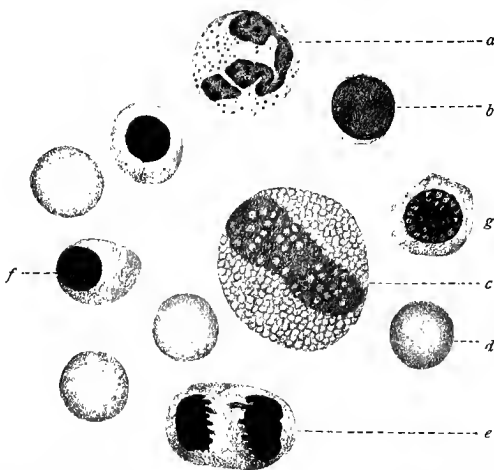


Fig. 160.—Cover-glass preparation from the bone-marrow of dog;  $\times 1200$  (from preparation of H. F. Müller): *a*, Mast-cell; *b*, lymphocyte; *c*, eosinophile cell; *d*, red blood-cell; *e*, erythroblast in process of division; *f*, *f*, normoblast; *g*, erythroblast. Myelocyte not shown in this figure.

larly by the presence of neutrophile granules not found in the mononuclear leucocytes.

2. *Nucleated Red Blood-cells containing Hemoglobin.*—Two varieties of these cells are recognized structurally, with intermediary stages, as one variety is developed from the other. The *erythroblasts*, being genetically the earlier cells, possess relatively large nuclei with distinct chromatin network, surrounded by a protoplasm tinged with hemoglobin, and are often found in a stage of mitosis. The other variety of nucleated red blood-cells, the *normoblasts*, are developed from the erythroblasts. They contain globular nuclei, staining deeply, in which no chromatin network is recognizable, and surrounded by a layer of protoplasm containing hemoglobin. The normoblasts are changed into the nonnucleated

red blood-discs by the extrusion of the nucleus. This process occurs normally in the red bone-marrow, or in the venous spaces of the bone-marrow (see below). In certain pathologic conditions, nucleated red blood-cells are found in the circulation.

3. *Cells with Eosinophile Granules.*—In the red bone-marrow are found numerous eosinophile (acidophile) cells, some with round or oval nuclei (mononuclear eosinophile cells), others with horse-shoe-shaped nuclei (transitional eosinophile cells), and still others with polymorphous nuclei. The latter, which are the most numerous, are no doubt the mature cells, and are identical with those elements of the blood having the same structure.

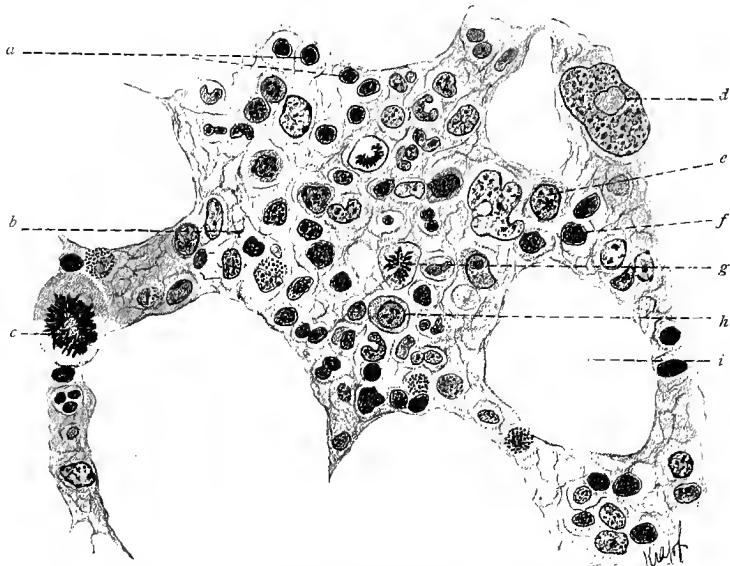


Fig. 161.—From a section through human red bone-marrow;  $\times 680$ . Technic No. 216: *a, f*, Normoblasts; *b*, reticulum; *c*, mitosis in giant cell; *d*, giant cell; *e, h*, myelocytes; *g*, mitosis; *i*, space containing fat-cells.

4. The various forms of *leucocytes* and the *lymphocytes* found in blood and lymph.

5. The *giant cells* (myeloplaxes), which are situated in the center of the marrow, and contain simple or polymorphous nuclei, or lie adjacent to the bone in the form of osteoclasts, which are, as a rule, polynuclear (compare p. 111). The physiologic significance of the giant cells is still obscure. They probably originate from single leucocytes by an increase in size of the latter, and not, as many assume, from a fusing of several leucocytes. The giant cells are endowed with ameboid movement, and often act as phagocytes (the latter quality is denied them by M. Heidenhain, 94).

M. Heidenhain (94) has made a particular study of the giant cells. According to him the nuclei of these cells take the form of perforated hollow spheres whose thick walls contain "endoplasm." The latter is continuous with the remaining protoplasm of the cell, the "exoplasm" through the "perforating canals" of the nuclear wall. The exoplasm is arranged in three concentric layers, separated from each other by membranes, the external membrane of the outer zone being the membrane of the cell. The outer layer or marginal zone is of a transient nature, but is always renewed by the cell. Thus, the cell-membrane is replaced by the secondary membrane situated between the second and third zone. According to the same author the functions of the giant cells appear to consist in "the selection and elaboration of certain albuminoid substances of the lymph and blood currents, which are later returned to the circulation." The number of centrosomes occurring in the mononuclear giant cells of the bone-marrow is very large, and in some cases, as in a pluripolar mitosis, may even exceed one hundred in number.

The distribution of the blood-vessels in the bone-marrow is as follows: On entering the bone the nutrient arteries divide into a large number of small branches, which then break up into small arterial capillaries. The latter pass over into relatively large venous capillaries, whose walls either finally disappear entirely or are broken through in many places so that the venous blood pours into the spaces of the red bone-marrow where the current is very slow. The blood passes out by means of smaller veins formed by the confluence of the capillaries which collect the blood from the marrow. It is worth mentioning that the venous vessels, while inside of the bone-marrow, possess no valves; but, on the other hand, they have an unusually large number of valves immediately after leaving the bone.

Yellow bone-marrow is derived from red bone-marrow by a change of the marrow-cells into fat-cells. The gelatinous marrow, on the contrary, is characterized by the small quantity of fat which it contains. Neither the yellow nor the gelatinous bone-marrow is a blood-forming organ (compare Neumann, 90; Bizzozero, 91; H. F. Müller, 91; van der Stricht, 92).

## E. THE THYMUS GLAND.

The thymus gland is usually considered as belonging to the lymphoid organs, although in its earliest development it resembles an epithelial, glandular structure. In the epithelial stage, this gland develops from the entoderm of the second and third gill clefts. Mesodermic cells grow into this epithelial structure, proliferate and then differentiate into a tissue resembling adenoid tissue. It retains this structure until about the end of the second year after birth, when it slowly begins to retrograde into a mass of fibrous tissue, adipose tissue, and cellular debris, which structure it presents in adult life.

By means of connective-tissue septa, the thymus is divided into larger lobes, and these again into smaller lobes, until finally a number of very small, almost spheric structures are formed—the lobules of the gland. These consist of a reticular connective tissue much more delicate at the periphery than at the center of the

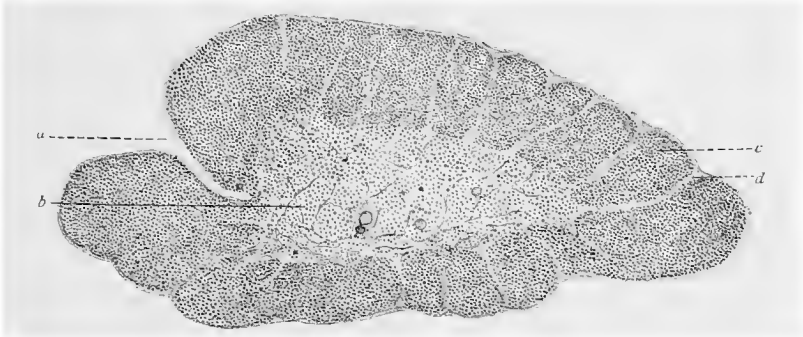

Fig. 162.—A small lobule from the thymus of child, with well-developed cortex, presenting a structure similar to that of the cortex of a lymph-gland;  $\times 60$ : *a*, Hilus; *b*, medullary substance; *c*, cortical substance; *d*, trabecula.

lobule. In the meshes of the reticular tissue are cellular elements, in structure similar to the lymphocytes, which are more numerous at the periphery of the lobule than at its center, so that we may here speak of the lobule as divided into a cortical and a medullary portion. The latter is usually entirely surrounded by the cortical substance, but may penetrate to the periphery of the lobule, allowing the blood-vessels to enter and leave at this point. In the cortical substance occur changes which result in the formation of structures closely resembling the cortical nodules of lymph-glands.

Until recently, little was known of the significance of this organ. A careful study revealed a similarity between certain cellular elements of the thymus and the constituents of the blood-forming organs,—a similarity still more striking from the presence of nucleated red blood-cells in the thymus. Logically, then, the embryonal thymus is to be regarded as one of the blood-forming organs (Schaffer, 93, I). The meshes of the capillary network are much wider in the medullary than in the cortical substance of the




Fig. 163.—Hassal's corpuscle and a small portion of medullary substance, showing reticulum and cells, from thymus of a child ten days old.

lobules, but small arteries also penetrate directly into the cortex. The lymphatics, concerning the origin of which nothing certain is known, pass out side by side with the arteries. It is probable that the peripheral looser portion of the cortex represents a lymph-sinus.

During embryonic life from the fourth month on and for some time after birth, there are found in the thymus peculiar epithelial bodies, known as the *corpuscles of Hassal*. They are spheric structures, about 0.1 mm. in diameter, whose periphery shows a concentric arrangement of the epithelial cells. In their central portions are found a few nuclear and cellular fragments. These bodies occur only in the thymus gland. They are remnants of the primary epithelial, glandular structure of the thymus, and are formed by an ingrowth of mesoderm which breaks down the epithelium into small irregular masses, mechanically compressed by the proliferating mesoderm.

## II. THE CIRCULATORY SYSTEM.

THE walls of the blood-vessels vary in structure in the different divisions of the vascular system. All the vessels, including the heart, possess an inner endothelial lining. In addition to this, the larger vessels are provided with other layers, which consist, on the one hand, of connective and elastic tissue and, on the other, of non-striated muscle-fibers. The vessels are also richly supplied with nerves, that form plexuses in which ganglion cells are sometimes found, and in the larger vessels the outer layer is honeycombed by nutrient blood-vessels, called *vasa vasorum*. In the heart, the muscular tissue is especially well developed. According to the structure of the vessels, we distinguish, in both arteries and veins, large, medium-sized, small, and precapillary vessels, and finally, the capillaries themselves. The latter connect the arterial and venous precapillary vessels. In the lymphatic system we must further distinguish between the larger lymph-vessels, the sinuses, and the capillaries.

### A. THE VASCULAR SYSTEM.

#### 1. THE HEART.

In the heart there are recognized three main coats—the endocardium, the myocardium, and the pericardium or epicardium.

The *endocardium* consists of plate-like endothelial cells, with very irregular outlines. Beneath this endothelial layer is a thin membrane composed of unstriated muscle-cells, together with a small number of connective-tissue and elastic fibers. Below this is a somewhat thicker and looser layer of elastic tissue connected externally with the myocardium. Between the two layers are found, here and there, traces of a layer of *Purkinje's fibers* (compare p.

132). Purkinje's fibers are found in the heart of many mammalia, although absent in the heart of the human adult.

The *auriculoventricular valves* of the heart represent, in general, a duplication of the endocardium. The layer of smooth muscle-fibers found in the latter is better developed on the auricular surface, while the elastic tissue is more prominent on the ventricular surface. At the points of insertion of the *chordæ tendineæ* the connective-tissue layer is strongly developed and assumes a tendon-like consistency. The *semilunar valves* of the aorta and pulmonary artery have a similar structure. In the nodules of these valves the elastic fibers are especially dense in their arrangement.

The *myocardium* is made up of the heart muscle-cells already described (*vid.* p 132). Between the heart muscle-fibers and bundles of such fibers are thin layers of fibrous connective tissue containing a network of capillaries. The myocardium of the auricles may be divided into two layers, of which the outer is common to both auricles; the heart muscle-fibers of this layer have a nearly circular arrangement. Three layers of muscle-fibers are met with in a longitudinal section through the ventricular wall, the outer and inner being chiefly longitudinal in direction, although not exactly parallel. In the left ventricle the outer layer is very strongly developed. The musculature of the auricles is almost completely separated from that of the ventricles by means of the *annulus fibrosus atrioventricularis*, which consists in the adult of connective tissue containing numerous delicate and densely interwoven elastic fibers.

The *pericardium* consists of a visceral layer, the *epicardium*, adhering closely to the myocardium, and a parietal layer (pericardium), loosely surrounding the heart and continuous at the upper portion of the heart with the visceral layer. Between the two layers is the pericardial cavity, containing a small quantity of a serous fluid—the pericardial fluid. In the visceral layer (the epicardium) we find a connective-tissue stroma covered by flattened endothelial cells. A similar structure occurs also in the parietal layer, although here the connective-tissue stroma is considerably reinforced. Deposits of fat, in most cases in the neighborhood of the blood-vessels, are sometimes seen between the myocardium and the visceral layer of the pericardium.

According to Seipp, the distribution of the elastic tissue in the heart is as follows: The endocardium of the ventricles contains far more elastic tissue than that of the auricles, especially in the left ventricle, where even fenestrated membranes may be present. In the myocardium of the ventricles there are no elastic fibers aside from those which are found in the adventitia of the contained blood-vessels. In the myocardium of the auricles, on the contrary, such fibers are very numerous and are continuous with the elastic elements in the walls of the great veins. The epicardium also presents elastic fibers in the auricles continuous with those of the great veins emptying into the heart, and in the ventricles continuous with

those in the adventitia of the conus arteriosus. In those portions of the heart-wall containing no muscular tissue the elastic elements of the epicardium are continuous with those of the endocardium. In the new-born the cardiac valves possess no elastic fibers, although they are present in the adult. They are developed on that side of each valve, which, on closing, is the more stretched—for instance, on the auricular side of the auriculoventricular valves.

The heart has a rich blood supply. The capillaries of the myocardium are very numerous, and so closely placed around the muscle bundles that each muscular fiber comes in contact with one or more capillaries. In the endocardium the vessels are confined to the connective tissue. The auriculoventricular valves contain blood-vessels, in contradistinction to the semilunar valves, which are non-vascular, while the chordæ tendinæ are at best very poorly supplied with capillaries.

The coronary arteries, which terminate in the capillaries above mentioned, are terminal arteries in the sense that "the resistance in the anastomosing branches is greater than the blood pressure in the arteries leading to those branches (Pratt, 98). This observer has further shown that the vessels of Thebesius (small veins which open on the endocardial surfaces of the ventricles and auricles and communicate directly with all the chambers of the heart) "open from the ventricles and auricles into a system of fine branches that communicate with the coronary arteries and veins by means of capillaries, and with the veins, but not with the arteries, by passages of somewhat larger size"; so that, although the blood supply through the coronary arteries for a given area of the myocardium is cut off, the heart muscle of this area may receive blood through the vessels of Thebesius.

*Lymphatic networks* have been shown to exist in the endocardium, and their presence in the pericardium is not difficult to demonstrate. Little is known with regard to the lymph-channels of the myocardium.

The nerve supply of the heart includes numerous medullated nerve-fibers, the dendrites of sensory neurones, and numerous non-medullated fibers, the neuraxes of sympathetic neurones. Smirnow (95) described sensory nerve-endings in the endocardium of amphibia and mammalia, which he suggests may be the terminations of the depressor nerve. Dogiel (98) has corroborated and extended these observations, and has described complicated sensory telodendria situated both in the endo- and pericardium. The latter states that, after forming plexuses and undergoing repeated division, the medullated sensory nerves lose their medullary sheaths, the neuraxes further dividing in numerous varicose fibers, variously interwoven and terminating in telodendria, which vary greatly in shape and configuration. These telodendria are surrounded by a granular substance containing branched cells, probably connective-tissue cells, the interlacing branches of which form a framework for the

telodendria. Similar sensory nerve-endings occur in the adventitia of the arteries and veins of the pericardium (Dogiel, 98); and Schemetkin has shown that sensory nerve-endings occur in the adventitia and intima, especially in the latter, of the arch of the aorta and pulmonary arteries. In the heart, under the pericardium on the posterior wall of the auricles and in the sulcus coronarius, are found numerous sympathetic neurones whose cell-bodies are grouped to form sympathetic ganglia. The neuraxes of these sympathetic neurones—varicose, nonmedullated nerve-fibers—form intricate plexuses situated under the pericardium and, penetrating the myocardium, surround the bundles of heart muscle-fibers. From the varicose nerve-fibers constituting these plexuses, fine branches are given off, which terminate on the heart muscle-cells in a manner previously described (see p. 149 and Fig. 127). The cell-bodies of the sympathetic neurones, the neuraxes of which thus terminate on the heart muscle-fibers, are surrounded by end-baskets, the telodendria of small medullated nerve-fibers which reach the heart through the vagi. The slowed and otherwise altered action of the heart-muscle, produced on stimulating directly or indirectly the vagus nerves is therefore due not to a direct action of these nerve-fibers on the heart muscle-cells, but to an altered functional activity produced by vagus stimuli in at least some of the sympathetic neurones situated in the heart, the neuraxes of which convey the impulse to the heart muscle. The heart receives further nerve supply through sympathetic neurones, the cell-bodies of which are situated in the inferior cervical and stellate ganglia, the neuraxes of which enter the heart as the augmentor or accelerator nerves of the heart. The mode of ending of these nerve-fibers has not as yet been fully determined. It may be suggested as quite probable that they terminate on the dendrites of sympathetic neurones, the cell-bodies of which are not inclosed by end-baskets of nerves reaching the heart through the vagi, as above described. It is also possible that they end directly on the heart muscle-cells. The cell-bodies of the sympathetic neurones, the neuraxes of which form the augmentor nerves, are surrounded by the telodendria of small medullated fibers, forming end-baskets, which leave the spinal cord through the anterior roots of the upper dorsal nerves. Besides the nerves here described, nonmedullated nerves (whether the neuraxes of sympathetic neurones, the cell-bodies of which are situated inside or outside of the heart has not been fully determined), form plexuses in the walls of the coronary vessels, terminating, it would seem, on the muscle-cells of the media (vasomotor nerves).

## 2. THE BLOOD-VESSELS.

A cross-section of a blood-vessel shows several coats. The inner consists of flattened endothelial cells, and is common to all vessels. The second varies greatly in thickness, contains most of

the contractile elements of the arterial wall, and is known as the media, or tunica media. Its elastic fibers have in general a circular arrangement and are fused at the inner and outer surfaces to form fenestrated membranes, the lamina elastica interna and externa. Outside of the media lies the adventitia or tunica externa, consisting in the arteries almost entirely of connective tissue and in the veins principally of contractile elements, smooth muscle-fibers. Between the internal elastic membrane and the endothelial layer is a fibrous stratum which varies in structure in the different vessels of larger caliber. This is the subendothelial layer, or the inner fibrous layer, and forms, together with the endothelium, the intima

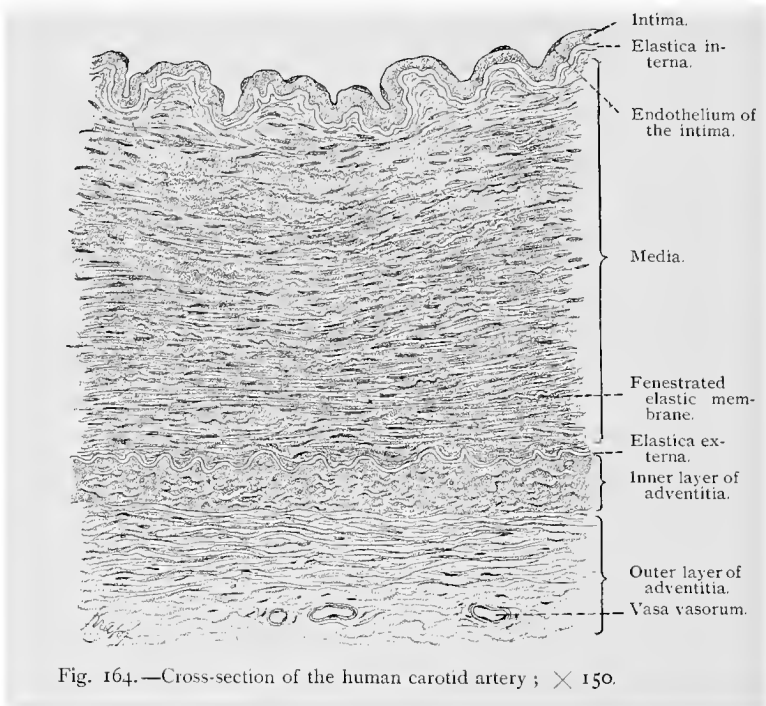


Fig. 164.—Cross-section of the human carotid artery ;  $\times 150$ .

or tunica intima. Bonnet (96), as a result of his own investigations, suggests a somewhat different classification of the layers composing the arterial wall. According to him, the endothelium alone constitutes the intima. The elastic membranes, both internal and external, together with the tissue lying between them, and that between the internal elastic membrane and the intima, constitute the media. The tissue layers outside the external elastic membrane form the tunica externa (adventitia).

(a) **Arteries.**—In the *great arterial trunks*, such as the pulmonalis, carotis, iliaca, etc., the tunica media possesses a very typical structure. It is divided by means of elastic fibers and membranes

(fenestrated membranes) into a large number of concentric layers containing but few muscle-fibers. Here also the tunica media is separated from the intima by an elastic limiting membrane, the fenestrated membrane of Henle, or the lamina elastica interna. In the aorta this membrane as such is not recognizable. The intima presents three distinct layers—the inner composed of flattened endothelial cells, and the other two consisting chiefly of elastic tissue (fibrous layers). Of these latter the inner is the richer in cellular

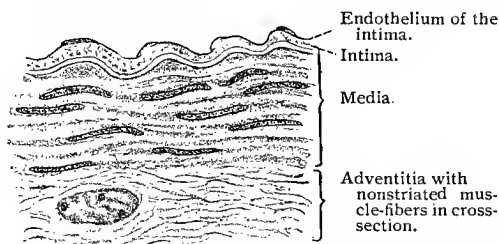


Fig. 165.—Section through human artery, one of the smaller of the medium-sized ;  $\times$  640.

elements and has a longitudinal arrangement of its fibers, while the outer is the looser in structure, possesses few cellular elements, and shows a circular arrangement of its fibers. The adventitia is also made up of fibro-elastic tissue, but in this case with a still looser structure and a longitudinal arrangement of its elastic fibers. In the outer portion of the adventitia the white fibrous tissue is more abundant. The adventitia is rich in blood-vessels.

The *medium-sized arteries* differ in structure from the larger in that the elastic elements of the intima and media are replaced to a considerable extent by nonstriated muscular fibers. To this type belong the majority of the arterial vessels, ranging in caliber from the brachial, crural, and radial arteries to the supraorbital artery. In these the intima shows, besides its endothelium, only a single connective-tissue layer with numerous longitudinal fibers, the subendothelial layer, which is thin and is limited externally by the fenestrated membrane of Henle (lamina elastica interna). The media no longer gives the impression of being laminated, but consists of circularly arranged muscle-fibers separated from each other by elastic fibers and membranes and a small amount of fibrous connective tissue in such a way that the muscle-cells form more or less clearly defined groups. Here also

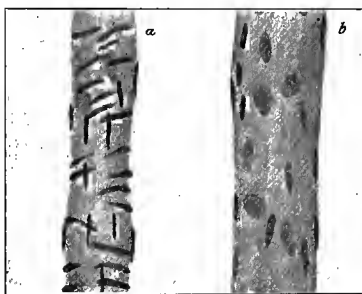


Fig. 166.—Precapillary vessels from mesentery of cat: *a*, Precapillary artery; *b*, precapillary vein possessing no muscular tissue.

the media is limited externally by the external elastic membrane. The adventitia, which becomes looser externally, is not so well developed as in the larger vessels, but presents in general the same structure. In certain arteries (renal, splenic, dorsalis penis) it shows in its inner layers scattered longitudinal muscle-cells, which, however, may also occur in other arteries at their points of division.

With regard to the elastic tissues, the arteries of the brain differ to some extent from those of the remainder of the body. The elastica interna is much more prominent, the elastic fibers in the

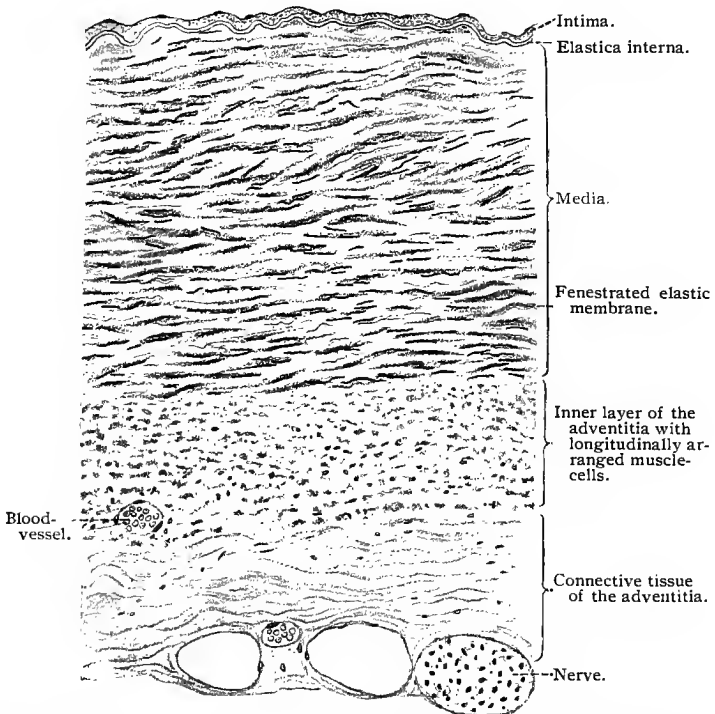


Fig. 167.—Cross-section of human internal jugular vein. At the left of the nerve are two large blood-vessels with a smaller one between them (vasa vasorum);  $\times 150$ .

circular muscular layer are fewer, and the longitudinal strands are almost entirely lacking (H. Triepel).

The walls of the smaller arteries consist mainly of the circular muscular layer of the media. The intima is reduced to the endothelium, which rests directly on the elastic internal limiting membrane. Outside of the external limiting membrane is the adventitia, which now consists of a small quantity of connective tissue. The vasa vasorum have disappeared. To this type belong the supra-orbital, central artery of the retina, etc.

In the so-called *precapillary* vessels the intima consists only

of the endothelial layer. The internal elastic membrane is very delicate. The media no longer forms a continuous layer, but is made up of a few circularly disposed muscular fibers. The adventitia is composed of a small quantity of connective tissue, and contains no vasa vasorum.

(b) **Veins.**—In the foregoing account of the structure of the arteries we have described the structure of their walls according to the caliber of the vessels. Such a differentiation in the case of the veins would be impossible, since sometimes veins of the same caliber present decided differences in structure in various parts of the body.

For the sake of convenience, we will commence with the description of a vein of medium size. Its intima consists of three layers: (1) Of an inner layer of endothelium; (2) of an underlying layer of muscle-cells, interrupted here and there by connective tissue; and (3) of a fibrous connective-tissue layer containing fewer elastic but more white fibrous connective-tissue fibers than is the case in the arteries. Externally, the intima is limited by an internal elastic layer. The media is in general less highly developed than that of a corresponding artery, and contains muscle-cells which have a circular arrangement which in some veins form a continuous layer, although they sometimes occur as isolated fibers. The adventitia shows

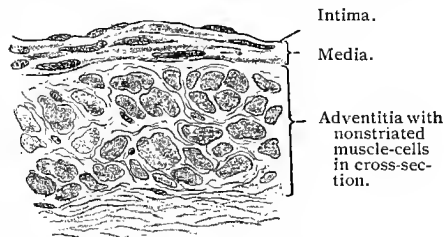


Fig. 168.—Section of small vein (human);  $\times 640$ .

an inner longitudinal muscular layer, which may be quite prominent and even form the bulk of the muscular tissue in the wall of the vein. Otherwise the adventitia of the veins belonging to this class corresponds in general to that of the arteries of the same size; but here also we have, as in the intima, a preponderance of white fibrous connective-tissue elements.

In the crural, brachial, and subcutaneous veins, the musculature of the media is prominent; while in the jugular, subclavian, and innominate veins, and in those of the dura and pia mater, the muscular tissue of the media is entirely wanting, and, as a consequence, the adventitia with its musculature, if present, is joined directly to the intima.

In the *smaller veins* the vascular wall is reduced to an endothelial lining, an internal elastic membrane, a media consisting of interrupted circular bands of smooth muscle-fibers (which may be absent), and an adventitia containing a few muscle-fibers. The *precapillary veins*, which possess in general thinner walls than the corresponding arteries, present a greatly reduced intima and adventitia, while the media has completely disappeared.

The *valves* of the veins are reduplications of the intima and vary slightly in structure at their two surfaces. The inner surface next to the blood current is covered by elongated endothelial cells, while the outer surface possesses an endothelial lining composed of much shorter cellular elements. The greater part of the valvular structure consists of white fibrous connective-tissue and elastic fibers. Flattened and circularly arranged muscle-cells are met with at the inner surface of many of the larger valves. The elastic fibers are more numerous beneath the endothelium on the inner surface of the valves (Ranvier, 89).

(c) **The Capillaries.**—The capillaries consist solely of a layer of endothelial cells, accompanied here and there by a very delicate structureless membrane, and rarely by stellate connective-tissue cells. The connective tissue in the immediate neighborhood of the capillaries is modified to such an extent that its elements, especially those of a cellular nature, seem to be arranged in a direction parallel with the

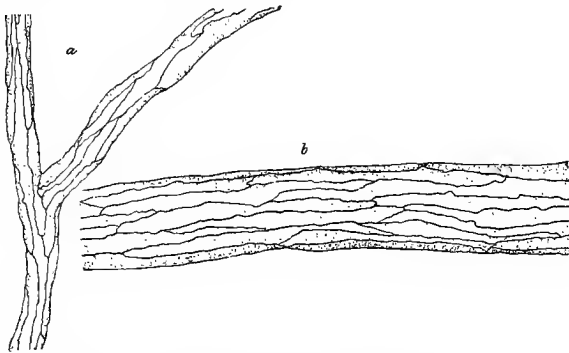


Fig. 169.—Endothelial cells of capillary (*a*) and precapillary (*b*) from the mesentery of rabbit; stained in silver nitrate.

long axis of the capillaries. When examined in suitable preparations, the endothelium of the capillaries is seen to form a continuous layer, the cells of which are, as a rule, greatly flattened and present very irregular outlines.

It is a well-known fact that a migration of the leucocytes occurs from the capillaries and smaller vessels (compare p. 175). In this connection arises the question as to whether or not the cells pass through certain preformed openings in the endothelium of these vessels, the so-called stomata, or through the stigmata and intercellular cement uniting the endothelial cells. The latter seems more probable, as stomata do not occur normally in the capillary wall. This subject will be further touched upon in the description of the lymphatic system.

The capillaries connect the arterial and venous precapillary vessels, and in general accommodate themselves to the shape of the elements of tissues or organs in which they are situated. In the

muscles and nerves, etc., they form a network with oblong meshes, while in structures having a considerable surface, such as the pulmonary alveoli, the meshes are more inclined to be round or oval; such small evaginations of tissue as the papillæ of the skin contain capillaries arranged in the shape of loops. In certain organs—as, for instance, in the lobules of the liver—the capillaries form a distinct network with small meshes.

(d) **Anastomoses, Retia mirabilia, and Sinuses.**—In the course of certain vessels, abrupt changes are seen to occur—as, for instance, when a small vessel suddenly breaks up into a network of capillary or precapillary vessels, which, after continuing as such for a short distance, again unite to form a larger blood-channel, the latter then dividing as usual into true capillaries. Such structures are known as *retia mirabilia*, and occur in man in the kid-

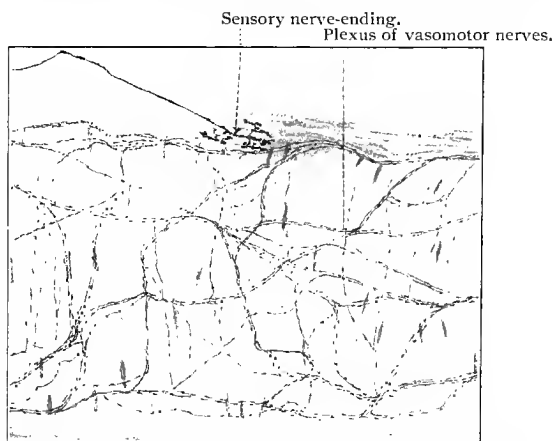


Fig. 170.—Small artery from the oral submucosa of cat, stained in methylene-blue, and showing a small portion of a sensory nerve-ending and the plexus of vasomotor nerves.

ney, intestine, etc. Again, instead of breaking up into capillaries, a vessel may empty into a large cavity lined by endothelial cells (blood sinus). The latter is usually surrounded by loose connective tissue and is capable of great distention when filled with blood from an afferent vessel, or when the lumen of the efferent vessel is contracted by pressure or otherwise. The cavernous or erectile tissue of certain organs is due to the presence of such sinuses (penis, nasal mucous membrane, etc.). If vessels of larger caliber possess numerous direct communications, a vascular plexus is the result; but if such communications occur at only a few points, we speak of anastomoses. Especially important are the direct communications between arteries and veins without the mediation of capillaries. Certain structural conditions of the tissue appear to favor such anomalies, which occur in certain exposed

areas of the skin (ear, tip of nose, toes) and in the meninges, kidney, etc.

The blood-vessels, and more particularly the arteries, possess a rich nerve supply, comprising both nonmedullated and medullated nerves. The nonmedullated nerves, the neuraxes of sympathetic neurones, the cell-bodies of which are situated as a very general rule in some distant ganglion, form plexuses in the adventitia of the vessel-walls; from this, single nerve-fibers, or small bundles of such, are given off, which enter the media and, after repeated division, end on the involuntary muscle-cells in a manner previously described. (See p. 149 and Fig. 128.) Through the agency of these nerves, the caliber of the vessel is controlled. They are known as vasomotor nerves. Quite recently Dogiel, Schemetkin, and Huber have shown that many vessels possess also sensory nerve-endings. The medullated nerve-fibers terminating in such endings, branch repeatedly before losing their medullary sheaths. These nerve-fibers with their branches accompany the vessels in the fibrous tissue immediately surrounding the adventitia. The nonmedullated terminal branches end in telodendria, consisting of small fibrils, beset with large varicosities and usually terminating in relatively large nodules.

The branches and telodendria of a single medullated nerve-fiber (sensory nerve) terminating in a vessel are often spread over a relatively large area, some of the branches of such a nerve often accompanying an arterial branch, to terminate thereon. In the large vessels, the telodendria of the sensory nerves are found not only in the adventitia, but also in the intima, as has been shown by Schemetkin. (See p. 193.)

## B. THE LYMPHATIC SYSTEM.

### 1. LYMPH-VESSELS.

The larger lymph-vessels—the thoracic duct, the lymphatic trunks, and the lymph-vessels—have relatively thin walls, and their structure corresponds in general to that of the veins. They possess numerous valves, and are subject to great variation in caliber according to the amount of their contents. When empty, they collapse and the smaller ones are not easily distinguished from the surrounding connective tissue. Timofeew and Dogiel (97) have shown that the lymph-vessels are supplied with nerves, which in their arrangement are similar to those found in the arteries and veins, though not so numerous. The latter, who has given the fuller description, states that the nerves supplying the lymph-vessels are varicose, nonmedullated fibers which form plexuses surrounding these structures. The terminal branches would appear to end on the nonstriated muscle cells found in the wall of the lymph-vessel.

## 2. LYMPH CAPILLARIES, LYMPH-SPACES, AND SEROUS CAVITIES.

The walls of the lymph capillaries consist of very delicate, flattened endothelial cells, which are, however, somewhat larger and more irregular in outline than those of the vascular capillaries. The two may also be further differentiated by the fact that the diameter of the lymph capillaries varies greatly within very short distances. From a morphologic standpoint, the relations of the lymph capillaries to the vascular capillaries and adjacent tissues are among the most difficult to solve. The distribution of the lymph-vessels and capillaries can be studied only in injected preparations, and it is easily seen that structures of such elasticity and delicacy are peculiarly liable to injury by bursting under this method of treatment. The resulting extravasations of the injection-mass then spread out in the direction of least resistance and still further obscure the picture, rendering it difficult to determine what spaces are preformed and what are the result of the injection. So much is, however, certain: that the more carefully and skilfully the injection is made, the greater are the areas obtained, showing the injection of true lymph capillaries.

In some regions very dense networks of lymph capillaries surrounding the smaller blood-vessels have been demonstrated. Larger cleft-like spaces, lined with endothelium and communicating with the lymphatic system, are also found surrounding the vessels, *perivascular spaces*. These are present in man in the Haversian canals of bone tissue, around the vessels of the central nervous system, etc., and are separated from the actual vessel-wall by flattened endothelial cells. As in the case of the so-called *perilymphatic spaces*, the walls of the perivascular spaces are joined here and there by connective-tissue trabeculæ covered by endothelium. Such structures exist in the perilymphatic spaces of the ear, the subdural spaces of the pia, the subarachnoidal space, the lymph-sinuses, etc. The perivascular spaces are better developed in the lower animals (amphibia, reptilia, etc.) than in mammalia.

The cell-spaces, with their anastomosing processes, found in connective tissue and previously described as the lymph-canalicular system, possess no endothelial lining and communicate directly or indirectly with the lymph capillaries. To the lymphatic system belong also the body-cavities, the pleural, pericardial, and peritoneal cavities. The walls of these consist of a connective-tissue stroma rich in lymph-spaces, lymph capillaries and lymph-vessels, and are lined by a layer of mesothelial cells. In them are found the stigmata and stomata mentioned in a former section. (See p. 85.) The synovial spaces belong also to the lymphatic system; they are lined by a layer of endothelial cells.

Mention has been made of the migration of leucocytes and, under certain conditions, of red blood-cells through the walls of blood capillaries, and in the case of the former through the walls of

lymph capillaries and lymph-vessels and spaces. This diapedesis of leucocytes probably takes place by a wandering of these cells through the stigmata and intercellular cement uniting the endothelial cells lining these spaces, and through the stomata in regions where these occur. According to later investigations, it would seem that leucocytes may bore through endothelial cells, and thus migrate from the vessel or space in which they are found previous to such migration. Kolossow (93), as a result of his investigations, advances still another theory. He believes that he has demonstrated that the cells lining the body-cavities are joined to each other by protoplasmic processes, and that their inner surfaces are covered by a cuticular membrane. These structures are especially well seen in the serous membranes of certain reptiles. Between the cells and between the protoplasmic processes connecting them are spaces which may be compared to the intercellular spaces found in the epidermis. It is thought by him that on stretching the serous membranes, the spaces between the lining cells become larger, and the cuticular portions of the cells become separated from each other, and in this way the stomata and stigmata are thought to be temporarily formed, and through these the migration of the leucocytes is believed to occur. This process is also supposed to occur in the smaller vessels and in the vascular and lymphatic capillaries. However, this whole question needs further investigation.

### C. THE CAROTID GLAND (GLANDULA CAROTICA, GLOMUS CAROTICUM).

At the point where the common carotid divides, there lies in man a small oval structure about the size of a grain of wheat, known as the carotid gland or the glomus caroticum. It is imbedded in connective tissue, surrounded by many nerve-fibers, and on account of its great vascularity has a decidedly red color. The connective-tissue envelope of the gland penetrates into the interior in the form of septa, which divide its substance into small lobules, and these in turn into smaller round masses, the cell-balls. A small branch from the internal or external carotid enters the gland, where it branches, sending off twigs to the lobules, and these in turn still smaller divisions to the cell-balls. The latter vessels break up into capillaries, which merge at the periphery of each cell-ball to form a small vein, from which the larger trunks that pass from the lobules are derived. Each lobule is thus surrounded by a venous plexus from which the larger veins originate that leave the organ at several points. The cell-balls are composed of cellular cords, or trabeculæ, the elements of which are extremely sensitive to the action of reagents. The cells are round or irregularly polygonal and separated from each other by a scanty reticular connective tissue. The capillaries already mentioned come in direct contact

with the cells of the cell-balls. The organ contains a relatively large number of nerve-fibers and a few ganglion cells.

As the individual grows older, the organ undergoes changes which finally make it unrecognizable. The former belief that the carotid gland was developed as an evagination of one of the visceral pouches has been replaced by a newer theory which gives it an origin solely from the vessel-wall (*vid.* Schaper). The structure of the coccygeal gland is in general like that of the carotid gland here described.

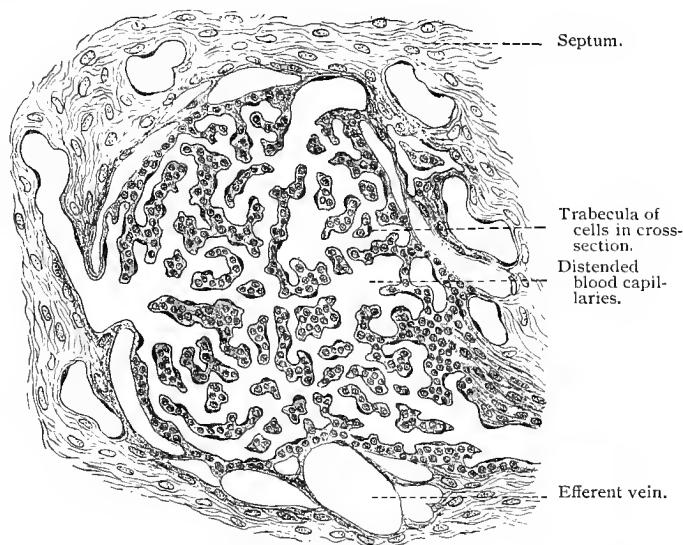


Fig. 171.—Section of a cell-ball from the glomus caroticum of man;  $\times 160$ . (Injected specimen, after Schaper.)

#### TECHNIC (BLOOD AND BLOOD-FORMING ORGANS).

184. Red blood-corpuscles may be examined in the blood fluid without special preparation. The tip of the finger is punctured and a small drop of blood pressed out, placed upon a slide, and immediately covered with a cover-glass and examined. In such preparations the red blood-cells soon become crenated. The evaporation causing the crenation may be prevented by surrounding the cover-glass with oil (olive oil). A fluid having but a slight effect upon the red blood-cells is **Hayem's solution**, which, however, is not adapted to the examination of leucocytes. It consists of sodium chlorid 1 gm., sulphate of soda 5 gm., corrosive sublimate 0.5 gm., and water 200 gm. The fresh blood is brought directly into this solution, the amount of which should be at least one hundred times the volume of the blood to be examined. The fixed blood-cells sink to the bottom, and after twenty-four hours the fluid is carefully poured off and replaced by water. The blood-corpuscles are then removed with a pipet and examined in dilute glycerin. They may be stained with eosin and hematoxylin.

185. Fresh red blood-corpuscles may also be fixed in osmic acid and other special fixing agents. This is done by dropping a small quantity of blood into the fixing fluid; the blood-cells immediately sink and allow the osmic acid to be decanted; they are then washed with water, drawn up with a pipet, and examined in dilute glycerin.

186. A method almost universally used consists in preserving the blood-corpuscles in dry preparations. A drop of fresh blood is placed between two thoroughly cleaned cover-glasses, which are then quickly drawn apart, leaving on the surface of each a thin film of blood which dries in a few moments at ordinary room temperature. The specimens are further dried for several hours at a temperature of  $120^{\circ}\text{C}$ . After they have been subjected to this process, they may be stained, etc.

187. The same results may be obtained by treating specimens dried in the air with a solution of equal parts of alcohol and ether for from one to twenty-four hours, after which they are again dried in the air, and are then ready for further treatment.

188. A cover-glass preparation of fresh blood may also be treated for a quarter of an hour with a concentrated solution of corrosive sublimate in saline solution, then washed with water, stained, dehydrated with alcohol and mounted in Canada balsam. A concentrated aqueous solution of picric acid may also be used, but in this case the specimen should remain in it for from twelve to twenty-four hours.

189. The elements of the blood may also be examined in sections. Small vessels are ligated at both ends, removed, fixed with osmic acid, corrosive sublimate, or picric acid, and imbedded in paraffin.

190. After fixation by any of the above methods the blood-cells may be stained. Eosin brings out very well the hemoglobin in the blood-cells, coloring it a brilliant red; the stain should be used in very dilute aqueous or alcoholic solutions (1% or less), or in combination with alum (eosin 1 gm., alum 1 gm., and absolute alcohol 200 c.c., E. Fischer). Eosin may also be used as a counterstain subsequent to a nuclear stain—for instance, hematoxylin. The preparation is stained for about ten minutes, then washed in water or placed in alcohol until the blood-cells alone remain colored; the cover-glass preparation should then be thoroughly dried between filter-paper and mounted in Canada balsam. Besides eosin, other acid stains—as orange G, indulin, and nigrosin—have the property of coloring blood-cells containing hemoglobin.

191. Blood platelets are best fixed with osmic acid, and may be seen without staining. They may also be stained and preserved in a sodium chlorid solution to which methyl-violet is added in a proportion of 1 : 20000 (Bizzozero, 82). Afanassiew adds 0.6% of dry peptone to the solution (this fluid must be sterilized before using).

192. The leucocytes of the circulating blood and those found in certain organs possess granulations which were first studied by Ehrlich and his pupils, and which may be demonstrated by certain methods. The names given to these granulations are based upon Ehrlich's classification of the anilin stains, which differs from that of the chemist. This author distinguishes acid, basic, and neutral stains. By the acid stains he understands those combinations in which the acid is the active staining principle, as in the case of the picrate of ammonia. Among these are congo, eosin, orange G, indulin, and nigrosin. The basic stains are

those which, like the acetate of rosanilin, consist of a color base and an indifferent acid. To these belong fuchsin, Bismarck brown, safranin, gentian, dahlia, methyl-violet, methylene-blue, and toluidin. Finally, the neutral anilins may be considered as those stains which, like the picrate of rosanilin, are formed by the union of a color base with a color acid. The granula may be demonstrated in dry preparations as well as in those fixed with alcohol, corrosive sublimate, glacial acetic acid, and sometimes even Flemming's solution. Five kinds of granules are distinguished, and designated by the Greek letters from alpha to epsilon.

**193.** The  $\alpha$ -granules (**acidophile, eosinophile**) occur in leucocytes of the normal blood, in the lymph, and in the tissues, and are differentiated from the others by their peculiar staining reaction to all acid stains. They are first treated for some hours with a saturated solution of an acid stain (preferably eosin) in glycerin, washed with water, subsequently colored with a nuclear stain (as hematoxylin or methylene-blue), and then dried and mounted in Canada balsam. Sections may be treated in the same way, with the exception that after being washed with water, they are first dehydrated with absolute alcohol before mounting in balsam.

**194.** Another method by which both nuclei and granules are stained consists in the use of Ehrlich's hematoxylin solution (*vid.* T. 63, page 42), to which 0.5% eosin is added. Before using, the solution should be permitted to stand exposed to the light for three weeks. This mixture stains in a few hours, after which the preparation is washed with water, treated with alcohol, and then mounted in Canada balsam. The  $\alpha$ -granules appear red, the nuclei blue.

**195.** The  $\beta$ -granules (**amphophile, indulinophile**) stain as well in acid as in basic anilins. They do not occur in man, but may be observed in the blood of guinea-pigs, fowl, rabbits, etc. They are demonstrated as follows: Equal parts of saturated glycerin solutions of eosin, naphthylamin-yellow, and indulin are mixed, and the dried preparations treated with this combination for a few hours, then washed with water, dried between filter-paper, and mounted in Canada balsam. The amphophile granules are stained black, the eosinophile granules red, the nuclei black, and the hemoglobin yellow.

**196.** The  $\gamma$ -granules, or those of the **mast-cells**, are found in normal tissues and also in small quantities in normal blood, and are found in larger numbers in leukemic blood. They may be shown by two methods: (1) A mixture is made consisting of concentrated solution of dahlia in glacial acetic acid 12.5 c.c., absolute alcohol 50 c.c., distilled water 100 c.c. (Ehrlich). The treatment is the same as for the amphophile granules; (2) Westphal's alum-carmin-dahlia solution (*vid.* Ehrlich). This mixture is used in staining dry preparations as well as sections of objects fixed for at least one week in alcohol. Alum 1 gm. is dissolved in distilled water 100 c.c., and carmin 1 gm. added. The whole is then boiled for one-quarter hour, cooled, filtered, and 0.5 c.c. of carbolic acid added (Grenacher's alum-carmin, *vid.* T. 60). This solution is now mixed with 100 c.c. of a saturated solution of dahlia in absolute alcohol, glycerin 50 c.c., and glacial acetic acid 10 c.c., the whole stirred and allowed to stand for a time. The specimen is stained for twenty-four hours, decolorized in absolute alcohol for the same length of time, and finally mounted in Canada balsam. The  $\gamma$ -granules are colored a dark blue and the nuclei red. A simpler method of demonstrating the

$\gamma$ -granules consists in overstaining dry and fixed cover-glass preparations with a saturated aqueous solution of methylene-blue, decolorizing for some time in absolute alcohol, drying between filter-papers, and mounting in Canada balsam.

197. The  $\delta$ -granules (**basophile**) occur in mononuclear leucocytes of the human blood. Their staining may be accomplished in a few minutes by treating fixed cover-glass preparations with a concentrated aqueous solution of methylene-blue, after which they are washed with water, dried between filter-papers, and mounted in Canada balsam.

198. The  $\epsilon$ - or **neutrophile granules** which are found normally in the polynuclear leucocytes of man (as also in pus-cells), in some of the transitional cells, and in the myelocytes, are stained by Ehrlich as follows: 5 vols. of a saturated aqueous solution of acid fuchsin are mixed with 1 vol. of a concentrated aqueous solution of methylene-blue. To this 5 vols. of water are added, and the whole allowed to stand for a few days, after which the solution is filtered. This mixture stains in five minutes, and the specimen is then washed with water, etc. The neutrophile granules are colored green, the eosinophile granules red and the hemoglobin yellow.

199. Neutrophile and eosinophile granules may also be stained in Ehrlich's neutrophile mixture:

Orange G, saturated aqueous solution,	. 130 to 135 c.c.
Acid fuchsin, " " " . . .	80 to 120 "
Methyl-green, " " " . . .	125 "
Distilled water, . . . . .	300 "
Absolute alcohol, . . . . .	200 "
Glycerin, . . . . .	100 "

Mix the above quantities of orange G, acid fuchsin, water, and alcohol in a bottle and add slowly, while shaking the bottle, the methyl-green and finally the glycerin. The cover-glass preparations should be fixed in the ether and alcohol solution for about one hour, or fixed with dry heat at a temperature of  $110^{\circ}$  C. for from fifteen to thirty minutes. Float the preparation on a small quantity of the stain for about fifteen minutes, wash in water, dry and mount in balsam. The red blood-cells are stained a reddish-brown color (brick-color), all nuclei a light blue-green, the eosinophile granules a fuchsin-red, and the neutrophile granules a violet-red. Grüber, of Leipzig, has prepared a dry powder, known as the Ehrlich-Biondi-Heidenhain three-color mixture, which is prepared for use by making a 0.4% solution in distilled water, to 100 c.c. of which are added 7 c.c. of a 0.5% aqueous solution of acid fuchsin.

200. The hemoglobin shows itself in the form of crystals. In certain teleosts the crystals are formed in the blood-corpuscles around the nuclei and often within a short time after death. In old alcoholic specimens, hemoglobin crystals (blood crystals) are found in the vessels and were first discovered here by Reichert in the blood of the guinea-pig. They have been found in large quantities in the splenic blood of a sturgeon which had been preserved for forty years in alcohol. The hemoglobin crystals belong to the rhombic series of crystallographic classification. The simplest method of demonstrating hemoglobin crystals is probably the following: The blood is first defibrinated by whipping or agitating with mercury, after which process sulphuric ether is added, drop by drop, until the mixture has been made laky; this change may be detected

macroscopically by the sudden change from an opaque to a dark, transparent, cherry-red color. No red blood-cells should now be seen under the microscope. The preparation is placed on ice for from twelve to twenty-four hours after which a drop of the blood is placed on a slide. In half an hour it will be seen that the margin of the drop has begun to dry. A cover-slip is now applied and, after a few minutes, numerous crystals are seen to form at the margin of the drop, a process which may be followed under the microscope. Large hemoglobin crystals are obtained by Gscheidtlen as follows: Defibrinated blood is placed in a glass tube, which is then hermetically sealed. The blood is now subjected to a temperature of about  $40^{\circ}$  C. for two or three days; if then the glass be broken and the blood poured into a flat dish, large hemoglobin crystals are immediately formed.

201. Crystals also appear if a drop of laky blood be placed in a thick solution of Canada balsam in chloroform and covered with a cover-slip.

202. Hemin crystals (Teichmann's crystals; hemin is hematin-chlorid) in the shape of rhombic plates are very easily obtained from the blood. A drop of the latter is placed on a slide and carefully mixed with a small drop of normal salt solution. This is then carefully warmed until the fluid evaporates and leaves a reddish-brown residue, after which a cover-glass is applied and glacial acetic acid added until the space between slide and cover-glass is filled. The preparation is now heated until the acetic acid boils. As soon as the latter evaporates, Canada balsam may be brought under the cover-glass, thus producing a permanent specimen. When fluids or stains suspected of containing blood are to be examined, the hemin crystals become of the utmost importance, as their demonstration is then a positive indication of the presence of blood. Fluids are evaporated and treated with glacial acetic acid as above directed. Suspected blood stains on cloth are treated as follows: Small pieces are cut from the cloth in the region of the stain, soaked in normal salt solution, and the resulting fluid treated as above. If the stain is on wood or other solid object, the stain is scraped off and dissolved in normal salt and then tested for hemin crystals. Hemin crystals are almost or entirely insoluble in water, alcohol, ether, ammonia, glacial acetic acid, dilute sulphuric acid, and nitric acid. They are, however, soluble in potassium hydrate.

203. A third form of crystals occasionally found in the blood and frequently in the corpora lutea and, under pathologic conditions, also in apoplectic areas, are the *hematoidin crystals* first discovered by Virchow. Masses of these crystals have an orange color. Microscopically, they appear as red rhombic plates. As they are soluble in neither alcohol nor chloroform, they are easily preserved in Canada balsam. Their



Fig. 172.—Fibrin from laryngeal vessel of child;  $\times$  about 300.

artificial production has as yet never been accomplished. Hematoidin contains no iron.

204. The fibrin thrown down when the blood coagulates may be demonstrated upon the slide in the form of very fine particles and filaments. A drop of blood is brought upon the slide and kept for a time in a moist chamber or on the table until it begins to clot; after which a cover-slip is applied and the preparation washed with water by continued irrigation. In this manner most of the red blood-corpuscles are removed. Lugol solution may now be added, which stains brown the filaments of the fibrin network adherent to the slide. In order to see the fibrin network in sections, it is better to use specimens previously fixed in alcohol; the sections are stained for ten minutes in a concentrated solution of gentian-violet in anilin water (Weigert), rinsed in normal salt solution, treated for about ten minutes with iodo-iodid of potassium solution, and then spread upon a slide and dried with filter-paper. They are now placed in a solution consisting of 2 parts of anilin oil and 1 part of xylol until they become perfectly transparent. This solution is then replaced by pure xylol and finally by Canada balsam. The fibrin network is stained a deep violet.

205. There are different methods and a variety of material at our disposal for the demonstration of the blood current through the vessels. The best object for this purpose is probably the frog. The procedure is as follows: The animal is immobilized by poisoning with curare.  $\frac{1}{2}$  gm. of a 1% aqueous solution injected into the dorsal lymph-sac will immobilize the frog in a short time. The exact dose can not, however, be given, as the commercial curare is not a uniform chemical compound; the dose must therefore be ascertained by experiment. As is well known, curare affects exclusively the nerve end-organs of striated voluntary muscle, but does not affect either the heart muscle or unstriated muscular tissue; hence the utility of curare for this purpose. In order to see the blood current, it is only necessary to stretch the transparent web between the frog's toes and fasten it with insect needles to a cork plate having a suitable opening. If the cork plate be large enough to accommodate the whole frog, it may be placed in such a position that its opening lies over that in the stage of the microscope. The web thus spread out may be examined with a medium magnification. The tongue of the frog is also used for the same purpose. As the latter is attached to the anterior angle of the lower jaw, it may be conveniently drawn out, suitably stretched, and then placed over the hole in the cork plate. A very good view of the circulation may be obtained by examining the mesentery of a frog. The migration of the leucocytes through the vessel-walls can also be studied in such preparations. An incision 0.5 cm. in length is made in the right axillary line through the skin of a frog (best in the male), care being taken not to injure any vessels (which can be seen through the skin in frogs possessing little pigment). The abdominal muscles are then incised and a pair of forceps introduced to grasp one of the presenting intestinal loops. The latter is then attached to the cork plate with needles, and the mesentery carefully stretched over the opening. On examining the specimen it is best to moisten it with normal salt solution and to cover the area to be examined with a fragment of a cover-glass. The lung may also be examined, but here the incision must be farther forward.

206. To obtain a general idea of the structure of lymphatic glands,

sections are made of small glands fixed in alcohol or corrosive sublimate. They are then stained with hematoxylin and eosin. In such preparations the cortical and medullary substances can be studied; the trabeculæ and blood take the eosin stain.

**207.** The flattened endothelial cells covering the trabeculæ are brought to view by injecting a 0.1% solution of silver nitrate into a fresh lymphatic gland. After half an hour the gland is fixed with alcohol and carried through in the regular way; the sections should be quite thick (not under 20  $\mu$ ). After the sections have been mounted in Canada balsam and exposed to light for a short time, the endothelial mosaic will be seen wherever the silver nitrate has penetrated.

**208.** Fixing with Flemming's solution and staining with safranin is the best method for studying the germ centers of the lymph-follicles. Other fluids which bring out the mitoses may also be employed.

**209.** Reticular tissue is best demonstrated by sectioning a fresh gland with a freezing microtome, removing a section to a test-tube one-quarter filled with water, and agitating it. The lymphocytes are thus shaken out of the meshes of the reticulum, leaving the latter free for examination.

**210.** The same results can be obtained by placing a section prepared in the above-named manner upon a slide, wetting it with water, and carefully going over it with a camel's-hair brush. The lymphocytes adhere to the brush. Both methods (His, 61) may be applied to hardened sections which have lain in water for a day or so. In this case, however, the removal of the lymphocytes is not so easy as in fresh sections.

**211.** In thick sections the reticulum is hidden by the lymphocytes. If, on the other hand, very thin sections (not over 3  $\mu$ ) be made, especially of objects fixed in Flemming's solution, the adenoid reticulum stands out clearly without any further manipulation.

**212.** The reticular structure may also be demonstrated by an artificial digestion of the sections with trypsin. The sections are then agitated in water, spread on a slide, dried, then moistened with a picric acid solution (1 gm. in 15 c.c. of alcohol and 30 c.c. of water), again dried, covered with a few drops of fuchsin S solution (fuchsin S 1 gm., alcohol 33 c.c., water 66 c.c.), and left to stand for half an hour. The fuchsin solution is then carefully removed, the section washed again for a short time in the same picric acid solution, then treated with absolute alcohol, xylol, and finally mounted in Canada balsam. The reticular tissue of both lymphatic glands and spleen are stained a beautiful red (F. P. Mall).

**213.** The treatment of splenic tissue is practically the same as that of the lymphatic glands.

**214.** In all these organs (lymph-glands, spleen, and bone-marrow) a certain amount of fluid may be obtained by scraping the surface of the fresh tissue. This may then be examined in the same manner as blood and lymph (see Technic of same). Sections of lymph-glands and spleen previously fixed in alcohol, mercuric chlorid, or even in Flemming's solution may be examined by the granula methods of Ehrlich.

**215.** By using the chrome-silver method a peculiar network of reticular fibers may be seen in the spleen. (Gitterfasern; Opperl, 91.)

**216.** The examination of the bone-marrow belongs also to this chapter. The marrow of the diaphysis is taken out by splitting the bone

longitudinally with a chisel. With a little practice, it is easy to obtain small pieces of the marrow, which are then fixed by the customary methods and cut into sections. In the epiphysis the examination is confined either to the pressing out of a small quantity of fluid with a vice, or to the decalcification of small masses of spongy bone, containing red bone-marrow. In the first case, methods applicable to blood examination are employed; in the second, section methods (see also the petrification method, T. 158) are used. The methods given for the preparation of lymph-glands and spleen are also applicable in many cases.

217. Enderlen has demonstrated reticular fibers (Gitterfasern) in the bone-marrow by means of the chrome-silver method.

### TECHNIC (CIRCULATORY SYSTEM).

218. To obtain a topographical view of the layers composing the heart and vessels, sections are made of tissues that have been fixed in Müller's fluid, chromic acid, etc. If the specimens are to be studied in detail, small pieces must be used, and are best fixed in chromic-osmic mixtures or corrosive sublimate. Celloidin imbedding is recommended for general topographic work. The further treatment is elective.

219. The endothelium of the intima may be brought to view by silver nitrate impregnation methods, by injecting silver solutions into the vascular system, etc. (*vid.* T. 109). The endothelial elements of the smallest vessels and capillaries are then clearly defined by lines of silver. Larger vessels must be cut open, the intima separated, and pieces of its lamellæ examined.

220. With regard to the isolation of the muscle-cells of the myocardium and of the walls of the vessels, see T. 170 to 172.

221. Elastic elements, plates and networks are best observed in the tunica media of the vessels, very small pieces of which are treated for some hours with 33% potassium hydrate.

222. The appropriate stains for sectionwork are those which bring out the elastic elements and the smooth muscle-cells. For the former, orcein is used (*vid.* T. 138).

223. For demonstrating the distribution of the capillaries, the reader is referred to the injection methods (*vid.* T. 100 *et seq.*) The lymph-capillaries are injected by puncture (T. 111); compare also the methods of Altmann (T. 112).

## III. THE DIGESTIVE ORGANS.

THE intestinal canal with the glands derived therefrom originates from the inner layer of the blastoderm, the entoderm. The latter, however, does not extend to the external openings of the body, as the ectoderm forms depressions at these points which grow inward toward the still imperforate fore and hind gut to communicate finally with its lumen. This applies as well to the formation of the primitive oral cavity, which is separated only secondarily into oral and nasal cavities, as to the anus. The anterior boundary

between the ectodermal and entodermal portions of the digestive tube consists of a plane passing through the opening of the posterior nares and continued downward along the palatopharyngeal arch. Everything lying anterior to this is of ectodermal origin, therefore the entire oral and nasal cavities with their derivatives. The lining of these cavities consists, however, of a true mucous membrane, closely resembling in its structure that of the intestinal tract.

### A. THE ORAL CAVITY.

The epithelium of the oral mucous membrane is of the stratified squamous type, differing from the epithelium of the epidermis in that the stratum granulosum does not appear here as an independent layer. The stratum lucidum is also wanting, and the cornification of the layer analogous to the stratum corneum of the skin is not complete (compare Skin). In the mucous membrane the cells of even the most superficial layers contain nuclei, which, although partly atrophied, still show chromatin, and as a consequence are easily demonstrated.

Beneath the epithelium lies a tissue of mesodermic origin, also belonging to the mucous membrane and known as the *mucosa* or *stratum proprium* (lamina propria, tunica propria), in which numerous glands are situated. The mucosa consists of a fibrillar connective tissue with few elastic fibers, and of adenoid tissue containing numerous lymphoid cells; essentially, therefore, a diffusely distributed adenoid tissue with occasional lymph-follicles imbedded in its substance. The mucosa presents numerous papillæ, which are either simple or compound (branched) elevations of the mucosa, varying in length and density, according to their location and extending for variable distances into the overlying epithelium. As in the papillary layer of the corium (see Skin), so also here the superficial layer of the stratum proprium contains very fine elastic and connective-tissue elements which contribute to the structure of the papillæ. All these papillæ contain capillaries and arterioles which are derived from an arterial network in the mucosa. The lymphatics are similarly arranged.

At the red margin of the lips the papillæ are unusually high and are covered at their summits by a very thin epithelial layer (Fig. 173). Besides the sebaceous glands which lie at the angles of the mouth, and whose ducts open at the surface, there are here no other glandular structures. In the mucosa of the mucous membrane of the lips and cheeks the papillæ are low and broad; here also open the ducts of compound lobular, alveolar glands, the *glandulæ labiales* and *buccales* whose structure is similar to that of the large salivary glands (see these). The gums possess very long and attenuated papillæ, covered by a very thin layer of epithelium, therefore bleeding at the slightest injury. That part of the gum

covering the tooth has no papillæ. The gums contain no glands. The papillæ of the hard palate are arranged obliquely, with their points directed toward the opening of the mouth. The papillæ of the soft palate are very low and may even be absent. They are somewhat higher on the anterior surface of the uvula. On the posterior surface of the latter occur ciliated epithelia distributed in islands between the areas of stratified squamous epithelium. In the soft palate and uvula are found small mucous glands.

Under the mucous membrane there is a layer consisting princi-

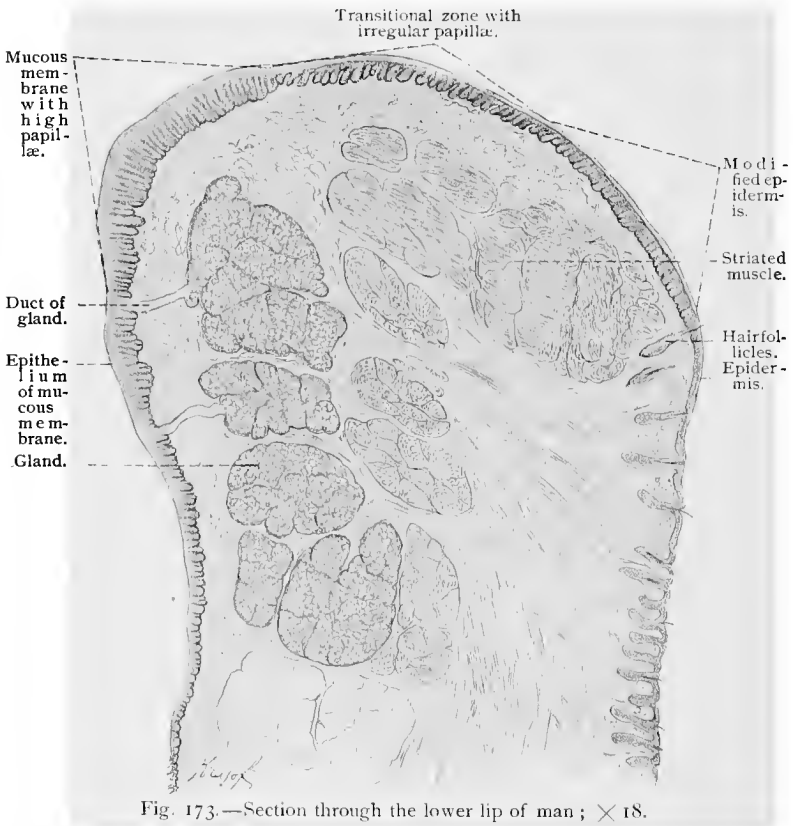


Fig. 173.—Section through the lower lip of man;  $\times 18$ .

pally of connective tissue and elastic fibers, the *submucosa* (stratum submucosum, tela submucosa). In the mucous membrane of the mouth the transition of the tissue of the mucosa into that of the submucosa is very gradual. The submucosa of the hard palate is closely connected with the periosteum and contains, especially at its posterior portion, numerous glands. In other regions of the mouth (lip) the glands extend also into the submucosa. The mucosa and epithelium lining the mouth cavity are richly supplied with nerves which terminate either in special sensory

nerve-endings or in free sensory nerve-endings, or on the blood-vessels. In the papillæ of the mucosa are found corpuscles of Krause. (See p. 154.) The nerves terminating in free sensory endings are the dendrites of sensory neurones (medullated sensory nerves), which, while yet medullated, branch and form plexuses with large meshes, situated in the submucosa and deeper portion of the mucosa. The medullated branches of the nerve-fibers constituting these plexuses proceed toward the epithelium, dividing further in their course. Immediately under the epithelium the medullated branches lose their medullary sheaths, divide further, and form the subepithelial plexuses. The nonmedullated branches enter the epithelium, where they form telodendria (end-brushes), the terminal branches of which surround the epithelial cells, between which they end either in very fine granules or in small groups of such, or, again, in variously shaped end-discs. (See Fig. 130.) The blood-vessels are richly supplied with vasomotor nerves, the neuraxes of sympathetic neurones, which terminate on the muscle-cells of the vessels. In the adventitia are also found free sensory nerve-endings. (See Fig. 170.)

### 1. THE TEETH.

**Structure of the Adult Tooth.**—The adult tooth is made up of three substances—the enamel, the dentin, and the cementum. The latter covers that part of the tooth within the alveolar process of the jaw and also the root of the tooth. The enamel caps that part of the tooth projecting into the oral cavity, the crown of the tooth. The neck of the tooth is the region where the cementum and enamel come in contact. The greater part of the tooth consists of dentin, which is present in the crown as well as in the root. All the substances of the tooth just mentioned become very hard from the deposition of lime-salts. Every tooth contains a cavity surrounded by dentin, the pulp cavity, or dental cavity. This is filled with a soft tissue, the pulp, consisting of white fibrous tissue, vessels, and nerves. That part of the pulp cavity lying in the axis of the fang is called the root-canal; by an opening in the latter (foramen apicis dentis) the pulp is connected with the periosteal connective tissue of the dental alveolus.

The **enamel** is a very hard substance, the hardest in the body, and may be compared to quartz. In uninjured teeth the enamel is covered by an exceedingly thin, structureless enamel membrane (cuticula dentis). The enamel contains very little organic substance (from 3% to 5%), in consequence of which it is soluble in acids with scarcely any residue. The elements composing it are prismatic columns, the *enamel prisms*, which occupy the whole thickness of the enamel from the superficial membrane to the dentin. These are thicker at the surface of the tooth than at the dentin, and in transverse section show a hexagonal or polygonal shape. They are

joined to each other by a cement-substance which is somewhat more resistant than the substance of the prisms themselves. In the adult they are entirely homogeneous, but in embryos and even in the new-born they show a (fibrillar) longitudinal striation. In their course through the thickness of the enamel they change their

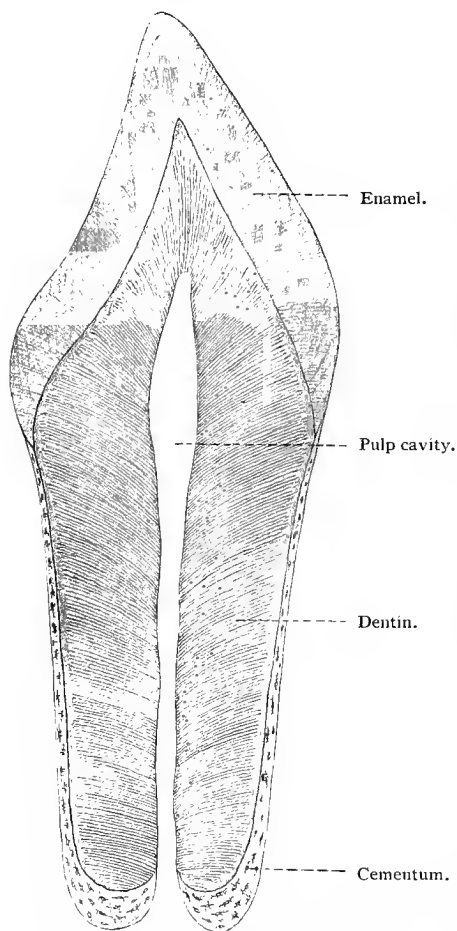


Fig. 174.—Scheme of a longitudinal section through a human tooth. In the enamel are seen the "lines of Retzius."

direction by a series of symmetrical curves, and cross each other in groups in a typical manner. There are also seen in the enamel the parallel lines known as the lines of Retzius (see Fig. 174), which are to be regarded as traces of the strata caused by the periodic deposition of lime-salts; they are very variable, as their structure depends on the nutritive condition during the deposition of the lime-salts (Berten).

The **dentin** is, next to the enamel, the hardest tissue of the tooth. After its decalcification a substance is left which yields gelatin. The dentin is permeated by a system of canals having usually a transverse direction, the so-called *dentinal tubules*, which are from  $1.3 \mu$  to  $4.5 \mu$  in diameter. These originate in the pulp cavity, and during their course become slightly curved, like the letter **S**. At their outer third they branch and become constantly smaller. As a rule, they extend as far as the enamel,

although a few now and then even cross the boundary of the enamel. They never reach the cement, but leave here a free zone in which the ground-substance of the dentin alone is present. The dentinal tubules possess sheaths, the sheaths of Neumann, which may be isolated, analogous to the sheaths of the canaliculi of bone, and which contain throughout their entire length filiform prolonga-

tions of certain pulp-cells (odontoblasts), the *dentinal fibers*. According to v. Ebner, the ground-substance of the dentin consists of bundles of connective-tissue fibrils, which in the root run parallel to the long axis of the tooth, and in the crown have a direction at right angles to that of the dentinal tubules. The S-shaped curves of the latter give rise to the lines of Schräger in the dentin, which are visible with an ordinary magnifying glass. Peculiar, irregularly branched spaces are often seen in the dentin. These are the *interglobular spaces*, and represent areas in which calcification has not taken place.

The **cementum** is closely adherent to the dentin, and consists of

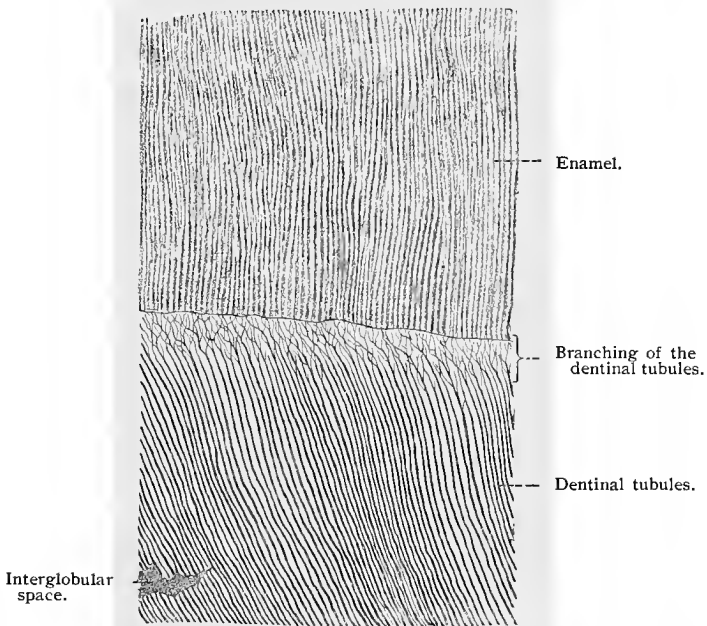


Fig. 175.—A portion of a ground tooth from man, showing enamel and dentin;  $\times 170$ .  
Technic No. 225.

bone tissue, the parallel lamellæ of which contain, as a rule, no Haversian canals. There occur, however, cement lamellæ, which in places lose their bone-cells. A peculiarity of the cementum is the presence of a large number of Sharpey's fibers, which are especially abundant in those areas containing no bone-corpuscles. These fibers are usually found in an uncalcified condition.

The *tooth-pulp* is a tissue resembling embryonic connective tissue, consisting of connective-tissue fibrils, branched connective-tissue cells, and a semifluid, interfibrillar ground-substance. It is characteristic of this tissue that the fibrils never join to form connective-tissue fibers. At the surface of the pulp is a continuous

layer of cells, the *odontoblasts*. These are columnar cells with basal nuclei and two or three processes extending into the canaliculi of the dentin, forming here the dentinal fibers already described. As a rule, the odontoblasts also send a single fiber into the pulp. These may intertwine and give rise to a network within its substance.

The tooth is joined to the periosteum of the alveolus by a reduplication of the latter over its root, the dental periosteum or periodental membrane. This consists of bundles of connective tissue (elastic fibers are here absent) directly continuous with Sharpey's fibers in the cementum. At the neck of the tooth the periodental membrane disappears in the submucosa of the gum; in

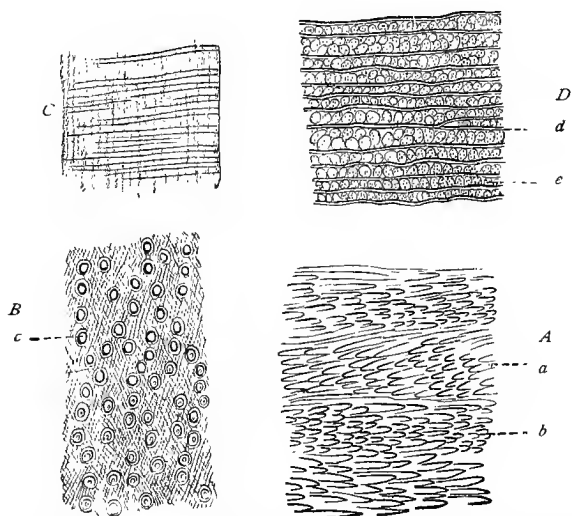


Fig. 176.—*A*, Longitudinal section through a human molar from the center of the enamel layer, decalcified with dilute hydrochloric acid; *B*, tangential, *C*, radiate, and *D*, transverse section through the dentin of a human tooth, showing the fibrillar structure of the ground-substance (taken from v. Ebner, 91): *a* and *b*, Two layers in which the direction of the enamel prisms changes; in *c* is seen a dentinal fiber with its sheath; *e*, groups of fibrils; *d*, dentinal tubules.

the former are found here and there peculiar masses of epithelial cells representing the remains of the enamel organs.

The tooth-pulp has a rich blood supply. A small artery enters the pulp cavity through the apical foramen, which, as it passes up through the pulp, gives off numerous smaller branches which end in a capillary network situated under the layer of odontoblasts. Numerous medullated nerve-fibers (dendrites of sensory neurones) enter the pulp cavity through the apical foramen. Some of these lose their medullary sheaths soon after entering, or just before entering, the pulp, and divide into long, fine, varicose fibers which interlace to form a loose plexus under the odontoblasts. Other

medullated fibers, grouped into small bundles, ascend in the pulp for variable distances; the nerve-fibers of the bundles then separate and as single fibers approach the superficial portion of the pulp, and, after losing their medullary sheaths, divide into fine varicose fibers forming under the odontoblasts a plexus continuous with the plexus above mentioned. From the varicose nerve-fibers of this plexus small terminal branches are given off which terminate between the odontoblasts, or pass through the layer of odontoblasts, to end between these and the dentine (Retzius, 94; Huber, 98). Medullated nerve-fibers also terminate in free endings in the peridental membrane.

**Development of the Teeth.**—In the second month of fetal life the first traces of the teeth are seen in the development of a groove along the inner edge of the fetal jaw, the dentinal or enamel groove. From the floor of the latter an epithelial ridge is formed constituting the anlage of the enamel organs and known as the dentinal ridge, or enamel ledge. At those points at which the milk-teeth later appear, the enamel ledge develops solid protuberances corresponding in number to the temporary teeth. These are known as the dentinal bulbs or *enamel germs*. In their first stage of development the enamel germs are knob-like, but later their bases spread, and they become flattened and finally cup-shaped by the pushing up into them of connective-tissue projections, the *dentinal papillæ*. At the same time they gradually sink deeper into the underlying tissue, but still remain connected, by means of a thin cord, with the epithelium of the enamel ledge, which now lies on the inner side of the enamel germs. The enamel germs now differentiate into enamel organs. In this stage they consist of an outer layer of columnar epithelial cells, which are to be regarded as a direct continuation of the basal cells from the epithelium of the oral mucous membrane, or still better, of the enamel ledge; the epithelium in the interior of the organ is derived from the stratum Malpighii of the oral epithelium. The cells of this layer, however, undergo a change in shape and structure, in that an increased quantity of lymph-plasma or intercellular substance collects in the interspinous spaces between the cells, pushing the cells apart, and allowing their processes to

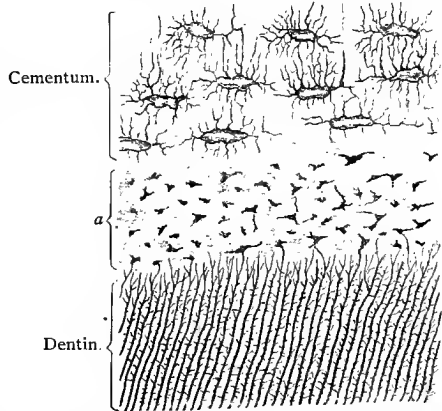


Fig. 177.—Cross-section of human tooth, showing cement and dentin;  $\times 212$ . Technic No. 225 (*vid.* also Technic 152). At *a* are seen small interglobular spaces (Tomes' granular layer).

the inner side of the enamel germs. The enamel germs now differentiate into enamel organs. In this stage they consist of an outer layer of columnar epithelial cells, which are to be regarded as a direct continuation of the basal cells from the epithelium of the oral mucous membrane, or still better, of the enamel ledge; the epithelium in the interior of the organ is derived from the stratum Malpighii of the oral epithelium. The cells of this layer, however, undergo a change in shape and structure, in that an increased quantity of lymph-plasma or intercellular substance collects in the interspinous spaces between the cells, pushing the cells apart, and allowing their processes to

develop until the cells finally assume a stellate shape. In this way the enamel pulp is gradually formed. The next stage is characterized by a vertical growth of the dentinal papillæ, which soon become surrounded on all sides by the cap-like enamel organs. The cylindrical cells (enamel cells) of the enamel organs lying next to the papillæ become lengthened, and after passing through further changes, finally develop into the enamel prisms of the teeth. At the periphery of the dentinal papillæ, there is differentiated a layer of columnar cells, the *odontoblasts*, which have a connective-tissue origin, and later form the dentin. During these processes a connective-tissue mantle, the *dental sac*, rich in cellular and fibrous elements, is formed around each tooth anlage.

The earliest appearance of the enamel is in the form of a cuticular membrane, developed from the ends of the enamel cells resting on the dentinal papilla, this cuticular membrane appearing in the form of a thin layer covering the top of the dentinal papilla. Some time later, short striated processes—*Tomes' processes*—appear on the

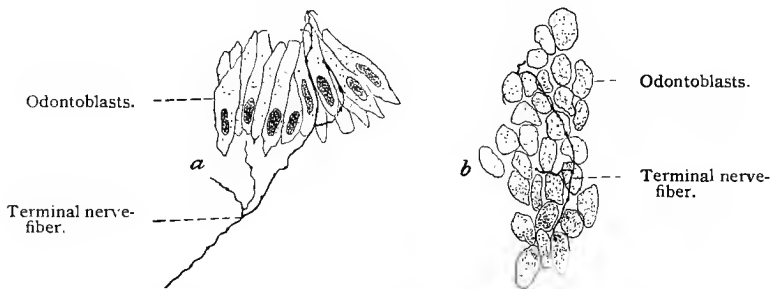

Fig. 178.—Nerve termination in the pulp of a rabbit's molar, stained in methylene-blue (*intra vitam*): *a*, Odontoblasts seen in side view; *b*, a number of odontoblasts seen in end view, showing a terminal branch of a nerve-fiber situated between the odontoblasts and the dentin (Huber, "Dental Cosmos," October, 1898).

lower end of each of the enamel cells (the end toward the dentinal papilla). These are imbedded in a cement-substance, forming a continuous layer. The Tomes' processes are regarded as the beginnings of the enamel prisms. Calcification begins in the middle of these processes; they thicken at the expense of the cement-substance surrounding them, which later also calcifies. The enamel as a whole thickens by the elongation of the Tomes' processes of the enamel cells and by their subsequent calcification. The process ends finally in the death and partial absorption of the enamel cells and the remaining elements of the enamel organs; these structures persist for a short time after the eruption of the tooth as a cuticular sheath.

The dentin is developed by the odontoblasts by a process analogous to that observed in the formation of bone by the osteoblasts. These epithelioid cells secrete at their outer surfaces a

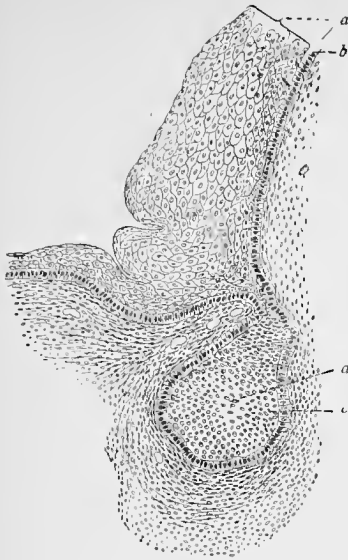


Fig. 179.

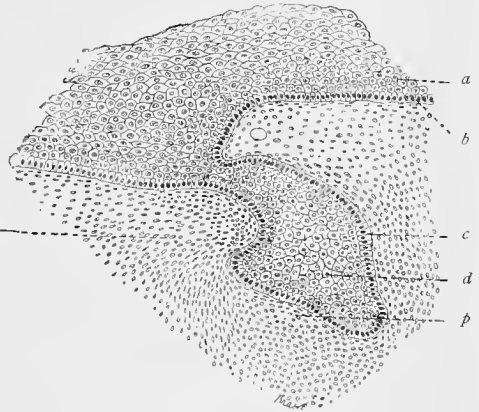


Fig. 180.

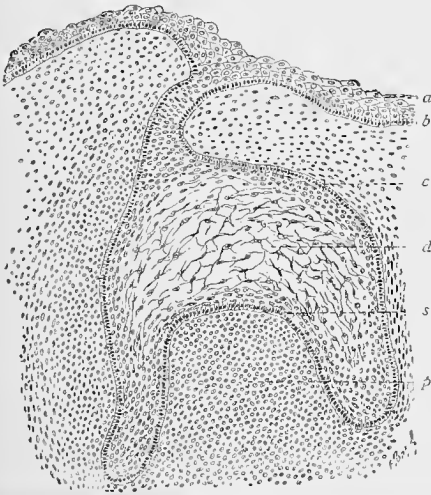


Fig. 181.

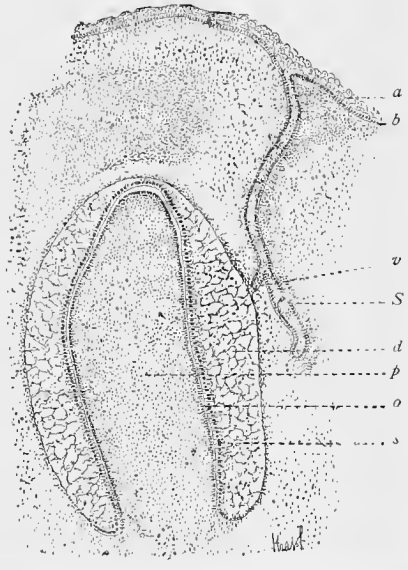


Fig. 182.

Figs. 179-182.—Four stages in the development of a tooth in a sheep embryo (from the lower jaw): Fig. 179, Anlage of the enamel germ connected with the oral epithelium by the enamel ledge; Fig. 180, first trace of the dental papilla; Fig. 181, advanced stage with larger papilla and differentiating enamel pulp; Fig. 182, budding from the enamel ledge of the Anlage of the enamel germ, which later goes to form the enamel of a permanent tooth; at the periphery of the papilla the odontoblasts are beginning to differentiate. Figs. 179, 180, and 181,  $\times 110$ ; Fig. 182,  $\times 40$ . *a, a, a, a*, Epithelium of the oral cavity; *b, b, b, b*, its basal layer; *c, c, c*, the superficial cells of the enamel organ; *d, d, d, d*, enamel pulp; *p, p, p*, dental papilla; *s, s*, enamel-forming elements (enamel cells); *o*, odontoblasts; *S*, enamel germ of the permanent tooth; *v*, part of the enamel ledge of a temporary tooth; *a*, surrounding connective tissue.

homogeneous substance which fuses to form a continuous layer, the *membrana præformativa*. The further development of the dentin is as follows: Its ground-substance is deposited at the cost of the lateral portions of the odontoblasts (under the *membrana præformativa*), the axial portion of the cells remaining intact as the dentinal fibers; the basal portions of the cells containing the nuclei persist, later constituting the odontoblasts of the adult pulp. By the fusion of the segments of the ground-substance formed by each cell, it becomes a homogeneous mass, but soon displays connective-tissue fibrils which gradually undergo a process of calcification. The mem-

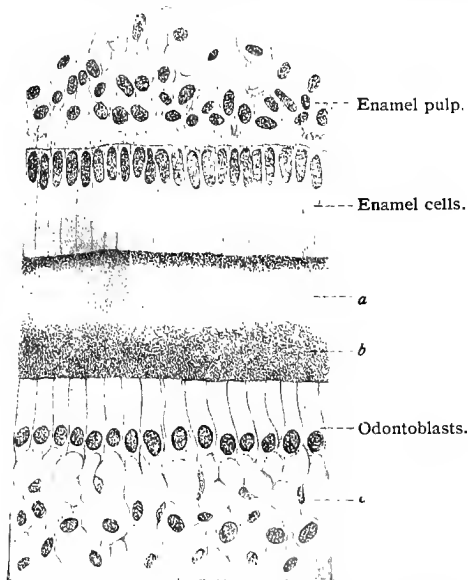


Fig. 183.—A portion of a cross-section through a developing tooth (later stage than in Fig. 182);  $\times 720$ : The dentin is formed, but has become homogeneous from calcification. Bleu de Lyon differentiates it into zones (*a* and *b*). At *c* is seen the intimate relationship of the odontoblasts to the tissue of the dental pulp.

Remains of this regressive portion persist as the epithelial nests of the dental root (compare p. 216).

The contents of the dental papillæ change into the tissue of the dental pulp.

As early as the third month outgrowths appear on the inner side of the enamel ledge next to the partly developed milk-teeth, which represent the anlagen of the enamel organs of the permanent teeth. Their further development is similar to that of the milk teeth. The enamel organs of the molars are also developed from an enamel ledge which is practically a backward continuation of the embryonic enamel ledge. With their crowns presenting, the temporary teeth

*membrana præformativa* has no fibers and calcifies much later. It lies immediately beneath the enamel or the cementum, and in the normal tooth always contains small interglobular spaces. In the adult tooth this membrane in its entirety is known as *Tomes' granular layer*.

The *cementum* is merely a periosteal growth of bone originating in the tissue of the dental sac and adhering to the dentin. Although at first the enamel organ almost entirely surrounds the dentinal papilla, later a portion of that part of it in the region of the fang is absorbed in order to allow the cementum to reach the surface of the dentin.

at last break through the epithelium of the gums. When the development of the permanent teeth is so far advanced that they are ready to perforate, regressive processes begin at the roots of the milk-teeth, which are due, as in like conditions of the bone, to the action of certain cells, which are here known as "odontoclasts." The crowns of the milk-teeth are then thrown off, one by one, by the growing permanent teeth.

For further information as to the teeth and their development, see the articles by Ebner (91), whose studies we have to a great extent followed on this subject.

## 2. THE TONGUE.

**The Lingual Mucous Membrane and its Papillæ.**—The mucous membrane of the tongue differs in general very little from

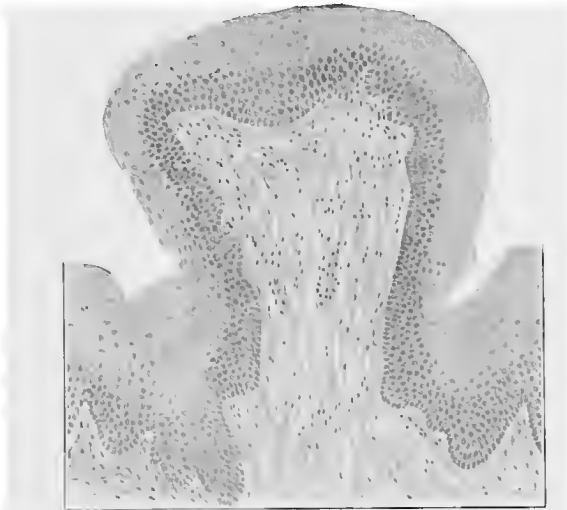

Fig. 184.—Fungiform papilla from human tongue.

that lining the rest of the oral cavity. It must, however, be borne in mind that in the greater part of the tongue the submucosa is poorly developed, and as a consequence the mucous membrane on the upper surface and base of the tongue is scarcely movable. Other peculiarities of the lingual mucous membrane are the absence of glands in the mucosa on the upper surface of the tongue,—although glands are found in the musculature of the tongue, their ducts passing through the mucosa,—the presence of epithelial papillæ, and of lymph-follicles at the base of the tongue.

The upper surface of the tongue is roughened by the presence of epithelial projections, the *lingual papillæ*. The latter are almost entirely epithelial structures, and should not be confused with those papillæ which are composed exclusively of connective tissue. There

are several classes of lingual papillæ—the filiform, the fungiform, and the circumvallate papillæ. The most numerous are the thread-like or *filiform papillæ* (from 0.7 to 3 mm. long). These are scattered over the entire upper surface of the tongue, and consist of conic projections of the epithelium and of the mucosa. The connective-tissue portions of these papillæ are very thin and long. The basal layers of the epithelium can not be distinguished from the same layers covering the surrounding mucosa, but the more super-

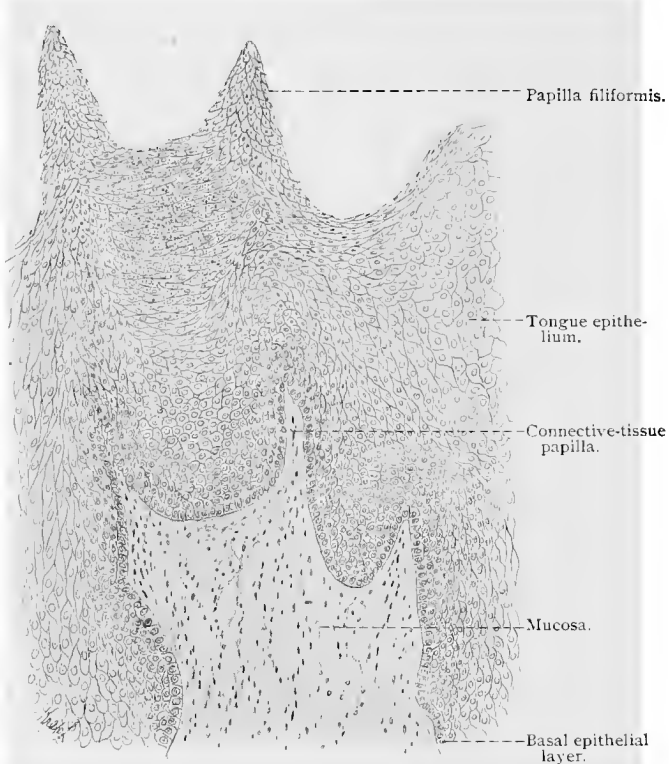


Fig. 185.—From a cross-section of the human tongue, showing short, thread-like papillæ (filiform);  $\times 140$ .

ficial layers are differentiated, in that their cells are arranged parallel to the long axes of the papillæ and overlap each other like tiles (Fig. 185). Their free ends are often continued into several spine-like processes. Less numerous than the filiform are the *fungiform papillæ* (from 0.7 to 1.8 mm. in height) scattered here and there between the former. They are nearly hemispheric in shape, and are joined to the surface of the tongue by a slightly constricted base. At times they are even partly sunk into the mucous membrane. The mucosa is raised under the epithelium to form connective-tissue papillæ (Fig. 184). On the free surface of the fungiform papillæ

are sometimes found taste-buds, or taste-goblets, which lie imbedded in the epithelium and extend through its entire thickness. The *circumvallate papillæ* occupy a definite region on the upper surface of the tongue, and are arranged in two rows, forming almost a right angle, with the apex directed backward and situated just in front of the foramen cæcum (Morgagni). These papillæ are few in number, about eight to fifteen in all. In shape they are similar to those of the fungiform type, but are much larger (about 1 or 2 mm. in diameter), and sunk so deeply into the mucous membrane that the latter forms a wall around their sides. Here also the mucosa passes up into the papillæ and forms connective-tissue papillæ of its own at the upper surface, while at the sides it merely adheres to the smooth inner surface of the epithelial layer. Taste-buds are found in the epithelium at the sides of the papillæ, and also in that of the ridges surrounding the papillæ. At the sides of the human tongue and near its base are the so-called *fimbriæ linguæ*. These are irregular folds of mucous membrane,

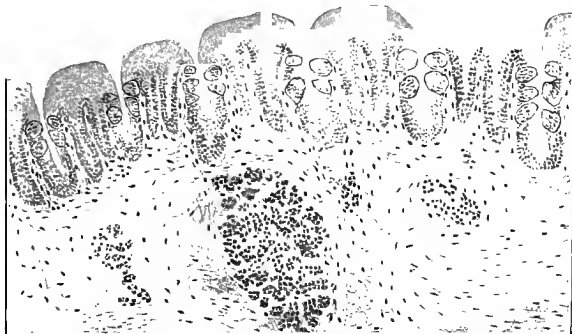


Fig. 186.—Longitudinal section of foliate papilla of rabbit, showing taste-buds.

the sides of which also contain taste-buds. In the rabbit they are more regular in structure and consist of parallel folds of mucous membrane thickly dotted with taste-buds, and are termed the *foliate papillæ*. In place of the circumvallate papillæ, the guinea-pig possesses structures similar to the foliate papillæ of the rabbit.

Into the depressions in which the circumvallate papillæ lie and into those between the folds of the *fimbriæ linguæ* open the ducts of numerous serous glands, the glands of Ebner (see below).

**The Taste-buds.**—The gustatory organs in the form of *taste-buds* are found on the surface of the tongue, principally on the lateral surfaces of the circumvallate papillæ and the *fimbriæ linguæ* (foliate papillæ). They are also occasionally met with in the epithelium of the fungiform papillæ and the soft palate, and on the posterior surface of the epiglottis. They always lie imbedded in the epithelium and extend through its entire thickness; they are ovoid in form, with base downward and the smaller pole at the

surface. The whole structure is surrounded by the epithelium of the mucous membrane of the regions in which they occur, except at the attenuated outer end of the taste-bud, where, by means of a small opening, the *taste-pore*, it communicates with the oral cavity. Most of the cells constituting the taste-buds are elongated, spindle-shaped structures, extending from one end of the organ to the other, with spaces between them. There are four varieties of these cells: (1) The *outer sustentacular* or tegmental cells, lying at the periphery of the organ with a nucleus in their center, and having a short, cone-shaped cuticular projection; (2) the *inner sustentacular* or rod-shaped cells, which are more slender structures with basally situated nuclei and without a cuticular projection; between the latter are (3) elongated, spindle-shaped, neuro-epithe-

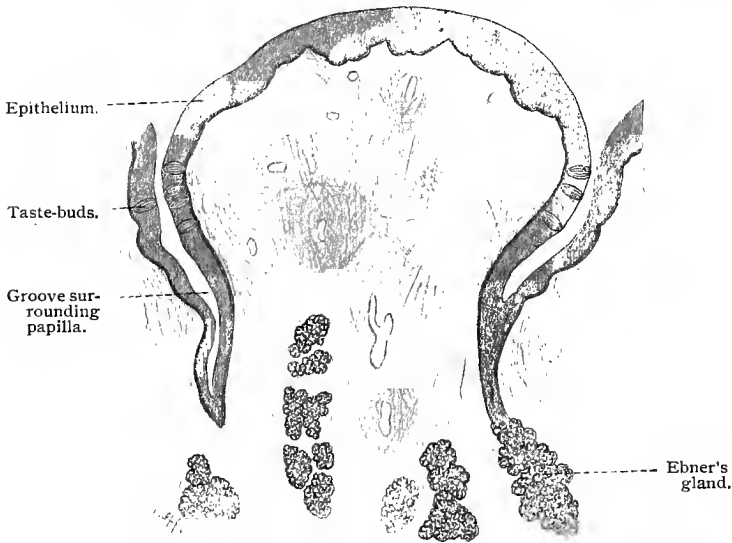


Fig. 187.—Longitudinal section of a human circumvallate papilla;  $\times 20$ .

lial cells, with the nucleus of each in the thickest portion of the cell, and with slender, stiff processes projecting into the taste-pore; (4) a few broad basal cells, communicating with each other as well as with the sustentacular cells by numerous processes. We have, therefore, in the cells of the first, second, and probably fourth varieties, elements which belong exclusively to the sustentacular apparatus of the organ (Hermann, 85, 88).

Von Ebner found in the taste-buds of the circumvallate papillæ of man, monkey, and cat, as well as of the papillæ foliatæ of the rabbit, an open space situated between the taste-pore and the tip of the taste-bud (Fig. 188). These spaces vary according to the species, and are bounded above by the summits of the tegmental cells and laterally and below by the more centrally situated sus-

tentacular cells. The cavities are often  $10\ \mu$  in depth, and are filled with a fluid apparently in communication with the fluid of the depression into which the circumvallate papillæ are sunk. The processes of the neuro-epithelial cells project into the cavity from its floor and lateral walls, but do not extend as far as the taste-pore.

The circumvallate papillæ are differentiated from the adjacent surface of the tongue by the development of a solid encircling epithelial ridge. Numerous taste-buds appear on the surface quite early in the history of the embryo. These, however, disappear completely when the permanent taste buds develop from the basal cells of the epithelial ridge. Similar phenomena occur in the fungiform papillæ (Hermann, 88).

The neural epithelia of the taste-goblets were formerly regarded as directly connected with the

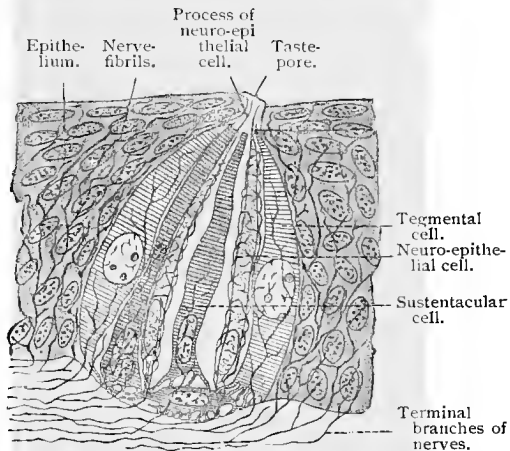


Fig. 188.—Schematic representation of a taste-goblet (partly after Hermann, 88).

nerve-fibers by means of long processes, but the latest researches have shown that dendrites of sensory neurones (sensory nerves) enter the taste-buds and end free in telodendria. The latter surround the neuro-epithelial and, to some extent, the sustentacular cells, their relations depending upon contact.

**The Lymph-follicles of the Tongue (Folliculi linguales) and the Tonsils.**—At the root of the tongue, and especially at its sides, are numerous elevations due to the increased quantity of lymphoid tissue found in the mucosa of these regions, the lingual tonsils, or lingual follicles. In the center of each follicle is a cavity communicating with the exterior and caused by an invagination of the epithelium. The lymphoid tissue contains a number of more or less distinctly defined lymph-nodules, some even showing germ centers (*vid.* p. 178). The whole structure is surrounded by a connective-tissue capsule. The epithelial walls of the follicular cavities often show extensive degenerative changes, which are accompanied by increased migration of leucocytes into the oral cavity. These leucocytes change (according to Stöhr, 84) into the so-called mucous or salivary corpuscles of the saliva. The pharyngeal tonsils may be regarded as clusters of small lymph-follicles,

similar to those found in the tongue. They are covered by a stratified pavement epithelium, resting on a mucosa possessing papillæ folded to form pits or crypts of irregular shape. The adenoid tissue of the tonsil is found in the form of diffuse adenoid tissue and a varying number of more or less clearly defined follicles of adenoid tissue often showing germ centers of Flemming.

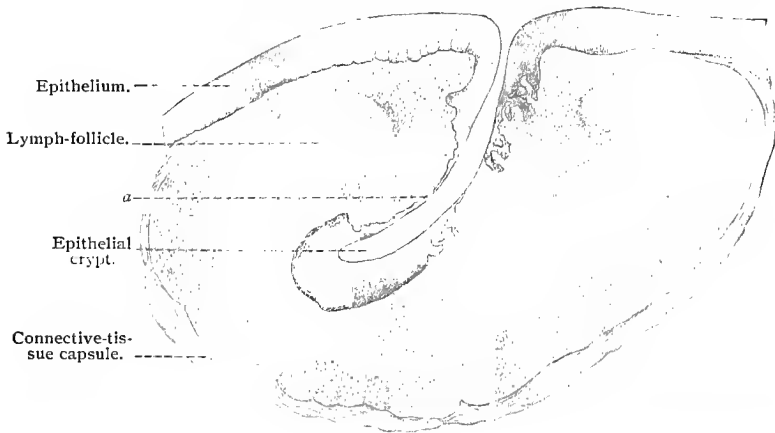


Fig. 189.—Section through tonsil of dog;  $\times 20$ : At *a* and at the opposite side the epithelium is composed of a very thin layer of cells.

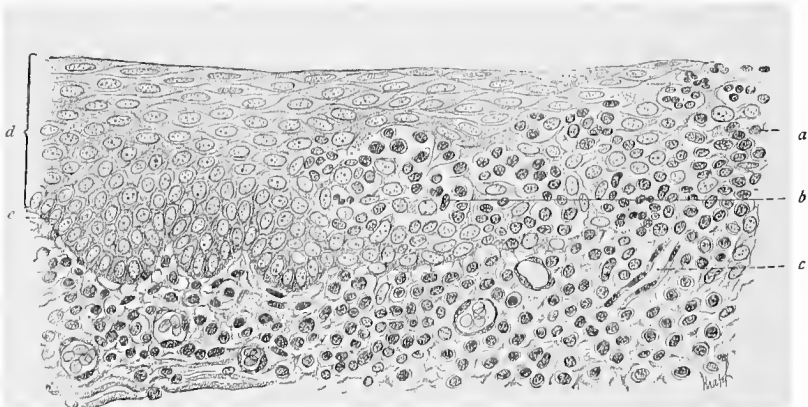


Fig. 190.—The area designated by *a* in the previous illustration, shown by a higher magnification;  $\times$  about 150: *a*, Leucocytes in the epithelium; *b*, one of the spaces in the epithelium filled with leucocytes and more or less changed epithelial cells; *c*, blood-vessel; *d*, normal epithelium; *e*, basal cell of the same.

The epithelium lining the crypts or cavities of the tonsils shows, as in the lingual follicles, extensive degenerative changes, resulting mainly in the formation of variously shaped, communicating spaces filled with lymphocytes and leucocytes. (See Fig. 190.)

Besides the nerves terminating in the taste-buds, the tongue is

richly supplied with sensory nerves which terminate in free sensory endings, which may be traced into the epithelium, and which are especially numerous in the fungiform and circumvallate papillæ; or in smaller or larger end-bulbs of Krause found in the mucosa of the fungiform papillæ. The motor nerves of the tongue terminate in motor-endings.

### GLANDS OF THE ORAL CAVITY.

The glands of the oral cavity comprise numerous lobular, tubulo-acinous glands situated in the mucosa and submucosa of the lips, cheeks, and tongue, and three pairs of lobar, tubulo-acinous glands — the parotid, submaxillary, and sublingual glands. These are classified according to their secretions into those secreting principally mucus (human sublingual and many of the smaller oral glands), and known as mucous glands; those secreting a fluid albuminoid substance containing no mucus, the serous glands (parotid glands and the small glands near the circumvallate papillæ); and those having a mixed secretion, mucous and serous glands (human submaxillary). The ducts of all these glands open into the cavity of the mouth. The ducts of the smaller oral glands are, as a rule, short and pass up through the mucosa and the epithelium to open on the free surface. The principal excretory ducts of the salivary glands are Steno's ducts (Stenson's ducts), passing from the parotid glands to the mouth; Wharton's ducts, the ducts of the submaxillary glands, and Bartholin's ducts for the sublingual glands. The salivary glands consist of numerous lobules and small lobes of glandular tissue, surrounded by a thin fibrous-tissue capsule which sends septa and trabeculæ between the lobules and lobes. The duct of each gland on reaching the gland divides into smaller ducts, which penetrate the gland between the lobes, the interlobular ducts; these in turn divide into ducts of the next order, which pass between the lobules, the interlobular ducts. The interlobular ducts pass over into short cylindrical tubes which enter the lobules, and are known as intralobular ducts. These are followed by very short, narrow tubules, the intermediate ducts or tubules,

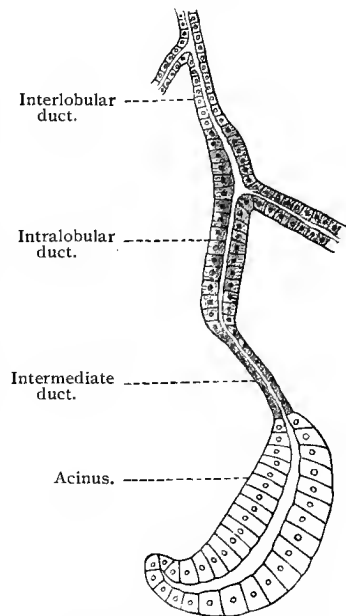


Fig. 191.—Scheme of a salivary gland.

by very short, narrow tubules, the intermediate ducts or tubules,

which finally terminate in the alveoli or acini, irregular and somewhat tortuous tubular structures with a lumen and possessing an epithelium characteristic of the particular variety of the gland (see below). The epithelium lining the different portions of the large excretory ducts varies somewhat. For a short distance from their oral end they are lined by a stratified columnar epithelium consisting of two layers of cells (Wharton's ducts are now and then lined for a short distance by a stratified pavement epithelium continuous with that lining the mouth). Beyond this stratified columnar epithelium, which extends for a variable distance, the large excretory ducts, the interlobar and interlobular ducts are lined by a pseudostratified columnar epithelium, possessing two rows of nuclei (Steiner). Outside of the epithelial lining there is found a firm fibro-elastic covering, forming the wall of the ducts. The intralobular ducts are lined by a single layer of columnar cells, the basal half of each cell showing a distinct striation. The intermediate portions of the ducts are lined by a low, cubic, or flattened epithelium.

Between the membrana propria and the secreting epithelium of the tube, and more especially in the acini, are branched cells which anastomose with each other, the so-called *basket cells*. Their processes penetrate between the glandular cells and form a supporting structure for them. The homogeneous membrana propria surrounding the entire glandular tube is in close relationship to these cells.

We shall now consider more in detail the structure of the alveoli or acini of the salivary glands.

### SALIVARY GLANDS.

**The Parotid Gland (Serous Gland).**—The epithelial cells lining the acini of this gland are short, irregularly columnar or cubic cells, their structure changing according to their physiologic condition. When at rest the secreting cells are only slightly granulated and contain a large quantity of clear secretion (paraplasm), while the nuclei are irregular and indented. As soon as the protoplasm of the cells commences the formation of secretion, the cells become smaller, more granular and opaque, and their nuclei assume a spheric shape; when, however, the cells throw off a portion of the granular material, an immediate increase in their protoplasm is noticed. After a long period of secretion the cells become still smaller and their contents still more turbid. They now contain very little protoplasm. These phenomena can only be regarded as due to the fact that the granular paraplasm is formed at the expense of the protoplasm of the cell during the period of rest.

**The Sublingual Gland (Mucous Gland).**—In the acini of mucous glands there are found two varieties of cells: (1) True mucous cells, which, when filled with secretion, are large and

clear, with their nuclei always at the periphery. During the expulsion of the secretion the mucous cells decrease in size and become cloudy, while the nuclei leave the periphery and increase in size. (2) Cells rich in protoplasm, situated in close apposition to the membrana propria. These cells resemble in structure serous cells, and are found either singly or in groups of crescentic shape. They are known as the *crescents of Gianuzzi* or the *demilunes of Heidenhain*. The margins of the individual cells composing the crescents are often so faintly outlined that the whole structure has the appearance of a large polynuclear giant cell.

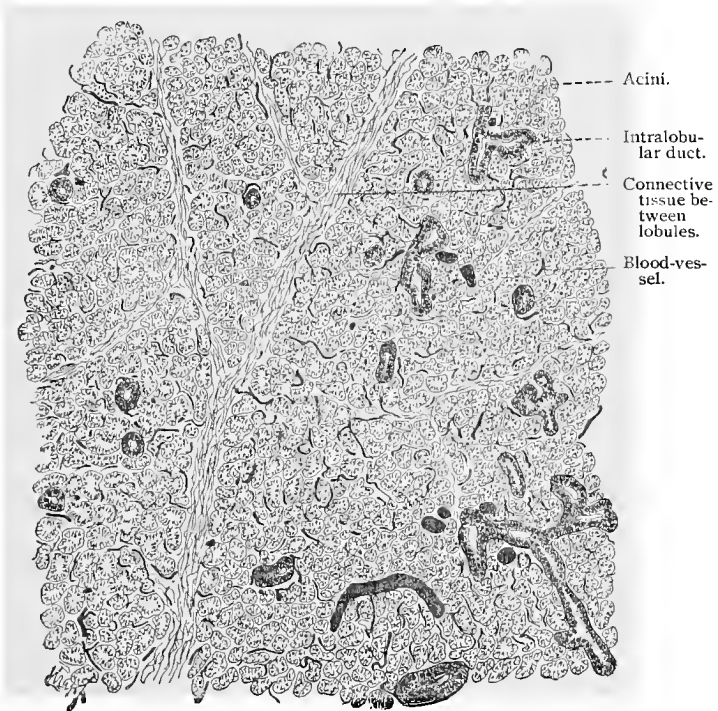


Fig. 192.—Section through salivary gland of rabbit, with injected blood-vessels;  $\times 70$ .

The demilunar cells have been variously interpreted by different observers. They have been regarded as permanent cells with a special secretion, as transitional structures, and again as cells destined to replace the degenerated mucous cells. Stöhr (87) believes that the cells of the acini are never destroyed in the process of mucous secretion, and that the crescents of Gianuzzi are therefore merely a complex of cells containing no secretion, which have been crowded to the wall by the adjacent enlarged and distended cells. Solger (96), on the other hand, does not regard the demilunes as transitional structures whose function is to replace the

destroyed cells, but considers them to be permanent secreting cells—an opinion which he bases on the results of special methods of investigation. According to him, then, the mucous salivary glands are mixed glands, in that the demilunes consist of cells of a serous type, while the remaining elements are mucous in character. The destruction of mucous cells during secretion is not admitted by him

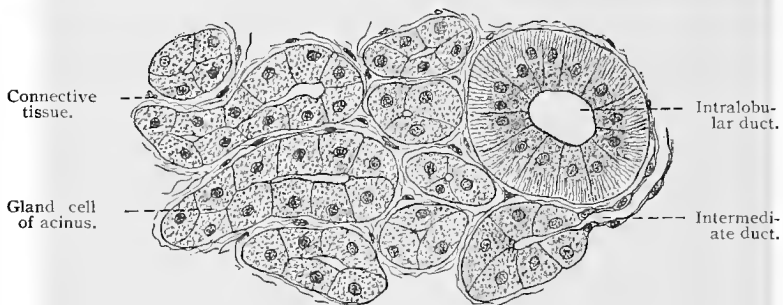


Fig. 193.—Section from parotid gland of man.

(compare also R. Krause). This latter view seems more in accord with recent observations.

**The Submaxillary Gland (Mixed Gland).**—With regard to the mixed glands it is sufficient to say that there is a simultaneous secretion of serous and mucous fluids, and that these two substances are produced in separate but adjacent acini, of which the

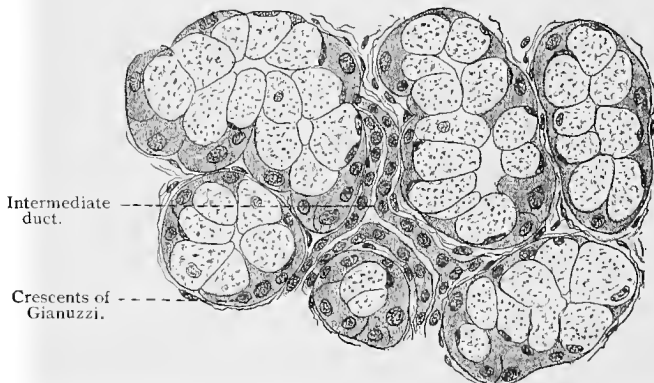


Fig. 194.—From section of human sublingual gland.

one type possesses a structure identical with that found in the parotid and the other with that in the sublingual.

By means of various methods the existence of a network of tubules surrounding the glandular cells may be demonstrated both in the serous and mucous glands. The same arrangement may be

observed in the case of the cells forming the demilunes. The course of these tubules may be followed to their junction with the lumen of the secreting portion of the gland tubule, and the whole structure would seem to indicate that the entire surface of the cells is concerned in the act of secretion (Erik Müller, 95; Stöhr, 96, II).

As to the part that the intermediate tubules and the intralobular tubes play in the process of secretion, Merkel's (83) theory is of interest. He believes that the former yield a part of the water in the saliva, while the salts are furnished by the rod-shaped epithelium of the intralobular tubes. These views of Merkel have been questioned, as it has been shown by chemic analysis that the relative quantity of water and salts in the secretion of the salivary glands is not at all proportionate to the number of the intermediate tubules and intralobular tubes. For example, Werther finds that although a great many intermediate tubules are present in the parotid gland of the rabbit and none at all in the submaxillary gland of the dog, nevertheless the secretions of these glands contain equal quantities of water. Furthermore, the secretions of the parotid of the rabbit and of the sublingual of the dog show equal quantities of salts, in spite of the fact that in the former there are large numbers of intralobular tubes with rod-shaped epithelium and in the latter none at all.

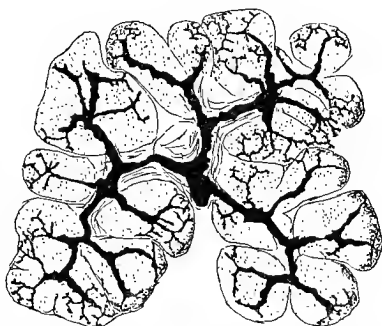


Fig. 195.—A number of alveoli from the submaxillary gland of dog, stained in chrome-silver, showing some of the fine intercellular tubules.

#### THE SMALL GLANDS OF THE MOUTH.

Besides the larger glands, there are in the oral cavity numerous small lobular, tubulo-acinous and simple branched tubulo-acinous glands. They are mostly of the mixed type, and are called, according to their location, *glandulæ labiales*, *palatinæ* and *linguales*. Serous glands, known as *v. Ebner's glands*, occur in the tongue, their ducts opening into the depressions of the circumvallate and foliate papillæ. The absence of intralobular tubes and well-defined intermediate tubules is characteristic of all the smaller glands of the oral cavity. As a consequence the secreting tubules are composed almost entirely of those parts corresponding to the acini of the larger glands. It appears that the smaller mucous glands, except those of the lips (J. Nadler), do not, as a rule, contain typical demilunes.

The salivary glands and smaller glands of the mouth have a

rich *blood supply*. In the salivary glands the arteries follow the ducts through their repeated branching, ultimately ending in capillaries which form a network inclosing the acini and the terminal portions of the system of ducts.

The *lymphatics* begin in clefts in the connective tissue surrounding and separating the acini. Larger lymph-vessels are found in the connective tissue separating the lobules and lobes of the gland.

The *nerve supply* of the salivary glands, may, owing to the importance of these structures, receive somewhat fuller consideration. Their nerve supply is from several sources. That of the sublingual and submaxillary glands will be considered first. Sensory nerve-fibers (no doubt the dendrites of sensory neurones, the cell-bodies of which are situated in the geniculate ganglion) terminate in free sensory endings in the large excretory ducts and their branches. These medullated fibers accompany the ducts in the form of small bundles. From place to place one or several fibers leave these bundles and, after dividing a number of times, lose their medullary sheaths. After further division the nonmedullated branches form plexuses under the epithelial lining of the ducts. From the fibers of these plexuses terminal fibrils are given off, which enter the epithelium, to end, often near the free surface, on the epithelial cells (Arnstein, 95; Huber, 96). The secretory cells of the acini receive their innervation from sympathetic neurones. The cell-bodies of those supplying the sublingual glands are grouped in a number of small, sympathetic ganglia situated in a small triangle formed by the lingual nerve, the chorda tympani and Wharton's duct, the chordal-lingual triangle. These ganglia may be known as the sublingual ganglia (Langley). The cell-bodies of the sympathetic neurones supplying the secretory cells of the submaxillary glands are grouped in small ganglia situated on Wharton's duct just before it enters the gland, in the hilum of the gland, and on the interlobar and interlobular ducts; they may be spoken of collectively as the submaxillary ganglia. In the glands under discussion, the neuraxes of the sympathetic neurones are grouped to form small bundles, which divide repeatedly, the resulting divisions joining to form plexuses situated in the outer portion of the walls of the ducts, and as such may be followed along the ducts, the bundles of nerve-fibers becoming smaller and the division of the bundles of fibers and the individual fibers occurring oftener as the smaller divisions of the system of ducts are reached. On reaching the acini, the terminal branches of the nerve-fibers form a plexus outside of the basement membrane, *epilamellar plexus*; from this branches are given off which penetrate the basement membrane, some forming a *hypolamellar plexus*, others ending on the gland-cells in small granules or clusters of granules (Arnstein). Throughout their entire course the neuraxes of the sympathetic neurones are varicose, nonmedullated nerve-fibers. The nerve-fibers of the chorda tympani end in terminal end-baskets, inclosing the cell-bodies of the sympathetic

neurones found in the sublingual and submaxillary ganglia, and not in the glands, as generally stated by writers. The increase of secretion from the submaxillary and sublingual glands on direct or indirect stimulation of the chorda tympani is due, therefore, not to a direct stimulation of the gland-cells by the fibers of this nerve, but to a stimulation of the sympathetic neurones of the sublingual and submaxillary ganglia, the neuraxes of which convey the impulse to the gland-cells. These glands have a further nerve supply from the superior cervical ganglia of the cervical sympathetic. The neuraxes of sympathetic neurones, the cell-bodies of which are situated in the superior cervical ganglia, accompany the blood-vessels to the sublingual and submaxillary glands; their mode of termination is, however, not as yet determined. The cell-bodies of the sympathetic neurones here in question are surrounded by end-baskets of nerves which leave the spinal cord through the second, third, and fourth dorsal spinal roots. The blood-vessels of the salivary glands are also richly supplied with vasomotor nerves, the neuraxes of sympathetic neurones, which terminate on the muscle-cells of their walls. The nerve supply of the parotid glands is, in the main, like that of the other salivary glands here described, although it has not been worked out with the same detail. The cell-bodies of the sympathetic neurones, the neuraxes of which innervate the gland-cells, are, it would appear, situated in the otic ganglia. The nerve-ending in the smaller glands of the mouth is similar to that given for the salivary glands, as has been shown by Retzius and other observers.

It is very probable that the cell-bodies of the sympathetic neurones, the neuraxes of which innervate the glands of the tongue, are situated in the small sympathetic ganglia found on the lingual branches of the glossopharyngeal and lingual nerves.

## B. THE PHARYNX AND ESOPHAGUS.

The mucous membrane of the pharynx and esophagus is similar in structure to that of the oral cavity.

The epithelium is of the stratified squamous variety, and also contains prickle cells and keratohyalin. (See Skin.) A stratified ciliated epithelium is present only in the fornix in the region of the posterior nares. The area covered by this type of epithelium is more extensive in the fetus and new-born, and extends over the whole nasopharyngeal vault. In the human embryo the superficial epithelial cells of the esophagus possess cilia up to the thirty-second week (Neumann, 76). The papillæ of the mucosa are loosely arranged and are in the form of slender cones. The mucosa of the pharynx contains diffuse adenoid tissue rich in cells which in some places forms accessory tonsils (*vid.* p. 225). There are but few mucous glands in the submucous tissue of the esophagus, but when present they contain well-marked demilunes. In

man the ducts of these glands do not reach the surface between the connective-tissue papillæ, as in the external skin, but pass up through them into the epithelium and thus to the surface. A layer consisting of nonstriated muscle-fibers, the *muscularis mucosæ*, the majority of the cells of which show a longitudinal arrangement, is found between the mucosa and submucosa in the esophagus, but not in the pharynx.

The external muscular coat of the pharynx is made up of transversely striated muscle-fibers, arranged in a complicated manner. This tissue extends downward to about the middle of the

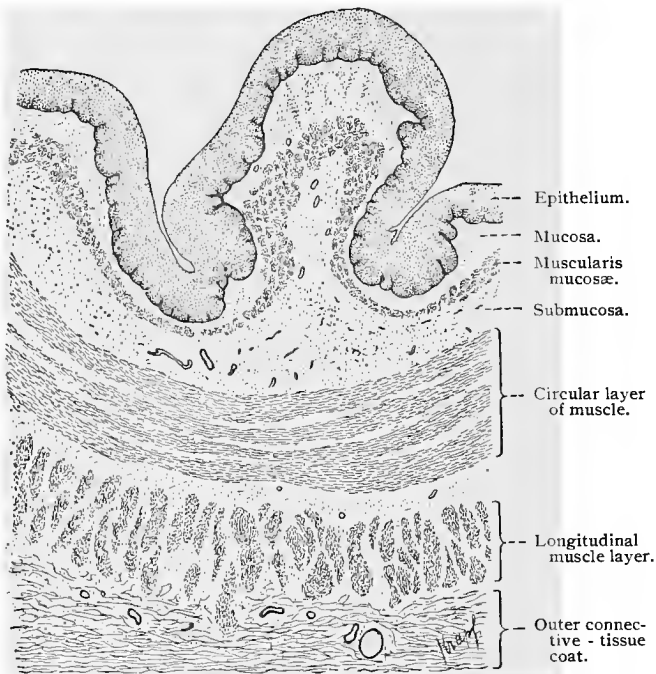


Fig. 196.—Section of esophagus of dog ;  $\times 18$ .

esophagus, in which it consists of an outer longitudinal and an inner circular layer. In the lower half of the esophagus nonstriated muscle-fibers alone are present. There is no sharply defined line of demarcation between the two types of muscular tissue, as the fibers of the unstriped variety penetrate for some distance upward into the substance of the striated muscle, giving the tissue here a mixed character.

## C. THE STOMACH AND INTESTINE.

### 1. GENERAL STRUCTURE OF THE INTESTINAL MUCOUS MEMBRANE.

The mucous membrane of the stomach and intestine, unlike that of the esophagus and oral cavity, possesses an epithelium of the simple columnar variety with elongated cells (about  $22 \mu$  in

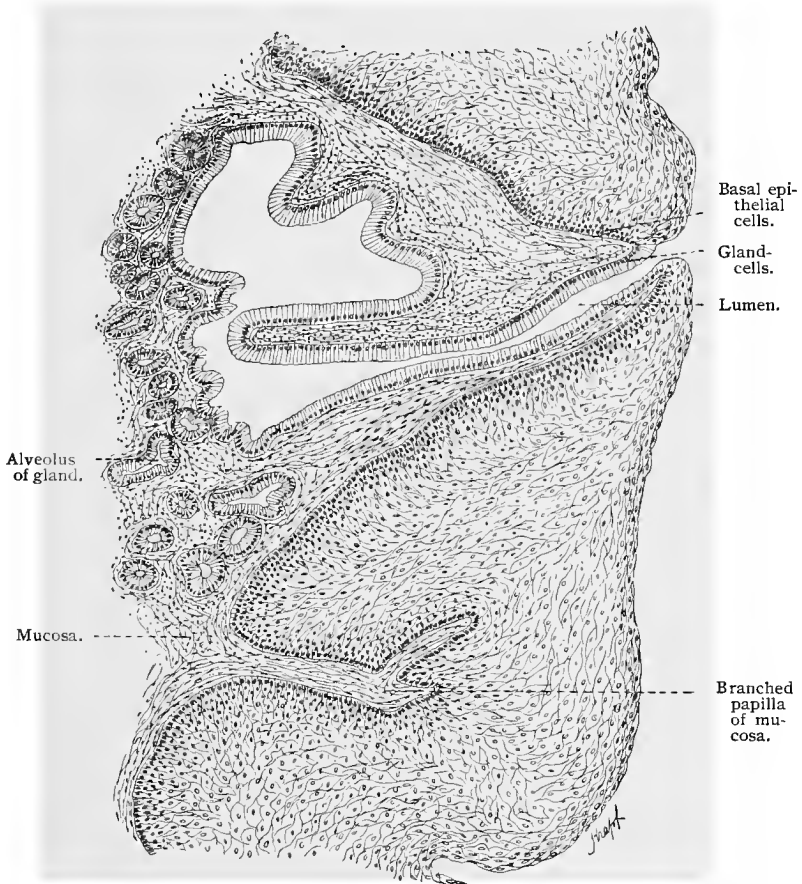


Fig. 197.—Part of section of human esophagus, showing duct of mucous gland;  $\times 120$ .

height). In the intestine the epithelium shows a well-marked striated cuticular border, striated protoplasm in the outer ends of the cells, extending to the immediate vicinity of the nuclei, which are situated in the basal portions of the cells. The basal portion of each cell consists of nonstriated protoplasm, ending in a longer or shorter process which extends to the basement membrane, or possibly

even penetrates it. The epithelial cells have the power of producing mucus, a phenomenon which, in the normal condition, rarely embraces whole areas of epithelium; these cells (goblet cells) are usually surrounded by others which are unchanged (for details about goblet cells see General Histology, p. 81). Throughout the entire intestinal tract the epithelium forms simple, branched, and compound tubular and alveolar glands. These are depressions lying in the mucosa, and only in the duodenum extend beyond it into the submucosa.

The mucosa consists of adenoid tissue, containing relatively few cells. It fills the interstices between the glands, and often forms a thin but continuous layer (granular layer of P. Mall) below the glands. It is therefore obvious that the development of the mucosa is inversely proportionate to the number and the density of arrangement of the glands; when the latter are present in large numbers, as, for instance, in the stomach, the mucosa is reduced to a minimum. In the small intestine it forms not only the permanent folds, but also certain finger-like elevations known as villi, which are covered with epithelium and project into the lumen of the intestine, thus increasing to a considerable extent the surface area of the mucous membrane. In the mucosa are found small nodules of adenoid tissue. These are spoken of as lenticular glands when occurring in the stomach, as solitary glands when found in the upper portion of the small intestine and in the large intestine. In the lower portion of the small intestine they are grouped to form the agminated glands, or Peyer's patches, which, when large, extend into the submucosa. Beneath the stratum proprium is a layer consisting of two or three strata of unstriped muscle-fibers, the *muscularis mucosæ*. As a rule, it is composed of an inner circular and an outer longitudinal layer. This arrangement is interrupted only where the larger glands and follicles penetrate into the submucosa. The epithelium with the glands, the mucosa with its lymph-nodules, and the *muscularis mucosæ* form together the *mucous membrane*, or *tunica mucosa*.

Below the mucous membrane is the connective-tissue *submucosa*. This is characterized by its loose structure, and consequently affords considerable mobility to the mucous membrane. In the small intestine it forms a large number of permanent transverse folds known as *valvulæ conniventes* (Kerkring). In the submucosa of the duodenum occur the secreting portions of *Brunner's glands* (glandulæ duodenales), and in the small intestine the larger lymph-nodes and Peyer's patches.

External to the submucosa is the muscular coat, which generally consists of two layers of unstriped muscle-tissue. The inner layer is composed of circular fibers (stratum circulare); the outer layer, of longitudinal fibers (stratum longitudinale). In the colon the longitudinal layer forms definite bands, the *tæniæ coli*. In some regions the circular fibers are also considerably reinforced, particularly in

the *plicæ sigmoideæ* which lie between the *tæniæ coli*. At these points the longitudinal layer also is thickened. In the rectum the circular fibers form the internal sphincter ani muscle. In the stomach a third layer is added to the two already mentioned, with fibers running obliquely. It lies internal to the circular fibers, but does not form a continuous layer.

According to Legge, elastic fibers are present throughout the entire digestive tract of all adult mammalia and vary only in minor details in the different species. In regions in which the tunica muscularis is prominent the elastic fibers attain a considerable size. There is also a difference in their development in carnivora and herbivora. In general, they form a dense network, present not only in the serous layer, but also in the submucosa and beneath the epithelium. These fibers preserve the elasticity of the intestinal walls and resist any hyperextension of the glands and follicles.

The intestine is covered externally by the peritoneum, forming the serous coat, which consists of an inner, very thin connective-tissue layer (subserosa) and an outer layer of mesothelial cells.

## 2. THE STOMACH.

The general structure of the gastric mucous membrane is essentially the same as that of the intestinal canal. It presents, however, depressions known as *gastric crypts*, due to an infolding of the epithelium into which the gastric glands open. In the fundus the crypts attain a depth of from one-fifth to one-sixth the thickness of the mucous membrane. In the pylorus they are deeper, many of them here extending through half the mucous membrane and some even reaching the muscularis mucosæ. The epithelium of the crypts and that of the folds between them is composed of long, slender cells, with basally situated nuclei. That portion of the cell-body near its free margin contains very little protoplasm, but is, on the other hand, rich in paraplast; the region of the cell containing the nucleus possesses more protoplasm. This part of the cell extends downward in a curved process of diminishing size, which assumes a position parallel to the corresponding parts of the neighboring cells, and finally penetrates the basement membrane. Into a single gastric crypt of the human fundus empty from three to seven gastric glands. Each gland consists of a simple tube, from

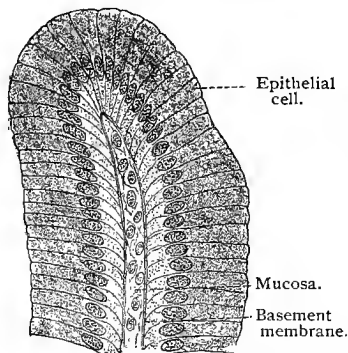


Fig. 198. — Epithelium of human stomach, covering the fold of mucosa between two gastric crypts;  $\times 700$ . Technic No. 241.

Each gland consists of a simple tube, from

0.4 to 2.2 mm. in length, whose inner segment, opening into the crypt, is quite narrow, and is known as the *neck of the gland*. The main portion of the gland is called its *body*, and the region at the distal blind end the *fundus*. In the gastric glands, more especially in the cardia and fundus of the stomach, two varieties of gland-cells are found. The cells of the one variety lie against the walls of the gland—that is, they rest on its basement membrane—and are particularly

numerous in the neck and body of the gland, but not so numerous in its fundus. These are known as the *parietal, oxyntic or delomorphous cells* (R. Heidenhain, 69; Rollet, 70). Their bodies often extend more or less beyond the even line

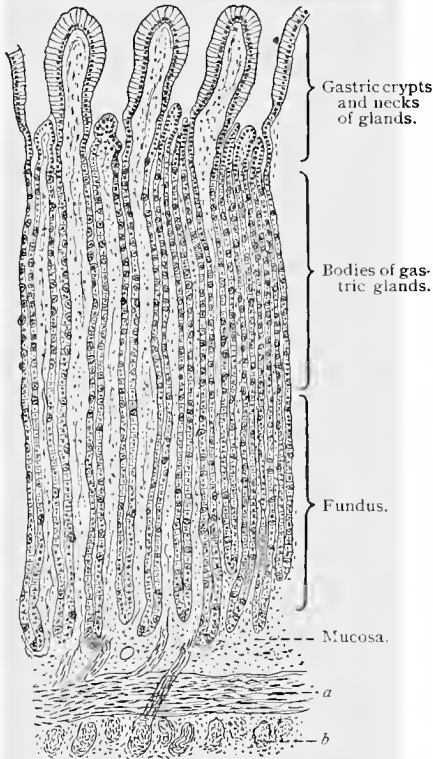


Fig. 199.—From vertical section through fundus of human stomach;  $\times 60$ : *a* and *b*, Interlacing fibers of the muscularis mucosæ; from *a* and *b* muscular fibers enter the mucosa. The fibers of the layer *b* penetrate those of layer *a*.

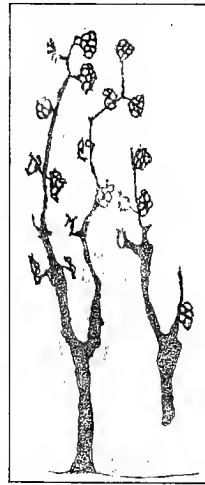

Fig. 200.—A number of gastric glands from the fundus of the stomach of young dog, stained after the chrome-silver method, showing the system of fine canals surrounding the parietal cells and communicating with the lumen of the glands.

of the remaining cells, thus forming, together with the membrana propria, a protuberance (particularly noticeable in the pig, where almost the entire cell may be enveloped by the basement membrane, giving it an appearance of being entirely extraglandular). Toward the lumen of the gland the contour of these cells is modified by pressure on the part of the adjacent cells belonging to the other variety, and they are indented according to the number of the latter.

Occasionally, a process is seen extending from a parietal cell to the lumen of the gland. The parietal cells are larger than the cells of the other variety and richer in protoplasm; they are of an irregular oval or triangular shape and possess, as a rule, a single nucleus.

According to Erik Müller and Golgi (93), there exists in the peripheral protoplasm of each parietal cell a system of canals in the form of a network communicating with the lumen of the gland and varying in structure according to the physiologic condition of the cell—wide-meshed in a state of hunger and fine-meshed during

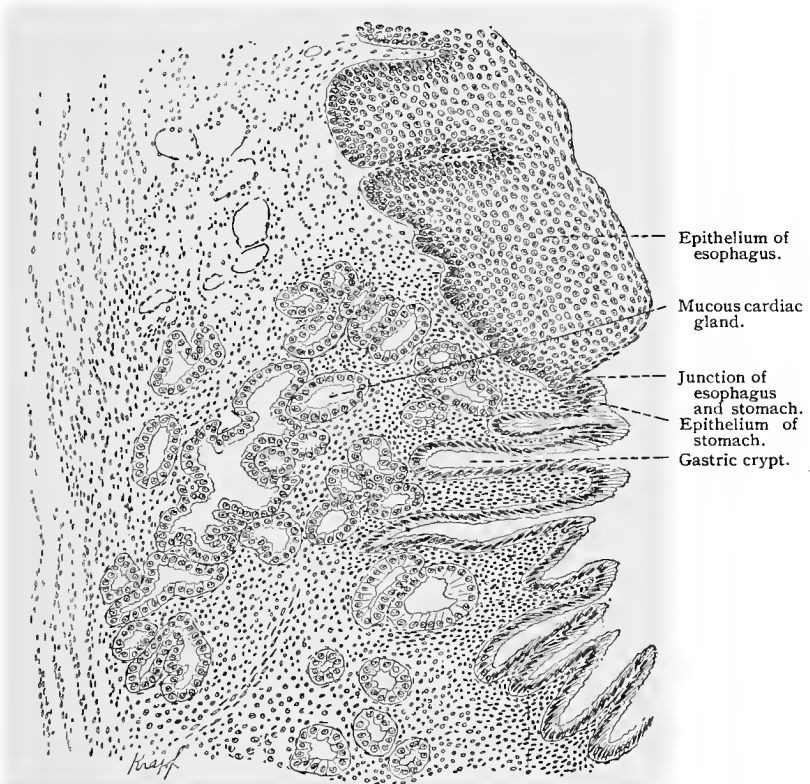


Fig. 201.—From a section through the junction of the human esophagus and cardia ;  
× 50.

digestion. A peripheral zone differing from the rest of the cell-body may occasionally be demonstrated in the parietal cells (mouse) by using the method of von Altmann (*vid.* T. 125).

The second variety of glandular cells is represented by the *central, chief, peptic, or adclomorphous* cells. These are short, irregular, columnar structures whose narrower portions point toward the lumen of the gland. They are situated either directly between the lumen and the basement membrane of the gland, or their

basilar surfaces border on a delomorphous cell. They are found throughout the tubule of the gland and occupy the spaces between the delomorphous cells. Their protoplasm is dark and the nuclei are, as a rule, somewhat smaller than those of the parietal cells. In both varieties of cells mitoses are rarely present in man. In the delomorphous cells pluripolar mitoses are sometimes seen.

At the cardia the stratified squamous epithelium of the esophagus terminates abruptly, the basilar layer of this epithelium being continued as the simple columnar epithelium of the stomach. (Fig. 201.) In that region of the gastric mucous membrane bordering upon the cardia are mucous glands (cardiac mucous glands) similar in appearance to those of the esophagus. The crypts of this region are not supplied with true gastric glands, the latter first making their appearance at some distance from the cardia and increasing in length toward the fundus.

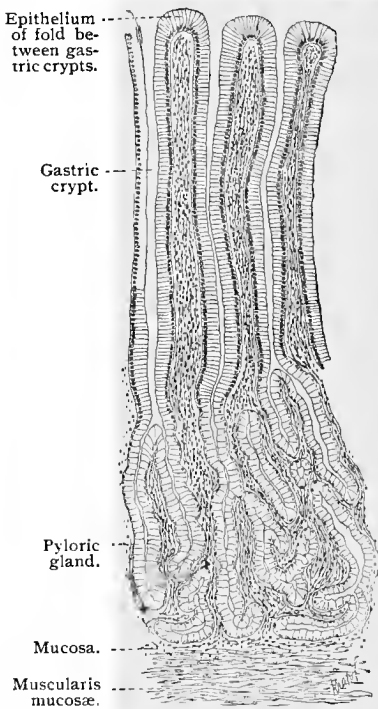


Fig. 202.—From vertical section through human pylorus;  $\times$  about 60. Technic No. 241.

tubules become tortuous and arch over the muscularis mucosæ. The most important feature is that in the great majority of the tubules only a single variety of cell is present in the pyloric gland. (Only here and there are found parietal cells in the pyloric glands of the human stomach.) These cells may be compared with the chief cells of the glands in the fundus. They are columnar, but of much more uniform structure—a condition probably due to the general absence of delomorphous cells. In the immediate vicinity of the gastroduodenal valve the pyloric glands become shorter,

The structure of the pyloric region of the stomach differs in some respects from that of the cardiac end and fundus. There is, however, no sharply defined boundary between fundus and pylorus, but a transitional zone in which changes gradually take place. Toward the pylorus the gastric crypts gradually become deeper and the parietal cells decrease in number. Here also the glands begin to branch. In the pylorus itself the crypts frequently extend half-way through the thickness of the mucous membrane, often even penetrating to the muscularis mucosæ, in which case the corresponding

and other glands, which extend into the submucosa, and which are identical in structure with the glands of Brunner in the duodenum, make their appearance. In this portion of the pylorus are also a few scattered villi, which from their structure may be considered as belonging to the duodenum (*vid.* Fig. 208).

In the normal condition the mucosa of the stomach seldom contains solitary lymph-nodules (lenticular glands) in the fundus region, but frequently in the pyloric region; well-defined lymph-nodules are constantly present in the immediate vicinity of the pylorus.

The muscularis mucosæ is usually composed of three layers, the fibers of the individual layers forming distinct interlacing bundles. Individual muscle-fibers very frequently branch off from the inner layer, assume a vertical position and disappear among the glands. Similar arrangements are also seen in the muscularis mucosæ of the stomach (Fig. 199).

Only the inner and middle layers of the muscular coat of the stomach enter into the formation of the sphincter pylori (Fig. 208). The fibers of the outer layer, however, penetrate through the sphincter pylori and may even be traced into the submucosa. When these alone contract, the muscular bundles of the sphincter act somewhat as pulleys, and a moderate dilatation of the lumen of the pylorus is the result (dilatator pylori, Rüdinger, 97).

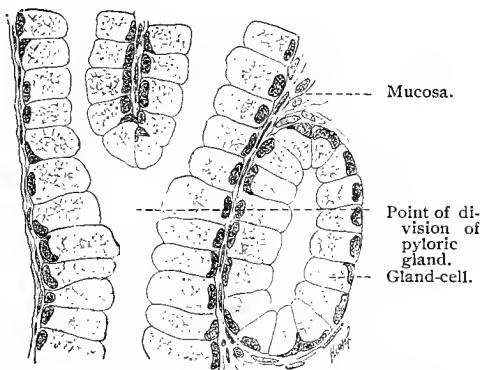


Fig. 203.—From section through human pylorus ;  
× 600. Technic No. 241.

(For further particulars about the stomach, compare Oppel, 96.)

The changes which the epithelium and the secretory cells of the stomach undergo during secretion are of special importance. These relations have been carefully studied in animals by R. Heidenhain (83). As far as our present knowledge goes, it would seem that the same processes also occur in man. In a state of hunger the chief cells of the fundus are large and clear, the parietal cells small; in certain cases the parietal cells abandon their mural position and, like the chief cells, border upon the lumen of the gland. During the first few hours of digestion the chief cells remain large, but become somewhat turbid, while the parietal cells increase in size. In the dog from the sixth to the ninth hour of digestion, the chief cells diminish in size and become cloudy, while the parietal cells remain large and even increase in size. From the fifteenth hour on, the process becomes reversed; the chief cells enlarge and become clear,

and the parietal cells diminish in size. In a condition of hunger the cells of the pylorus are clear, of medium size, and do not begin to enlarge until six hours after feeding. From the fifteenth hour on, the cells become smaller and more turbid, while the nuclei return

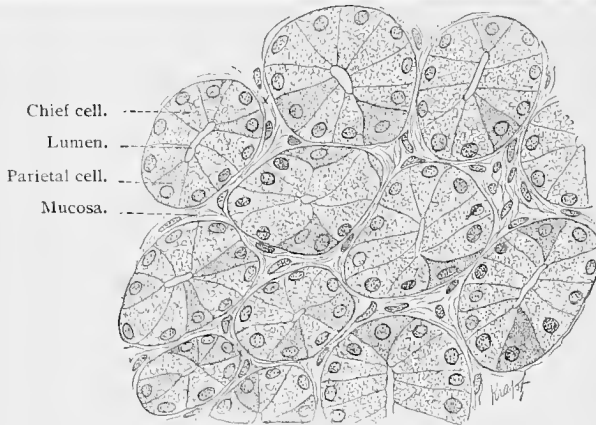


Fig. 204.—Section through fundus of human stomach in a condition of hunger;  $\times 500$ .  
Technic No. 242.

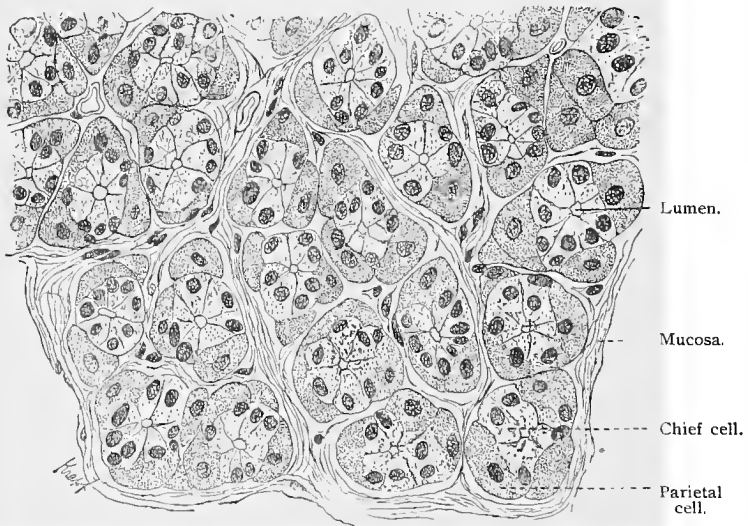


Fig. 205.—Section through fundus of human stomach during digestion;  $\times 500$ .  
Technic No. 242.

to the center of the cells. Since chemic examination has shown that the amount of pepsin found in the gastric mucous membrane increases with the enlargement of the chief and pyloric cells, and decreases with their diminution in size, there can be hardly any

doubt that this ferment is elaborated by these cells. The process consists either in a direct change of the cellular protoplasm into the ferment, or in a preliminary stage before its final transformation into the finished ferment. It is assumed that the parietal cells secrete the acid of the gastric juice, although, in spite of all efforts, it has not yet been definitely proved that these cells possess an acid reaction.

The vascular and lymph-vessels of the stomach, and also its nerve supply, will be considered in a general discussion of these structures pertaining to the entire intestinal canal.

### 3. THE SMALL INTESTINE.

The mucous membrane of the small intestine is characterized by the presence of *villi*. These are more or less elongated elevations of the mucous membrane projecting into the lumen of the intestine. They greatly increase the surface of this portion of the intestine and are actively concerned in the absorption of its contents. The mucous membrane also forms permanent folds in both the duodenum and the remainder of the small intestine, the *valvulae conniventes* (Kerkring). Upon these the villi rest, and, indeed, it is probable that the very existence of the *plicae* is due to the blending of the basilar ends of the villi. The latter are leaf-shaped in the duodenum, columnar in the jejunum, and club-shaped in the ileum.

The epithelium of the intestinal mucous membrane covers the villi in a continuous layer, and penetrates into the mucosa to form the glands. Its structure is essentially the same in all regions of the small intestine, the cells being of the high columnar variety with free surfaces covered by wide, striated cuticular borders. The basilar portions of these cuticular borders are nearly always homogeneous, and upon vertical section give the appearance of a fine line. The cuticular borders of adjacent cells blend with each other, forming a continuous membrane, large areas of which may be detached from the villi (cuticula). The body of the cell consists of a granular, reticular, or striated protoplasm, containing, especially at the beginning of mucous secretion, clear vacuoles of different sizes—mucus. If the cuticular margin be intact, a confluence of the vacuoles may form a large drop of mucus. The nuclei lie usually in the basilar third of the cells, and only where they show mitoses, as for instance in the tubular intestinal glands, do they pass to the free ends of the cells. The basal ends of the epithelial cells in the small intestine are also seen to be pointed, and the probability is that they rest upon the basement membrane. The question has, however, not been fully settled.

The epithelial cells undergo a special metamorphosis, after which, by an increased production of mucus, they change into goblet cells. From recent investigations it would seem that any epithelial cell, whether it be situated upon the upper surface of a

villus or deep down in one of the tubules of the intestinal glands, is capable of transformation into a goblet cell. The number of goblet cells is subject to great variation; they are found singly in small numbers, or are very numerous, according to the stage of digestion and quantity of food in the intestine. The manner in which an ordinary epithelial cell changes into a goblet cell is very easily explained if the mechanical action on the cell caused by an accumulation of secretion be taken into consideration. As the secretion increases in quantity the upper portion of the cell becomes distended,

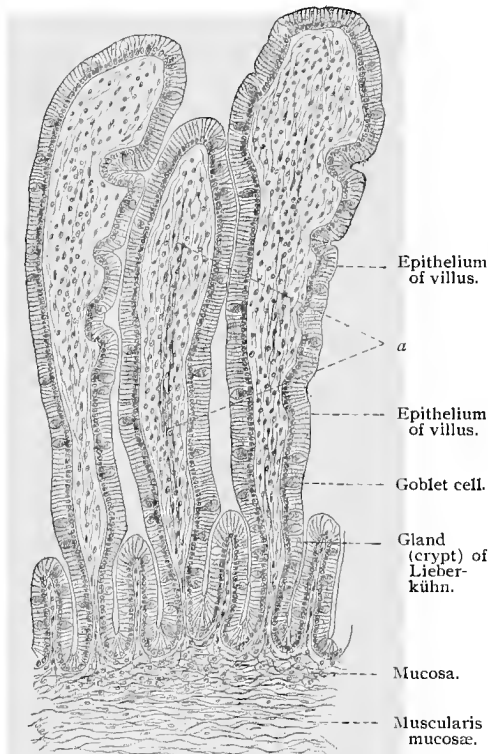


Fig. 206.—Section through mucous membrane of human small intestine;  $\times 88$ . Technic No. 243: At *a* is a collapsed chyle-vessel in the axis of the villus.

and the remains of the protoplasm, together with the nucleus, are pushed toward the narrow base of the cell; the cuticular zone is stretched, bulges into the lumen of the intestine, and is finally perforated, and perhaps even thrown off. In this way the cell loses its mucous secretion, collapses, and then appears as a thin, almost rod-like structure, with a long nucleus. It is the generally accepted theory that such an empty goblet cell may again assume the shape of an ordinary epithelial cell and repeat the process just described.

Leucocytes are sometimes found within the epithelial cells, but more usually between them, and according to Stöhr (84, 89, 94), when seen in these positions, are in the act of migrating

into the lumen of the intestine. That some of these cells actually pass into the lumen is probably true; but as yet no leucocytes have ever been observed in the cuticula itself, and neither is the number of cells found in the lumen of the intestine proportionate to the leucocytes present in the epithelium. Since many are seen in the epithelium undergoing karyokinetic division, it is more probable that a part of them actually wander into the epithelium for the purpose of

division (chemotaxis ?), only to return to the mucosa after the completion of the process (compare p. 54).

Into the spaces between the villi open numerous tubular glands. These are seldom branched, and are known as *Lieberkühn's glands*, or *crypts*. Their length varies from  $320\ \mu$  to  $450\ \mu$ . They are regularly arranged in a continuous row, and often have an ampulla-like widening of their lumina extending almost to the muscularis mucosæ, but never quite reaching it. They are uniformly distributed not only throughout the small intestine, but also throughout the large intestine and rectum. Their cells are somewhat lower than those of the villi, and possess a very narrow cuticular zone. The cells are, however, conical,—a condition probably due to the curvature of the glandular wall,—the base of each cone lying toward the basement membrane, the apex toward the lumen of the gland—a condition opposite to that found in the villi. Numerous goblet cells are also present. They vary only slightly in shape during mucous secretion, and never, as in the villi, assume the form of goblets with distinct pedicles. Mitoses are always seen in the intestinal glands, especially in cells which do not contain mucin. They are readily distinguished, since the nuclei in process of division, as we have seen, lie outside of the row formed by the remaining nuclei. The plane of division in these cells lies

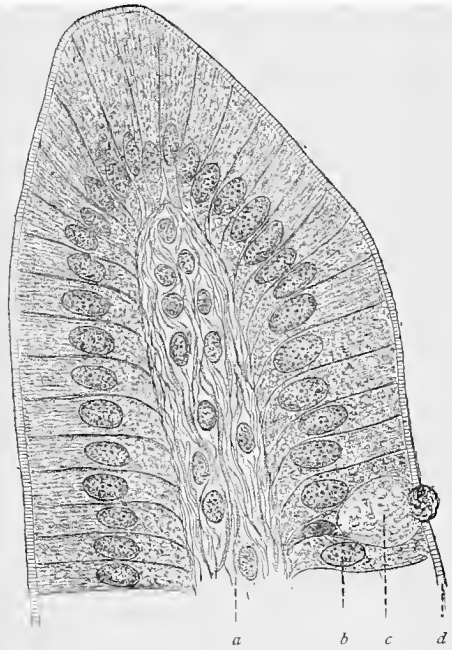


Fig. 207.—Longitudinal section through summit of villus from human small intestine;  $\times 900$  (Flemming's solution): At *a* is the tissue of the villus axis; *b*, epithelial cells; *c*, goblet cell; *d*, cuticular zone.

horizontal to the long axis of the gland, so that an increase in the number of cells results in an increase in the area of the glandular walls. Mitoses are very rarely observed in the epithelium covering the villi. If, therefore, any cells be destroyed on the surface of the villi, it must be assumed that the loss is replaced by new elements pushed up from the glands below (Bizzozero, 89, 92, I).

The entire duodenum, as well as that part of the pylorus in the immediate vicinity of the pyloric valve, is characterized by the presence of glands of a second type. In the duodenum these are

seen intermingled with the glands of Lieberkühn, and in the pylorus with the pyloric glands. These glands, *Brunner's glands*, have a diameter of from 0.5 to 1 mm., and are compound, branched tubular glands, with tubules provided with alveoli, especially along their lower portions. The bodies of the glands are situated principally in the submucosa, although a part may be in the mucosa. In the stomach they open into the gastric crypts, in the intestine either independently between the villi, or into the glands of Lieberkühn. Here the glandular cells are in general similar to those of the pyloric glands, although, as a rule, somewhat smaller than the latter. Just as the duodenal glands extend into the stomach, so also the pyloric glands of the latter are found in the upper portion of the duodenum. Besides short villi, there are also present in the duodenum depressions of the mucous membrane analogous to the gastric crypts. The glands of Lieberkühn begin at a certain distance from the pylorus; at first they are short, and do not attain their customary length until a point is reached at which the gastric glands extending into the duodenum finally disappear (*vid.* Fig. 208). It is therefore obvious that a transition zone exists between pylorus and duodenum, and that a distinct boundary line can not be drawn between the two, at least so far as the mucous membrane is concerned. The duodenal glands, as their name would indicate, are present only in the duodenum. Between the jejunum and ileum there is no distinct boundary, not even when microscopically examined. The differences are mostly of a quantitative nature; in the jejunum the valvulæ conniventes are more numerous than in the ileum, and the villi more slender and closer together. The glands of Lieberkühn also appear to be more numerous in the jejunum.

The mucosa of the small intestine consists of reticular adenoid tissue containing lymph-cells. It supports the glands and extends into the villi whose axes it forms. The mucosa is separated from the glands, from the epithelium of the villi, as well as from that of the remaining surface of the intestine by a peculiar *basement membrane*. The latter somewhat complicates a proper histologic analysis, and as a consequence opinions regarding its structure and significance vary considerably. By some it has been described as a homogeneous, hyaline, and exceedingly fine membrane containing nuclei, by others as a lamella consisting entirely of endothelial cells. At all events, there are certainly nuclei in the basement membrane. Beneath the basement membrane is a marginal layer of a more fibrillar character. This is closely associated with the mucosa, and may be regarded as a differentiation of the latter. Toward the muscularis mucosæ the mucosa is terminated by a reticulated elastic membrane (F. P. Mall, in the dog), containing openings for the entrance of vessels, nerves, and muscle-fibers.

The *muscularis mucosæ* consists of two layers of unstripped muscular fibers arranged in a manner similar to that in the external muscular tunic—*i. e.*, having an inner circular and an outer longi-

tudinal layer. The fibers are frequently gathered into bundles, which appear to be separated from each other by connective tissue. From both layers, but more especially from the inner, muscle-fibers are given off at right angles, which enter the tunica propria and pass between the glands of Lieberkühn, and even into the villi. In the latter these muscle-fibers are arranged in bundles, and lie

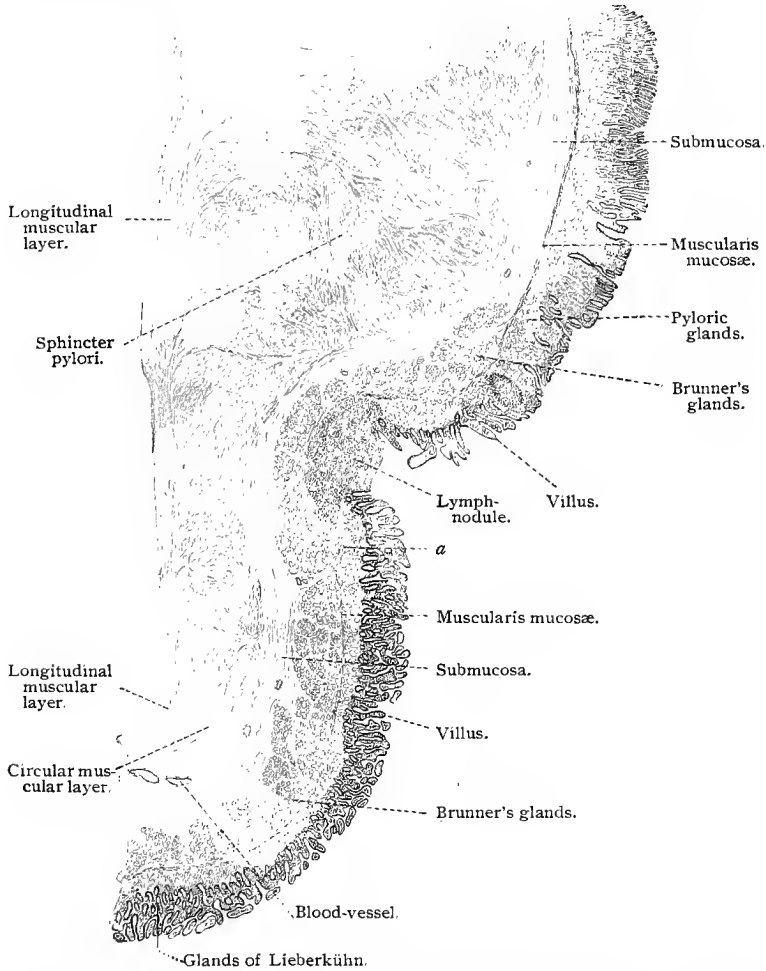


Fig. 208.—Section through the junction of the human pylorus and duodenum;  $\times$  about 15 : At *a* the pyloric glands extend into the duodenum.

near their axes around the lacteal vessels. The contraction of these fibers causes a contraction of the entire villus.

Lymph-nodules are distributed throughout the mucosa of the small intestine, occurring either singly, as solitary follicles, or aggregated, as Peyer's patches. At the points where they occur,

the villi are absent and a lateral displacement of the glands of Lieberkühn is observed. The lymph-nodule is usually pyriform in shape. The thinner portion protrudes somewhat in the direction of the lumen of the intestine, while the thicker portion extends outward to the muscularis mucosæ, the latter being frequently indented or even perforated if the lymph-nodules be markedly developed. Their structure is similar to that of the lymph-follicles (see under these), and consists of reticular adenoid tissue, supporting lymph-cells. It should be remembered that every nodule may possess a germ center. Peyer's patches are collections of these lymph-follicles. The surface of the nodule presenting toward the lumen of the intestine is covered with a continuous layer of intestinal epithelium. In man the summit of that portion of the

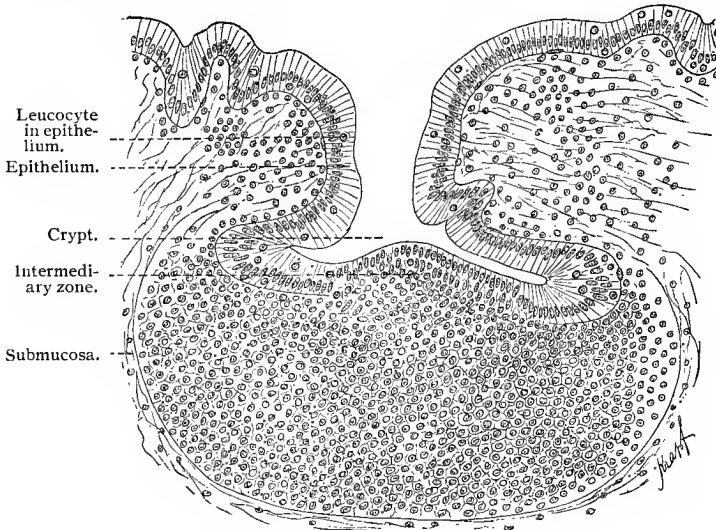


Fig. 209.—Section of solitary lymph-nodule from vermiform appendix of guinea-pig, showing crypt;  $\times$  about 400 (Flemming's fluid).

nodule projecting into the lumen of the intestine presents but a slight depression of the intestinal epithelium, while in some animals (guinea-pigs), and especially in the nodules composing Peyer's patches, there is a deeper depression, even leading to the formation of a so-called "crypt" or "lacuna" (*vid.* Fig. 209). At the summit, the intestinal epithelium where it comes in contact with the lymph-nodule, is peculiarly altered. In most cases there is an absence of a basement membrane, the epithelium resting directly upon the lymphoid tissue. No clearly defined boundary between the two is distinguishable (intermediate zone of v. Davidoff); they are therefore in the closest relationship to each other. The basal surfaces of the epithelial cells are fibrillar, the fibrils seeming to penetrate into the adenoid reticulum of the follicles.

#### 4. THE LARGE INTESTINE, RECTUM, AND ANUS.

The small intestine ends at the ileocecal valve. At some distance from the margin of the valve the villi of the ileum become broad and low. In the immediate vicinity of the valve their basilar portions become confluent, forming a honeycomb structure which supports a few villi. At the base of the honeycomb open the glands of Lieberkühn. On the cecal side of the valve the villi become fewer in number and finally disappear, while the folds which give the honeycomb appearance persist for a considerable distance. In

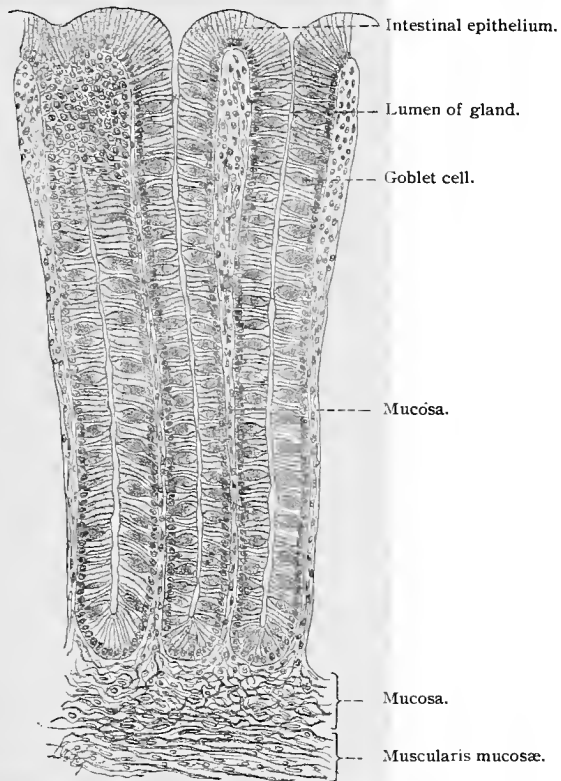


Fig. 210.—From colon of man, showing glands of Lieberkühn;  $\times 200$ .

the adult cecum the villi are absent. The mucosa and glands present a structure similar to that of the remainder of the large intestine. In the mucosa of the vermiform appendix is found a relatively large number of solitary lymph-follicles, occasionally forming a continuous layer. The marked development of the lymph-follicles encroaches upon the glands of Lieberkühn, so that many are obliterated; they are penetrated by the adenoid tissue, the epithelial cells of the glands mingling with the lymph-cells. What finally

becomes of the secretory cells has not been definitely ascertained (Rüdinger, 91).

In the colon the villi are wanting, while the glands of the mucosa are densely placed and distributed with regularity.

The glands of Lieberkühn in the colon are somewhat longer, and as a rule contain many more goblet cells than those in the small intestine. Only the neck and fundus of the glands show cells devoid of mucus. Transitional stages between the latter and the goblet cells have been observed in man (Schaffer, 91). Solitary lymph-follicles are found throughout the colon. They are situated in the mucosa, only the larger ones extending into the submucosa. The glands of Lieberkühn are displaced in the regions of the lymph-follicles.

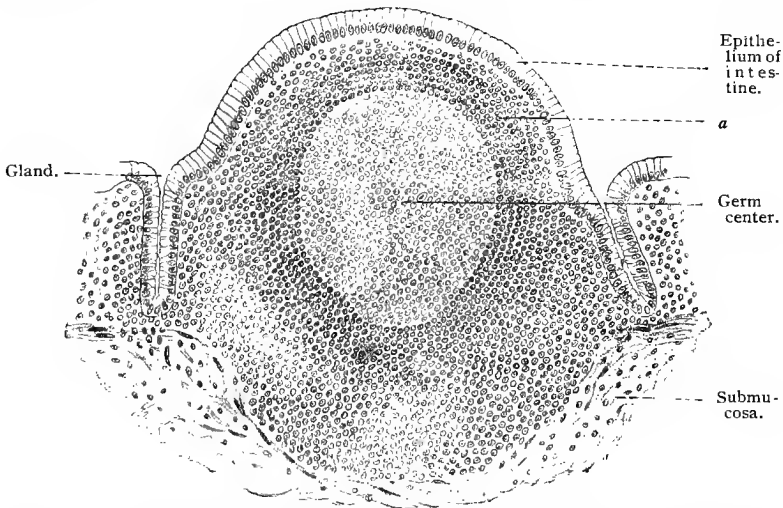


Fig. 211.—A solitary lymph-follicle from the human colon: At *a* is seen a pronounced concentric arrangement of the lymph-cells.

The *tæniæ* and *plicæ semilunares* cease at the sigmoid flexure, and are replaced in the rectum by the *plicæ transversales recti*. Permanent longitudinal folds, the so-called *columnæ rectales Morgagni*, are present only in the lower portion of the rectum. Here the intestinal glands are longest but disappear simultaneously with the rectal columns. At the anus the mucous membrane of the rectum forms a narrow ring devoid of glands, covered by stratified pavement epithelium, and terminating in the skin in an irregular line. The transition from the mucous membrane to the skin is gradual, yet reminding one of the appearance presented at the junction of the esophagus with the cardiac end of the stomach.

External to the anus, and at a distance of about one centimeter from it, are numerous highly developed sweat-glands, the *circum-anal glands*, which are almost as large as the axillary glands.

### 5. BLOOD, LYMPH, AND NERVE SUPPLY OF THE INTESTINE.

In general, the following holds true with regard to the blood-vessels of the intestinal tract (further details will be discussed in dealing with the vessels of the various regions of the intestine): The arteries enter along the line of the mesenteric attachment and penetrate the longitudinal muscular layer. Between the two muscular layers branches are given off which form an intermuscular plexus, from which, in turn, smaller branches pass out to supply the muscles themselves. The arterial trunks penetrate the circular muscular layer and form an extensive network of larger vessels in the deeper layer of the submucosa. This is known as *Heller's plexus* (F. P. Mall). From this, radiating branches are

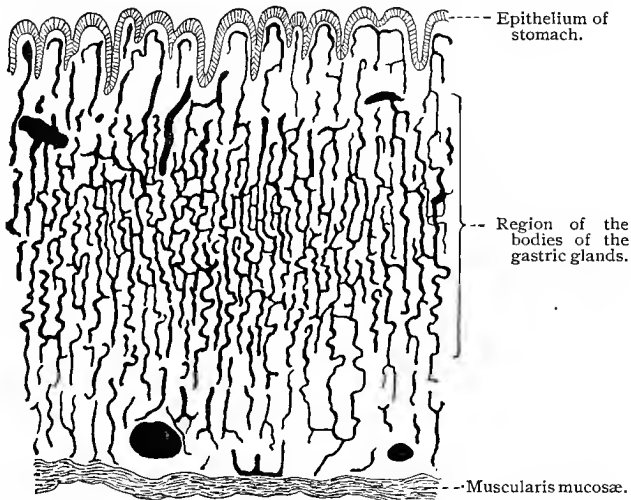


Fig. 212.—Section through fundus of cat's stomach. The blood-vessels are injected;  $\times 60$ .

given off which supply the muscularis mucosæ, forming under the latter a close network of finer vessels. This plexus, together with that of Heller, gives rise to vessels which penetrate the muscularis mucosæ and break up into capillaries in the mucous membrane. The veins of the mucous membrane form beneath the muscularis mucosæ a plexus with small meshes, giving off many radiating branches; these in turn unite to form an extensive network of coarser vessels. Veins extend from the latter and unite to form larger trunks, which then lie side by side with the arteries. According to Mall, delicate *retia mirabilia* occur here and there in the venous network in the submucosa of the intestine of the dog.

In the esophagus the arteries end in a capillary network situated

in the mucosa and extending into the connective-tissue papillæ of the mucosa.

The vessels of the stomach are arranged in plexuses in the muscular coat, submucosa, and beneath the muscularis mucosæ, as previously described. From the plexus beneath the muscularis mucosæ, small branches are given off which pass through this layer and in the mucosa form a capillary network, consisting of relatively small capillaries, which surround the gastric glands, this plexus being particularly well developed in the region around the body and neck of the glands, where the parietal cells are most numerous. The capillaries of this network are continuous with capillaries of a much larger size, forming a network surrounding the gastric crypts and situated immediately under the epithelium lining the mucosa of the stomach. The blood is collected from this capillary plexus by small veins which pass nearly perpendicularly through the mucosa, forming a plexus above the muscularis mucosæ, from which small veins pass through the muscularis mucosæ to the venous plexus in the submucosa.

The blood-vessels of the mucosa of the small intestine may be divided into (1) the arteries of the villi and (2) the arteries of the intestinal glands. The former arise principally from the deep arterial network in the submucosa, then penetrate the muscularis mucosæ and give off branches at acute angles which continue without further branching into the summits of the villi. Within the villi themselves the arteries lie in the axes. The broader villi may contain two arteries. The circular muscle-fibers of the arteries gradually disappear inside of the villi (dog), and at the summit of the latter the vessels break up into a large number of capillaries. These form a dense network extending beneath the basement membrane and into its marginal layer. These networks give rise to venous capillaries which unite to form small vessels and finally end in two or more larger veins inside of the villi. These latter are connected with the venous network in the mucosa.

The glandular arteries, derived principally from the superficial network of the submucosa, also pass through the muscularis mucosæ and break up internally into capillary nets which encircle the intestinal glands; these give rise to small veins which empty into the venous plexus of the mucosa. The veins of the plexus in the mucosa unite to form larger branches, which connect with the plexus in the submucosa (compare Fig. 213). In the dog these trunks inside of the muscularis mucosæ are encircled by bundles of muscle-fibers (sphincters, F. P. Mall). The capillaries of the solitary lymph-nodules do not always penetrate into the centers of the latter, but often leave a central nonvascular area.

The blood-vessels of the mucosa of the large intestine are, in their distribution, similar to the glandular vessels of the small intestine and stomach.

The lymph-vessels begin in the mucosa near the epithelium, pass

down between the glands, and are arranged in the form of a network just above the muscularis mucosæ, but with coarser meshes than that formed by the blood-vessels. Here the valves begin to make their appearance. The lymph-vessels pass through the muscularis mucosæ and in the outer portion of the submucosa form a plexus with open meshes, from which are derived the efferent vessels which penetrate the muscular coat and thus gain access to the mesentery. In their course through the muscular coat they communicate with the branches of a plexus of lymph-vessels situated between the two muscular layers, and also with lymph-vessels found in the serous coat.

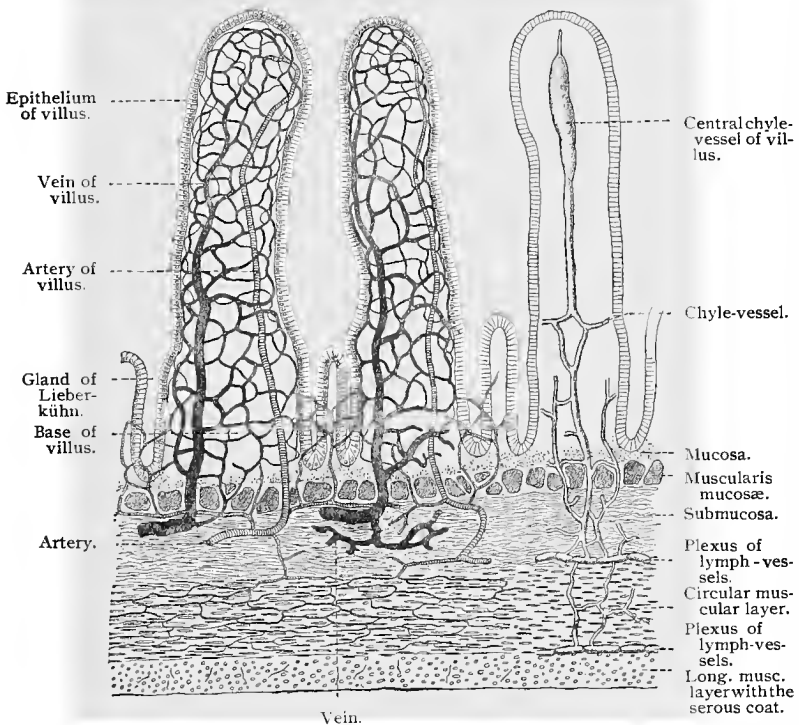


Fig. 213.—Schematic transverse section of the human small intestine (after F. P. Mall).

The lymphatics of the small intestine begin in the axes of the villi. When filled, these lymph-vessels are conspicuous, irregularly cylindrical capillary tubules, lined by endothelial cells, and known as the *axial canals*, the *chyle-vessels*, or the *lacteals* of the villi. They are hardly discernible when collapsed. If the villus be broad, it may contain two chyle-vessels, which then join at the apex of the villus, and may also be connected with each other by a few anastomoses. At the base of the villus the chyle-vessel enters a lymphatic capillary network, the structure of which is due to the confluence

of similar canals. Numerous lymph-vessels from this network penetrate the mucous membrane in a vertical direction, uniting at the bases of the intestinal glands to form a second plexus—subglandular plexus of the mucosa. A few of the lymph-vessels penetrating the mucous membrane directly perforate the muscularis mucosæ to join the lymphatic network of the submucosa. The subglandular plexus also communicates with the submucous lymphatic plexus by means of small radiating branches (*vid.* Fig. 213). The solitary lymph-nodules themselves contain no lymphatic vessels, but are encircled at their periphery by a network of lymph capillaries. The same is true of the nodules in Peyer's patches. It is an interesting fact that in the rabbit lymph-sinuses exist around Peyer's patches, giving to the latter a still greater similarity to the nodules of lymph-glands. The solitary nodules of the same

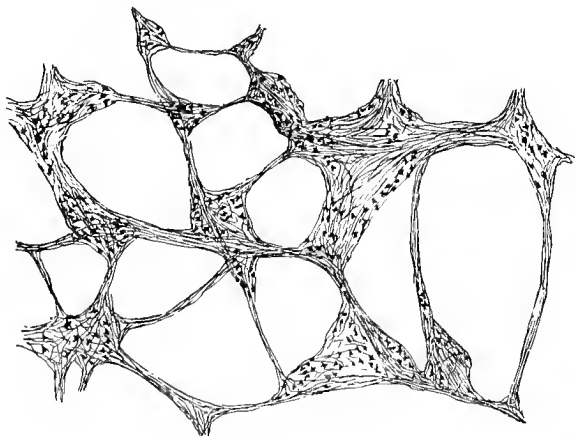


Fig. 214.—A portion of the plexus of Auerbach from stomach of cat, stained with methylene-blue (*intra vitam*), as seen under low magnification.

animal are not surrounded by the sinuses just mentioned (Stöhr, 94).

The structures of the alimentary canal receive their innervation mainly from sympathetic neurones, the cell-bodies of which are grouped to form small ganglia, located at the nodal points of two plexuses, one of which is situated between the two layers of the muscular coat, the other in the submucosa. These two plexuses are found in the entire digestive tract, although not equally well developed in its different regions. The outer plexus, the more prominent of the two, situated between the two layers of the muscular coat, is known as the *plexus myentericus*, or the *plexus of Auerbach*. It consists of innumerable small sympathetic ganglia, united by small bundles of nonmedullated fibers, containing here and there a much smaller number of medullated nerve-fibers. The cell-bodies of the sympathetic neurones of this plexus are grouped to form the

sympathetic ganglia. The dendrites, the number of which varies for the different cells, divide and redivide in the ganglia, some extending into the nerve bundles uniting the ganglia. The neuraxes of the sympathetic neurones of the ganglia form nonmedullated nerve-fibers, which leave the ganglia by one of the several roots possessed by each ganglion, and, after repeated division and forming intricate plexuses in the circular and longitudinal layers of the muscular coat, terminate on the involuntary muscle-cells of these layers.

The plexus in the submucosa, known as the *plexus of Meissner*, is similarly constructed, although it contains fewer and much smaller ganglia and the meshes of the plexus are much finer. It communicates by numerous anastomoses with the plexus of Auerbach. The neuraxes of the sympathetic neurones of this plexus have not been traced, with any degree of certainty, to their terminations. Numerous nonmedullated nerves enter the muscularis mucosæ and, according to Berkley (93, I), form in the dog terminal bulbs and nodules which perhaps represent the endings of motor (sympathetic) nerves in this layer. Nerve-fibers have also been traced into the mucosa, and in the vicinity of the glands and in the villi are found numerous exceedingly fine nerve-fibers which interlace, but in the greater portion of the intestinal tract the endings of these fibers have not been fully worked out. That they end on the gland-cells seems very probable from observations made by Kytmanow (96), who was

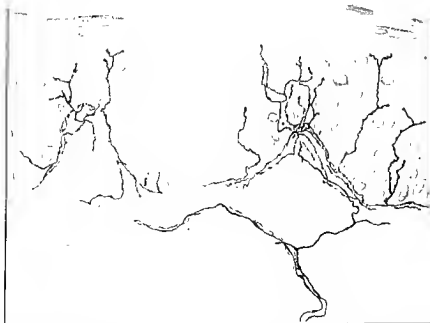

Fig. 215.—From thin section of esophagus of cat, showing the epithelium and a portion of the mucosa and the terminal nerve-fibrils in the epithelium (from preparation of Dr. DeWitt).

able, by means of the methylene-blue method, to stain plexuses of fine nerve-fibrils surrounding the gastric glands of the cat, some of these fibrils being traced through the basement membrane of the glands and to and between the gland-cells, where they terminated in clusters of small nodules on both the chief and parietal cells. The plexus of Meissner is not so well developed in the esophagus as in the remaining portions of the digestive tract.

That the cell-bodies of many of the sympathetic neurones of Auerbach's and Meissner's plexuses are capable of being stimulated by cerebrospinal nerves seems certain from observations made by Dogiel (95), who has shown that many small medullated nerve-fibers which enter the digestive tract through the mesentery (small and large intestines) terminate after repeated division in terminal end-baskets which surround the cell-bodies of many of the sympathetic neurones of these plexuses. Similar nerve-fibers ending in

baskets have also been observed in the ganglia of the plexuses of the stomach and esophagus. Large medullated nerve-fibers, the dendrites of sensory neurones, have also been traced to the alimentary canal. In the esophagus these pass to the mucosa, where, after repeated division, they lose their medullary sheaths, the non-medullated terminal branches forming a subepithelial plexus from which terminal, varicose branches, further dividing, enter the stratified epithelium and may be traced to near the surface of the epithelium.

Large medullated nerve-fibers may be traced through the ganglia of Auerbach's and Meissner's plexuses in the stomach and intestinal canal and through the nerve bundles uniting these ganglia (Dogiel, 99), but the termination of these fibers has not been determined.

## 6. THE SECRETION OF THE INTESTINE AND THE ABSORPTION OF FAT.

The cells of Brunner's glands are similar in many respects to those of the pyloric glands. During digestion they show analogous changes—*i. e.*, the secretory cells are large and clear during a state of hunger, and become smaller and opaque during the process of secretion. Another and still greater similarity between Brunner's glands and the pyloric glands is established by the fact that the cells of the former, especially during hunger, have been shown to be rich in pepsin. It is well known that the goblet cells of the intestinal glands are very numerous during starvation, and that they nearly disappear after continued functional activity; furthermore, they entirely disappear in certain portions of the rabbit's intestine after pilocarpin-poisoning. It would therefore appear that the principal physiologic function of the glands of Lieberkühn is to secrete mucus, although the possibility of the production of another secretion, especially in the small intestine, must not be excluded (compare R. Heidenhain, 83).

Until recently it was believed that the fat contained in the food was emulsified in the intestine, and furthermore that the bile acted upon the cuticular margins of the epithelial cells in the villi in such a manner that an assimilation of the emulsified fat by the cells of the villi (not by the goblet cells) was made possible. It has been repeatedly observed that the epithelial cells contained fat granules during absorption. Hence a mechanism was sought for which would account for an assimilation of globules of emulsified fat on the part of the cells. It seemed most probable that protoplasmic threads (pseudopodia) were thrown out from each cell through its cuticular zone, which, after taking up the fat, withdrew with it again into the cell. But when it was shown that, after feeding with fatty acids or soaps, globules of fat still appeared in the epithelial cells as before, and that the chyle also contained fat, the hypothesis was

suggested that the fat is split up by the pancreatic juice into glycerin and fatty acids, and that the fatty acids are then dissolved by the bile and the alkalies of the intestinal juice, only again to combine with the glycerin to form fat within the epithelial cells. It remains for the histologist to ascertain the exact mechanism in the cell which changes the fatty acids into fat. Altmann (94) claims that certain granules of the cells (elementary organisms) offer a solution to this problem. The manner in which the fat globules gain access to the central vessels of the villi is a question which has not as yet been settled.

#### D. THE LIVER.

In the adult the liver is a lobular, tubular gland with anastomosing tubules. When viewed with the unaided eye or under low magnification the liver is seen to be composed of a large number

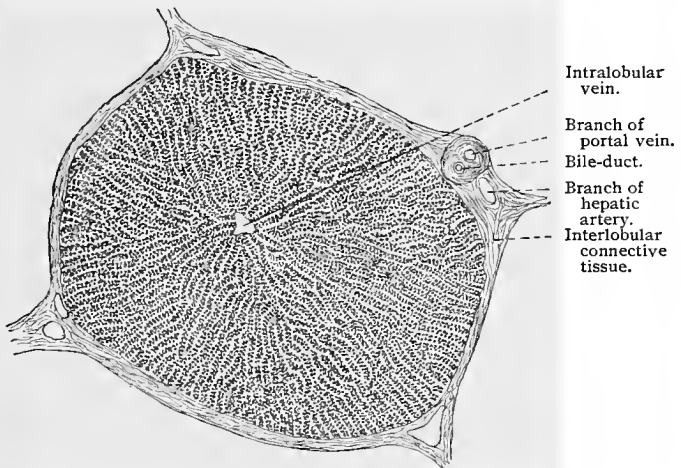


Fig. 216.—Section through liver of pig, showing chains of liver-cells;  $\times 70$ .

of nearly spheric divisions of equal size; this is particularly noticeable in some animals, especially in the pig. These divisions are the *liver lobules* and have a diameter of from 0.7 to 2.2 mm. They are separated from each other by a varying amount of interlobular connective tissue, which is a continuation of the *capsule of Glisson*, a fibro-elastic layer surrounding the entire liver and covered for the greater portion by a layer of mesothelium. In the interlobular septa are found the larger blood-vessels, bile passages, nerves and lymph-vessels. On examining a thick section of the liver with a low power, a radiate structure of the lobule is noticeable, and an open space is seen in its center, which according to the direction of the section, is either completely surrounded by liver tissue or connected with the periphery of the lobule by a canal. This open

space represents the *central* or *intra-lobular vein* of the lobule which belongs to the system of the inferior vena cava. From the center of the lobule toward its periphery extend numerous radiating strands of cells, which branch freely and anastomose with each other, and are known as the *trabeculae*, or *cords of hepatic cells*. Between the latter are small, clear spaces occupied partly by blood capillaries and partly by the intra-lobular connective tissue. The above description is in some respects not a true statement of the appearance presented by the human liver, as in the latter one or more lobules may blend with each other, thus rendering the individual lobules less distinct.

The *hepatic cords* consist of rows of hepatic cells. The cells

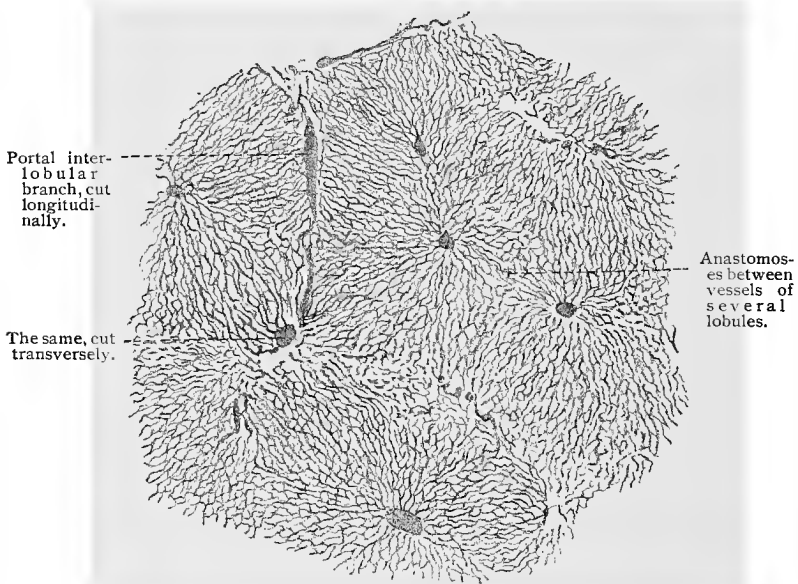


Fig. 217.—Section through injected liver of rabbit. The boundaries of the lobules are indistinct;  $\times$  about 35.

are usually polyhedral in form, with surfaces so approximated that a cylindric capillary space, known as the *bile capillary* remains between them. The angles of the cells also show grooves which join those of the neighboring cells to form canals in which lie the blood capillaries. A closer examination of the hepatic cells reveals the fact that they possess no distinct membrane, and, in a resting state, usually contain a single nucleus, although some possess two. It is an interesting fact that nearly all the hepatic cells of some animals—as, for instance, the rabbit—contain two nuclei. The cell-bodies of the hepatic cells, which average from  $18\ \mu$  to  $26\ \mu$  in diameter, show a differentiation into protoplasm and paraplastm. This is especially manifest in a state of hunger. In this condition

it is seen that the network of protoplasm around the nucleus is unusually dense, and becomes looser in arrangement as it extends toward the periphery of the cell-body. The paraplasm is slightly granular, and contains glycogen and bile drops during the functional activity of the cell (secretion vacuoles). The vacuoles in the paraplasm play an important part in the secretion of the cell, and are

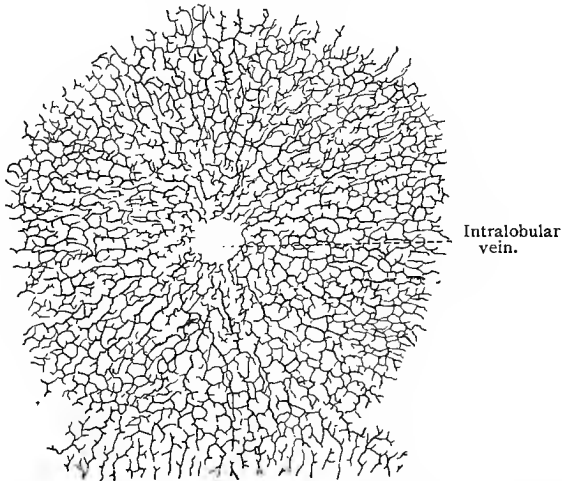


Fig. 218.—Human bile capillaries. The capillaries of one lobule are seen to anastomose with those of the adjoining lobule (below, in the figure);  $\times 110$  (chrome-silver method).




Fig. 219.—Human bile capillaries as seen in section;  $\times 480$  (chrome-silver method).

due to the confluence of minute drops of bile into a large globule. As soon as the vacuole has attained a certain size it tends to empty its contents into the bile capillary through a small tubule connecting the vacuole with the bile capillary (Kupffer, 73, 89).

The *bile capillaries* are, as we have remarked, nothing but tubular, capillary spaces between the hepatic cells, with no distinct indi-

vidual walls. They may be compared to the lumen of a tubular gland, although in the human liver their walls consist of only two rows of hepatic cells. In the lower vertebrates the walls of the bile capillaries appear in transverse section to consist of several cells (in the frog generally three, in the viper as many as five). The bile capillaries naturally follow the course of the hepatic cords—*i. e.*, in man extending radially. They form networks, the meshes of which correspond to the size of the hepatic cells. At the periphery of the lobule the hepatic cells pass directly over into the epithelial cells of the smaller interlobular bile-ducts. The epithelium of the latter is of the cubical variety, its cells being considerably smaller than the hepatic cells. At the point where the hepatic cells become continuous with the walls of the smaller passages we find a few cells of gradually decreasing size which represent a transition stage from the cells of the bile capil-

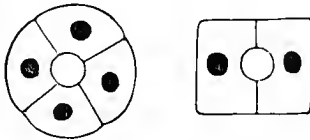


Fig. 220.—Schematic diagram of hepatic cord in transverse section. At the left the bile capillary is formed by four cells, at the right by two; the latter type occurs in the human adult.

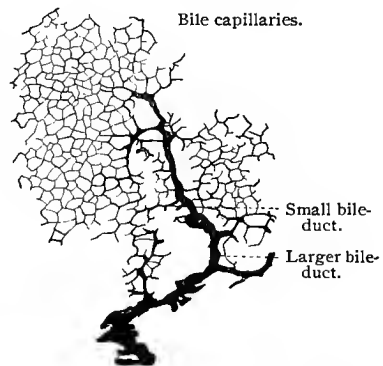


Fig. 221.—From the human liver, showing the beginning of the bile-ducts;  $\times 90$  (chrome-silver).

laries (hepatic cells) to those of the interlobular bile passages.

The vascular system of the liver is peculiar in that, besides the usual arterial and venous vessels common to all organs, there is found another large afferent vein—the *portal vein*. It arises from a confluence of the superior and inferior mesenteric, the splenic, coronary veins from the stomach, and cystic veins. It divides into two branches, the right supplying the right lobe of the liver, the left the remaining lobes. These branches again divide into numerous smaller branches, the smallest of which finally reach the individual lobules. While still within the interlobular tissue, the branches of the portal vein receive the venous blood from the hepatic arterial system. These smaller divisions constitute the internal radicals of the portal vein, since they are within the liver itself. Along its whole course through the interlobular connective tissue the portal vein and its branches are accompanied by divisions of the hepatic artery and bile passages. In a transverse section of the liver the arrangement of these structures in the interlobular tissue is such that the cross-sections of the vessels

belonging to the hepatic vein are seen to be at some distance from the closely approximated branches of the portal vein and bile passages. Branches of the portal vein encircle the liver lobules at different points, and while they remain within the interlobular connective tissue, are known as *interlobular veins*. From these, small offshoots are given off to the lobules which, on entering, divide into capillaries and form a closely reticulated network between the hepatic cords. The meshes of this network are about as large as an hepatic cell, each cell coming in repeated contact with the blood capillaries. All of these capillaries pass toward the central or intralobular vein of the lobule, which during its efferent passage through the lobule continues to receive capillaries from the portal

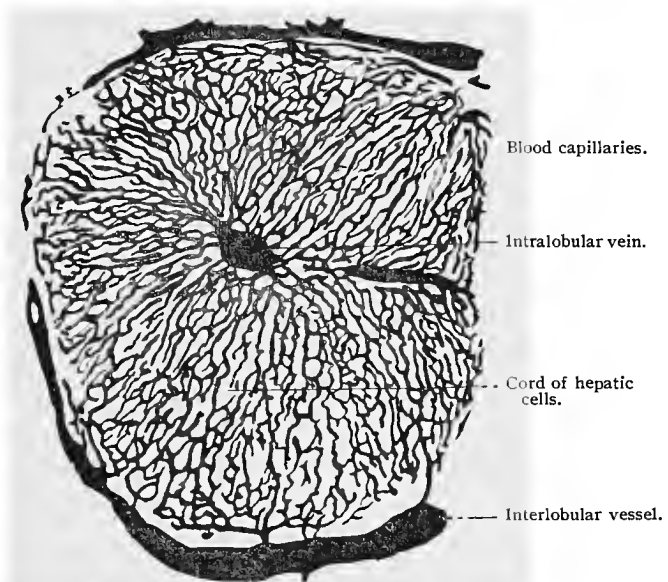


Fig. 222.—Injected blood-vessels in liver lobule of rabbit;  $\times 100$ .

system. The intralobular veins unite to form the sublobular veins, situated in the interlobular connective tissue, and these unite to form the larger hepatic veins which empty into the inferior vena cava. The relations of the various blood-vessels within the lobule are in themselves somewhat difficult of comprehension, but the whole becomes still more complicated when the reciprocal relations of the vessels and bile capillaries are taken into consideration. In order to understand the structure of the liver lobule, with its hepatic cords, vessels, and bile capillaries, the following points should be borne in mind: The course of the bile capillaries is along the surfaces, and that of the blood-vessels along the angles of the hepatic cells; every cell comes in contact with a bile capillary and a blood

capillary. The latter, however, do not come in contact with the former, but in man are separated by at least half the breadth of a hepatic cell. In animals in which the bile capillaries are bounded by more than two cells, the blood-vessels extend along the outer sides of the hepatic cells; here the bile and blood capillaries are separated from each other by the breadth of a whole cell.

The connective tissue within the hepatic lobules presents points of interest which, however, are not demonstrable in organs treated by ordinary methods. But when the liver tissue is treated by a certain special method (*vid.* T. 258), an astounding number of fibers are seen extending in regular arrangement from the periphery toward the central vein. These fibers are extremely delicate, of nearly equal size, and intermingle in such a manner as to form an enveloping network about the blood capillaries (Gitterfasern; Kupffer;

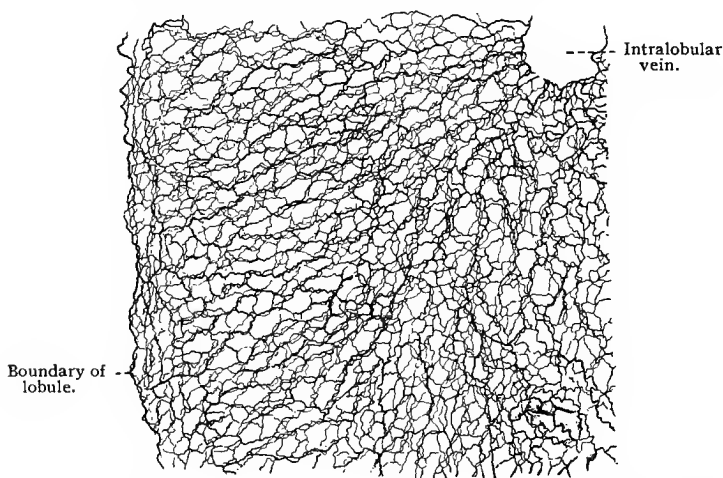


Fig. 223.—Reticulum (Gitterfasern) of dog's liver;  $\times 120$  (gold-chlorid method).

Oppel, 91; *vid.* Fig. 223). A few coarser fibers (radiate fibers, Kupffer, 73) seem to enter in a less degree into the formation of the sheath around the blood capillaries; they also extend from the periphery toward the center of the lobule and form a coarse reticulum, the meshes of which are drawn out radially. The radiate fibers are less prominent in man, but are numerous and well developed in animals (rat, dog). With what exuberance the intralobular connective tissue may develop, is seen in the accompanying sketch of a sturgeon's liver, which is taken from one of Kupffer's preparations.

Certain peculiar cells—the so-called *stellate cells* of Kupffer (76)—occur exclusively in the lobule, and are seen only after a special method of treatment. They are uniformly distributed, of different shapes, elongated, and end in two or three pointed projec-

tions. They are smaller than the hepatic cells, and contain one or two nuclei.

In a recent communication Kupffer (99) states that the stellate cells belong to the endothelium of the intralobular capillaries of the portal vein. In such cells blood-corpuscles and fragments of such were often found. The endothelium of these capillaries possesses, therefore, a phagocytic function, taking up particles of foreign matter, blood-corpuscles, etc.

The efferent ducts of the liver, the *bile-ducts*, are lined by columnar epithelium, varying in height in direct proportion to the caliber of the passage. The smallest ducts possess a low, the medium sized a cubical, and the larger a columnar epithelium. The smaller bile-ducts have no clearly defined external walls other than the *membrana propria*; the larger ones, on the other hand, possess a

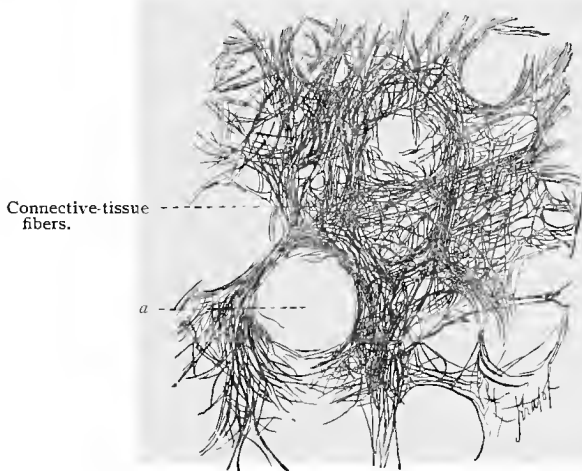


Fig. 224.—Connective tissue from liver of sturgeon. At *a* is an open space from which the hepatic cells were mechanically removed during treatment.

connective-tissue sheath which may even present two layers in the larger passages. Unstriped muscular fibers occur in the large ducts, but do not form a continuous layer until the gall-bladder is reached, where two layers are found. The epithelium of the gall-bladder is of the columnar variety, with nuclei in the lower thirds of the cells; a cuticular zone is either absent or very poorly developed. The mucous membrane of the gall-bladder is raised into folds having a peculiar reticular arrangement. The gall-bladder contains a few mucous glands; these are, however, more numerous in the hepatic, cystic, and common bile-ducts.

Besides the network of *lymph-vessels* accompanying the portal vein and hepatic artery, there are also lymphatic networks about the branches of the hepatic vein (v. Wittich). The lymph-vessels penetrate the liver lobules and pass between the hepatic cells

and the blood capillaries to form perivascular capillary lymph-spaces.

Berkley (94) has described several divisions of the intrinsic nerves of the liver, all connected and morphologically alike. These nerves are no doubt the neuraxes of sympathetic neurones, the cell-bodies of which are located in ganglia outside of this organ. No medullated fibers were found by him, although it seems probable that the nerve-fibrils terminating between the cells of the bile-ducts (see below) are terminal branches of sensory nerve-fibers. The nerves of the liver accompany the portal vessels, the hepatic arteries, and the bile-ducts. The first division of the nerves, embracing the larger number of the intrinsic hepatic nerves, accompanying the branches of the portal vessels, form plexuses about them, and end in interlobular and intralobular ramifications, the latter showing here and there knob-like terminations on the liver-cells, and, in their course, give off here and there branches which end on the portal vessels.

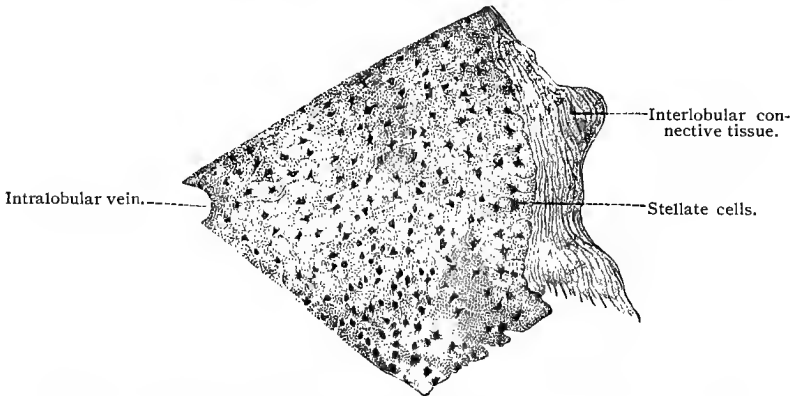


Fig. 225.—Part of a section through liver lobule from dog, showing stellate cells ;  
 $\times 168$  (*vid.* T. 257).

The nerve-fibers following the hepatic arteries are in every respect like the vascular nerves in other glands. Some of the terminal branches seem, however, to end on hepatic cells. The nerve-fibers following the bile-ducts may be traced to the smaller and medium-sized ducts, forming a network about them, and ending here and there in small twigs on the outer surface of the cells, and occasionally, it would seem, between the epithelial cells lining the ducts. The suggestion seems warranted that these terminal fibrils are the endings of sensory nerves. Some of the nerve-fibers following the bile-ducts may be traced into the hepatic lobules. The intralobular plexus is formed, therefore, by the terminal branches of the non-medullated nerve-fibers accompanying the portal and hepatic vessels and the bile-ducts. In the wall of the gall-bladder are found numerous small sympathetic ganglia formed by the grouping of the cell-bodies of sympathetic neurones (Dogiel). The neuraxes of these

innervate the nonstriated muscle of this structure. Large, medullated nerve-fibers may be traced through these ganglia which appear to end in free sensory endings in and under the epithelium lining the gall-bladder (Huber).

In the human embryo the liver originates from the intestine during the second month as a double ventral diverticulum. Later solid trabecular masses are developed which then unite and become hollow. At this stage the whole gland is uniform in structure, as a division into lobules does not take place until later. The bile capillaries are surrounded by more than two rows of cells. In this stage the embryonal liver suggests a condition which is permanent during the life of certain animals. Only later when the venæ advehentes, which later represent the branches of the portal vein, penetrate the liver, is there a secondary division into lobules (about the fourth month), by which process the primitive type gradually changes to that characteristic of the adult.

## E. THE PANCREAS.

Like the liver, the pancreas is an accessory intestinal gland, and originates as a diverticulum of the intestine. It remains in permanent communication with the intestine by means of its duct—the *pancreatic* or *Wirsungian duct*. The pancreas is composed of numerous microscopic lobules, surrounded by connective tissue which penetrates into the lobules and between the alveoli and is accompanied by vessels and nerves. The secretory portion of the organ may be regarded as a branched tubulo-acinal gland with terminal alveoli, the latter forming the principal portion of the gland. The epithelial walls of the alveoli consist of a number of secretory

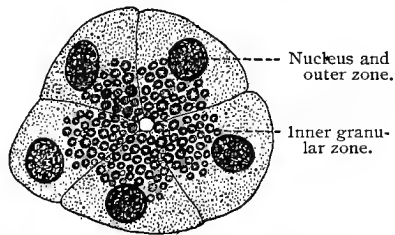


Fig. 226.—Transverse section through alveolus of frog's pancreas. Technic No. 125.

cells, whose appearance varies according to the functional state of the organ. The basilar portions of the cells present a homogeneous protoplasm, while those parts of the cells bordering upon the lumen are granular. The relation of these zones to each other depends upon the physiologic condition of the gland; during starvation the internal or granular zone is wide and prominent; after moderate secretion the cells become as a whole somewhat smaller, the granules decrease in number, and the outer or protoplasmic zone increases in size. After prolonged secretion there is an entire absence of the granules, and the whole cell apparently consists of homogeneous protoplasm. It is therefore probable

that during a state of rest peculiar granules (zymogen granules) are formed at the expense of the protoplasm, and that these granules represent a preliminary stage of the finished secretion. During the functional activity of the gland the granules gradually disappear, while the fluid secretion simultaneously makes its appearance in the lumen, although the granules have as yet never been observed in the lumen itself. After secretion the cell grows again until it reaches its original size, only again to begin the formation of zymogen granules. Whether the cells of the gland are destroyed or not during secretion is still a matter of uncertainty.

An *intermediate tubule* similar to those of the salivary glands connects with each alveolus, and then passes over into a short *intralobular duct*. This is lined, as in the salivary glands, with columnar epithelial cells, which are not, however (at least in man), striated at their basal ends. The intralobular ducts merge

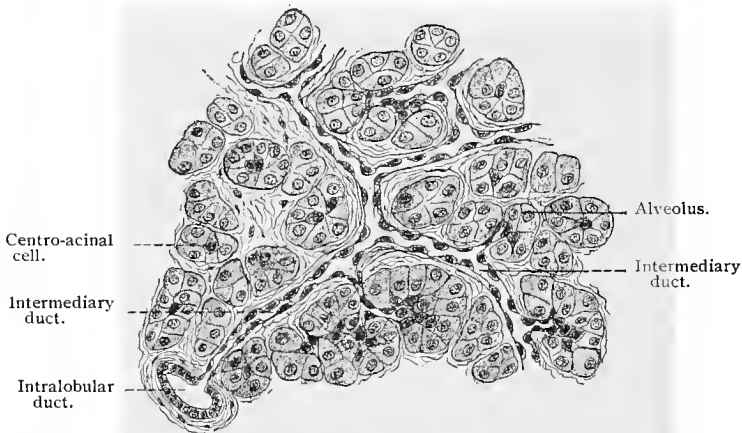


Fig. 227.—From section through human pancreas;  $\times$  about 200 (sublimite).

into excretory ducts, which finally empty into the pancreatic duct. The epithelium of the excretory ducts is simple columnar in type. Goblet cells are seen only in the pancreatic duct.

In the secreting alveoli small protoplasmic, polygonal, and even stellate cells are often seen, the so-called *centro-acinal cells*, or *cells of Langerhans*. The significance of these structures is not fully understood. Langerhans himself supposed that they belonged to the walls of the excretory ducts. This interpretation seems warranted by the fact that it has been found that the secreting cells of the alveoli are directly joined to the low cells of the intermediate tubules. When the alveoli lie closely packed together, the adjoining intermediate tubules fuse and are reduced to one or, at most, a few cells. As a result a condition is seen within the alveolar complexus, especially when the excretory ducts are in a collapsed state, closely resembling the structures seen by Langer-

hans. Peculiar cells, wedged in here and there between the secretory cells, but resting on the membrana propria, have also been observed. They undoubtedly are sustentacular cells of the gland (cuneate cells, Podwysotszki, 82).

The *membrana propria* of the alveoli is probably homogenous. Immediately adjoining it is another delicate but firm membrane, consisting of fibrils whose structure in many respects resembles that of the reticular fibers (Gitterfasern) in the liver and spleen, but which are here in relation to the alveoli (Podwysotszki, 82).

In warm- and cold-blooded animals, groups of cells differing in arrangement, size, and structure from the secretory cells, are found among the gland tubules and alveoli of the pancreas; these are known as the *intertubular cell-masses*, or *areas of Langerhans*. They

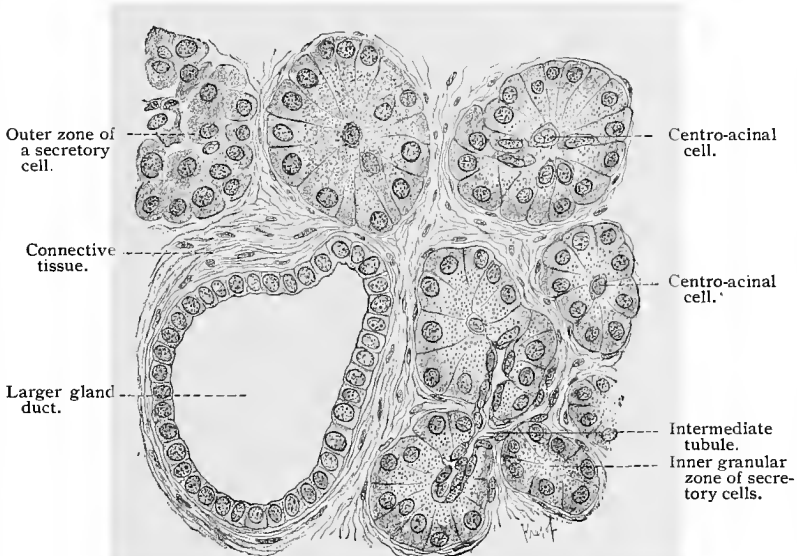


Fig. 228.—From section through human pancreas;  $\times 450$  (sublimite).

consist of slightly granular cells, smaller than the secretory cells of the alveoli, arranged in the form of anastomosing trabeculæ, with irregular spaces, varying in size, separating the trabeculæ. Dogiel (93) has shown that in a well-preserved human pancreas treated by the chrome-silver method, in which the gland ducts even to their finest intra-alveolar branches were well stained, no ducts were found in the areas of Langerhans. Such areas are, in the human pancreas, usually separated from the surrounding gland tissue by a small amount of connective tissue. They possess a blood supply, consisting of relatively large capillaries found in the spaces formed by the trabeculæ of cells above mentioned. The areas of Langerhans have been variously interpreted. They have been looked upon as small areas of gland tissue in process of degeneration, or

again as arcs of embryonic gland tissue. From their structure and distinct blood supply, and the fact that no ducts have been traced into these areas, it seems probable that they are small masses of cells forming a secretion which passes into the blood-vessels—internal secretion.

The blood-vessels enter the gland with the pancreatic duct, divide into smaller branches in the lobules, and finally break up into

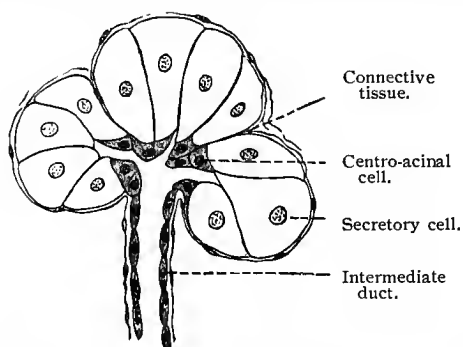


Fig. 229.—Scheme showing relation of three adjoining alveoli to excretory duct, illustrating origin of centro-acinal cells.

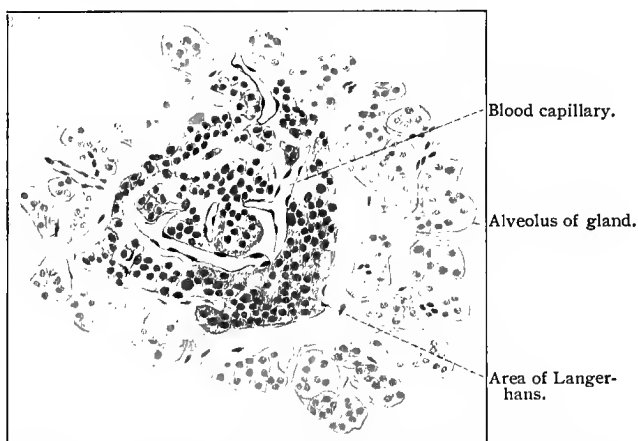


Fig. 230.—From section of human pancreas, showing gland alveoli surrounding an area of Langerhans.

capillaries which encircle the secreting alveoli. The meshes of the capillary network are not all of the same size. In some regions they are so wide that quite large areas of the alveoli are without blood-vessels.

The nerves of the pancreas have been investigated by Cajal and Sala (91) and Erik Müller (92), who find in this gland large numbers of nonmedullated nerve-fibers, some coming from sympathetic

ganglion cells situated in the pancreas and others entering from without. The nonmedullated nerve-fibers form plexuses surrounding the excretory ducts and end in periacinal networks. Fibrils from the network about the alveoli were traced to the secretory cells. A portion of the nonmedullated nerves in the pancreas form perivascular plexuses.

The development of the pancreas is peculiar in that the larger portion, together with the duct of Santorini, originates from the dorsal intestinal wall, and a smaller portion from the ductus choledochus. The latter part, with its accessory pancreatic duct, fuses with the former, after which there is a gradual retrogression of the duct of Santorini, so that finally the entire secretion of the pancreas almost invariably flows into the pancreatic or Wirsungian duct.

### TECHNIC.

**224.** The oral mucous membrane may be fixed with corrosive sublimate or alcohol, stained in bulk, and examined in cross-section. If special structures, such as glands, nerves, or the distribution of mitoses, are to be examined, special methods must be adopted.

**225.** In order to obtain a general view of the structure of the teeth, the latter must be macerated and ground as in the case of bone (T. 152).

**226.** The relations of the hard and soft parts in undecalcified teeth are best studied by the use of Koch's petrification method (*vid.* T. 158).

**227.** The teeth may also be examined in section, and when decalcified are treated as bone (*vid.* T. 157). Hydrochloric acid, dilute chromic acid, and picric acid dissolve the enamel prisms, their cement-substance being the first to disappear (von Ebner, 91).

**228.** The enamel of young teeth stains brown in a solution of chromic acid or its salts, and blackens in osmic acid. In the enamel cells, globules are seen, which are stained in osmic acid. If longitudinal sections of the enamel be corroded with hydrochloric acid, the cruciform arrangement of the enamel prisms is plainly seen.

**229.** The fibrils of the dentin may be demonstrated by decalcifying a tooth in the fluid recommended by von Ebner (T. 157), the teeth of young individuals being well adapted for this purpose. Occasionally carious teeth also show the fibrils plainly. Corrosion with hydrochloric acid produces the same result.

**230.** The cementum, especially that part lacking in cells, contains a large number of Sharpey's fibers.

**231.** The development of the teeth is studied in the embryo; the jaw-bone is fixed, decalcified, and cut in serial sections. The most convenient material is a sheep embryo, which can almost always be had from the slaughter-house.

**232.** To study the taste-buds of the tongue and the relations which their constituent cells bear to each other, fixation in Flemming's fluid is recommended. The orientation of the taste-buds must be very carefully done, after which exactly longitudinal or transverse serial sections are made (not thicker than  $5\ \mu$ ) and stained with safranin-gentian-violet (*vid.* T. 120).

233. The nerves in the taste-buds are brought out either by Golgi's method, the methylene-blue method, or by the use of gold chlorid. If the last be used the procedure is as follows: A papilla foliata of a rabbit is removed with a sharp razor and placed for ten minutes in lemon juice, then in gold chlorid for from three-quarters of an hour to one hour, after which the specimen is placed in water weakly acidulated with acetic acid (5 drops to 100 c.c. of water) and exposed to the light. As soon as reduction has taken place the specimen is treated with alcohol and cut in vertical sections. These may be treated for a short time with formic acid (in which they swell slightly), washed with water, and mounted in glycerin.

234. In certain objects, such as the nictitating membrane of the frog, certain lobules of the rabbit's pancreas (the latter being so thin as to be especially well adapted for microscopic examination), etc., the glandular structure may be examined in normal salt solution.

235. Microscopically, the glands present varying pictures according to the phase of secretion in which they are fixed. Specimens in the different stages may be obtained either by feeding and then killing the animal after a definite period, or by irritating certain nerves, or finally by the use of certain poisons especially adapted to this purpose, such as atropin and pilocarpin. In the rabbit, for instance, 1 c.c. of a 5% solution of pilocarpin hydrochlorate or 1 c.c. of a 0.5% solution of atropin sulphate is used for each kilogram of the animal's weight. In atropin-intoxication secretion is suppressed, while in pilocarpin-poisoning it is increased. By this method cells are obtained either full of secretion or containing no secretion at all.

236. Sections should be made from carefully selected material which has been fixed either in Flemming's solution or corrosive sublimate, although fixation with strong alcohol also gives instructive pictures.

237. In preparations fixed with Flemming's solution the crescents of Gianuzzi stain somewhat more deeply than the remaining cells of the alveoli, and in objects that have been treated with alcohol or corrosive sublimate and then stained with hematoxylin the crescents take on a very deep color. The intermediate tubules of the salivary glands also assume a deeper stain with hematoxylin and carmin. The intralobular tubes are particularly well defined by certain stains, as for instance when Congo red is used after staining with hematoxylin; other acid anilin stains may also be used (compare T. 242). The intralobular tubes of most salivary glands (not, however, of the parotid of the rabbit nor of the sublingual of the dog) are stained a dark-brown color (calcareous reaction) by agitating small, fresh pieces of tissue in order to facilitate the entrance of air, and then treating them with a dilute aqueous solution of pyrogallic acid. The stain persists for some time in specimens preserved in alcohol. Sections made by free hand from tissues treated by this method give excellent results (Merkel, 83).

238. Mucin is soluble in dilute alkalis, as for instance lime-water, and may be precipitated from these solutions by the addition of acetic acid, although the precipitate does not redissolve in an excess of acetic acid; mucin is also precipitated by alcohol, but not by heat. Mucinogen does not stain with hematoxylin, as does mucin. By this latter test a gland in a state of functional activity may be differentiated from one at rest (R. Heidenhain, 83). After treatment with alcohol, safranin

stains mucin orange-yellow. For the demonstration of mucin, more especially in alcoholic preparations, H. Hoyer (90) has recommended thionin or its substitute, toluidin-blue. Indeed, the basic anilin dyes in general seem to have a particular affinity for mucin.

239. P. Mayer (96) recommends the following two solutions for the staining of mucin: (1) Mucicarmin—Carmin 1 gm., aluminium chlorid 0.5 gm., and distilled water 2 c.c. are stirred together and heated over a small flame till the mixture becomes quite dark. As soon as the mixture has attained the consistency of thick syrup, 50% alcohol is added and the whole transferred to a bottle in which it is shaken after the addition of more alcohol. Finally, still more 50% alcohol is added until the whole amounts to 100 c.c. Before using, this stock solution is diluted tenfold with tap-water rich in lime-salts. (2) Muchematein: (a) Aqueous solution—0.2 gm. of hematein is ground in a mortar containing a few drops of glycerin; to this are added 0.1 gm. aluminium chlorid, 40 c.c. glycerin, and 60 c.c. distilled water. (b) Alcoholic solution—0.2 gm. hematein, 0.1 gm. aluminium chlorid, 100 c.c. 70% alcohol, and 1 or 2 drops of nitric acid. Both of these solutions are used for staining mucin in sections and thin membranes. By the use of these methods the mucous acini of mixed glands are shown with ease and precision. Under favorable conditions the whole secretory and excretory system of the gland may be brought out by Golgi's method (see this).

240. In order to obtain a general structural view of the esophagus a small animal may be selected, in which case small pieces of tissue are fixed and imbedded in paraffin. If a large animal is used, the tissue is imbedded in celloidin.

241. The mucous membrane of the stomach should be fixed while still fresh and warm, the best fixative for this purpose being corrosive sublimate. Mixtures of osmic acid are also serviceable, but fixing with corrosive sublimate increases the staining power of the tissue. In order to preserve the stomach and intestine in a dilated condition, they should be filled with the fixing fluid and after ligation placed whole in the fixing agent.

242. In gastric mucous membrane that has been fixed either with corrosive sublimate or alcohol, the parietal cells are easily differentiated from the chief cells by staining. The most reliable and convenient method is as follows: Sections fastened to the slide by the water-albumin fixative method are stained with hematoxylin and then placed in a dilute aqueous solution of Congo red until they assume a red color (minutes); they are then washed with dilute alcohol until the parietal cells appear red and the chief cells bluish (Stintzing). Almost all acid anilin dyes have an affinity for the parietal cells; hence the red stains may be combined with hematoxylin and the blue ones with carmin. The chief cells then take the color of the carmin or hematoxylin, and the parietal cells that of the anilins.

243. An accurate fixation of that portion of the small intestine possessing villi is attended with great difficulty, since the axial tissue of the villi shows a tendency to retract from the epithelial layer surrounding it (the latter becoming fixed first); and as a consequence spaces are formed at the summits of the villi which undoubtedly represent artefacts. A good method is to cut pieces from tissue while still warm and fix in osmic acid. If portions of the intestine be filled with alcohol or corrosive sublimate and thus dilated, both the glands and villi are shortened. The

methods above mentioned for staining mucin may be used to stain the goblet cells. The villi may also be examined in a fresh condition in one of the indifferent fluids (*vid.* T. 13). For this purpose the intestine of the mouse is especially well adapted.

**244.** The absorption of fat is best studied in preparations fixed in osmic acid, and especially in those treated by Altmann's method (*vid.* T. 124).

**245.** The technic for the solitary lymph-follicles and Peyer's patches is the same as that for lymph-glands. For this purpose the cecum of a rabbit or guinea-pig is the best material.

**246.** The nerves of the intestinal mucous membrane are best demonstrated by means of the methylene-blue method or Golgi's method (*vid.* Technic), and the coarser filaments of Auerbach's and Meissner's plexuses may also be stained by the gold method (Löwit's procedure, T. 182). Good results are also obtained by staining with hematoxylin such specimens as have been previously fixed and distended with alcohol. The plexuses then appear somewhat darker than the remaining tissue of the isolated mucous membrane or muscular layer.

**247.** The arrangement of the liver lobules is best seen in the pig's liver. In the human liver and in most domestic animals the lobules are not sharply defined, two or three adjacent lobules merging into each other. In the liver of the fetus, of the new-born, and of children, the lobules are seen indistinctly or not at all, although the perivascular spaces of the blood-vessels are better seen than in the adult.

**248.** The liver-cells are best examined by treating small pieces of tissue with 1% osmic acid or osmic mixtures; in the latter case subsequent treatment with pyroligneous acid is necessary (T. 18). Good results can also be obtained by fixing with corrosive sublimate and staining with hematoxylin (after M. Heidenhain, T. 65).

**249.** In order to see the glycogen in the liver-cells Ranvier (89) proceeds as follows: A dog is fed on boiled potatoes for two days, after which sections of its liver are cut with a freezing microtome and examined in iodized serum (T. 13). In a short time the glycogen is stained a wine-red. If the preparation be now exposed to osmic acid vapor, the stain will remain fixed for from twenty-four to forty-eight hours. Glycogen is insoluble in alcohol and ether, and stains a port wine-red in iodine solutions; the color disappears when the specimen is warmed, but returns again on cooling.

**250.** The distribution of the hepatic blood-vessels is usually demonstrated by injection of the portal vein, as the injection of the hepatic artery does not, as a rule, give such satisfactory results.

**251.** The injection method is also employed for the demonstration of the bile capillaries. Chrzonszczewsky recommends the following so-called physiologic autoinjection: A saturated aqueous solution of indigo-carmin is injected into the external jugular vein three times in the course of one and one-half hours (dog 50 c.c. each time, cat 30 c.c., full-grown rabbit 20 c.c.). The animal is then killed and small pieces of its liver fixed in absolute alcohol or in potassium chlorid; in the latter case a saturated solution of the salt may be injected into the blood-vessels. A subsequent injection of the blood-vessels with carmin-gelatin may also be employed and the whole liver then hardened in alcohol. By

this method the bile capillaries finally become filled with the indigo-carmin by a gradual elimination of the substance from the blood- and lymph-vessels and passage through the cells into the biliary system, while the blood-vessels themselves are distended by the carmin-gelatin. In the frog, the demonstration of the biliary passages is more easily accomplished by injecting 2 c.c. of the indigo-carmin solution into the large lymph-sac and killing it after a few hours. The liver is then fixed in the manner described above and is then ready for further treatment.

**252.** The bile passages may also be injected directly through the hepatic duct or the ductus choledochus. For this purpose it is best to use a concentrated aqueous solution of Berlin blue (Berlin blue that is soluble in water). The results obtained by this method are not, however, always satisfactory, and even in the best of cases only the peripheral portions of the liver lobules are successfully injected.

**253.** The bile capillaries may be impregnated with chrome-silver. Fresh pieces of liver tissue are placed for two or three days in a potassium bichromate-osmic acid solution (4 vols. of a 3% bichromate of potassium solution and 1 vol. of 1% osmic acid) and then transferred to a 0.75% aqueous solution of silver nitrate. After rinsing in distilled water the specimens are cut with a razor, the sections again washed with distilled water, placed for a short time in absolute alcohol, cleared in xylol, and finally preserved in hard Canada balsam. Both celloidin and paraffin imbedding are admissible, but either process must be hurried, as the preparation always suffers under such treatment. In the finished specimen, the bile capillaries appear black by direct light.

**254.** Another method which brings to view more extensive areas of the bile capillaries is as follows: A piece of liver tissue from a freshly killed animal is fixed in rapidly ascending strengths of potassium bichromate solution (from 2% to 5%). After three weeks the specimen is placed in a 0.75% silver nitrate solution, when after a few days (very marked after eight days) the bile capillaries, if examined in sections, will appear black by direct light (Oppel, 90).

**255.** Sometimes the bile capillaries are brought out in preparations treated by the method of R. Heidenhain (T. 85), although only small areas are colored and these not constantly. The application of other stains, as for instance the method of M. Heidenhain (T. 65) following the gold chlorid treatment, often results in the staining of small areas of bile capillaries.

**256.** In all the methods used for the demonstration of the bile capillaries, whether physiologic autoinjection, direct injection, or impregnation, the secretion vacuoles of the liver-cells are clearly brought to view.

**257.** By treating pieces of liver tissue according to the method of Kupffer (76) the connective tissue of the liver, especially the reticular structure (Gitterfasern), is shown. Fresh liver tissue is cut with the double knife and the thinnest sections placed for a short time in a 0.6% sodium chlorid solution or in a 0.05% solution of chromic acid. From this they are transferred to a very dilute solution of gold chlorid (Gerlach) (gold chlorid 1 gm., hydrochloric acid 1 c.c., water 10 liters), and kept for one to several days in the dark until they assume a reddish or violet color. If the staining has been satisfactory (which is by no means always the case), the reticular fibers, and occasionally also the stellate cells, are

seen. Instead of the double knife the freezing microtome may be used and the method continued as stated (Rothe).

**258.** The reticular fibers are seen under more favorable conditions by using the following method, recommended by Oppel (91): Fresh pieces of tissue fixed in alcohol are placed for twenty-four hours in a 0.5% aqueous solution of yellow chromate of potassium (larger pieces in stronger solutions up to 5%), then washed with a very dilute solution of nitrate of silver (a few drops of a 0.75% solution to 30 c.c. distilled water), and transferred to a 0.75% solution of silver nitrate. In twenty-four hours the intralobular network surrounding the blood capillaries will have become stained. The best areas lie at the periphery of the specimen, and extend about 1 mm. into the parenchyma. Free-hand sections are made, or the specimens are quickly imbedded in celloidin or paraffin, to be cut afterward by means of the microtome. The same results are obtained by placing small fresh pieces of the tissue for two or three days in a 0.5% chromic acid solution and then one or two days in a 0.5% solution of silver nitrate. The further treatment is as in the preceding method.

**259.** The method of Mall (*vid.* T. 212) is also employed in the examination of the hepatic connective tissue.

**260.** The following method is recommended by Berkley for demonstrating the nerves of the liver: Small pieces of liver tissue from 0.5 to 1 mm. in breadth are placed in a half-saturated aqueous solution of picric acid for from fifteen to thirty minutes, and then in 100 c.c. of potassium bichromate solution that has been saturated in the sunlight and to which 16 c.c. of 2% osmic acid has been added. The specimens now remain in this fluid for forty-eight hours in a dark place, and at a temperature of 25° C. After this the tissue is treated with a 0.25% to 0.75% aqueous solution of silver nitrate for five or six days, washed (quick imbedding may be employed), cut, cleared in oil of bergamot, and mounted in xylol-Canada balsam.

**261.** The cellular elements of the pancreas may be examined without further manipulation in very thin lobules from the rabbit (Kühne and Lea).

**262.** There are various methods of differentiating the inner and outer zones of the cells. In sections of the tissue fixed in alcohol, carmin stains the outer zone of the cells more intensely than the inner (R. Heidenhain, 83). For the staining of the inner zone, fixation in Flemming's fluid is to be recommended, then staining with safranin, and finally washing in an alcoholic solution of picric acid. The granules of the inner zone (zymogen granules) appear red. These also stain red with the Biondi-Ehrlich mixture (T. 78). The simplest and most precise method of demonstrating the zymogen granules is that of Altmann (T. 124). The secretory and excretory ducts of the pancreas are shown, as in the case of the salivary glands, by the chrome-silver method (compare T. 253).

## IV. ORGANS OF RESPIRATION.

## A. THE LARYNX.

THE greater portion of the laryngeal mucous membrane is covered by a stratified columnar ciliated epithelium containing goblet cells, and resting on a thick basement membrane. The epithelium covering the free margin of the epiglottis, the true vocal cords, and

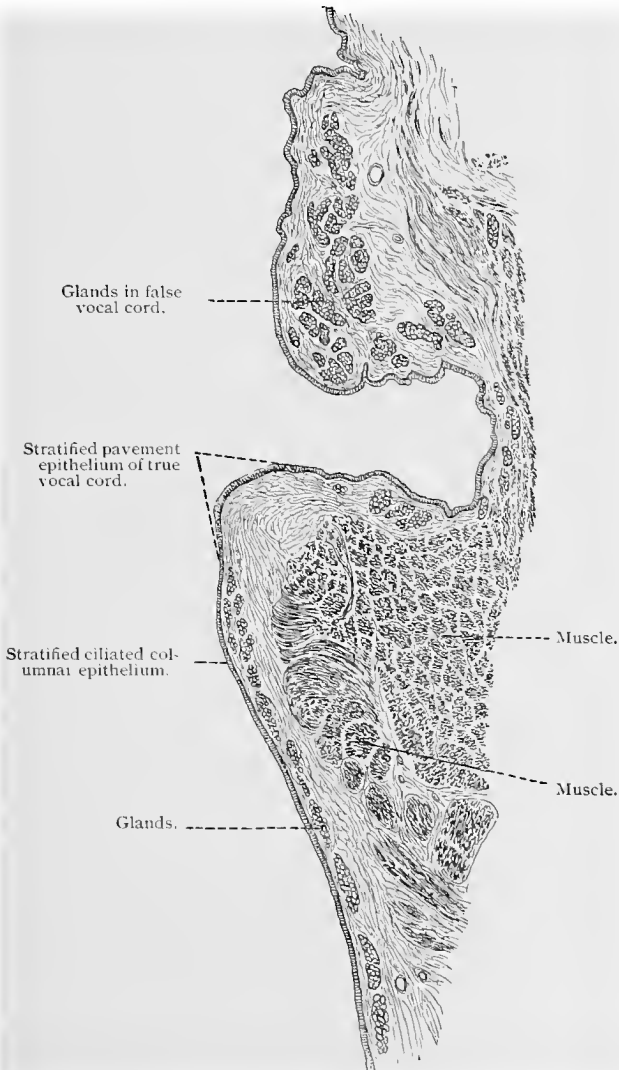


Fig. 231.—Vertical section through the mucous membrane of the human larynx ;  $\times 5$ .

part of the arytenoid cartilage as far as the cavity between these cartilages, is of the stratified squamous variety, and is provided with connective-tissue papillæ. The mucosa contains many elastic fibers, and is rather firmly connected with the structures underneath it, but is somewhat more loosely connected in the regions supplied with squamous epithelium. In it are found branched tubulo-acinal glands, which may be single or arranged in groups. These are found at the free posterior portion of the epiglottis, in the region of the latter's point of attachment—*i. e.*, in the so-called cushion of the epiglottis. Larger collections of glands are found in the false vocal cords, and on the cartilages of Wrisberg (cuneiform cartilages), which appear almost imbedded in the glandular tissue. In the remaining parts of the larynx glands are found only at isolated points. The true vocal cords have no glands.

The cartilages of the larynx are of the hyaline variety, with the exception of the epiglottis, the cartilages of Santorini (the latter are derivatives of the epiglottis, Göppert), the cuneiform cartilages, the processus vocalis, and a small portion of the thyroid at the points of attachment of the vocal cords, which consist of elastic cartilage.

The vascular supply of the larynx is arranged in three superimposed networks of blood-vessels. The capillaries are very fine, and lie directly beneath the epithelium. The lymphatic network is arranged in two layers, the superficial being very fine and directly beneath the network of blood capillaries.

The nerves of the laryngeal mucous membrane will be described in connection with those found in the trachea.

## B. THE TRACHEA.

The trachea is lined by a stratified ciliated columnar epithelium containing goblet cells and resting on a well-developed basement membrane. The mucosa is rich in elastic tissue. In the superficial portion of the mucosa the elastic fibers form dense strands, which usually take a longitudinal direction. The deeper layer of the mucosa is more loosely constructed, and passes over into the perichondrium of the semilunar cartilages of the trachea without any sharp line of demarcation. Numerous leucocytes are scattered throughout the mucosa, and are also frequently found in the epithelium. Connecting the free ends of the semilunar cartilages, which are of the hyaline variety, are found bundles of nonstriated muscle tissue, the direction of which is nearly transverse.

The trachea contains numerous branched tubulo-acinal glands of the mucous variety containing here and there crescents of Gianuzzi. The glands are especially numerous where the tracheal wall is devoid of cartilage.

The larynx and trachea receive their nerve supply from sensory

nerve-fibers and sympathetic neurones. These have been described by Ploschko (97) working in Arnstein's laboratory. According to this observer, the sensory fibers divide in the mucosa, forming sub-epithelial plexuses from which fibrils are given off which enter the epithelium of the larynx and trachea and, after further division, end on the epithelial cells in small nodules, or small clusters of nodules. In the trachea of the dog, such fibrils were traced to the ciliary border of the columnar ciliated cells before terminating. Numerous sympathetic ganglia are found in the larynx and trachea. In the latter they are especially numerous in the posterior wall. The neuraxes of the sympathetic neurones forming these ganglia were traced to the nonstriated muscular tissue of the trachea. The cell-bodies of these sympathetic neurones are surrounded by end-baskets of small medullated fibers terminating in the ganglia. Medullated

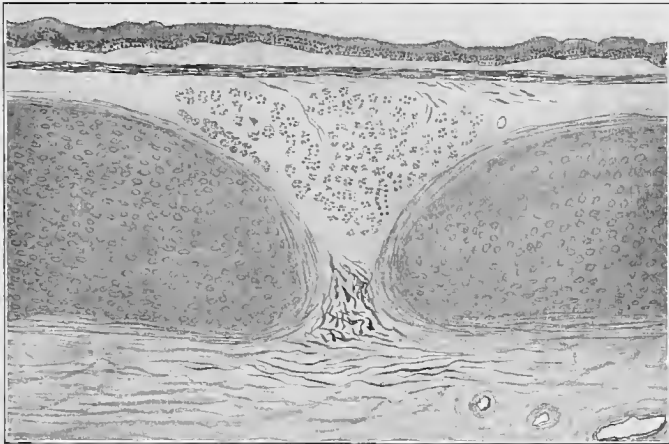


Fig. 232.—From longitudinal section of human trachea, stained in orcein.

nerve-fibers, ending in the musculature of the trachea in peculiar end-brushes, were also described by Ploschko.

### C. THE BRONCHI, THEIR BRANCHES, AND THE BRONCHIOLES.

The primary bronchi and their branches show the same general structure as the trachea. The epithelium of the bronchi of medium size (up to 0.5 mm. in diameter) consists of a ciliated epithelium having three strata of nuclei. Kölliker (81) distinguishes a deep layer of basilar cells, a middle layer of replacing cells, and a superficial zone consisting of ciliate and goblet cells. The number of the last varies greatly. Glands are found only in bronchial twigs that are not less than 1 mm. in diameter; as in the trachea, they are branched tubulo-acinous glands of the mucous variety.

In these structures the mucosa contains a large number of elastic fibers, the greater part of which have a longitudinal direction. Furthermore, numerous lymph-cells are found, and here and there a lymph-nodule. The muscularis presents, as a rule, circular fibers, which do not, however, form a continuous layer. The cartilaginous framework here no longer consists of symmetrically arranged rings, but of irregular platelets, which are absent in bronchial twigs less than 0.85 mm. in diameter.

The smaller bronchi subdivide into still finer tubules of less than 0.5 mm. in diameter (bronchioles), which contain neither car-

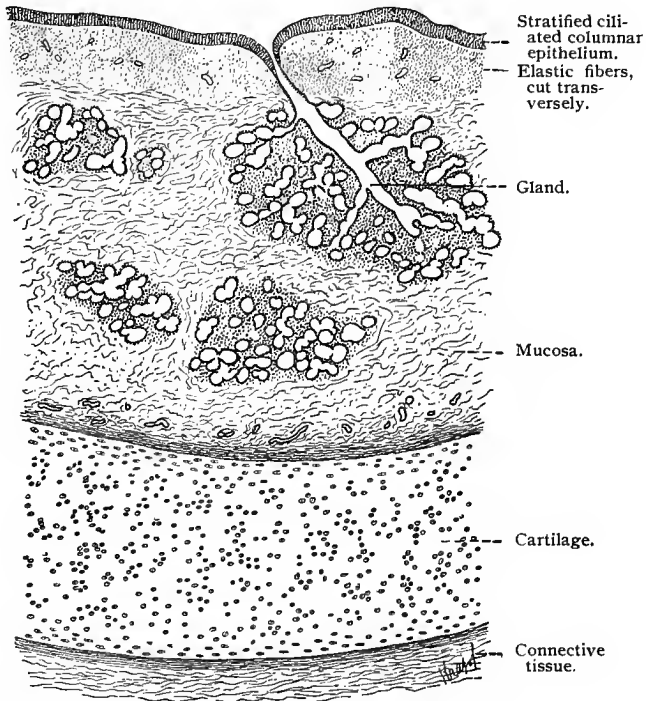


Fig. 233.—Transverse section through human bronchus;  $\times 27$ .

tilage nor glands. The stratum proprium, as well as the external connective-tissue sheath, becomes very thin; and the epithelium now consists of but one layer, but is still ciliated.

### D. THE RESPIRATORY BRONCHIOLES, ALVEOLAR DUCTS, AND INFUNDIBULA.

The bronchioles are continued as the respiratory bronchioles.

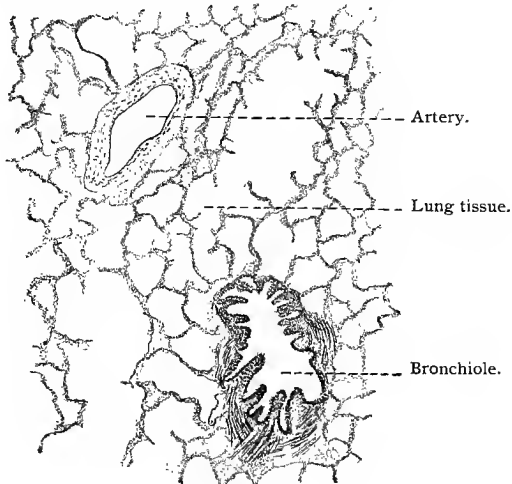


Fig. 234.

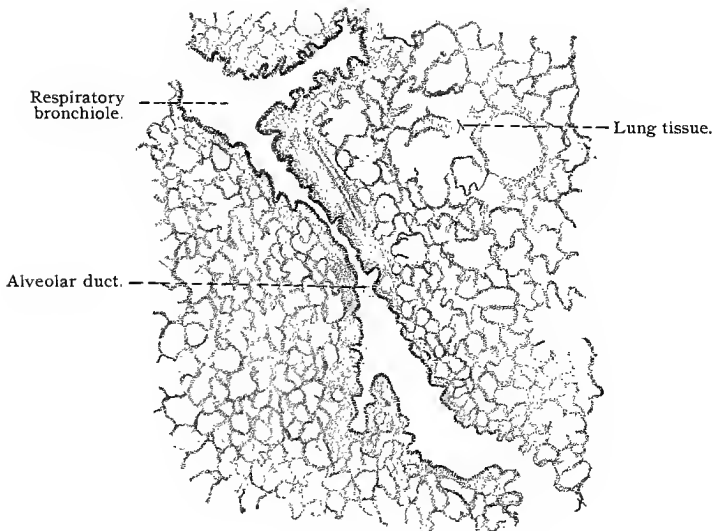


Fig. 235.

Figs. 234 and 235.—Two sections of cat's lung: Fig. 234,  $\times 52$ ; Fig. 235,  $\times 35$ .

The epithelium of the latter is ciliated in patches, but ultimately becomes nonciliated, and assumes the character of the respiratory epi-

thelium. (See below.) The fine tubular segments of the respiratory passages, lined by an epithelium which marks the transition from the mixed to the respiratory epithelium, are known as the alveolar ducts. The muscle-fibers may be traced as far as these segments, where they are lost. Both in the walls of the respiratory bronchioles and along the alveolar ducts there occur diverticula called alveoli.

Each alveolar duct is continuous with a so-called infundibulum.

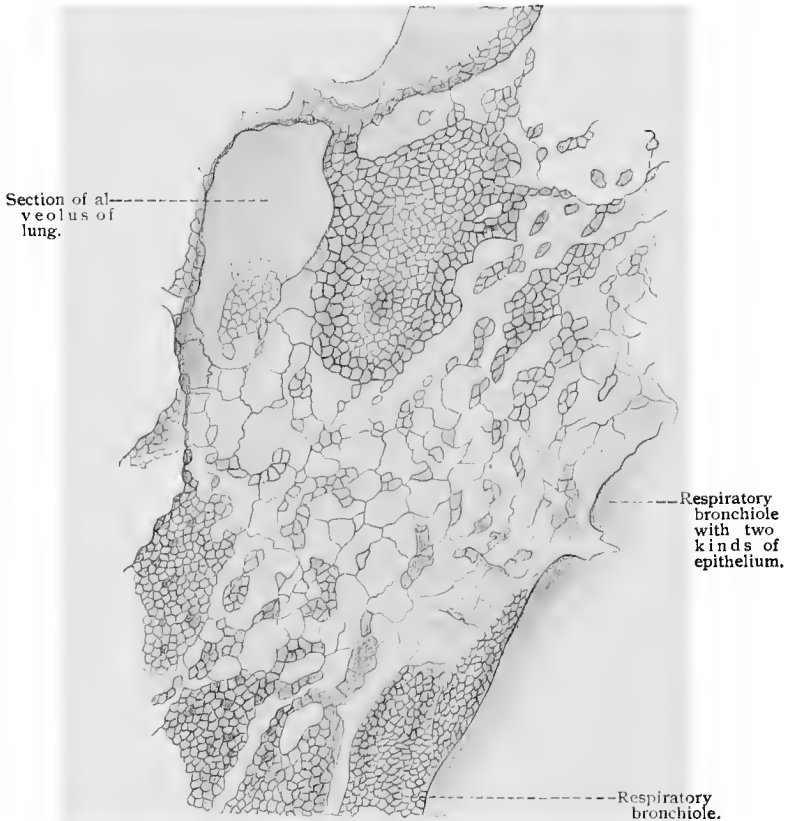

Fig. 236.—Internal surface of a human respiratory bronchiole, treated with silver nitrate;  $\times 234$  (after Kölliker).

The general shape of the latter is conical, the base of the cone being turned away from the duct. Numerous diverticula are present in the walls of the infundibula, known as the air-sacs or alveoli of the lung. The epithelium of the infundibulum ( $11 \mu$  to  $15 \mu$  in diameter) and of its alveoli (the so-called respiratory epithelium) consists of two varieties of cells (F. E. Schulze)—smaller nucleated elements and larger nonnucleated platelets (the latter derived very probably from the former). The arrangement of the epithelial cells

is generally such that the nonnucleated platelets rest directly upon the blood capillaries, while nucleated cells lie between them. The basement membrane beneath the epithelium of the respiratory passages gradually becomes thinner as it approaches the infundibula, and in the latter is scarcely to be seen.

In amphibia the epithelium of the alveoli consists of cells, of which the portion containing the nucleus forms a broad cylindrical base; from the free end of each cell a lateral process extends over the adjoining capillary to meet a similar process from the neighboring cell. When viewed from above, the basal portion of the cell appears dark and granular, while the processes are clear and transparent. These cells, together with their prolongations, are about  $50\ \mu$  in diameter. The surface view greatly resembles that of the human respiratory epithelium [Duval, Oppel, 89].

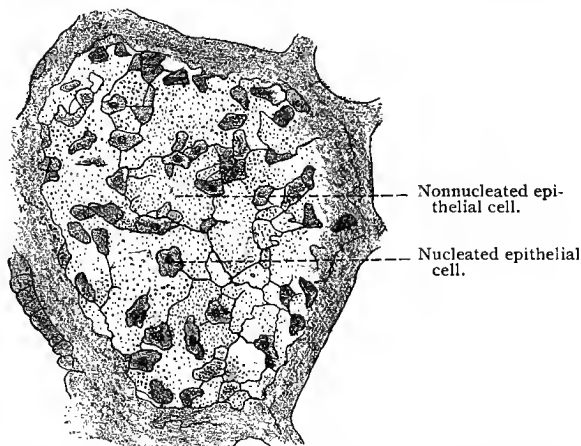


Fig. 237.—Inner surface of human alveolus treated with silver nitrate, showing respiratory epithelium;  $\times 240$  (after Kölliker).

The walls of the infundibulum and its alveoli are encircled by very delicate elastic fibers.

The lung tissue is arranged in small lobules, which form definite units in its anatomy and pathology (Councilmann, 1900). These lobules have a diameter of from 1 to 3 cm. in the adult, and from 0.5 to 1.5 cm. in the child from two to eight years old. They are of pyramidal shape, the apex of the lobule being formed by a small bronchus. They are separated from one another by a small amount of interlobular fibrous tissue. The small bronchus entering the apex of each lobule divides within the lobule several times, each bronchiole becoming a respiratory bronchiole, alveolar duct, and infundibulum, with alveoli or air-sacs associated with them.

The visceral and the parietal layers of the pleura consist of a layer of fibro-elastic tissue covered by a layer of mesothelium.

The blood-vessels of the lung have been described by Miller

(93) working under Mall's direction. His account is closely followed in the following description: The pulmonary artery follows closely the bronchi through their entire length. An arterial branch enters each lobule of the lung at its apex in close proximity to the bronchus. After entering the lobule the artery divides quite abruptly, a branch going to each infundibulum; from these branches the small arterioles arise which supply the alveoli of the lung. "On reaching the air-sac the artery breaks up into small radicals which pass to the central side of the sac in the sulci between the air-cells, and are finally lost in the rich system of capillaries to which they give rise. This network surrounds the whole air-sac and communicates freely with that of the surrounding sacs." This capillary network is exceedingly fine and is sunk into the epithelium of the air-sacs so that between the epithelium and the capillary

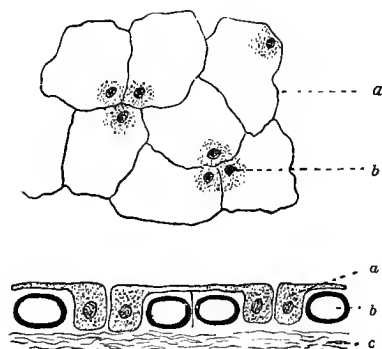


Fig. 238.—Scheme of the respiratory epithelium in amphibia: The upper figure gives a surface view: *b*, Basilar portion; *a*, the thin process. The lower figure is a section: *a*, Respiratory epithelial cell; *b*, blood-vessel; *c*, connective tissue around the alveoli.

there is only the extremely delicate basement membrane. The infundibula, the alveolar ducts and their alveoli, and the alveoli of the respiratory bronchioles are supplied with similar capillary networks. The veins collecting the blood from the lobules lie at the periphery of the lobules in the interlobular connective tissue, and are as far distant from the intralobular arteries as possible. These veins unite to form the larger pulmonary veins.

The bronchi, both large and small, as well as the bronchioles, derive their blood supply from the bronchial arteries, which also partly supply the lung itself. Capillaries derived from these arteries surround the bronchial system, their caliber varying according to the structure they supply—finer and more closely arranged in the mucous membrane, and coarser in the connective-tissue walls. In the neighborhood of the terminal bronchial tubes the capillary nets anastomose freely with those of the respiratory capillary system. From the capillaries of the bronchial arteries, veins are formed which empty either into the bronchial veins or into the branches of the pulmonary veins.

The lymphatics of the lung originate between the alveoli. They form two sets of vessels (Councilmann, 1900)—the one found in the interlobular connective tissue, which communicates with lymph-vessels in the pleura, forming a rich plexus, terminating in several lymphatic vessels, provided with valves, which end in the lymph-glands at the root of the lung, and "a central set which accompa-

gies the pulmonary artery and passes directly into the bronchial glands at the hilum of the lung."

Accompanying the bronchi and bronchial arteries are found numerous nerve-fibers, of the nonmedullated and medullated varieties, arranged in bundles of varying size, in the course of which are

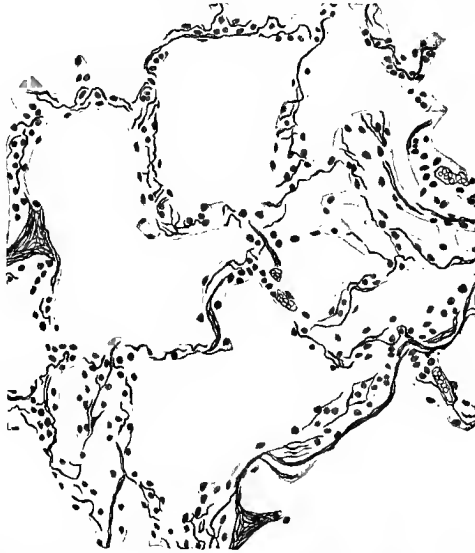


Fig. 239.—From section of human lung stained in orcein, showing the elastic fibers surrounding the alveoli.

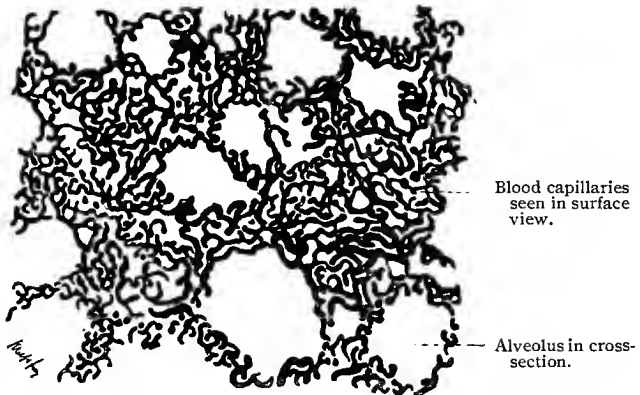


Fig. 240.—Section through injected lung of rabbit.

found sympathetic ganglia. Berkley (94), who has studied the distribution of the nerves of the lung with the chrome-silver method, finds that in the external fibrous layer of the bronchi is found a plexus of very fine and of coarser fibers, from which branches are

given off which end in the muscle tissue of the bronchi, and others which pass through this layer to form, after further division, a sub-epithelial plexus from which fibrils may be traced into the connective-tissue folds in the larger bronchi and between the bases of the epithelial cells in the smaller bronchi and bronchioles. Some few fibrils were traced between alveoli situated near bronchi, "terminating, apparently, immediately beneath the pavement epithelium in an elongated or rounded minute bulb;" these may, however, represent endings on nonstriated muscle tissue. The bronchial arteries have an exceedingly rich nerve supply.

### E. THE THYROID GLAND.

The thyroid gland is developed from three sources: Its middle portion, the isthmus of the gland, originates as a diverticulum of

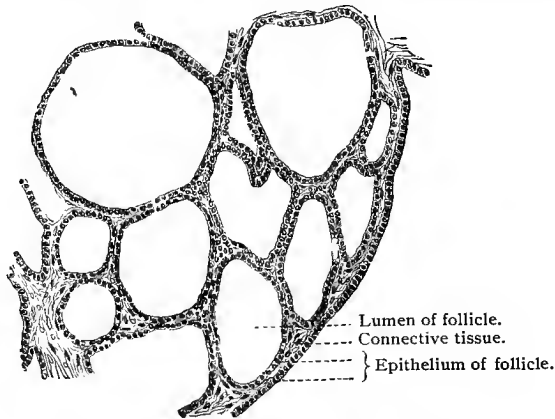


Fig. 241.—From section through thyroid gland of child.

the pharyngeal epithelium, from what is later the foramen cæcum of the tongue; both lateral portions, the right and left lobes, are formed from a complicated metamorphosis of the epithelium of the fourth visceral pouch. These various parts unite in man into one, so that in the adult the structure of the organ is continuous. The thyroid gland consists of numerous noncommunicating acini or follicles of various sizes lined by a nearly cubic epithelium; the lobules are separated from each other by a highly vascularized connective tissue, continuous with the firm connective-tissue sheath surrounding the whole gland. The follicles are either round, polyhedral, or tubular, and are occasionally branched (Streff). At an early stage the acini are found to contain a substance known as "colloid" material (*vid.* Technic).

Langendorff has shown (*vid.* Technic) that two varieties of cells exist in the acini of the thyroid body—the *chief cells* and *colloid*

*cells.* Those of the first variety apparently change into colloid cells, while the latter secrete the colloid substance. During the formation of this material the colloid cells become lower, and their entire contents, including the nuclei, change into the colloid mass. Hürthle distinguished two processes of colloid secretion; in the one the cells remain intact, in the other they are destroyed. He claims that the colloid cells of Langendorff participate in the former process, while in the latter they are first modified (flattened) and then changed into the colloid substance. The colloid material may enter the lymph-channels, either directly by a rupture of the acini, or indirectly by a percolation of the substance into the intercellular clefts, whence it is carried into the larger lymphatics.

Anderson (91) and Berkley (94) have studied the distribution of the nerve-fibers of the thyroid gland with the chrome-silver method; the account given by the latter is the more complete and will be followed here. The nonmedullated nerves entering the gland form plexuses about the larger arteries, which are less dense around the smaller arterial branches. Some of these nerve-fibers are vascular nerves and end on the vessels; others form perifollicular meshes surrounding the follicles of the gland. From the network of nerve-fibers about the follicles, Berkley was able to trace fine nerve filaments which seemed to terminate in end-knobs on or between the epithelial cells lining the follicles. Even in the best stained preparations, however, not nearly all the follicular cells possess such a nerve termination. In methylene-blue preparations of the thyroid gland (Dr. De Witt) some few medullated fibers were found in the nerve plexus surrounding the vessels. In a number of preparations these were traced to telodendria situated in the adventitia of the vessels, showing that at least a portion of these medullated nerves are sensory nerves ending in the walls of the vessels.

### PARATHYROID GLANDS.

Small glandular structures found on the posterior surfaces of the lateral lobes of the thyroid were discovered by Sandström in 1880. They are surrounded by a thin connective-tissue capsule and divided into small imperfectly developed lobules by a few thin fibrous-tissue septa or trabeculæ, which support the larger vessels. The epithelial portions of these structures consist of relatively large cells and capillary spaces. According to Schaper (95), who has recently subjected these structures to a careful investigation, the epithelial cells have a diameter which varies from 10  $\mu$  to 12  $\mu$ , possessing nuclei 4  $\mu$  in diameter. These cells are of polygonal shape and have a thin cell-membrane, a slightly granular protoplasm, and a nucleus presenting a delicate chromatic network. The cells are arranged either in larger or smaller clusters or, in some instances, in anastomosing trabeculæ or columns, consisting either of a single row or of several rows of cells. Between the clusters or columns of cells are found rela-

tively large capillaries, the endothelial lining of which rests directly on the epithelial cells. Connective-tissue fibrils do not, as a rule, follow the capillaries between the cell-masses. The structure of the parathyroid resembles in many respects that of certain embryonic stages of the thyroid, and it has been suggested that these bodies represent small masses of thyroid gland tissue, retaining their embryonic structure. Schaper has observed parathyroid tissue, the cells of which were here and there arranged in the form of small follicles, some of which contained colloid substance. Such observations lend credence to the view regarding the parathyroid as an embryonic structure. Whether in this stage they form a special secretion has not been fully determined. (See Schaper, 95.)

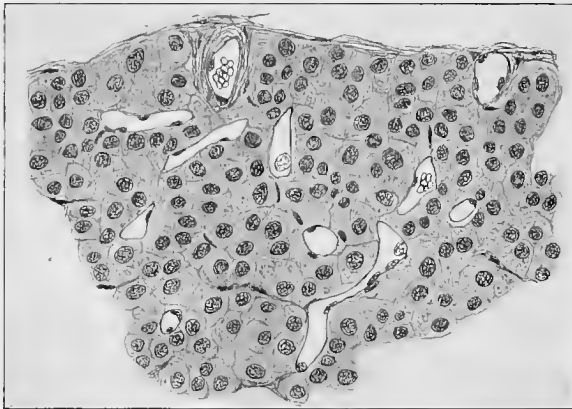


Fig. 242.—From parathyroid of man.

#### TECHNIC.

**263.** For the demonstration of the larynx and trachea, young and healthy subjects should be selected. Pieces of the mucous membrane or the whole organ should be immersed in a fresh condition. Sections through the entire organ present only a general structural view; but if a close examination of accurately fixed mucous membrane be desired, the latter should be removed with a razor before sectioning and treated separately.

**264.** Chromic-osmic acid mixtures are recommended as fixing agents, and safranin as a stain. Besides the nuclear differentiation, the goblet cells stain brown, and the elastic network of the stratum proprium and the submucosa a reddish-brown.

For examining the epithelium, isolation methods are employed, such as the  $\frac{1}{3}$  alcohol of Ranvier (T. 128).

**265.** The examination of the respiratory epithelium is attended with peculiar difficulty; it is, perhaps, best accomplished by injecting a 0.5% solution of silver nitrate into the bronchus until the lumen is completely filled, and then placing the whole in a 0.5% solution of the same salt. After a few hours, wash with distilled water and transfer to

70% alcohol. Thick sections are now cut and portions of the respiratory passages examined; the silver lines represent the margins of the epithelial cells. Such sections should not be fastened to the slide with albumen, as the latter soon darkens and blurs the picture. These specimens may also be stained.

266. For the elastic fibers, especially those of the alveoli, fixation in Müller's fluid (T. 27) or in alcohol and staining with orcein is a good method. Fresh pieces of lung tissue treated with potassium hydrate show numerous isolated elastic fibers.

267. Pulmonary tissue may be treated by Golgi's method, which brings out a reticular connective-tissue structure in the vessels and alveoli (*vid.* T. 252, Oppel).

268. The pulmonary vessels may be injected with comparative ease.

269. The thyroid gland is best fixed in Flemming's solution; it is then stained with M. Heidenhain's hematoxylin solution or, better still, with the Ehrlich-Biondi mixture which differentiates the chief from the colloid cells; the former do not stain at all, while the latter appear red with a green nucleus (Langendorff). The colloid substance of the thyroid gland does not cloud in alcohol or chromic acid, nor does it coagulate in acetic acid, but swells in the latter; 33% potassium hydrate hardly causes the colloid material to swell at all, though in weaker solutions it dissolves after a long time.

## V. THE GENITO-URINARY ORGANS.

### A. THE URINARY ORGANS.

#### 1. THE KIDNEY.

THE kidney is a branched tubular lobular gland, which in man consists of from ten to fifteen nearly equal divisions of pyramidal shape known as the *renal lobes*. The apex of each pyramid (the Malpighian pyramid) projects into the pelvis of the kidney. The kidney is surrounded by a thin but firm capsule consisting of fibrous connective tissue containing a few elastic fibers and, in its deeper portion, a thin layer of nonstriated muscle-cells.

The secreting portion is composed of a large number of tubules twisted and bent in a definite and typical manner, the *uriniferous tubules*. In each one of these tubules we distinguish the following segments: (1) *Bowman's capsule*, or the ampulla, surrounding a spheric plexus of capillaries, the *glomerulus*, which, with the capsule of Bowman, forms a *Malpighian corpuscle*;

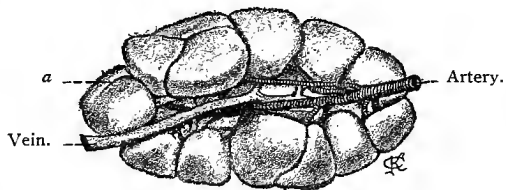


Fig. 243.—Kidney of new-born infant, showing a distinct separation into reniculi; natural size. At *a* is seen the consolidation of two adjacent reniculi.

(2) a *proximal convoluted portion*; (3) a **U-shaped** portion, consisting of straight *descending* and *ascending limbs* and the *loop of Henle*; (4) a *distal convoluted portion* or *intercalated portion*; and (5) an *arched collecting portion*; from the confluence of a number of these are formed the larger *straight collecting tubules*, which, in turn, finally unite to form the papillary ducts or tubules of Bellini, which pass through the renal papillæ and empty into the renal pelvis. Besides the uriniferous tubules the kidney contains a complicated vascular system, a small amount of connective tissue, etc.

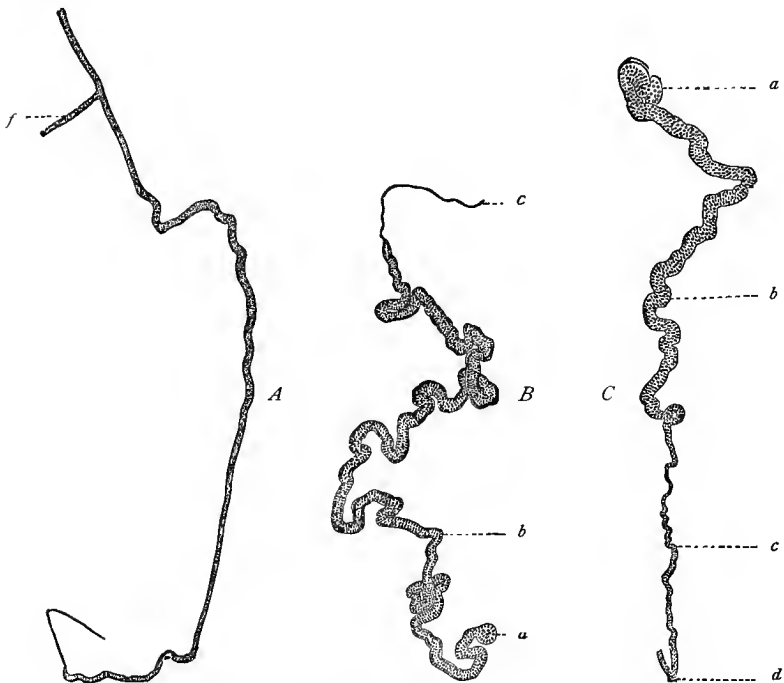

Fig. 244.—Isolated uriniferous tubules: *A* and *B*, from mouse; *C*, from turtle. In all three figures *a* represents the Malpighian corpuscle; *b*, the proximal convoluted tubule; *c*, the descending limb of Henle's loop; *d*, Henle's loop; *e*, the straight collecting tubule; *f*, the arched collecting tubule.

In a longitudinal median section the kidney is seen to be composed of two substances,—the one, the *medullary substance*, possessing relatively few blood capillaries and containing straight collecting tubules and the loops of Henle; the other, the *cortical substance*, richer in blood-vessels, and containing principally the Malpighian corpuscles and the proximal and distal convoluted tubules. In each renal lobe we find these two substances distributed as follows: The Malpighian pyramid consists entirely of medullary substance, which sends out a large number of processes, the *medul-*

*lary rays*, or *pyramids of Ferrein*, toward the surface of the kidney. The latter do not, however, quite reach the surface, but terminate at a certain distance below it; they are formed by collecting tubules which extend beyond the medullary substance. The entire remaining portion of the kidney is composed of cortical substance; between the medullary rays it forms the *cortical processes*, and at the periphery of the kidney, where the medullary rays are absent, the *cortical labyrinth*. Those portions of the cortical substance separating the Malpighian pyramids are known as the *columns of Bertini*, or *septa renis*.

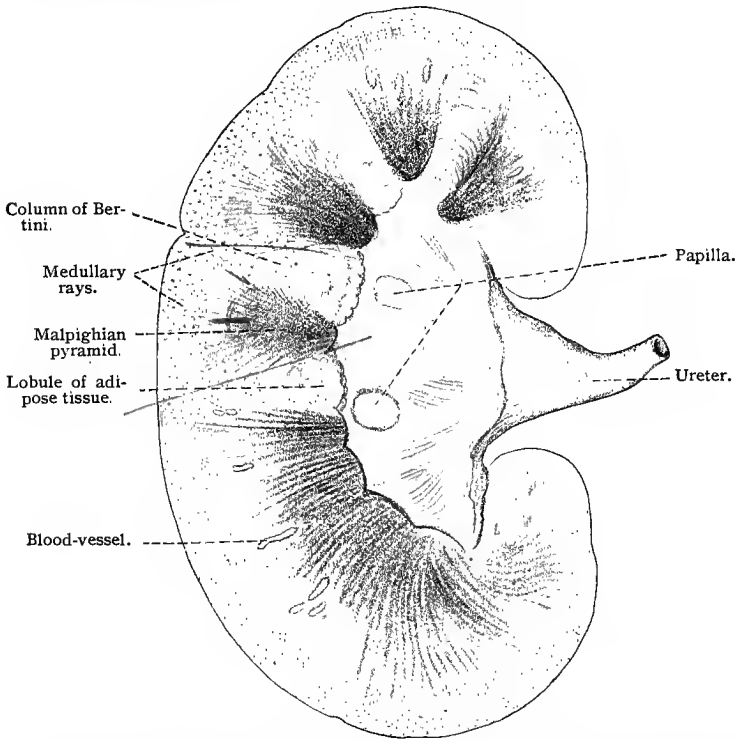


Fig. 245.—Median longitudinal section of adult human kidney; nine-tenths natural size. In the peripheral portion the limits between its renal lobes are no longer recognizable.

The various segments of the uriniferous tubule are characterized by their shape and size and by their epithelial lining.

The Malpighian corpuscle has a diameter of from  $120\ \mu$  to  $220\ \mu$ . The capsule surrounding the glomerulus consists of two layers, which are to be distinguished from each other when its relation to the glomerulus is taken into consideration. The capsule forms a double-walled membrane around the glomerulus; a condition which is easily understood by imagining an invagination of the

glomerulus into the hollow capsule. Between the inner wall covering the surface of the glomerulus (glomerular epithelium) and the outer wall (Bowman's capsule) there remains a cleft-like space which communicates with the lumen of the corresponding uriniferous tubule. In the adult the glomerular epithelium is very flat, with nuclei projecting slightly into the open space of the Malpighian corpuscle. The epithelium of the outer wall is somewhat higher, but still of the squamous type. The capsule of Bowman communicates with the proximal convoluted tubule by means of a short and narrow neck. Its epithelium passes over gradually into

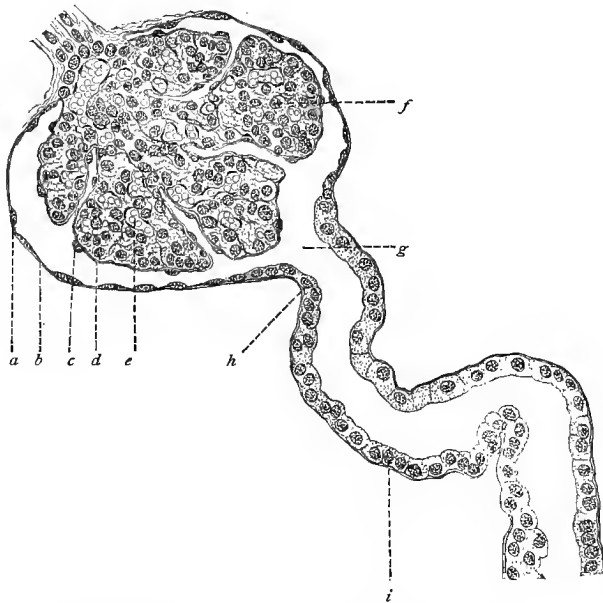


Fig. 246.—From section of cortical substance of human kidney;  $\times 240$ : *a*, Epithelium of Bowman's capsule; *b* and *d*, membrana propria; *c*, glomerular epithelium; *e*, blood-vessels; *f*, lobe of the glomerulus; *g*, commencement of uriniferous tubule; *h*, epithelium of the neck; *i*, epithelium of proximal convoluted tubule.

the cubical epithelium of the neck, which, in turn, merges into that of the proximal convoluted tubule.

The *proximal convoluted portion*, from  $40\ \mu$  to  $70\ \mu$  in diameter, is lined by short columnar epithelial cells, the protoplasm of which is striated and may be separated by means of certain reagents into fibers (R. Heidenhain, 83). In man the nuclei are situated in the upper portions of the cells, while the basal portions show the striation more distinctly. The cells, especially in their indifferent, non-striated regions, are so intimately connected that the cell limits are not always distinguishable. In well-fixed preparations the inner portions of the cells often show a narrow striated border,

often giving the appearance of short cilia. In the guinea-pig the basal regions of the lateral surfaces of the cells constituting the epithelium of the proximal convoluted portion present numerous projections which interlock and give to a surface view an irregular fringe-like outline. In cross-section the cells *appear* to be striated from their bases upward to the middle of the nucleus. Here, however, the striation is without doubt due to the outlines of the irregular ridges. (Fig. 248.) These structural relations have lately been confirmed in the case of the guinea-pig, and also found to hold true for man (Landauer). This striation is much coarser than that

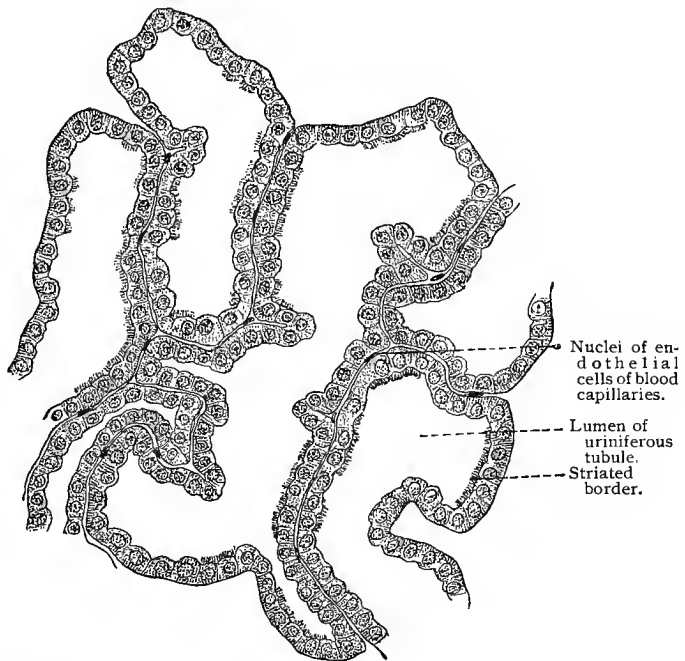


Fig. 247.—Section of proximal convoluted tubules from man;  $\times 580$ .

found by Heidenhain, but both are, under certain circumstances, seen together.

The *descending limb of Henle's loop*, from  $9\mu$  to  $15\mu$  in diameter, is narrow and possesses flattened epithelial cells, the centers of which, containing the nuclei, project into the lumen of the tubule. These central projections of the cells are not directly opposite those of the cells on the opposite wall, but alternate with the latter, thus giving to the lumen a zigzag outline corresponding to the length of the cell. The thick portion of the loop, for the most part represented by the ascending limb, from  $23\mu$  to  $28\mu$  in diameter, possesses a columnar epithelium similar to that of the proximal convoluted

portion. Here, however, the basal striation of the cells is not so distinct, the lumen is somewhat larger than that of the descending limb, and by treatment with certain reagents the epithelium may




Fig. 248.—Epithelium from proximal convoluted tubule of guinea-pig, with surface and lateral views (chrome-silver method);  $\times 590$ : *a, a*, The irregular interlacing projections.

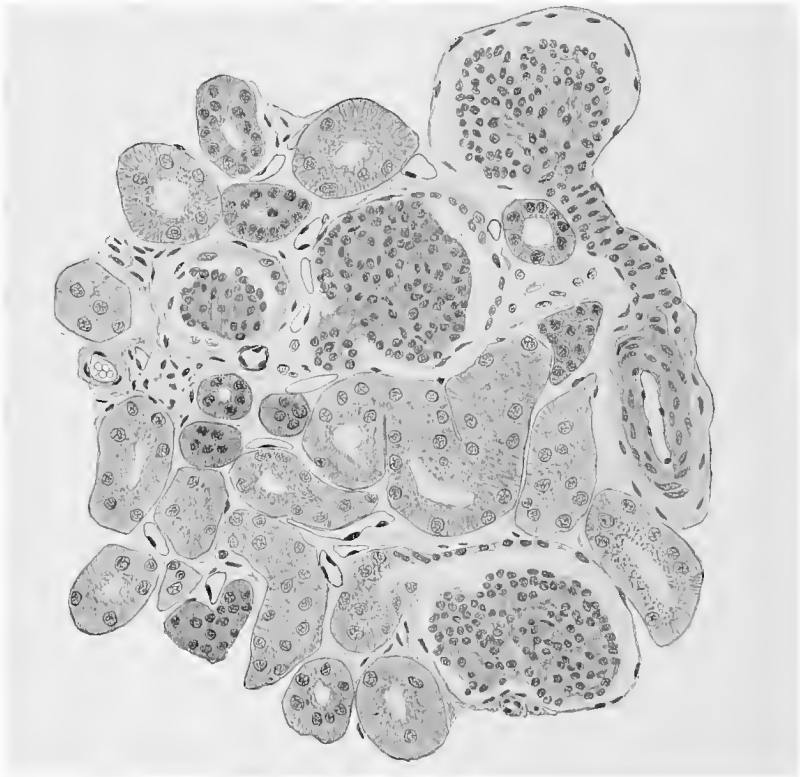


Fig. 249.—From cortical portion of longitudinal section of kidney of young child.

often be separated as a whole from the underlying basement membrane.

The *distal convoluted* or *intercalated portion*, from  $39\mu$  to  $45\mu$  in

diameter, is only slightly curved (2 to 4 convolutions). Its epithelium is relatively high, though not so high as that lining the proximal convoluted portion and not so distinctly striated. The cells are provided with large nuclei and their basal portions are joined by interlacing projections.

The next important segment is the short *arched collecting portion*, which has nearly cubical epithelial cells and a lumen somewhat wider than that of the intercalated tubule. The smaller straight collecting tubules have a low columnar epithelium with cells of somewhat irregular shape, the basal portions of which are provided with short, irregular, intertwining processes, which serve to hold the cells in

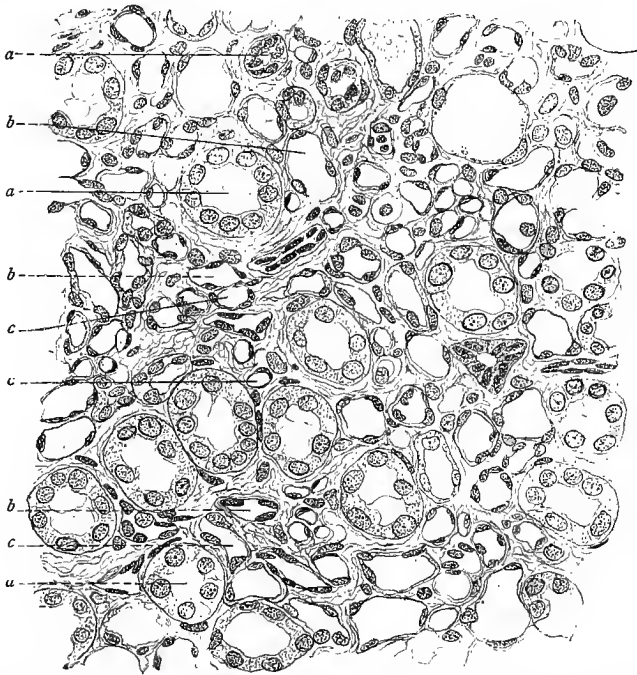


Fig. 250.—Section of medulla of human kidney;  $\times$  about 300: *a, a, a*, Ascending limb of Henle's loop; *b, b, b*, blood-vessels; *c, c, c*, descending limb of Henle's loop.

place. The diameter of the collecting tubules measures from  $45\ \mu$  to  $75\ \mu$ .

In the larger collecting tubules the epithelium is more regular and becomes higher as the tube widens. These tubules gradually unite within the Malpighian pyramid and the regions adjacent to the columns of Bertini to form about 20 papillary ducts from  $200\ \mu$  to  $300\ \mu$  in diameter. The latter have a high columnar epithelium, and empty into the pelvis of the kidney at the apex of the papilla, forming the *foramina papillaria*.

Besides the epithelium, the uriniferous tubules possess an ap-

parently structureless membrana propria, that of the collecting tubules being very thin. According to Rühlc (97), the membrana propria of the uriniferous tubules consists of fine circular and longitudinal fibers which are at no point connected with the cells, and which represent nothing more than a thickened and more regularly distributed layer of the interstitial reticular tissue. The basement membrane of the vascular loops in the glomeruli also appears to have a fibrous structure and presents numerous fine openings.

Between the Malpighian pyramids are found the columns of Bertin, presenting a structure similar to that of the cortex of the kidney, and extending to the hilum of the kidney.

Between the uriniferous tubules and surrounding the blood-vessels of the kidney there is found normally a small amount of connective tissue. Between the convoluted portions of the tubules this is present only in small quantity, a somewhat greater amount

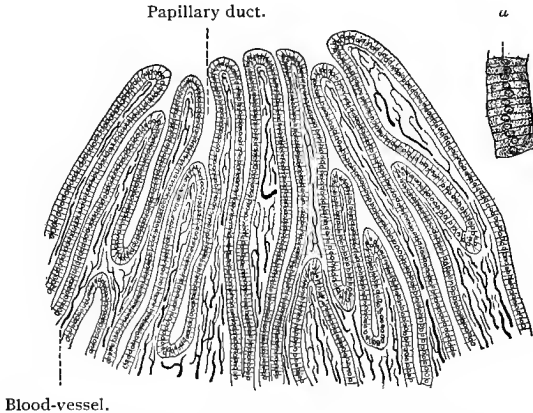


Fig. 251.—From longitudinal section through papilla of injected kidney;  $\times 40$ : *a*, Epithelium of collecting tubule under greater magnification.

being found in the neighborhood of the Malpighian corpuscles, in the boundary zone between the cortex and medulla and between the larger collecting tubules in the apices of the Malpighian pyramids.

From what has been said concerning the uriniferous tubule it must be evident that its course is a very tortuous one. Beginning with the Malpighian corpuscles, situated in the cortex between the medullary rays, the tubule winds from the cortex to the medulla and back again into the cortex, where it ends in a collecting tubule, which passes to the medulla to terminate at the apex of a Malpighian pyramid. The different portions of the tubules have the following positions in the kidney: In the cortex between the medullary rays are found the Malpighian corpuscles, the neck, the proximal and distal convoluted portions of the uriniferous tubule, and the

arched collecting tubules. The medullary rays are formed by the cortical portions of the straight collecting tubules and a portion of the ascending limbs of Henle's loops. The medulla is made up mainly of straight collecting tubules of various sizes and of the descending limbs and loops of Henle's loops, the latter being often found in the boundary zone between the cortex and medulla. (See Fig. 250.)

The **blood-vessels** of the kidney have a characteristic distribution, and are in the closest relationship to the uriniferous tubules.

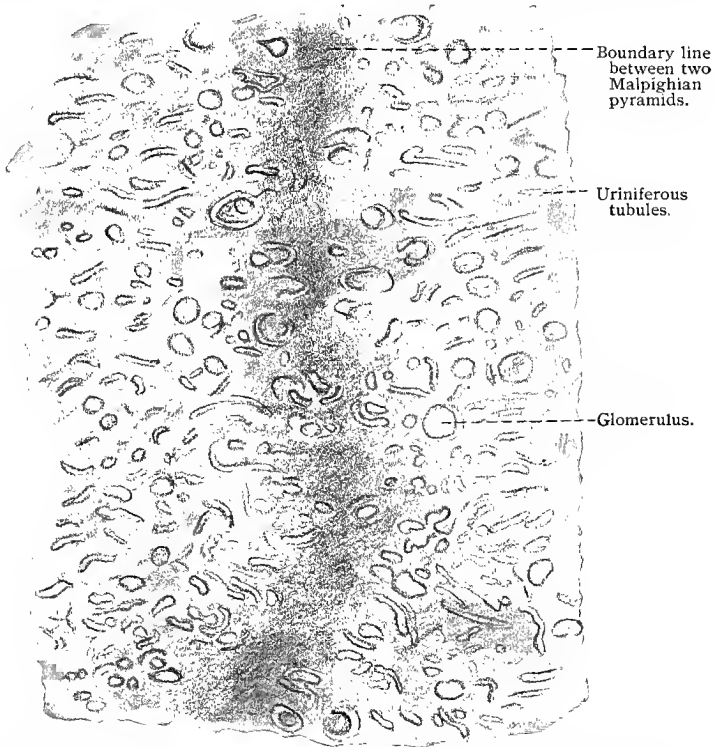


Fig. 252.—Section through junction of two lobules of kidney, showing their coalescence; from new-born infant.

The renal artery divides in the neighborhood of the hilum into two branches,—a dorsal and a ventral,—which again divide, the resulting trunks giving off lateral branches to the renal pelvis, supplying its mucous membrane and then breaking up into capillaries which extend as far as the “area cribrosa.” The venous capillaries of this region empty into veins which accompany the arteries. Besides these, other arteries originate from the principal branches, or from their immediate offshoots, and pass backward to supply the walls of the renal pelvis, the renal capsule, and the ureter. The main

trunks themselves penetrate at the hilum, and divide in the columns of Bertini to form arterial arches (*arteriæ arciformes*) which extend between the cortical and medullary substances. Numerous vessels, the *intralobular arteries*, originate from the *arteriæ arciformes* and penetrate into the cortical pyramids between the medullary rays. Here they give off numerous twigs, each of which ends in the glomerulus of a Malpighian corpuscle. These short lateral twigs are the *vasa afferentia*. Each glomerulus is formed by the breaking down of its afferent vessel, which, on entering the Malpighian corpuscle, divides into a number of branches, each in turn subdividing into a capillary net. From each of these nets the blood passes into a somewhat larger vessel constituting one of the branches of the efferent vessel which carries the blood away from the glomerulus. Since the afferent and efferent vessels lie in close proximity, the capillary nets connecting them are necessarily bent in the form of loops. The groups of capillaries in a glomerulus are separated from each other by a larger amount of connective tissue than separates the capillaries themselves, so that the glomerulus may be divided into lobules. In shape the glomerulus is spheric, and is covered by a thin layer of connective tissue over which lies the inner membrane of the capsule, the glomerular epithelium. On its exit from the glomerulus the *vas efferens* separates into a new system of capillaries, which gradually becomes venous in character. Thus, the capillaries which form the glomerulus, together with the *vas efferens*, are arterial, and may be included in the category of the so-called arterial *retia mirabilia*. Those capillaries formed by the *vas efferens* after its exit from the Malpighian corpuscle lie both in the medullary rays and in the cortical pyramids. The meshes of the capillary networks distributed throughout the medullary rays are considerably longer than those of the networks supplying the cortical pyramids and labyrinth, the latter being quadrate in shape. The glomeruli nearest the renal papillæ give off longer *vasa afferentia* which extend into the papillary region of the Malpighian pyramids (*arteriolæ rectæ spuriae*) and form there capillaries which ramify throughout the papillæ with oblong meshes.

Arterial *retia mirabilia* also occur in the course of the *vasa afferentia* between the intralobular arteries and the glomeruli, but nearer the latter. Each is formed by the breaking down of the small afferent vessels into from two to four smaller branches, which then reunite to pass on as a single vessel. In structure these *retia* differ greatly from the glomeruli in that here the resulting twigs are not capillaries and have nothing to do with the secretion of urine (Golubew).

From the *vasa afferentia* arterial twigs are occasionally given off, which break down into capillaries within the cortical substance. Other arteries originate from the lower portion of the intralobular arteries or from the arciform arteries themselves and enter the medullary substance, where they form capillaries. These

vessels constitute the so-called "arteriolæ rectæ veræ." Their capillary system is in direct communication with the capillaries of the vasa afferentia and "vasa recta spuria." The intralobular arteries are not entirely exhausted in supplying the vasa afferentia which pass to the glomeruli. A few extend to the surface of the kidney and penetrate into the renal capsule, where they terminate in capillaries which communicate with those of the recurrent, suprarenal, and phrenic arteries, etc. Smaller branches

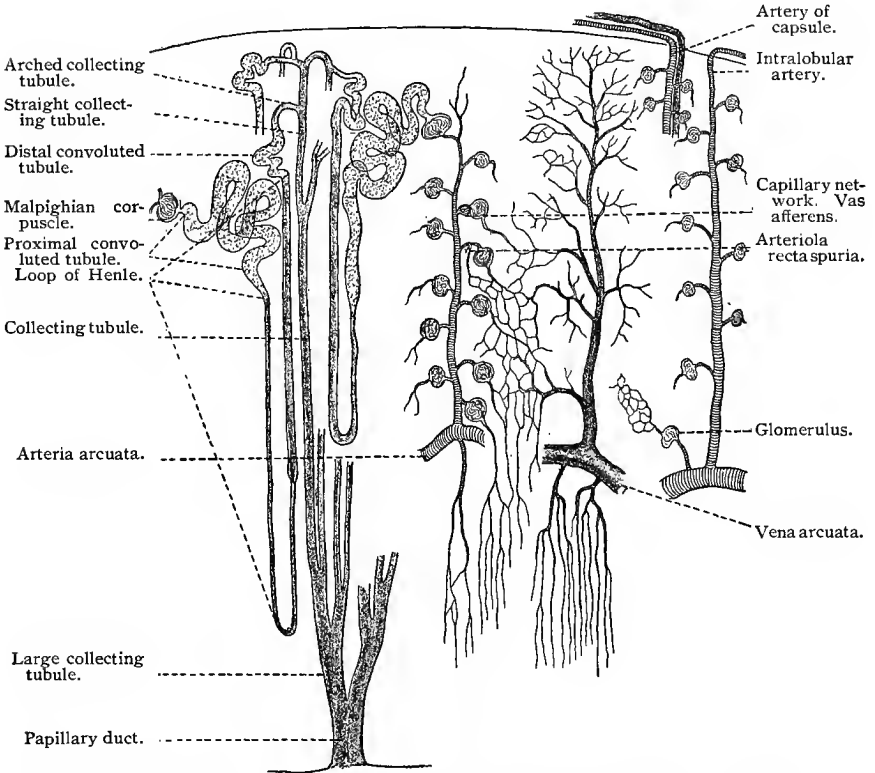


Fig. 253.—Diagrammatic scheme of uriniferous tubules and blood-vessels of kidney. Drawn in part from the descriptions of Golubew.

from these latter vessels may penetrate the cortex and form glomeruli of their own in the renal parenchyma (arteriæ capsulares glomeruliferæ). These relations, first described by Golubew, are of importance not only in the establishment of a collateral circulation, but also as a partial functional substitute in case of injury to the renal arteries. The same author also confirms the statements of Hoyer (77) and Geberg, that between the arteries and veins of the kidney, in the cortical substance, in the columns of Bertin, and

at the bases of the Malpighian pyramids, etc., direct anastomoses exist by means of precapillary twigs.

From the capillaries the venous blood is gathered into small veins which pass out from the region of the medullary rays and cortical pyramids and unite to form the "intralobular veins." These have an arrangement similar to that of the corresponding arteries. The venous blood of the labyrinthian capillaries also flows into the intralobular veins, and as a result a peculiar arrangement of these vessels is seen at the surface of the kidney where the capillaries pass radially toward the terminal branches of the intralobular veins and form the stellate figures known as the *venæ stellatæ*. This system is also connected with those venous capillaries of the capsule

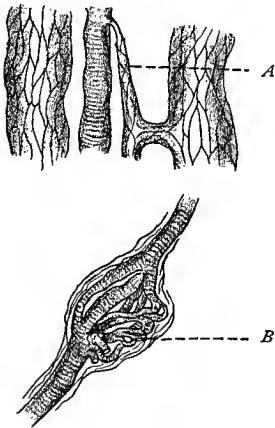


Fig. 254.—*A*, Direct anastomosis between an artery and vein in a column of Bertin of child; *B*, bipolar rete mirabile inserted in the course of an arterial twig. Dog's kidney (after Golubew).

which do not empty into the veins accompanying the arteries of the capsule. The capillary system of the Malpighian pyramids unites to form veins, the "venulæ rectæ," which empty into the venous arches (*venæ arciformes*) which lie parallel with and adjacent to the corresponding arteries. The larger veins are found side by side with the arteries and pass out at the hilum of the organ.

The lymph-vessels of the kidneys need to be investigated further. Lymph clefts have been observed in the cortex between the convoluted tubules; these have been traced into larger vessels found in the capsule.

The kidneys receive their innervation through nonmedullated and medullated nerve-fibers. The former accompany the arteries and may be traced along these to the Malpighian corpuscles. From the plexuses surrounding the vessels small branches are given off, which end on the muscle-cells of the media. According to Berkley, small nerve-fibrils may be traced to the uriniferous tubules, which pierce the membrana propria and end on the epithelial cells. Dogiel has shown that medullated (sensory) nerve-fibers terminate in the adventitia of the arteries of the capsule.

The most important investigations into the secretory processes of the uriniferous tubules are those of R. Heidenhain (83) who used indigo-carmin in his researches. If a saturated aqueous solution of indigo-carmin be injected into the blood-vessels of a rabbit, the elimination of the substance will be found to take place through the kidneys as well as by means of the other excretions. Microscopic examination of such a kidney reveals the fact that the proximal convoluted tubules and ascending limbs of the loops of

Henle are alone concerned in the elimination of the substance, while apparently water alone is filtered through the remaining segments of the uriniferous tubules. Among others, Disse has recently taken up the subject of cellular secretion in the uriniferous tubules. According to him, we may distinguish in the convoluted tubules (1) those with a wide lumen, having low cells apparently with no cell limits and no distinct basilar zone, but with peculiar structures which may be likened to cuticulæ, so called, or a striated border (Tornier) (Fig. 247); (2) tubules with a narrow lumen and wedge-shaped epithelial cells, with indistinct cell limits and diffusely granular protoplasm; (3) tubules with an extremely narrow lumen and high epithelial cells with differentiated protoplasm, the basal portion of which is dark and striated, the upper clear and containing the nucleus. These results are not, however, confirmed by the painstaking researches of Sauer. This author finds that the secretory portions of the uriniferous tubules (convoluted portions of the tubules and part of the loops of Henle) always have the same unchanged epithelium, but that, during secretion, the lumina of the tubules are subject to great variation; in tubules with scarcely recognizable lumina the epithelial elements are high and narrow; in those with wide lumina, low and broad. In the former the striation of Heidenhain is naturally fine; in the latter, somewhat coarser. The peculiar terminations of Tornier are found by Sauer during all phases of secretion. According to this view, then, neither the striation of Heidenhain nor the terminations of Tornier are temporary appearances due to a particular phase of secretion, but represent permanent structural peculiarities of the cells in certain definite portions of the uriniferous tubules. The volumetric changes in the uriniferous tubules also probably influence the form and number of the indentations in the epithelial cells described on page 291.

The permanent kidney is developed as early as the fifth week of embryonic life. The renal anlagen, from which the epithelium of the ureter, renal pelvis, and uriniferous tubules is formed, originate from the median portion of the posterior wall of the Wolffian duct. These buds grow with their blind ends extending anteriorly, and are soon surrounded by cellular areas, the blastema of the kidneys. After the renal bud has become differentiated into a narrow tube (the ureter) and a wider central cavity (the renal pelvis) hollow epithelial buds are developed from the latter. These extend radially toward the surface of the renal anlagen, where they undergo a T-shaped division. These latter are the first traces of the papillary ducts and collecting tubules. The cup-shaped capsules are formed by the invagination of the ends of the tubules by the glomeruli which originate separately and in this way become connected with the uriniferous tubules. The remaining portions of the adult uriniferous tubules are gradually formed from the tubes connecting the glomeruli with the collecting tubules.

## 2. THE PELVIS OF THE KIDNEY, URETER, AND BLADDER.

The renal pelvis, ureter, and urinary bladder are lined by stratified transitional epithelium. Its basal cells are nearly cubical; these support from two to five rows of cells of varying shape. They may be spindle-shaped, irregularly polygonal, conical, or sharply angular, and provided with processes. Their variation in form is probably due to mutual pressure. The superficial cells are large

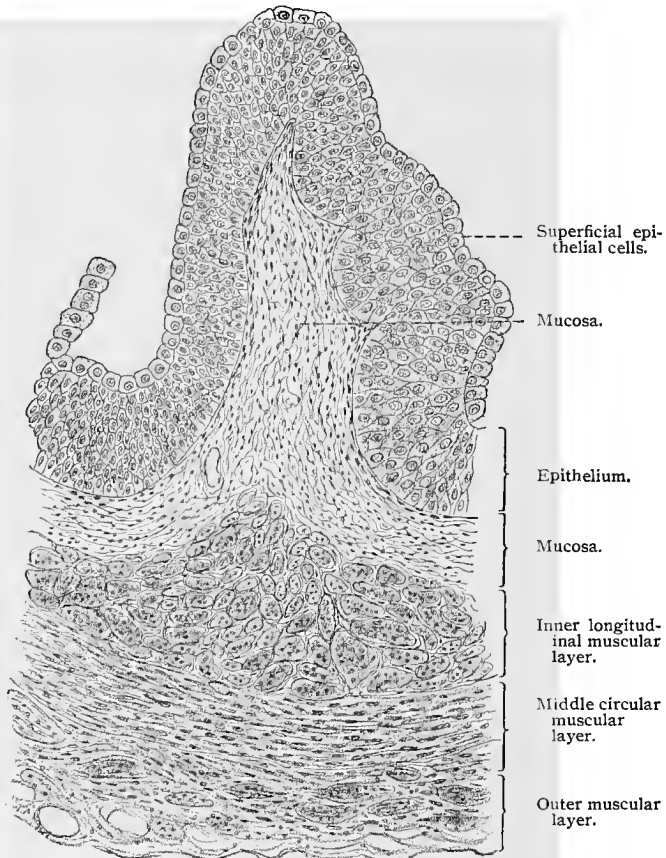


Fig. 255.—Section of lower part of human ureter;  $\times 140$ .

and cylindric, a condition characteristic of the ureter and bladder. Their free ends and lateral surfaces are smooth, but their bases present indentations and projections due to the irregular outlines of the underlying cells. The superficial cells often possess two or more nuclei.

The mucosa often contains diffuse lymphoid tissue, which is more highly developed in the region of the renal pelvis. A few

mucous glands are also met with in the pelvis and in the upper portion of the ureter. The ureter possesses two layers of nonstriated muscle-fibers—the inner longitudinal, the outer circular. From the middle of the ureter downward a third external muscular layer is found with nearly longitudinal fibers.

The urinary bladder has no glands, and its musculature apparently consists of a feltwork of nonstriated muscle bundles, a condition particularly well seen in sections of the dilated organ. But even here three indistinct muscle layers may be distinguished, the outer and inner layers being longitudinal and the middle circular. A remarkable peculiarity of these structures is the extreme elasticity of their epithelium, the cells flattening or retaining their natural shape according to the amount of fluid in the cavities which they line (compare London, Kann).

The nerve supply of the bladder has been studied by Retzius, Huber, and Grünstein in the frog and a number of the smaller mammalia. Numerous sympathetic ganglia are observed, situated outside of the muscular coat, at the base and sides of the bladder. The neuraxes of the sympathetic neurones of these ganglia are grouped into smaller or larger bundles which interlace and form plexuses surrounding the bundles of nonstriated muscle-cells. From these plexuses nerve-fibers are given off, which penetrate the muscle bundles and end on the muscle-cells. The cell-bodies of the sympathetic neurones are surrounded by the telodendria of small medullated fibers, which terminate in the ganglia. Passing through the ganglia large medullated fibers (sensory nerves) may be observed which pass through the muscular coat, branch repeatedly in the mucosa, and lose their medullary sheaths on approaching the epithelium in which they end in numerous telodendria, the small branches of which terminate between the epithelial cells.

The ureters are surrounded by a nerve plexus containing non-medullated and medullated nerve-fibers. The former end on cells of the muscular layers; the latter pass through the muscular layer, and on reaching the mucosa branch a number of times before losing their medullary sheaths. The nonmedullated terminal branches form telodendria, the terminal fibers of which have been traced between the cells of the lining epithelium (Huber).

## B. THE SUPRARENAL GLANDS.

The suprarenal gland is surrounded by a fibrous-tissue capsule containing nonstriated muscle-cells, blood- and lymph-vessels, nerves, and sympathetic ganglia. The glandular structure is divided into a cortical and a medullary portion. In the former are distinguished three layers, according to the arrangement, shape, and structure of its cells—an outer glomerular zone, a middle broad fascicular zone, and an inner reticular zone. According to Flint, who

worked in Mall's laboratory, and whose account will here be followed, the framework of the gland is made up of reticulum. In the glomerular zone this reticulum is arranged in the form of septa, derived from the capsule, which divide this zone into more or less regular spaces of oval or oblong shape. In the fascicular zone the reticulum is arranged in processes and fibrils running at right angles to the capsule. In the reticular zone the fibrils form a dense network, while in the medulla the reticular fibrils are arranged in processes and septa which outline numerous spaces.

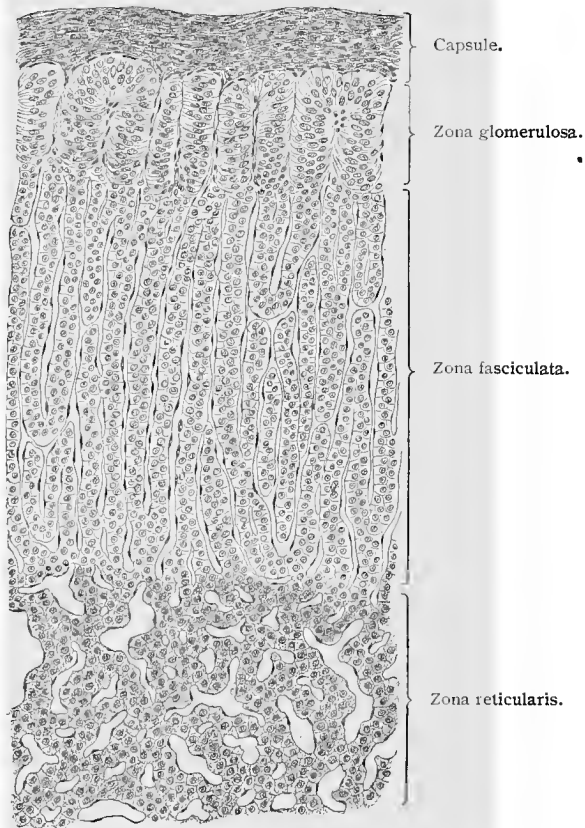


Fig. 256.—Section of suprarenal cortex of dog ;  $\times 120$ .

The gland-cells of the glomerular zone are arranged in coiled columns of cells found in the compartments formed by the septa of reticulum above mentioned. The cells composing these columns are irregularly columnar, with granular protoplasm and deeply staining nuclei. In the fascicular zone the cells are arranged in regular columns, consisting usually of two rows of cells, and situated between the reticular processes, which run at right angles to the cap-

sule. The cells of this zone are polyhedral in shape, with granular protoplasm often containing fat droplets and with nuclei containing little chromatin. Similar cells are found in the reticular zone, but here they are found in small groups situated in the meshes of the reticulum. The cells of the medullary substance are less granular and smaller in size than those of the cortex, and are grouped in irregular, round, or oval masses bounded by the septa of reticulum. These cells stain a deep brown with chromic acid and its

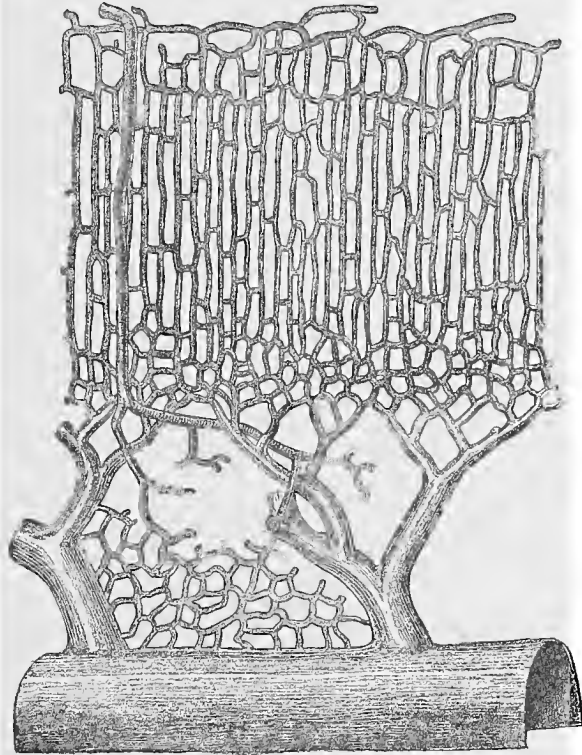


Fig. 257.—Arrangement of the intrinsic blood-vessels in the cortex and medulla of the dog's adrenal (Fig. 17, Plate V, of Flint's article in "Contributions to the Science of Medicine," dedicated to Professor Welch, 1900).

salts, and the color can not be washed out with water—a peculiarity which shows itself even during the development of these elements, and which is possessed by few other types of cells. Numerous ganglion cells, isolated and in groups, and many nerve-fibers occur in this portion of the organ.

The blood-vessels of the suprarenal glands are of special interest, since it has been shown that the secretion of the glands passes directly or indirectly into the vessels. The following statements

we take from Flint: The blood-vessels, derived from various sources, form in the dog a poorly developed plexus, situated in the capsule. From this plexus three sets of vessels are derived, which are distributed respectively in the capsule, the cortex, and the medulla of the gland. The vessels of the capsule divide into capillaries, which empty into a venous plexus situated in the deeper portion of the capsule. The cortical arteries divide into capillaries which form networks, the meshes of which correspond to the arrangement of the cells in the different parts of the cortex, encircling the coiled columns of cells in the glomerular zone, while in the fascicular zone the capillaries are parallel with occasional anastomoses. These capillaries form a fine-meshed plexus in the reticular zone and unite in the peripheral portion of the medulla to form small anastomosing veins, from which the larger veins are derived. The latter do not anastomose, and are therefore terminal veins. The arteries of the medulla pass through the cortex without giving off any branches until the medulla is reached, where they break up into a capillary network surrounding the cell masses situated here. The blood from this plexus may be collected into veins of the medulla which empty into the terminal vein or some of its larger branches, or may flow directly into branches of the venous tree. The endothelial walls of the capillaries rest directly on the specific gland cells, with the intervention here and there of a few reticular fibrils. According to Pfaundler, the walls of the blood-vessels of the entire suprarenal body consist solely of the tunica intima.

The **nerves** of the suprarenal glands have been studied recently by Fusari and Dogiel (94); the description given by the latter will here be followed. Numerous nerve-fibers, both nonmedullated and medullated, arranged in the form of a plexus containing sympathetic ganglia, are found in the capsule. From this plexus numerous small bundles and varicose fibers enter the cortex, where they form plexuses surrounding the columns of cells or groups of cells found in the three zones of the cortex and about the vessels and capillaries of the cortex. The nerve-fibers of these plexuses are on the outside of the columns and cell groups and do not give off branches which pass between the cells. The nerve supply of the medullary substance is very rich, and is derived mainly from large nerve bundles which pass from the plexus in the capsule to the medulla, where they divide and form dense plexuses which surround the groups of gland-cells and veins; from these plexuses fine varicose fibers pass between the gland-cells, forming intercellular plexuses. In the medulla there are found in many animals large numbers of sympathetic cells, some isolated, others grouped to form small ganglia. Pericellular networks surround the cell-bodies of certain of these sympathetic cells. (For further information concerning the suprarenal glands consult Gottschau, Weldon, Hans Rabl, C. K. Hoffmann (92), Pfaundler, Flint, and Dogiel.)

## TECHNIC.

**270.** The arrangement of the cortical and medullary portions of the kidney is best seen in sections of the kidney of small mammalia, cut in the proper direction, and, if possible, embracing the whole organ. If, on the other hand, the finer epithelial structures are to be examined, small pieces are first fixed in osmic acid mixtures or in corrosive sublimate.

**271.** Impregnation with silver nitrate (method of Golgi or Cox) reveals some points as to the relation of the cells of the uriniferous tubules to each other.

**272.** In order to isolate the tubules, thin strips of kidney tissue are treated for from fifteen to twenty hours with pure hydrochloric acid having a specific gravity of 1.12 (for this purpose kidney tissue is used taken from an animal killed twenty-four hours previously). It is then washed, teased, and examined in glycerin (Schweiger-Seidel). Fuming nitric acid (40%), applied for a few hours to small pieces of tissue, occasionally isolates the uriniferous tubules very extensively. The further treatment is then the same as after hydrochloric acid. A 35% potassium hydrate solution may also be employed. The isolated pieces are, however, not easily preserved permanently.

**273.** The epithelium of the uriniferous tubules may be isolated either in  $\frac{1}{3}$  alcohol (*vid.* T. 128) or, according to R. Heidenhain (83), in a 5% aqueous solution of neutral ammonium chromate. The latter method shows clearly the striation of the epithelium.

**274.** The autophysiologic injection with indigo-carmin (Chrzon-szczewsky *vid.* T. 245), applied as in the case of the liver, fills the uriniferous tubules, which may then be further examined in sections.

**275.** The blood-vessels are examined in injected specimens (injection of the kidney is easily accomplished). In larger animals the injection is made into the renal artery, while in smaller ones the whole posterior half of the body is injected through the abdominal aorta.

**276.** The ureter and bladder are cut open, fixed, and then sectioned. In this way the organs are shown in a collapsed condition, in which the arrangement of the epithelium is totally different from that found in the distended organs. In order to observe them in the latter condition the fixing agent is injected into the ureter or bladder, when, after proper ligation, they are placed in the same fixing agent.

**277.** The usual fixing fluids are employed in the demonstration of the suprarenal capsule; but mixtures containing chromic acid, whether Flemming's fluid, chromic acid, or its salts, are of special importance in the examination of the organ, since the medullary substance of the suprarenal capsule stains a specific brown when treated by these mixtures (a condition only reduplicated in certain cells of the hypophysis). This brown staining also occurs when the cortical and medullary portions are entirely separated, as is the case in certain animals and during the development of the suprarenal capsule. The fat found in the cells of the suprarenal cortex is not identical with that of the rest of the body, as it may be dissolved by chloroform and oil of bergamot out of tissue fixed with osmic acid (Hans Rabl).

## C. THE FEMALE GENITAL ORGANS.

### 1. THE OVUM.

The product of the ovaries is the matured "ovum," or egg, having a diameter of from 0.22 to 0.32 mm. It forms a single cell with a thick membrane, from  $7\mu$  to  $11\mu$  in thickness, known as the zona pellucida. The ovum consists of a cell-body known as the yolk or vitellus, and a nucleus, from  $30\mu$  to  $40\mu$  in diameter, termed the germinal vesicle. The vitellus consists of two substances—a protoplasmic network, with a somewhat denser arrangement at the periphery of the cell and in the neighborhood of the germinal vesicle, and of small, highly refractive, and mostly oval bodies imbedded between the meshes of the protoplasm—the yolk globules. These latter, as a rule, are merely browned on being treated with osmic acid, although occasionally a true fatty reaction may be obtained. The germinal vesicle is surrounded by a distinct membrane having a double contour. In its interior we find a scanty lining framework containing very little chromatin, and one or two relatively large false nucleoli, or germinal spots, from  $7\mu$  to  $10\mu$  in diameter, due to a nodal thickening of the chromatin. In the latter a further very distinct differentiation is sometimes seen in the shape of a small body (vacuole?) of doubtful origin, which has been called Schrön's granule. The germinal vesicle and spot were formerly known as "Purkinje's vesicle" and "Wagner's spot," respectively, from their discoverers.

### 2. THE OVARY.

The ovaries are almost entirely covered by peritoneum. The mesothelial cells of the latter, however, undergo here a differentiation, to form the germinal epithelium. At the hilum the peritoneal covering is absent, and it is here that the connective-tissue elements of the ovarian ligament penetrate into the organ to form its connective-tissue framework, the so-called *stroma* of the ovary. At an early period in the development of the ovaries, the germinal epithelium begins a process of invagination into the stroma of the ovary, so that at the periphery of the organ a zone is soon formed which consists of both connective tissue and epithelial (mesothelial) elements. This zone is called the *cortex*, or parenchymatous zone. That portion of the organ in the neighborhood of the hilum (aside from the rudimentary structure known as the epoophoron) consists of connective tissue containing numerous elastic fibers and unstriped muscle-cells, and is known as the *medullary substance*, or vascular zone. This connective tissue penetrates here and there into the cortex, separates the epithelial elements of the latter from each other, and is in direct continuation with a stratum immediately beneath the germinal epithelium, called the tunica albuginea. This latter layer of connective tissue is very distinct in the adult ovary, although its

structure and thickness vary to a considerable extent. In young ovaries it is irregular, but shows in its highest development three layers distinguishable from each other by the different direction of the fibers. In the medullary substance the connective-tissue fibers are long, in the cortex short, and in the zone containing the follicles (see below) are mingled with numerous connective-tissue cells. Nonstriated muscle-fibers occur exclusively in the medulla. Here they are gathered in bundles which accompany the blood-vessels, and may even form sheaths around the latter. They are especially prominent in mammalia.

The *germinal epithelium* is distinguished from that of the remaining peritoneum by the greater height of its cells, which are

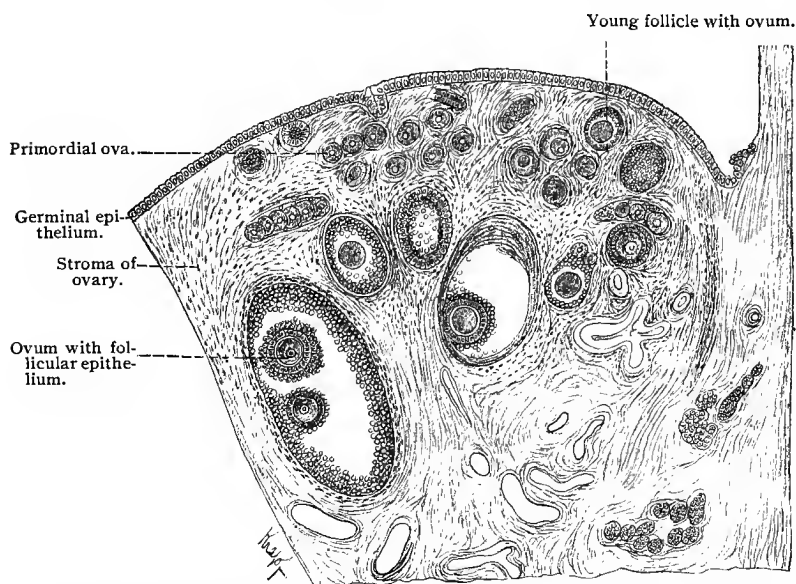


Fig. 258.—Section from ovary of adult dog. At the right the stellate figure represents a collapsed follicle with its contents. Below and at the right are seen the tubules of the parovarium (copied from Waldeyer).

cubical or even cylindric in shape. At an early period in the development of the ovaries this epithelium pushes into the underlying embryonic connective tissue in solid projections, to form the *primary egg tubes of Pflüger*, the cells of which very soon begin to show differentiation. Some retain their original characteristics and shape, while others increase in size, become rounded, and develop into the young ova. Those retaining their indifferent type become the follicular cells surrounding the egg. This differentiation into ova and follicular elements may even occur in the germinal epithelium itself, in which case the larger round cells are known as the *primitive* or *primordial ova*. In the further development of the ovarian cortex

the primitive egg tubes are penetrated throughout by connective tissue, so that each egg tube is separated into a number of irregular divisions. In this way a number of distinct epithelial nests are formed, which lose their continuity with the germinal epithelium and finally lie imbedded in the connective tissue. According to the shape and other characteristics of these epithelial nests, we may distinguish several different groups: (1) The primitive egg tubes

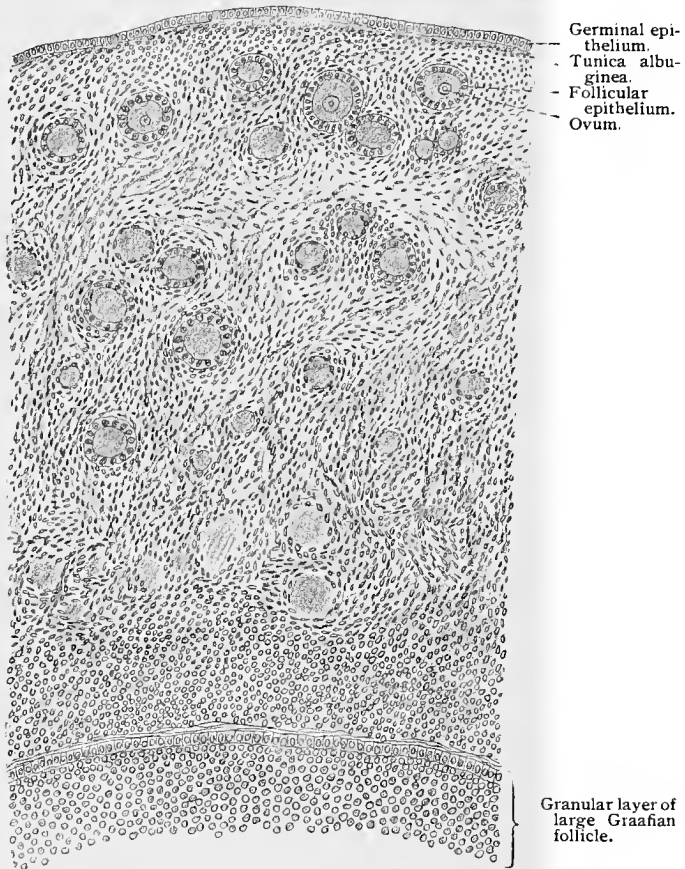


Fig. 259.—From ovary of young girl;  $\times 190$ .

of Pflüger; (2) the typical primitive follicles—*i. e.*, those which contain only a single egg-cell (present in the twenty-eighth week of fetal life); (3) the atypic follicles—*i. e.*, those containing from two to three egg-cells; (4) the so-called nests of follicles, in which a large number of follicles possess only a single connective-tissue envelope; (5) follicles of the last-named type which may assume the form of an elongated tube, and which are then known as the con-

stricted tubes of Pflüger. The fourth, fifth, and possibly the third types are further divided by connective-tissue septa, until they finally form distinct and typical follicles (Schottländer, 91, 93).

In the adult ovary true egg tubes are no longer developed. Isolated invaginations of the germinal epithelium sometimes occur, but apparently lead merely to the formation of epithelial cysts (Schottländer). The theories as to when the formation of new epithelial nests or follicles ceases are, however, very conflicting, some authors believing that cessation takes place at birth, others that it continues into childhood and even into middle age.

The typical primitive follicle consists of a relatively large egg-cell surrounded by a single layer of smaller cubical or cylindrical follicular cells. The growth of the follicle takes place by means of mitotic division in the follicular cells and increase in size of the ovum. The egg-cell is soon surrounded by several layers of cells, and gradually assumes an eccentric position in the cell complex. At a certain distance from the ovum and nearly in the center of the follicle one or more cavities form in the follicular epithelium. These become confluent, and the resulting space is filled by a fluid derived, on the one hand, from a process of secretion and, on the other hand, from the destruction of some of the follicular cells. The cavity is called the antrum of the follicle, and such a follicle has received the name of *Graafian follicle*. Its diameter varies from 0.5 to 6 mm. The follicle increases in size through cell-proliferation, the cavity increasing and gradually inclosing the egg together with the follicular cells immediately surrounding it, although the latter always remain connected with the wall of the vesicle at some point. The egg now lies imbedded in a cell-mass, the *discus proligerus*, which is composed of follicular epithelium, and projects into the follicular cavity. The follicular epithelium forming the wall of the cavity is known as the *stratum granulosum*, the cavity as the *antrum*, and the fluid which it contains as the *liquor folliculi*. Those follicular cells which immediately surround and rest upon the ovum are somewhat higher than the rest and constitute the egg epithelium, or *corona radiata*.

During the growth of the follicle the connective tissue surrounding it becomes differentiated into a special envelope, called the *theca folliculi*. In it two layers may be distinguished—the outer, the *tunica externa*, consisting of fibrous connective tissue, is continuous with the inner, or *tunica interna*, rich in blood-vessels and cellular elements. The follicle gradually extends to the surface of the ovary, at which point it finally bursts (see below), allowing the ovum to escape into the body cavity and thus into the oviduct.

During the growth and development of the ovarian follicles the ova undergo certain changes of size and structure which may receive further consideration. These have been described for the human ovary by Nagel (96), whose account will here be followed. The

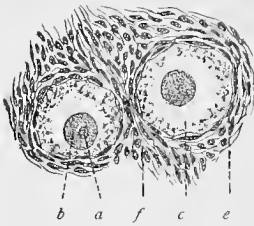


Fig. 260.

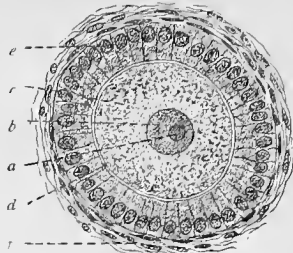


Fig. 261.

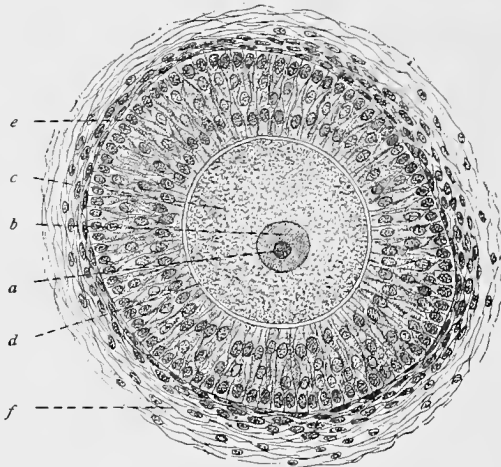


Fig. 262.

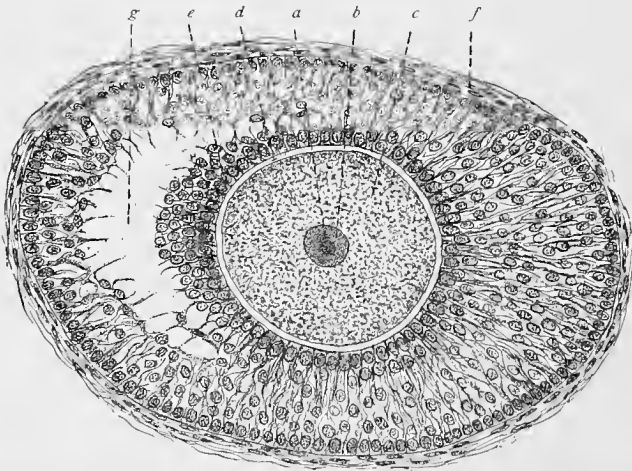


Fig. 263.

Figs. 260, 261, 262, and 263. — From sections of cat's ovary, showing ova and follicles in different stages of development;  $\times 225$ : *a, a, a, a*, Germinal spots; *b, b, b, b*, germinal vesicles; *c, c, c, c*, ova; *d, d, d*, zonæ pellucidæ; *e, e, e, e*, corona radiata; *f, f, f, f*, thecæ folliculorum; *g*, beginning of formation of the cavity of the follicle (compare Fig. 266).

ova of the primitive or primordial follicles attain a size (in fresh tissue teased in normal salt solution) varying from  $48\ \mu$  to  $69\ \mu$ . They possess a nucleus varying in size from  $20\ \mu$  to  $32\ \mu$ , presenting a doubly contoured nuclear membrane, and containing a distinct chromatin network with a nucleolus and several accessory nucleoli. The protoplasm shows a distinct spongioplastic network containing a clear hyaloplasm. The primitive ova, until they undergo further development, retain this size and structure, irrespective of the age of the individual. They are numerous in embryonic life and early childhood, always found during the ovulation period, but not observed in the ovaries of the aged. Changes in the size and structure of the ova accompany the proliferation of the follicular cells in the growing follicles. As soon as the follicular cells of a primitive follicle proliferate, as above described, the ovum of the follicle increases in size until it has attained the size of a fully developed ovum. The zona pellucida now makes its appearance, and after this has reached a certain thickness, yolk granules (deutoplasmic granules) develop in the protoplasm of the ovum. In a fully developed Graafian follicle the ovum presents an outer clearer protoplasmic zone and an inner fine granular zone containing yolk granules; in the former lies the germinal vesicle. Between the protoplasm of the ovum and the zona pellucida is found a narrow space known as the perivitelline space. The germinal vesicle (nucleus), which is usually of spheric shape, possesses a doubly contoured membrane and a large germinal spot (nucleolus), which shows ameboid movements.

The origin of the zona pellucida has not as yet been fully determined. It probably represents a product of the egg epithelium, and may be regarded in general as a cuticular formation of these cells. At all events it contains numerous small canals or pores into which the processes of the cells composing the corona radiata extend. These processes are to be regarded as intercellular bridges (Retzius, 90); and, according to Palladino, they occur not only between the ovum and the corona radiata, but also between the follicular cells themselves. In the ripe human ovum the pores are apparently absent (Nagel), and it is very probable that they have to do with the passage of nourishment to the growing egg. Retzius believes that the zona pellucida is derived from the processes of the cells composing the corona radiata, which at first interlace and form a network around the ovum. Later, the matrix of the membrane is deposited in the meshes of the network, very probably by the egg itself.

Further developmental changes are, however, necessary before a fully developed ovum (ripe ovum) may be fertilized. These are grouped under the head of maturation of the ovum. They have in part been described in a former section (p. 65), but may receive further consideration at this time. During maturation the chromosomes are reduced in number, so that the matured ovum presents

only half the number found in a somatic cell of the same animal. The manner in which this reduction takes place has been described for many invertebrates and vertebrates, and in all ova studied with reference to this point essentially the same phenomena have been observed. In this account we shall follow the process as it occurs in the Copepoda (Rückert, 94).

During the period of growth the cells composing the last generation of oogonia (primitive ova) increase in size, and are then

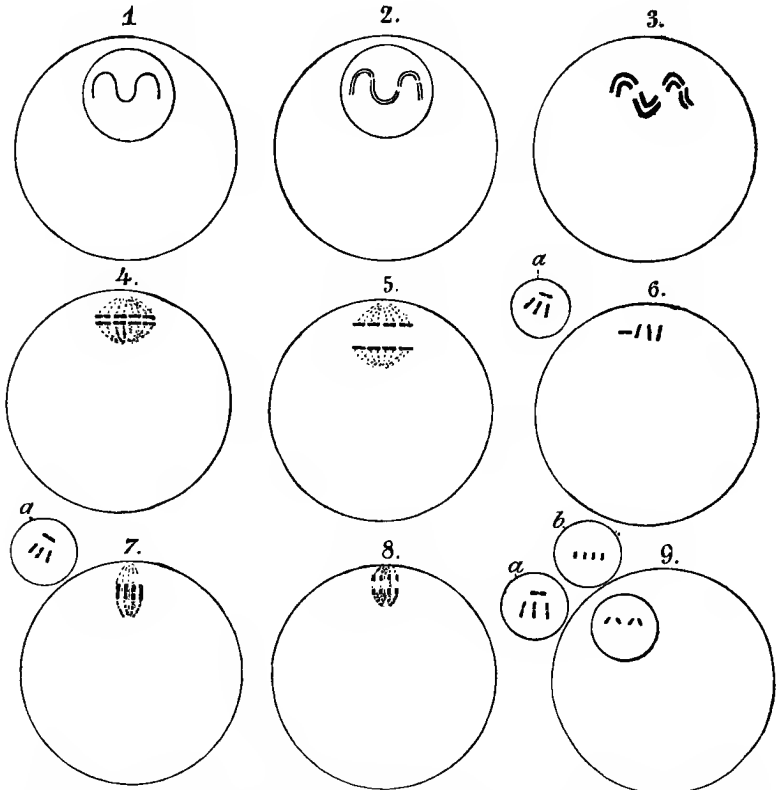


Fig. 264.—Schematic representation of the behavior of the chromatin during the maturation of the ovum (from Rückert, 94). Instead of 12 chromosomes we have drawn, for the sake of simplicity, only four: *a, a, a*, First, and (*b*) second polar body.

known as “oocytes” (the ripe ova). These then undergo mitotic division, and in each a spirem is formed which divides into 12 chromosomes, and not into 24 as in the case of the somatic cells. These 12 chromosomes split longitudinally, so that the germinal vesicle is seen to contain 12 pairs of chromosomes, or daughter loops. By this process the oogonia have become egg mother cells (O. Hertwig, 90) or oocytes of the first order. The loops now begin to shorten and each soon divides crosswise into two equal

rods, thus giving rise to 12 groups of 4 chromosomes, or 12 tetrads. The mother cell now divides into 2 unequal parts, the process consisting in a distribution of the rods composing the tetrads in such a way that the pairs of rods derived from one set of daughter loops pass to the one daughter cell, and those derived from the other set to the second daughter cell. In this manner are formed the large egg daughter cells (O. Hertwig) or oocytes of the second order, and a smaller cell, the first polar body. From this it is seen that the daughter cell still retains 12 pairs of rods. A second unequal division immediately follows without a period of rest, but in this case the component parts of the pairs of rods are so divided that each separate rod moves away from its fellow, although they both originated from the same daughter loop. In this manner a cell of the third generation is formed, the oocyte of the third order, or *mature ovum*, as well as a second polar body. The second division in the period of maturation is peculiar in that here daughter chromosomes are formed, not by a longitudinal splitting of the chromosomes, but by a transverse division.

In the process of development of the ova, three periods are therefore distinguishable. The first, or period of proliferation, represents a stage of repeated mitotic division in the oogonia, during which the latter become gradually reduced in size. In the second, or period of growth, the oogonia increase in size and are then ready for the third, or period of maturation. In the latter, by means of a modified double mitotic division, uninterrupted by any resting stage, the matured ovum and the polar bodies are formed. These several periods are represented in figure 265.

The manner in which the fully developed Graafian follicle bursts and its ovum is freed is still a subject of controversy; the following may be said regarding it: By a softening of the cells forming the pedicle of the discus proligerus, the latter, together with the ovum, are separated from the remaining granulosa, and lie free in the liquor folliculi. At the point where the follicle comes in contact with the tunica albuginea of the ovary, the latter, with the theca folliculi, becomes thin, and in this region, known as the stigma, the blood-vessels are obliterated and the entire tissue gradually atrophies; thus a point of least resistance is formed which gives way at the slightest increase in pressure within the follicle, or in its neighborhood.

The increase of pressure within the follicle, leading to its rupture, is, according to Nagel (96), due to a thickening of the tunica interna of the theca of the follicle. The cells of this layer proliferate and increase in size and show yellowish colored granules. This cell-proliferation leads to a folding of the tunica interna, the folds encroaching on the cavity of the follicle, and causing its contents to be pushed toward the stigma.

When the ovum is released, the rest of the follicle remains behind to form a *corpus luteum*. In the formation of the much larger

corpus luteum verum—*i. e.*, one whose ovum has been fertilized and is in process of further development—the regressive metamorphosis is much slower than is the case with the corpora lutea spuria, whose ova have not been impregnated. In place of the liquor folliculi the corpus luteum usually contains a blood coagulum which is formed as a result of the rupture of the adjacent blood-vessels. Then follows a proliferation of the tissue composing the tunica interna of the theca folliculi. This ingrowth gradually surrounds and finally penetrates into the coagulum and the few granulosa cells remaining, while the latter degenerate and are eventually absorbed. The proliferating tissue contains cells filled with pigment, the *lutein cells*, and it is these which give rise to the characteristic yellow color of the bodies. The inner wall of the corpus luteum is gradually folded in and the

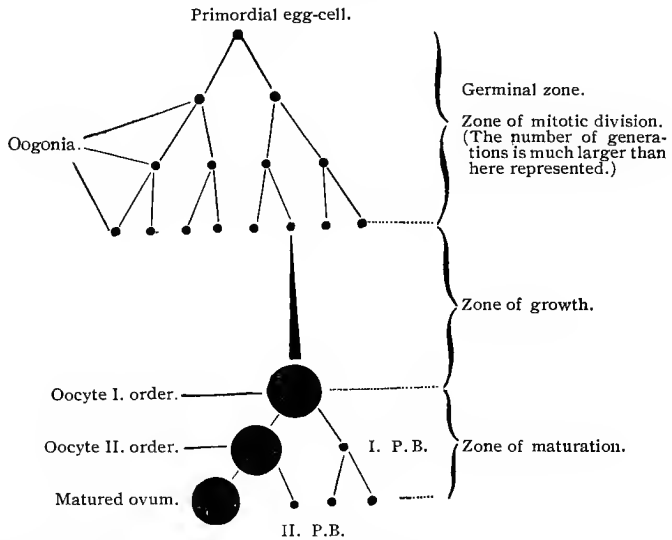


Fig. 265.—Scheme of the development and maturation of an ascaris ovum (after Boveri) : P. B., Polar bodies. (From "Ergebn. d. Anat. u. Entw.," Bd. I.)

degenerating central portion is finally penetrated by vessels and absorbed by the proliferating cells from the outer wall. In the folds of the tunica interna, composed of lutein cells, there is found a variable amount of fibrous connective tissue carrying blood-vessels which break up into capillaries, the latter penetrating between the lutein cells.

According to Sobotta (96 and 97), the corpus luteum of both the mouse and the rabbit is formed chiefly by a hypertrophy of the epithelial cells, while the vascular connective tissue of the inner thecal layer penetrates between the epithelial cells in the shape of processes accompanied by leucocytes, which form a cellular network around the central coagulum. The blood is finally absorbed

without the formation of hematoidin crystals, and a mucoid connective-tissue mass is the result. There is then no further proliferation of connective tissue and the corpus luteum is fully developed in this condition. Later, fat globules are deposited in the greatly enlarged epithelial cells. In the mouse there is no difference as to structure or size between corpora lutea derived from follicles whose ova have been impregnated and those whose ova have not been fertilized.

After a variable time the tissue of the corpus luteum itself undergoes hyaloid degeneration, a process which may be compared to the formation of scar tissue, and which finally results in the formation of the *corpus albicans*. The latter is then in its turn

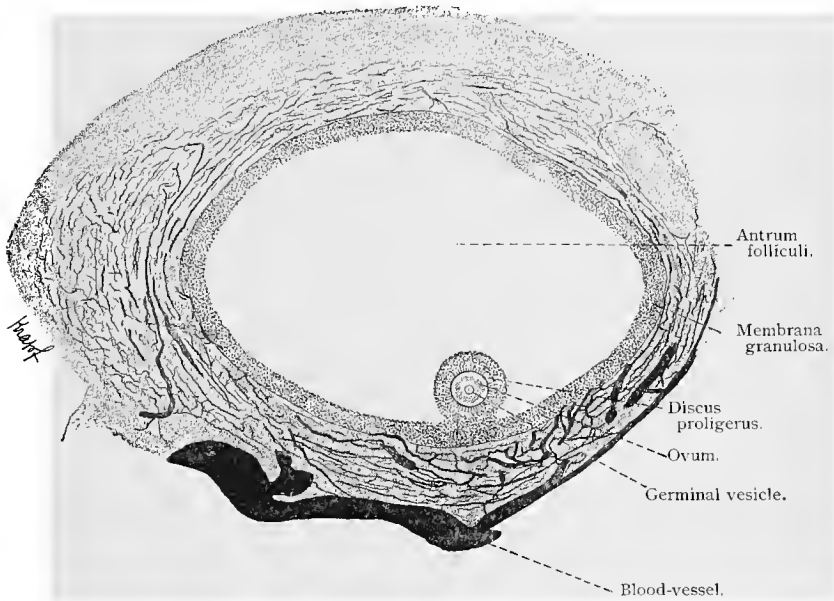


Fig. 266.—Section of fully developed Graafian follicle from injected ovary of pig;  $\times 50$ .

absorbed, and in the end there remains in its place only a connective tissue containing very few fibers.

Not all of the eggs and follicles reach maturity; very many are destroyed by a regressive process known as *atresia of the follicles*. This process may begin at any stage, even affecting the primitive ova while still imbedded in the germinal epithelium—first attacking the egg itself and later the surrounding follicular epithelium, although in both the degenerative process is identical. The germinal vesicle and the nuclei of the follicular cells usually undergo a chromatolytic degeneration, although they sometimes disappear without apparent chromatolysis (direct atrophy), while

the cell-bodies are generally subjected to a fatty degeneration or may even undergo what is known among pathologists as an albuminous degeneration—*i. e.*, one characterized by granulation and showing no fat reaction but numerous reactions such as are observed where albumin is present. These two forms of metamorphosis result in a liquefaction of the cell-body, and finally lead to a hyaline swelling, which renders the substance of the cell homogeneous. The zona pellucida softens, increases in volume, becomes wrinkled, and after some time is absorbed. A further stage in the regressive process consists in the formation of scar tissue, as in the case of the corpus luteum. Here leucocytes accompany the proliferation from the tunica interna of the theca folliculi, and assist in absorbing the products of degeneration, the result being a connective-tissue scar (*vid.* G. Ruge, and Schottländer, 91, 93).

The **blood-vessels** of the ovary enter at the hilum and branch in the medullary substance of the ovary. From these medullary vessels branches are given off which penetrate the follicular zone, giving off branches to the follicles and terminating in a capillary network in the tunica albuginea (Clark, 1900). The relations of the branches to the follicles are such that in the outer layer of the theca folliculi the vessels form a network with wide meshes while the inner layer contains a fine capillary network (Fig. 266). The veins are of large caliber and form a plexus at the hilum of the ovary.

The lymphatics of the ovary are numerous. They begin in clefts in the follicular zone, which unite to form vessels lined by endothelial cells in the medulla. They leave the ovary at the hilum.

The nerves accompany and surround the blood-vessels, while very few nerve-fibers penetrate into the theca folliculi; those doing so form a network around the follicle and end often in small nodules without penetrating beyond the theca itself. Ganglion cells of the sympathetic type also occur in the medulla of the ovary near the hilum (Retzius, 93; Riese, Gawronski).

### 3. THE FALLOPIAN TUBES, UTERUS, AND VAGINA.

The **Fallopian tubes** consist of a mucous membrane, muscular coat, and peritoneal covering.

The mucous membrane presents a large number of longitudinal folds which frequently communicate with one another. Very early in the development four of these folds are particularly noticeable in the isthmus; these may also be recognized at times in the adult. These are the chief folds, in contradistinction to the rest, which are known as the accessory folds (Frommel). The accessory folds are well developed in the isthmus, and are here so closely arranged that no lumen can be seen with the naked eye. The epithelium lining the tubes is composed of a single layer of ciliated columnar

cells which entirely cover the folds as well as the tissue between them. Glands do not occur in the oviducts, unless the crypts between the folds may be considered as such. The mucosa beneath the epithelium contains relatively few connective-tissue fibers, but numerous cellular elements. In the isthmus it is compact, but in the ampulla and infundibulum its structure is looser. The mucosa contains a few nonstriated muscle-fibers, which have a longitudinal direction and extend into the chief folds, but not into the accessory folds.

External to the mucosa is found the muscular coat, consisting of an inner circular and an outer and thinner longitudinal layer. The latter is imperfectly developed in the ampulla and may be

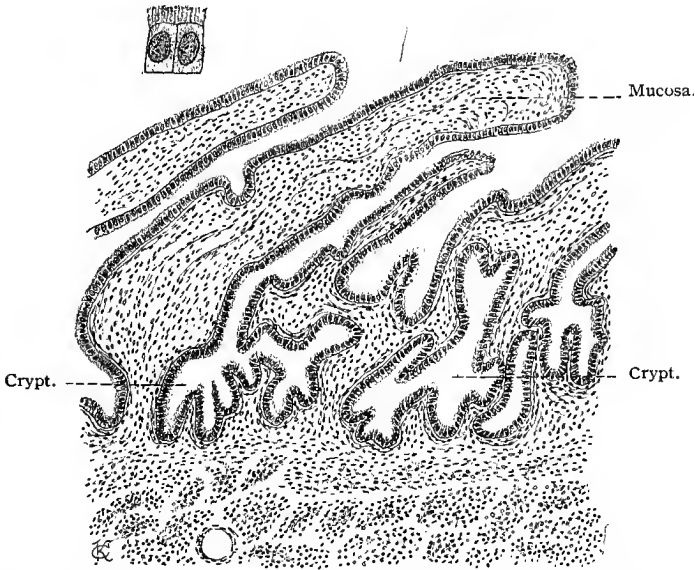


Fig. 267.—Section of oviduct of young woman. To the left and above are two enlarged ciliated epithelial cells from the same tube;  $\times 170$ .

entirely absent in the infundibulum. The peritoneal layer consists of a loose connective tissue covered by mesothelium.

The **uterus** is composed of a mucous, a muscular, and a peritoneal coat.

The mucosa of the body of the uterus and cervix is lined by a single layer of columnar ciliated epithelial cells; these are somewhat higher in the cervix than in the corpus. Barfurth (96) has found intercellular bridges between the cells of the uterine epithelium in the guinea-pig and rabbit. In the cervix of the virgin the ciliated columnar epithelium extends as far as the external os, at which point this usually changes to a stratified squamous epithelium. In

multiparæ the squamous epithelium extends into the cervical canal and may be found, with occasional exceptions (islands of ciliated epithelium), throughout its entire lower third. This arrangement is subject to considerable variation, so that even in children the lower portion of the cervical canal may sometimes be lined by stratified epithelium. In the body of the uterus the mucosa is composed of a reticular connective tissue, resembling in structure that of the mucosa of the intestinal canal. This reticular connective tissue consists of connective-tissue fibers and branched connective-tissue cells arranged in the form of a network, in the meshes of which are found lymphocytes and leucocytes. The mucosa of the cervix is somewhat denser, containing more fibrous tissue.

In the cervical canal the mucosa of the anterior and posterior walls is elevated to form numerous folds, extending laterally from larger median folds. These folds are known as the *plicæ palmatæ*. The mucosa of the body of the uterus and of the cervix contains numerous glands, the uterine and cervical glands. The uterine glands are branched tubular in type, and extend through the mucosa and for a short distance into the muscular layer. They are lined by ciliated columnar epithelium, resting on a basement membrane. The cervical glands are of the same shape and structure. Above the *plicæ palmatæ* the glands are numerous; below, they gradually diminish in number. Besides these glands the cervix also contains peculiar short crypts with lateral sacculations, the lumina of which are wider and the epithelium higher than in the cervical glands. The glands and crypts extend as far as the external os. In the mucous membrane of the cervical region we find peculiar, closed sacs of varying size lined by simple cylindrical or ciliated epithelium, the so-called *ovula Nabothi*, which probably represent cystic formations (*vid. A. Martin*).

It has been the opinion of most gynecologists hitherto that the ciliary movement of the epithelium in the oviducts and uterus was in the direction of the tubo-uterine opening; but later investigations have established the fact that in both the uterus and oviducts the general direction of the wave-like ciliary motion is toward the vagina (*Hofmeier*).

Three layers of muscular tissue are to be seen both in the corpus and cervix uteri—an inner longitudinal, a middle nearly circular, in which the principal blood-vessels are found, and an outer longitudinal. The inner and outer layers are known respectively from their position as the stratum mucosum and stratum serosum, the middle and more vascular as the stratum vasculosum. As compared with the middle, the inner and outer muscle layers are poorly developed. The complicated conditions found in the uterine musculature can be better understood if some attention be paid to its origin. The circular layer should be regarded as the original musculature of the Müllerian ducts. The outer longitudinal layer develops later, and is derived from the musculature of the broad

ligament. Between these two are the large vessels accompanied by a certain amount of muscular tissue—a condition which persists throughout life in the carnivora. In man the blood-vessels penetrate into the circular musculature and only appear later in the inner muscular layer. A true muscularis mucosæ is not present in the human uterus (Sobotta, 91).

The serous or peritoneal layer consists of a layer of mesothelial cells and submesothelial connective tissue.

The uterus derives its blood supply from the uterine and ovarian arteries, which enter from the broad ligament through its lateral portion. These vessels pass to the stratum vasculosum of the muscular layer, where they branch repeatedly, some of the branches

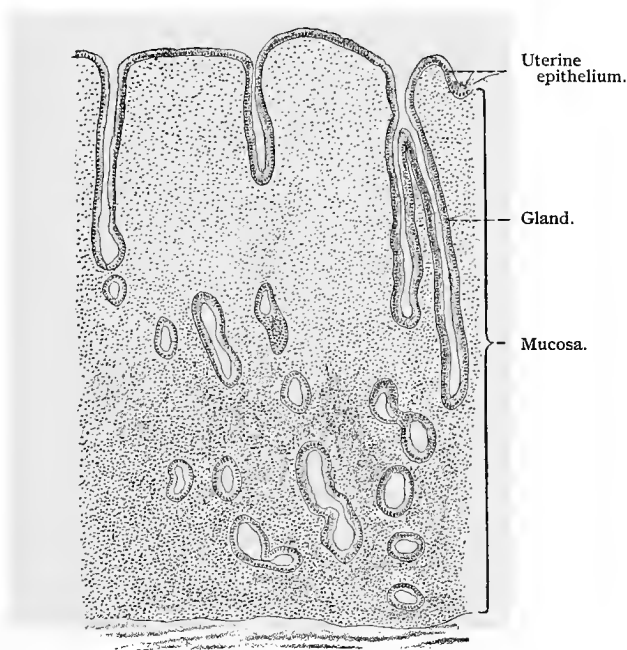


Fig. 268.—From uterus of young woman;  $\times 34$ . (From a preparation by Dr. J. Amann.)

entering the mucosa, where they form capillary networks surrounding the glands and a dense capillary network situated under the uterine epithelium. The veins form a venous plexus in the deeper portion of the mucosa, especially well developed in the cervix and os uteri. From this plexus the blood passes to a second well-developed venous plexus situated in the stratum vasculosum of the muscular layer, whence the blood passes to the plexus of uterine and ovarian veins.

The lymphatics begin in numerous clefts in the uterine mucosa ;

from here the lymph passes by way of lymph-vessels to the muscular coat, between the bundles of which are found numerous lymph-vessels especially in the middle or vascular layer. These lymph-vessels terminate in larger vessels found in the subserous connective tissue.

The uterus and Fallopian tubes receive numerous medullated and nonmedullated nerves. The latter terminate in the muscular layers. Medullated fibers have been traced into the mucosa, where they form plexuses under the epithelium, from which branches have been traced between the epithelial cells and between the gland-cells. In the course of the nerves ganglion cells of the sympathetic type have been observed.

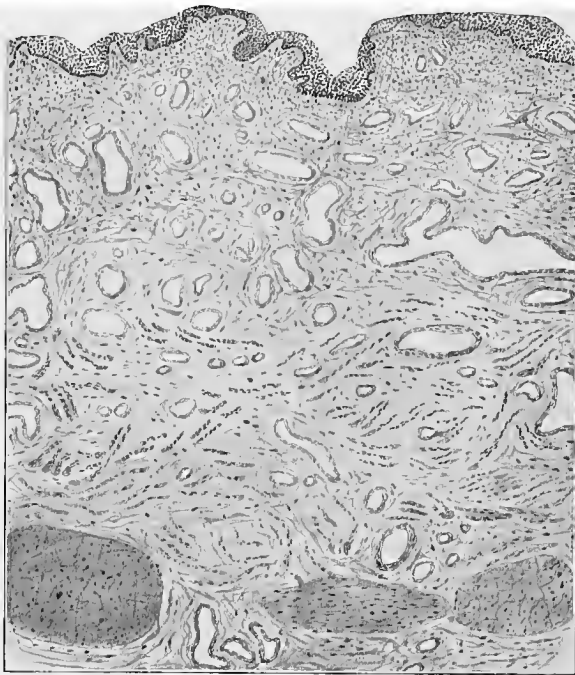

Fig. 209.—From section of human vagina.

In the **vagina** we distinguish also three coats—the mucous membrane, the muscular layer, and the outer fibrous covering.

The epithelium of the mucous membrane is of the stratified squamous type, and possesses, as usual, a basal layer of cylindric cells. The mucosa of the vagina consists of numerous connective-tissue fibers mingled with a number of exceptionally coarse elastic fibers. Papillæ containing blood-vessels are present everywhere except in the depressions between the columnæ rugarum. It is generally stated that the vagina has no glands, but according to the observations of von Preuschen and C. Ruge, a few isolated glands occur in

the vagina. They are relatively simple in structure, form irregular tubes, and are lined by ciliated columnar epithelium. The excretory ducts are lined by stratified squamous epithelium. Diffuse adenoid tissue is met with in the mucosa, which sometimes assumes the form of lymphatic nodules.

The muscular coat, which in the lower region is quite prominent, may be separated indistinctly into an outer longitudinal and an inner circular layer; the latter is, as a rule, poorly developed, and may be entirely absent. The muscular coat is especially well developed anteriorly in the neighborhood of the bladder.

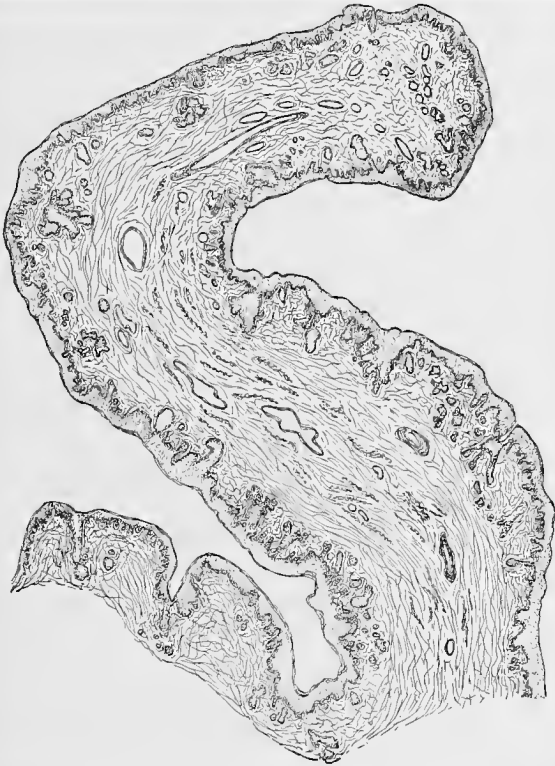

Fig. 270 —From section of human labia minora.

The outer fibrous layer consists of dense connective tissue loosely connected with the adjacent structures.

At its lower end the vagina is partially closed by the hymen which must be regarded as a rudiment of the membrane which in the embryo separates the lower segment of the united Müllerian ducts from the ectoderm of the sinus urogenitalis. Accordingly, the epithelium on the inner surface of the hymen partakes of the character of the vaginal epithelium; that on the outer surface resembling the skin in structure (G. Klein).

The epithelium of the *vestibulum* gradually assumes the characteristics of the epidermis; its outer cells lose their nuclei and sebaceous glands occur here and there in the neighborhood of the urethral orifice and on the labia minora. Hair begins to appear on the outer surface of the labia majora.

The clitoris is covered by a thin epithelial layer, resembling the epidermis. This rests on a fibrous-tissue mucosa having numerous papillæ, some of which contain capillaries, others special nerve-endings. In the clitoris of the adult no glands are found. The greater portion of the clitoris consists of cavernous tissue, homologous to the corpora cavernosa of the penis; the corpus spongiosum is not present in the clitoris.

The glands of Bartholin the homologues of the glands of Cowper in the male, are mucous glands situated in the lateral walls of the vestibule of the vagina. The terminal portions of their ducts are lined by stratified squamous epithelium.

Free sensory nerve-endings, with or without terminal enlargements, have been demonstrated in the epithelium of the vagina (Gawronski). The sensory nerve-fibers form plexuses in the mucosa, and lose their medullary sheaths as they approach the epithelium. Sympathetic ganglia are met with along the course of these nerves, and nonmedullated nerves terminate in the involuntary muscular tissue of the vaginal wall.

In the connective-tissue papillæ and in the deeper portions of the mucosa of the glans clitoridis are found, besides the ordinary type of tactile corpuscles and the spherical end-bulbs of Krause, the so-called genital corpuscles (see p. 155). Numerous Pacinian corpuscles have been observed in close proximity to the nerve-fibers of the clitoris and the labia minora.

---

In varying regions of the medullary substance of the ovary, but more usually in the neighborhood of the hilum, there occur irregular epithelial cords or tubules provided with columnar epithelium, ciliated or nonciliated, which constitute the *paroophoron*. These are the remains of the mesonephros, and are continuations of that rudimentary organ—the *epoophoron*—of similar structure which lies within the broad ligament. The separate tubules of the epoophoron communicate with the *duct of Gärtner* (Wolffian duct), which in the human being is short, ends blindly, and never, as in certain animals, opens into the lower portion of the vagina. These derivatives of the primitive kidney consist of blindly ending tubules of varying length lined by a ciliated epithelium, the cells of which are often found in process of degeneration.

The *hydatids of Morgagni* are duplications of the peritoneum.

## D. THE MALE GENITAL ORGANS.

## 1. THE SPERMATOOZON.

The semen, or sperma, is a fluid that, as a whole, consists of the secretion of several sets of glands in which the sexual cells, the spermatozoa, or spermatozoa, which are formed in the testes, are suspended.

We shall first consider the structure of the typical adult spermatozoon, taking up consecutively its component parts. Three principal parts may be distinguished—the *head*, the *middle piece*, and the *tail* or *flagellum*. The round or oval body of the head terminates in a lanceolate extremity. The former consists of chromatin, and is most intimately associated with the phenomenon of fertilization. The middle piece, which is attached to the posterior end of the head, is composed of a protoplasmic envelop which surrounds a portion of the so-called *axial thread*. The latter is enlarged anteriorly just behind the head to form the *terminal nodule*, which fits into a depression in the head. From the middle piece on, the axial thread

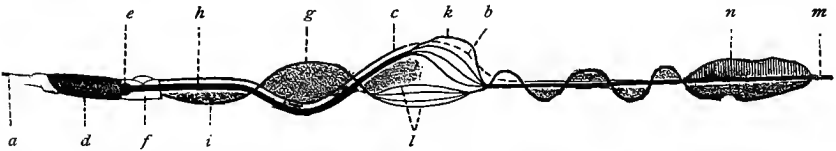


Fig. 271.—Diagram showing the general characteristics of the spermatozoa of various vertebrates: *a*, Lance; *b*, segments of the accessory thread; *c*, accessory thread; *d*, body of the head; *e*, terminal nodule; *f*, middle piece; *g*, marginal thread; *h*, axial thread; *i*, undulating membrane; *k*, fibrils of the axial thread; *l*, fibrils of the marginal thread; *m*, end piece of Retzius; *n*, rudder-membrane.

is continued into the tail of the spermatozoon, and is here surrounded by a transparent substance—the *sheath of the axial thread*. The envelop is lacking at the posterior extremity of the tail, where the axial thread extends for a short distance as a naked filament called the *end-piece of Retzius*. From the middle piece a still finer thread is given off, the *marginal thread*, which extends at a certain distance from the axial thread as far as the end-piece of Retzius. In its course it crosses and recrosses the axial thread at various points, and may even wind around it in a spiral manner. In all instances it is connected with the sheath of the axial thread by a delicate membrane—the *undulating membrane*. Another and still more delicate filament—the *accessory thread*—runs parallel with the axial thread along the surface of its sheath and terminates at a certain distance from the end-piece of Retzius. Near the extremity of the flagellum and immediately in front of the end-piece is another and shorter membrane,—the *rudder membrane*,—which is continuous with the undulating membrane. Maceration reveals a fibrillar

structure of both the axial and marginal threads (Ballowitz), while the accessory thread is separated into a number of short segments.




Fig. 272.—Human spermatozoa. The two at the left after Retzius (81); the one at the extreme left is seen in profile; the other in surface view; the one at the right is drawn as described by Jensen: *a*, Head; *b*, terminal nodule; *c*, middle piece; *d*, tail; *e*, end-piece of Retzius.

In mammalia, and especially in man, the spermatozoa seem to be more simply constructed. Here the head is pyriform, and somewhat flattened, with a slight ridge along the depression at either side of its anterior thinner portion (Fig. 272). In some mammalia (mouse), the head is provided with a so-called cap, which corresponds to the lance previously mentioned. The middle piece is relatively long and shows a distinct cross-striation, which may be attributed to its spiral structure. Here also the middle piece is traversed by the axial thread, which ends at the head in a terminal nodule, and may be separated as in other mammalia into a number of fibrils. Some years ago Gibbes described an undulating membrane in the human spermatozoon, an observation which was confirmed by W. Krause (81). The head of the human spermatosome is from  $3\ \mu$  to  $5\ \mu$  long, and from  $2\ \mu$  to  $3\ \mu$  in breadth; the middle piece is  $6\ \mu$  long and  $1\ \mu$  in breadth; the tail is from  $40\ \mu$  to  $60\ \mu$  long, and the end-piece  $6\ \mu$  long.

The spermatozoa are actively motile, a phenomenon due to the flagella, which give them a spiral, boring motion. They are characterized by great longevity and are very resistant to the action of low temperatures (*vid.* Piersol, 83). In some species of bat the spermatozoa penetrate into the oviduct of the female in the fall, but do not contribute to impregnation until the spring, when the ova mature. (For the structure of the spermatosomes see Jensen, Ballowitz.)

## 2. THE TESTES.

The testis is inclosed within a dense fibrous capsule,—the *tunica albuginea*,—about one-sixteenth of an inch in thickness, and surrounded by a closed serous sac, derived from the peritoneum during the descent of the testes, and therefore lined by mesothelial cells. This serous sac—the *tunica vaginalis*—consists of a visceral layer attached to the tunica albuginea, and a parietal layer which blends with the scrotum. The cavity contains normally a small amount of serous fluid. On the inner surface of the tunica albuginea is found a thin layer of loose fibrous tissue containing blood-vessels—the *tunica vasculosa*. The tunica albuginea is thickened in its

posterior portion to form the *mediastinum testis*, or the *corpus Highmori*, which projects as a fibrous-tissue ridge for a variable distance into the substance of the testis. The gross structure of the testis is best seen in a sagittal longitudinal section. Even a low magnification will show that the testis is composed of lobules. These are produced by septa which extend into the substance of the organ and are derived from the investing tunics of the testis and diverge in a radiate manner from the mediastinum testis. The lobules are of pyramidal shape, with their bases directed toward the capsule and their apices toward the mediastinum. They consist principally of the seminiferous tubules, whose transverse, oblique, and longitudinal

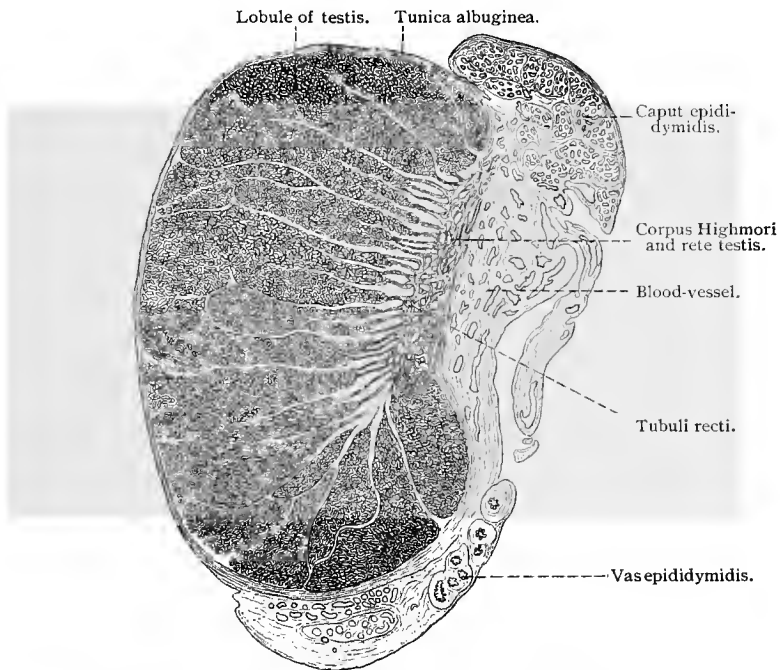


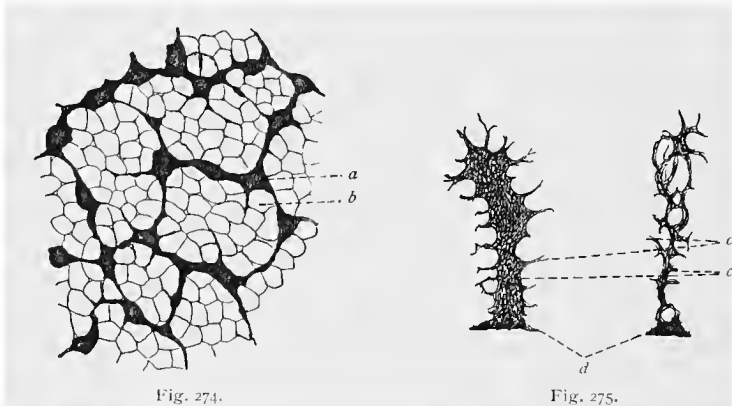
Fig. 273.—Longitudinal section through human testis and epididymis. The light areas between the lobules are the fibrous-tissue septa of the testis;  $\times 2$ .

sections may be observed in sections of the testis. When isolated, these tubules are seen to begin in the testis as closed canals, which are closely coiled upon each other (convoluted tubules) and describe a tortuous course, until they finally reach the corpus Highmori. Immediately before they reach the latter, the convoluted tubules change into short, straight and narrow segments—the *straight tubules*, or *tubuli recti*. Within the corpus Highmori, all the straight tubules of the testis unite to form a tubular network—the *rete testis* (Haller).

From this network about fifteen tubules—the *vasa efferentia*—

arise. The latter, at first straight, soon begin to wind in such a manner that the various convolutions of each canal form an independent system, invested by a fibrous sheath of its own—*coni vasculosi Halleri*. These lobules constitute the elements of the globus major of the epididymis. In cross-section the vasa efferentia are seen to be stellate in shape. The vasa efferentia gradually unite to form one canal—the *vas epididymidis*. This is markedly convoluted and is situated in the body and tail of the epididymis itself.

The epithelium of the convoluted seminiferous tubules consists of sustentacular cells (cells or columns of Sertoli) and of spermatogenic elements. The former are high, cylindrical structures (see below), the basilar surfaces of which are in contact. They do not form a continuous layer, but their basal processes are interwoven to form a superficial network surrounding the epithelium of the



Sustentacular cells (cells of Sertoli) of the guinea-pig (chrome-silver method). Figure 274, surface view of the seminiferous tubules; figure 275, profile view;  $\times 220$ : *a*, Basilar surface of a cylindrical sustentacular cell; *b*, flattened sustentacular cell; *c*, *c*, depressions in the sustentacular cells due to pressure from the spermatogenic cells; *d*, basilar portion of sustentacular cells.

seminiferous tubules. (Fig. 275.) In the meshes of the reticulum are deposited numbers of plate-like cells, which lie in contact with the basement membrane and also represent sustentacular elements (*vid.* Merkel, 71).

Between the sustentacular cells are found from four to six rows of cells, possessing relatively large nuclei, rich in chromatin, and derived from cells of the deeper strata by mitotic cell division. The epithelium of the convoluted portion of the seminiferous tubules is, therefore, a stratified epithelium. The cells of this epithelium present various peculiarities according to their stage of development, and will be considered more fully in discussing spermatogenesis. Externally, the walls of the convoluted tubules are limited by a single layer or several layers of spindle-shaped, epithelioid cells. A basement membrane is present, but very thin, and in some cases

hardly capable of demonstration. The convoluted tubules are separated from each other by a small amount of connective tissue, in which, in addition to the vessels, nerves, etc., are found peculiar groups of large cells containing large nuclei, and known as interstitial cells. Nothing definite is known regarding the significance of these cells; but they are probably remains of the Wolffian body. Reinke (96) found repeatedly crystalloids of problematic significance in the interstitial cells of the normal testis.

The stratified epithelium of the convoluted tubules changes in

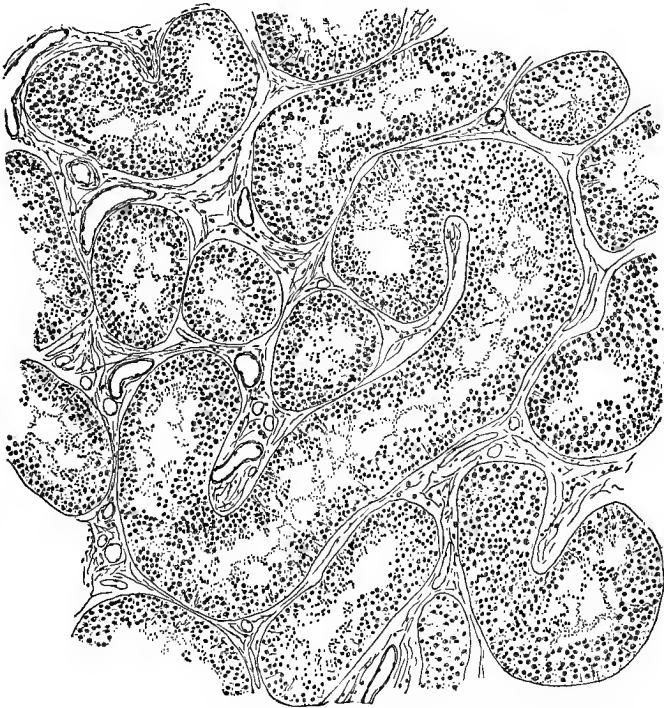


Fig. 276.—From section of human testis, showing convoluted seminiferous tubules.

the tubuli recti to an epithelium consisting of a single layer of short columnar or cubical cells resting on a thin basement membrane.

The canals of the rete testis (Haller) are lined by nonciliated epithelium, which varies in type from flat to cubical. Communicating with the rete testis is a blind canal, the vas aberrans of the rete testis, lined with ciliated epithelium.

The vasa efferentia are lined partly by ciliated columnar and partly by nonciliated cubical epithelium. The two varieties form groups which alternate, giving rise to nonciliated depressions, which represent gland-like structures (Schaffer, 92), but do not

cause corresponding evaginations of the mucosa. Outside of the mucosa, which consists of fibrous connective tissue, there are found several layers of nonstriated muscle-fibers circularly disposed.

The vas epididymidis is lined by stratified ciliated columnar epithelium, resting on a thin mucosa, outside of which there is

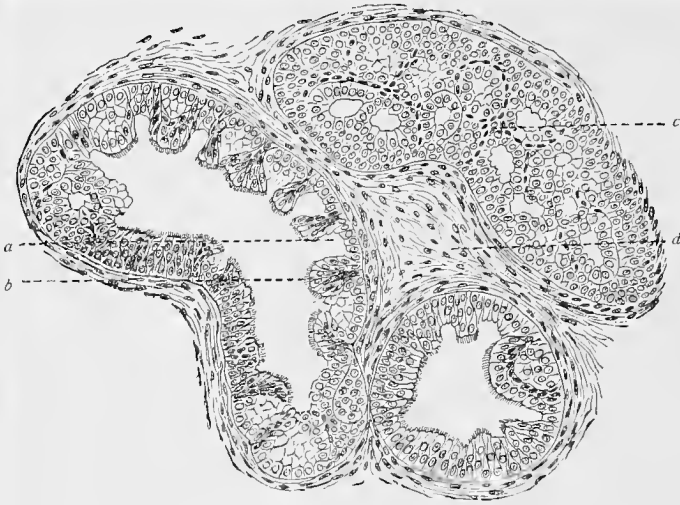


Fig. 277.—Section through human vasa efferentia : *a*, Glands ; *b*, ciliated epithelium ; *c*, glandular structure ; *d*, connective tissue.

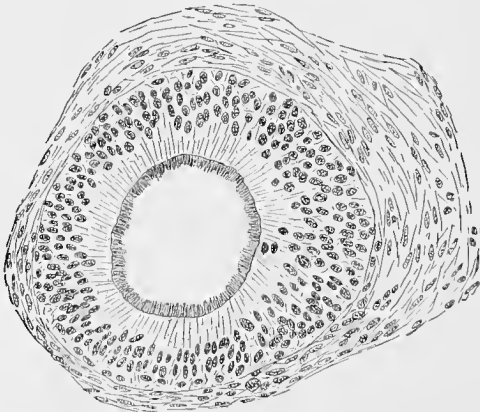


Fig. 278.—Cross-section of vas epididymidis of human testis.

found an inner circular and an outer, though thin, longitudinal layer of nonstriated muscular tissue.

An aberrant canaliculus also communicates with the vas epididymidis, and is here known as the *vas aberrans Halleri*. Num-

bers of convoluted and blindly ending canaliculi are frequently found imbedded in the connective tissue around the epididymis. These constitute the *paradidymis*, or *organ of Giralès*.

The blood-vessels of the testis spread out in the corpus Highmori and in the tunica vasculosa of the connective-tissue septa and of the tunica albuginea, their capillaries encircling the seminal tubules in well-marked networks.

The lymphatic vessels begin in clefts in the tunica albuginea and in the connective tissue between the convoluted tubules. They converge toward the corpus Highmori and pass thence to the spermatic cord.

Retzius (93) and Timofeew (94) have described plexuses of nonmedullated, varicose nerve-fibers surrounding the blood-vessels of the testis. From such plexuses single fibers, or small bundles of such, could be traced to the seminiferous tubules, about which they also form plexuses. Such fibers have not been traced into the epithelium lining the tubules. In the epididymis Timofeew found numerous sympathetic ganglia, the cell-bodies of the sympathetic neurones of which were surrounded by pericellular plexuses. In the wall of the vas epididymidis and the vasa efferentia were observed numerous varicose nerve-fibers, arranged in the form of a plexus, many of which seemed to terminate on the nonstriated muscle cells found in these tubes. Some of the nerve-fibers were traced into the mucosa, but not into its epithelial lining.

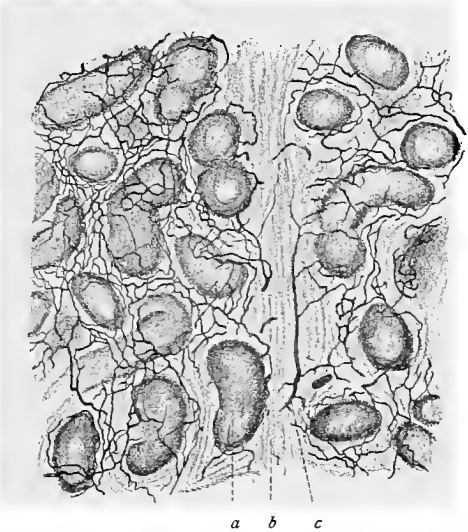


Fig. 279.—Section of dog's testis with injected blood-vessels (low power): *a*, Seminiferous tubule; *b*, connective-tissue septum; *c*, blood-vessel.

### 3. THE EXCRETORY DUCTS.

The *vas deferens* possesses a relatively thick muscular wall, consisting of three layers, of which the middle is circular and the other two longitudinal. The subepithelial mucosa is abundantly supplied with elastic fibers and presents longitudinal folds. The lining epithelium is in part simple ciliated columnar and in part stratified ciliated columnar, with two rows of nuclei. The cilia are, however, often absent, beginning with the lower portion of the vas epididymidis.

dymidis. According to Steiner, the epithelium of the vas deferens varies. It may be provided with cilia in the lower segments, or it may even be similar to that found in the bladder and ureters.

The inner muscular layer is wanting in the ampulla of the vas deferens; here the epithelium is mostly simple columnar and pigmented. Besides the folds, there are also evaginations and tubules which sometimes form anastomoses—structures which may be regarded as glands.

The *seminal vesicles* are also lined, at least when in a distended condition, by simple, nonciliated columnar epithelium containing yellow pigment. In a collapsed condition the epithelium is pseudostratified, with two or even three layers of nuclei. The arrangement of the epithelial cells in a single layer would therefore seem to be the result of distention. The mucous membrane shows

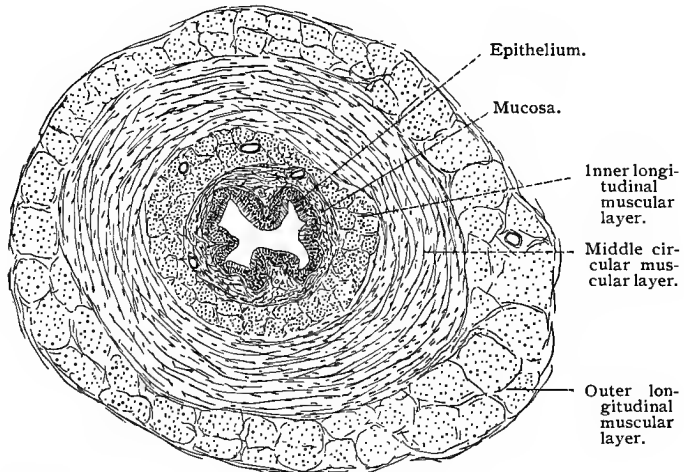


Fig. 280.—Cross-section of vas deferens near the epididymis (human).

numerous folds, which, in the guinea-pig for instance, present a delicate axial connective-tissue stroma. Besides scanty subepithelial connective tissue, the seminal vesicles are provided with an inner circular and an outer longitudinal layer of muscle-fibers. Spermatozoa are, as a rule, not met with in the seminal vesicles.

The epithelium of the *ejaculatory ducts* is composed of a single layer of cells; the inner circular muscle-layer is very poorly developed. In the prostatic portion of the ejaculatory ducts the longitudinal muscle-layer mingles with the musculature of the prostate and loses its individuality. The ejaculatory ducts empty either directly into the urethra at the colliculus seminalis, or indirectly into the prostatic portion of the urethra through the vesicula prostatica.

The *prostate* is a compound branched alveolar gland. Its capsule

consists of dense layers of nonstriated muscle-fibers, connective tissue, and yellow elastic fibers. Processes and lamellæ composed of all these elements extend into the interior of the gland, converging toward the base of the colliculus seminalis. Between the larger trabeculæ are situated numerous glands, consisting of large,




Fig. 281.—Cross-section of wall of seminal vesicle, showing the folds of the mucosa (human).

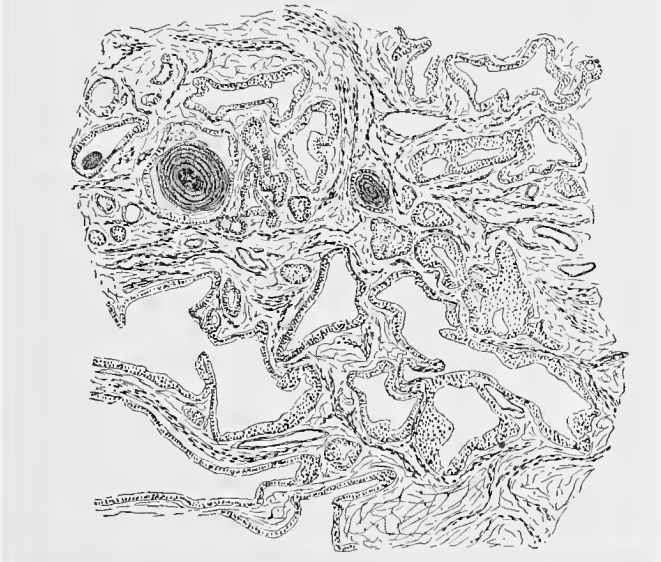


Fig. 282.—From section of prostate gland of man.

irregular alveoli, separated by fibromuscular septa and trabeculæ. The alveoli are lined by simple columnar epithelium, the inner portion of the cells often showing acidophile granules. Now and then the alveoli present a pseudostratified epithelium, with two rows of nuclei (Rudinger, 83). A basement membrane, although

present, is difficult to demonstrate. The numerous excretory ducts, lined by simple columnar epithelium, become confluent and form from 15 to 30 collecting ducts which empty, as a rule, either at the colliculus seminalis or into the sulcus prostaticus. Near their terminations the larger ducts are lined by transitional epithelium similar to that lining the prostatic portion of the urethra.

In the alveoli of the glands, peculiar concentrically laminated concretions are found, known as prostatic bodies or concretions (*corpora amylacea*). They are more numerous in old men, but are found in the prostates of young men and also of young boys. The secretion of the prostate (*succus prostaticus*) is not mucous in character, but resembles a serous secretion and has an acid reaction. The *vesicula prostatica* (*sinus pocularis*) is lined by stratified epithelium, consisting of two layers of cells and provided with a distinct cuticular margin upon which rest cilia. In its urethral region occur short alveolar glands.

The glands of Cowper are branched tubular alveolar glands, the alveoli being lined by mucous cells. Crescents of Gianuzzi are, however, seldom seen. The smaller excretory ducts, lined by cubical epithelium, unite to form two ducts, one on each side of the urethra; these are  $1\frac{1}{2}$  inches long, and are lined by stratified epithelium consisting of two or three layers of cells.

The blood-vessels of the prostate ramify in the fibromuscular trabeculæ and form capillary networks surrounding the alveoli. The veins collecting the blood pass to the periphery of the gland, where they form a plexus in the capsule. The lymphatics begin in clefts in the trabeculæ and follow the veins. The terminal branches of the vessels supplying Cowper's glands are, in their arrangement, like those of other mucous glands.

Numerous sympathetic ganglia are found in the prostate under the capsule and in the larger trabeculæ near the capsule. The neuraxes of the sympathetic cells of these ganglia may be traced to the vessels and into the trabeculæ; their mode of ending has, however, not been determined. Small medullated nerve-fibers terminate in these ganglia in pericellular baskets. Timofeew has described peculiar encapsulated sensory nerve-endings, found in the prostatic and membranous portions of the urethra of certain mammals. They consist of the terminal branches of two kinds of nerves, inclosed within nucleated laminated capsules: one large medullated nerve-fiber, after losing its medullary sheath, breaks up into a small number of ribbon-shaped branches with serrated edges, which may pass more or less directly to the end of the nerve-ending or may be bent upon themselves; and very much smaller medullated nerve-fibers which, after losing their medullary sheaths, divide into a large number of varicose fibers which form a dense network encircling the ribbon-shaped fibers previously mentioned.

The *penis* consists of three cylindrical masses of erectile tissue—the two *corpora cavernosa*, forming the greater part of the penis

and lying side by side, and the corpus spongiosum, surrounding the urethra and lying below and between the corpora cavernosa. The two latter are surrounded by a dense connective-tissue sheath, the tunica albuginea. These erectile bodies are surrounded by a thin layer of skin, containing no adipose tissue and no hair-follicles. The corpus spongiosum is enlarged anteriorly to form the glans penis.

The principal substance of the erectile bodies is the so-called erectile tissue: septa and trabeculæ, consisting of connective tissue, elastic fibers, and smooth muscle-cells inclosing a system of communicating spaces. These latter may be regarded as venous sinuses, the walls of which, lined by endothelial cells, are in apposition to the erectile tissue. Under certain conditions the venous sinuses are distended with blood, but normally they are in a collapsed state and form fissures which simulate the clefts found in ordinary connective tissue. In other words, there is here such an arrangement of the blood-vessels within the erectile tissue that the circulation may be carried on with or without the aid of the cavernous spaces. The arteries of the corpora cavernosa possess an especially well-developed musculature. They ramify throughout the trabeculæ and septa of the erectile tissue and break up within the septa into a coarsely meshed plexus of capillaries. A few of these arteries empty directly into the cavernous spaces. On the other hand, the arteries give off a rich and narrow-meshed capillary network immediately beneath the tunica albuginea. This is in communication with a deeper and denser venous network, which, in turn, gradually empties into the venous sinuses. Aside from these there are anastomoses between the arterial and venous capillaries, which later communicate with the venous network just mentioned. The blood current, regulated as it thus is, may pass either through the capillaries alone, or may divide and flow through both these and the venous sinuses. These conditions explain both the erectile and quiescent state of the penis. The relations are somewhat different in the corpus spongiosum urethræ and in the glans penis.

The epithelium of the urethra varies in the several regions. The prostatic portion possesses an epithelium similar to that of the bladder. In the membranous portion, the epithelium may be similar to that found in the prostatic portion, but more often presents the appearance of a pseudostratified epithelium with two or three layers of nuclei. The cavernous region is lined by pseudostratified epithelium, except in the fossa navicularis, where a stratified squamous epithelium is found. Between the fibro-elastic mucosa and the epithelium there is a basement membrane. There occur in the urethra, beginning with the membranous portion, irregularly scattered epithelial sacculations of different shapes. Some of these show alveolar branching, and are then known as the glands of Littre.

The submucosa of the cavernous portion of the urethra, which

contains nonstriated muscle-tissue arranged circularly, is richly supplied with veins, and contains pronounced plexuses communicating with cavernous sinuses, which correspond in general to those of the corpora cavernosa penis.

In the glans penis the cavernous spaces are small and of more regular shape than in the corpora cavernosa. The glans is covered by a layer of stratified squamous epithelium, often possessing a thin stratum corneum (see Skin).

Near the corona of the glans penis there are now and then found small sebaceous glands (see Hair), known as glands of Tyson. The prepuce is a duplication of the skin, the inner surface presenting the appearance of a mucous membrane.

The nerves terminating in the glans penis have recently been studied by Dogiel, who made use of the methylene-blue method in his investigation. He finds Meissner's corpuscles in the connective-tissue papillæ under the epithelium, Krause's spheric end-bulbs somewhat deeper in the connective tissue, and the genital corpuscles situated still deeper (see Sensory Nerve-endings). In the epithelium are found free sensory nerve-endings. Pacinian corpuscles have also been found in this region.

#### 4. SPERMATOGENESIS.

In order that the student may obtain an understanding of the complicated process of spermatogenesis we shall give a description of it as it occurs in *salamandra maculosa*, which of all vertebrate animals presents the phenomena in their simplest and best known form. The student should understand, however, that many of the details here described have not been observed in the testes of mammalia; and, since the spermatozoa of many of the mammalia are of simpler structure than those of the salamander, the development of the spermatozoa of the former is consequently simpler. It should also be noticed that the general structure of the testes of the salamander differs in some respects from that of the testes of mammalia, as given in the preceding pages.

At first the seminiferous tubules consist of solid cellular cords, and it is only during active production of spermatozoa that a central lumen is formed, in which the spermatosomes then lie. The cells which compose these solid cords may be early differentiated into two classes—those of the one class being directly concerned in the production of the spermatosomes; those of the other appearing to have a more passive rôle. The cells of the first class—the *spermatogonia*, or *primitive seminal cells*—undergo a process of division accompanied by an increase in size. In this way they soon commence to press upon the cells of the second class—the *follicular* or *sustentacular cells*. The result is that the nuclei of the latter are forced more or less toward the wall of the seminal tubule, while their protoplasm is so indented by the adjacent spermatogonia that the cells

assume a flattened cylindrical shape presenting indentations and processes on all sides. In this stage the spermatogonia have a radiate arrangement and entirely surround the elongated sustentacular cells. At present three periods are distinguished in the development of the male sexual cells (spermatosomes) from the spermatogonia. The first period embraces a repeated mitotic division of the spermatogonia—the period of proliferation. In the second, the spermatogonia, which have naturally become smaller from repeated division, begin to increase in size—the period of growth. The third is characterized by a modified double mitotic division without intervening period of rest, and results in the matured spermatozoa—the period of maturation, figure 283. During the third period, a very important and significant process takes place—the

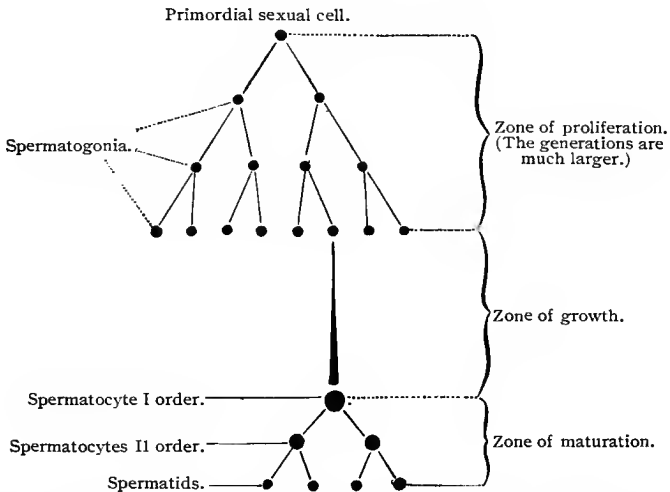


Fig. 283.—Schematic diagram of spermatogenesis as it occurs in *Ascaris* (after Böveri). ("Ergebn. d. Anat. u. Entw.," Bd. 1.)

reduction in the number of chromosomes, so that in the spermatids, the chromosomes are reduced to half the number present in a somatic cell of the same animal. The manner in which this reduction in the number of chromosomes takes place will be described as it occurs in *Salamandra maculosa*.

After the cells composing the last generation of spermatogonia have attained a certain size (period of growth), they undergo karyokinetic division. First, the usual skein or spirem is formed, but instead of dividing into twenty-four chromosomes, as in the somatic cell, the filament of the skein segments into only twelve loops. The cell thus provided with twelve chromosomes now enters upon the period of maturation, and is known as a spermatocyte of the first order, or a "mother cell" (O. Hert-

wig, 90). The division of these cells is heterotypic (*vid.* p. 64); the chromosomes split longitudinally and in such a way that the division begins at the crown of the loops, extending gradually toward their free ends. In this case the daughter chromosomes remain for some time in contact, so that the metakinetic figure resembles a barrel in shape. Finally, the daughter chromosomes separate and wander toward the poles. As soon as the daughter stars (diaster) are developed, the number of chromosomes is again doubled by a process of longitudinal division. The spermatocyte of the first order thus divides into two spermatocytes of the second order, or daughter cells (O. Hertwig, 90). The nuclei of the daughter cells now contain twenty-four chromosomes, as is the case in the somatic cell, and, without undergoing longitudinal splitting, the daughter chromosomes are distributed to the two nuclei of the spermatids. In other words, the latter contain only twelve chromosomes. The spermatozoa are formed from the spermatids by a rearrangement of the constituent elements of these cells. It may thus be said that even in the stage of the segmenting skein in the mother cells, the spermatocytes of the first degree contain twice as many chromosomes as a somatic cell, a condition which is first clearly seen in the stage of the diaster (here only an apparent duplication in the diaster stage). As a result, there is, first, a decrease in the double number of chromosomes found in the spermatocytes of the second degree to the normal number; second, a decrease in the number of chromosomes in the spermatocytes of the third degree (spermatids) to one-half the number present in a somatic cell, a condition probably due to the fact that here there is no stage of rest nor longitudinal splitting of the chromosomes. This is the general process in heterotypic division. Besides the heterotypic form, there occurs in the division of the spermatocytes another (homeotypic) form of karyokinetic cell-division. This differs from the heterotypic in the shortness of the chromosomes, the absence of the barrel phase, the late disappearance of the aster, and the absence of duplication in the chromosomes of the diaster. According to Meves (96), the spermatocytes of the first degree undergo heterotypic, those of the second degree, homeotypic division.

The spermatids develop into the spermatozoa, beginning immediately after the close of the second division of maturation. This process has been fully described for *salamandra maculosa* by Hermann, Flemming, Benda, and others, but need not engage our attention at this point beyond the statement that the chromatin of the nuclei of the spermatids develops into the heads of the spermatozoa, while the remaining structures are developed from the protoplasm. "The mature spermatozoon of the salamander represents a completely metamorphosed cell; in the course of its development no portion of the original cell is cast off" (Meves, 97).

Spermatogenesis in mammalia may be compared to the foregoing

process, with the exception that here the different stages are seen side by side in the seminiferous tubule and without any apparent sequence, making the successive stages more difficult to demonstrate. The various generations of cells form columns, and are arranged in such a manner that the younger are found near the lumen and the older close to the wall of the tubule. (Figs. 284 and

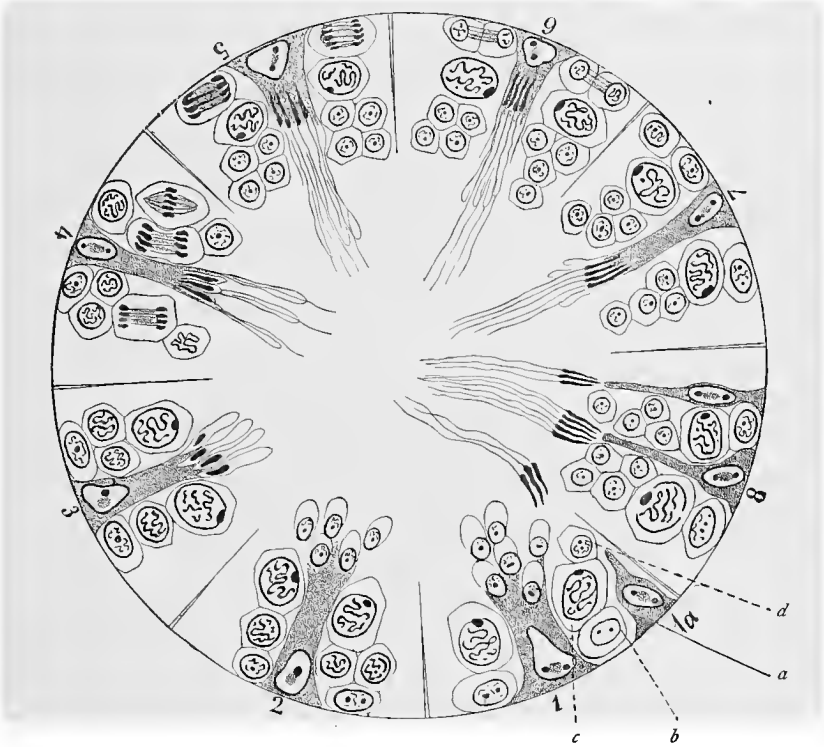


Fig. 284.—Schematic diagram of section through convoluted seminiferous tubule of mammal, showing the development of the spermatosomes. The number of chromosomes is not shown in the various generations of the spermatogenic cells. The progressive development of the spermatogenic elements is illustrated in the eight sectors of the circle: *a*, Young sustentacular cell; *b*, spermatogonium; *c*, spermatocyte; *d*, spermatid. In 1, 2, 3, and 4 the spermatids rest on the enlarged sustentacular cell in the center of the sector; on both sides of the sustentacular cells are the spermatogenic or mother cells in mitosis. In the sectors 5, 6, 7, and 8 spermatozoa are seen in advanced stages resting on the sustentacular cells, with new generations of spermatids on each side. [From Rauber (after Brown) with changes (after Hermann).]

285.) These columns are separated from each other by high sustentacular cells, or Sertoli's cells or columns. The metamorphosis of the cells into spermatids and spermatosomes is accomplished by the changing of the cells bordering upon the lumen and then of those in the deeper layers, etc., into spermatids and then into spermatosomes. During this process the spermatids arrange

themselves around the ends of Sertoli's columns, a phenomenon which was formerly regarded as representing a copulation of the two elements, although it was clearly understood that no real fusion or interchange of chromatin occurred, but that the close relations of the two were for the purpose of furnishing nourishment to the developing spermatosomes. The whole forms a spermatoblast of von Ebner. Since the spermatids lining the lumen are changed into spermatozoa, and the process is repeated in the cells of the deeper layers as they come to the surface, the result is that the entire column is finally used up. The compensatory elements are supplied by the proliferation of the adjacent spermatogonia. The resulting products again divide, and thus build up an entirely new generation of spermatogenic cells. Hand in hand with these progressive phenomena occurs an extensive destruction of the cells taking part in spermatogenesis. This is shown by the presence of so-called karyolytic figures in the cells, which later suffer complete demolition.

These developmental changes are represented in the preced-

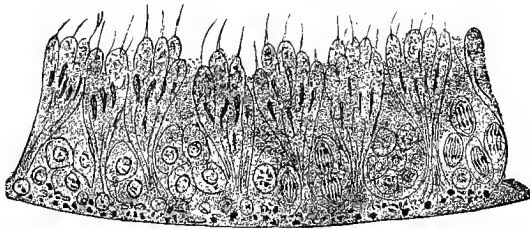


Fig. 285.—Section of convoluted tubule from rat's testicle (after von Ebner, 88). The pyramidal structures are the sustentacular cells, together with spermatids and spermatosomes. Between these are spermatogenic cells, some of which are in process of mitotic division. Below, on the basement membrane and concealing the spermatogonia, are black points representing fat-globules, a characteristic of the rat's testicle. Fixation with Flemming's fluid.

ing schematic figure (Fig. 284), and may in part be observed in figure 285.

In mammalia it has been possible to trace the development of the spermatids into the spermatosomes. These phenomena have been studied and described by numerous writers, and although many conflicting views have been expressed, the essential steps of this process seem quite clearly established. The account here given is based in part on the recent observations of v. Lenhossék and the observations of Benda. Before considering the method of development of the spermatosomes from the spermatids, a few words concerning the structure of the latter may be useful. The sharply outlined spermatid possesses a slightly granular protoplasm and a round or slightly oval nucleus with a delicate chromatic network. In the protoplasm there is found a sharply defined globule, known as the sphere or sphere substance, which lies near the nucleus and

presents throughout a nearly homogeneous structure. This substance is first noticed in the spermatocytes, disappears during the cell-divisions resulting in the spermatids, and reappears in the latter. In the protoplasm of the spermatid, lying near the nucleus, there is further found a small globular body, the chromatoid accessory nucleus of Benda, smaller than the sphere and staining very deeply in Heidenhain's hematoxylin. A true centrosome may also be found in the spermatid.

The nucleus of the spermatid develops into the head of the spermatosome, during which change the originally spheric nucleus becomes somewhat flattened and at the same time assumes a denser structure and moves toward that portion of the spermatid pointing away from the lumen of the seminiferous tubule. Accompanying these changes in the nucleus, marked changes are observed in the shape and structure of the sphere, which marks the position of the future anterior end of the head of the spermatosome, and applies itself to the nucleus on the side pointing away from the lumen of the tubule. In this position it differentiates into an outer clear homogeneous zone and a central portion which stains more deeply and to which *v. Lenhossék* has given the name akrosome. From these structures are developed the head-cap and the lance of the spermatosomes, which differ in shape and relative size in the spermatosomes of the different vertebrates. Recent investigation seems to establish quite clearly that the axial thread of the tail is developed from the centrosome (from the larger, if two are present), which is situated at some distance from the nucleus. Soon after the beginning of the development of the axial thread the centrosome wanders to the posterior part of the future head of the spermatosome (the pole of the nucleus opposite the head-cap) and becomes firmly attached to the nuclear membrane in this position (observations made on the rat by *v. Lenhossék*, and on the salamander by *Meves*). The middle piece and the undulating membrane, it would appear, are differentiated from the protoplasm, although the question of the mode of their development is still open to discussion. The chromatoid body assumes a position near the axial thread at its junction with the cell membrane; its fate has not, however, been fully determined.

According to *Hermann* (97), the end-piece in the selachia is derived from the centrosome, the ring-shaped body from the invaginated half of the intermediate body of the spermatid formed during the last spermatocytic division, and the axial thread from filaments of the proximal half of the central spindle. The lance, according to him, represents a modified portion of the nuclear membrane of the spermatid.

For further particulars regarding spermatogenesis see the investigations of *v. la Valette* *St. George*, 67-87; *v. Brunn*, 84; *Biondi*, *Benda*, *Meves*, and *v. Lenhossék*.

## TECHNIC.

278. The ovaries of the smaller animals are better adapted to study than those of the human being, since the former are more easily fixed.

279. The germinal epithelium and its relations to the egg-tubes of Pflüger are best studied in the ovaries of young or newly born animals—cats, for instance, being especially well adapted to this purpose.

280. Normal human ovaries are usually not easily obtainable. Human ovaries very often show pathologic changes, and in middle life frequently contain but few follicles.

281. Fresh ova may be easily procured from the ovaries of sheep, pig, or cow in the slaughter-houses. On their surfaces are prominent transparent areas—the larger follicles. If a needle be inserted into one of these follicles and the liquor folliculi be caught upon a slide, the ovum may as a rule be found, together with its corona radiata. That part of the preparation containing the ovum should be covered with a cover-glass under the edges of which strips of cardboard are laid. If no such strips are employed, the zona pellucida of the ovum is likely to burst in the field of vision, giving rise to a funnel-shaped tear. These tears have often been pictured and described as preformed canals (micropyles).

282. The best fixing fluid for ovarian tissue is Flemming's or Hermann's (*vid.* T. 17, 18), either of which may be used for small ovaries or pieces of large ovaries; safranin is then used for staining. Good results are also obtained with corrosive sublimate (staining with hematoxylin according to M. Heidenhain), and also with picric acid (staining with borax-carmin).

283. The treatment of the Fallopian tubes is the same as that of the intestine; in order to obtain cross-sections of a tube it is advisable to dissect away the peritoneum near its line of attachment and then distend the tube before fixing. It is instructive to dilate the tube by filling it with the fixing agent, thus causing many of the folds to disappear.

284. No special technic is necessary in fixing the uterus and vagina. The epithelium is, however, best isolated with one-third alcohol (*vid.* T. 128).

285. Seminal fluid to which normal salt solution has been added may be examined in a fresh condition. The effect upon the spermatozoa of a very dilute solution of potassium hydrate (1% or weaker) or of a very dilute acid (acetic acid) is worth noticing. The spermatozoa of salamandra maculosa show the different structural parts very clearly (lance, undulating membrane, marginal thread, etc.). In macerated preparations (very dilute chromic acid), or in those left for some time in a moist chamber, the fibrillar structure of the marginal and axial threads may be seen quite distinctly. The spermatozoa may also be examined in the form of dry preparations (treatment as for blood), stained, for instance, with safranin. Osmic acid, its mixtures, and osmic vapors are useful as fixing agents, certain structures being better brought out so than by employing the dry methods.

286. In examining the testicle (spermatogenesis) it is advisable to begin with the testis of the salamander, which does not show such complicated structures as do the testes of mammalia. Here also either Flemming's or Hermann's fluid may be used as a fixing agent, the latter being

followed by treatment with crude pyroligneous acid (*vid.* T. 18). For the salamander Hermann recommends a mixture composed of 1% platinum chlorid 15 c.c., 2% osmic acid 2 c.c., and glacial acetic acid 1 c.c., and for mammalia the same solution with double the amount of osmic acid. This fluid is allowed to act for some days, the specimen then being washed for twenty-four hours in running water and carried over into alcohols of ascending strengths. Paraffin sections are treated as follows: Place for from twenty-four to forty-eight hours in safranin (safranin 1 gm. is dissolved in 10 c.c. of absolute alcohol and diluted with 90 c.c. of anilin water; *vid.* T. 119). After decolorizing with pure or acidulated absolute alcohol the sections are placed for three or four hours in gentian-violet (saturated alcoholic solution of gentian-violet 5 c.c. and anilin water 100 c.c.), and are then placed for a few hours in iodo-iodid of potassium solution until they have become entirely black (iodin 1, iodid of potassium 2, water 300); finally, they are washed in absolute alcohol, until they become violet with a dash of brown. The various structures appear differently stained: for instance, the chromatin of the resting nucleus and of the dispirem, bluish-violet; the true nucleoli, red; while, on the other hand, in the aster and diaster stages the chromatin stains red.

It is of especial importance that small testicles should not be cut into pieces before fixing, as this causes the seminal tubules to swell up and show marked changes, even in regions at some distance from the cut (Hermann, 93, I).

The treatment of the remaining parts of the male reproductive organs requires no special technic.

## VI. THE SKIN AND ITS APPENDAGES.

### A. THE SKIN (CUTIS).

THE skin consists of two intimately connected structures—the one, of mesodermic origin, is the true skin, corium or *dermis*; the other, of ectodermic origin, is the *epidermis* or cuticle. The superficial layer of the corium is raised into ridges and papillæ which penetrate into the epidermis, the spaces between the papillæ being filled with epidermal elements. Thus, the lower surface of the epidermis is alternately indented and raised into a system of furrows and elevations corresponding to the molding of the corium.

In the epidermis two layers of cells may be observed—the *stratum Malpighii*, or stratum germinativum (Flemming), and the horny layer, or stratum corneum. According to the shape and characteristics of its cells, the stratum germinativum may also be divided into three layers—first, the deep or basal layer, consisting of columnar cells resting immediately upon the corium; second, the middle layer, consisting of polygonal cells arranged in several strata, the number of the latter varying according to the region of the body; and third, the upper layer, or *stratum granulosum*, which is composed, at most, of two or three strata of gradually flattening cells characterized by their peculiar granular contents.

All these cell layers consist of prickly cells, and for this reason the stratum Malpighii is sometimes known as the stratum spinosum. When these cells are isolated by certain methods, their surfaces are seen to be provided with short, thread-like processes. In section the cells appear to be joined together by their processes. Since it has been proved that the processes of adjacent cells do not lie side by side, but meet and fuse, they must be regarded as belonging alike to both cells. Between the fused processes, which are known as *intercellular bridges*, there exists a system of channels which is in communication with the lymphatic system of the corium. The prickles just mentioned are variously regarded by different investigators; some considering them to be exclusively protoplasmic

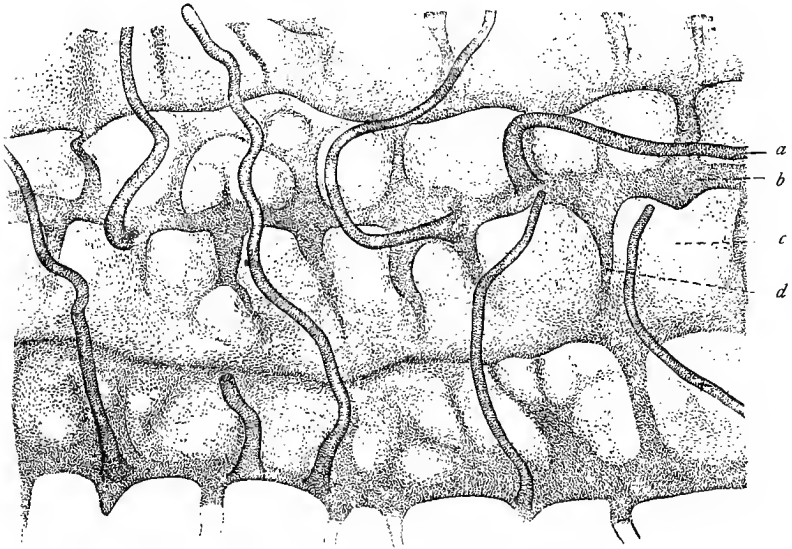


Fig. 286.—Under surface of the epidermis, separated from the cutis by boiling. The sweat-glands may be traced for a considerable part of their length;  $\times 40$ : *a*, Sweat-gland; *b*, longitudinal ridge; *c*, depression; *d*, cross-ridge.

processes of the cells, others regarding them as derived from the membranes of the cells composing the stratum Malpighii. Ranvier and others ascribe a fibrillar structure to the peripheral portion of the cellular protoplasm, and, according to them, these fibrillæ, surrounded by a small quantity of indifferent protoplasm, form the processes. Ranvier has also shown that such fibrillæ may extend from one cell around several others before reaching their ultimate destination in other cells at some distance. (Fig. 288.) The cells of the stratum granulosum contain peculiar deposits of a substance to which Waldeyer has given the name of *keratohyalin*. This substance occurs in the form of irregular bodies varying in size and imbedded in the protoplasm. The nuclei of such cells always

show degenerative processes, which are possibly due to the formation of the keratohyalin (Mertsching, Tettenhamer). These karyolytic figures and keratohyalin possess in common many apparently identical microchemic peculiarities, and it is very probable that karyolysis and the formation of keratohyalin are processes originally very closely allied—*i. e.*, that the keratohyalin is derived from the fragments of the dying nucleus.

The stratum corneum forms the outer layer of the epidermis and presents, as a rule, a somewhat differentiated lower stratum. This

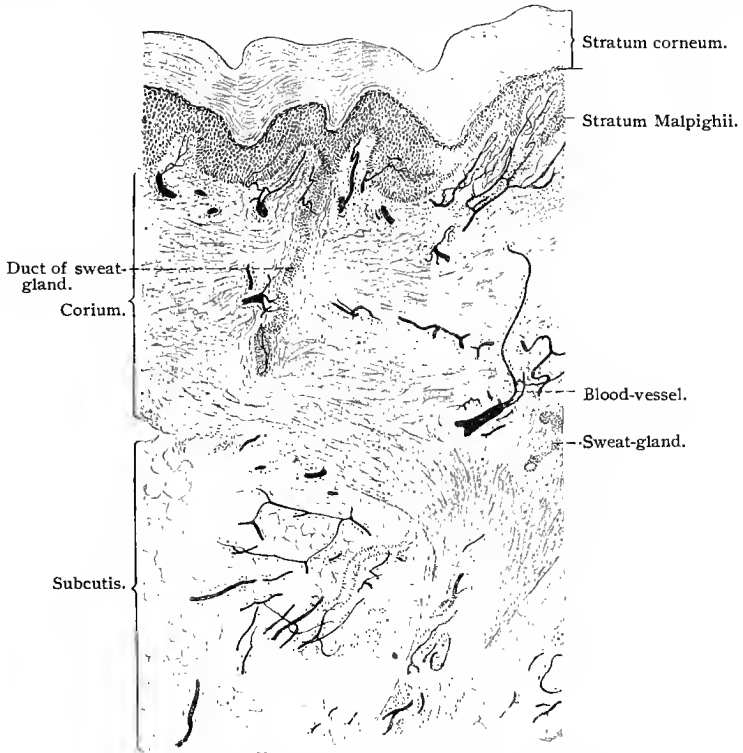


Fig. 287.—Cross-section of skin of child, with blood-vessels injected;  $\times 30$ .

latter is more especially noticeable in those regions in which the stratum corneum is highly developed, and is known as the *stratum lucidum*. It is quite transparent, this property being due to the presence in its cells of a homogeneous substance, the *eleidin*. Eleidin is in all probability a derivative of the more solid keratohyalin of the stratum granulosum. The cells of the stratum corneum are more or less flattened and cornified, especially at their periphery. This applies more particularly to the superficial cells. In the interior of each cell a more or less degenerated nucleus may be seen, but otherwise its contents are homogeneous, or, at most, arranged

in concentric lamellæ (Kölliker, 89). Here and there between the cornified cells structures may be seen which probably represent the remains of intercellular bridges. The thickness of the epidermis varies greatly according to the locality, and is directly proportionate to the number of its cell layers. As a rule, the stratum Malpighii is thicker than the stratum corneum, but in the palm of the hand and the sole of the foot the latter is considerably the thicker.

The various layers of the epidermis are in close genetic relationship to one another. The constant loss to which the epidermis is subjected by desquamation is compensated by a continuous upward pushing of its lower elements; cell-proliferation occurs in the basal cells and adjacent cellular strata of the stratum germinativum (Malpighii), where the elements are often seen in process of mitotic division. The young cells are gradually pushed outward, and during their course assume the general characteristics of the elements

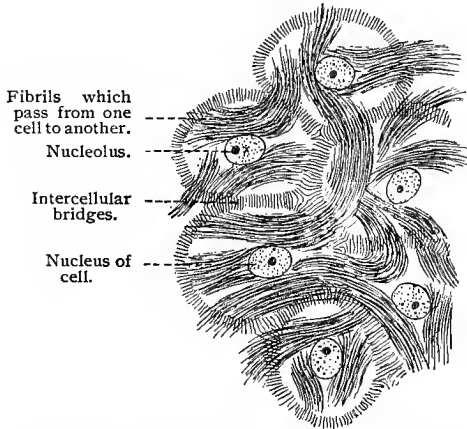


Fig. 288.—Prickle cells from the stratum Malpighii of man;  $\times 480$ .

composing the layers through which they pass. For instance, such a cell changes first into a cell of the stratum germinativum; then, when it commences the formation of keratohyalin, into a cell of the stratum granulosum; later, into a cell of the stratum lucidum, and finally into an element of the stratum corneum, where it loses its nucleus, cornifies, and at last drops off.

The mesodermic portion of the skin, the *corium*, consists of a loose, subcutaneous connective tissue containing fat, the subcutaneous layer, with the panniculus adiposus, and of the true skin, or corium proper. The amount of adipose tissue in the subcutaneous layer is subject to great variation; there are, however, a few regions in which there is normally very little or no fat (external ear, eyelids, scrotum, etc.). To the subcutaneous connective tissue is due the mobility of the skin. The corium may be compared to the mucosa of a mucous membrane, and consists of two layers—of a deeper and looser *pars reticularis*, and of a superficial *pars papillaris* supporting the papillæ. The transition from the one to the other is very gradual. Elastic fibers are present in the connective tissue of both layers.

The *pars reticularis* is made of bundles of connective-tissue fibers arranged in a network, nearly all of the strands of which have a direc-

tion parallel with the surface of the skin and are surrounded by a reticulum of rather coarse elastic fibers. In that portion of the pars papillaris bordering upon the epidermis, the interlacing strands of connective tissue, as well as the surrounding reticulum of elastic fibers, are finer, so that the whole tissue is denser. This stratum supports the papillæ—knob-like or conical elevations of still denser tissue ending in one or more points. We accordingly speak of simple or compound papillæ. These structures are especially numerous and well developed in the palm of the hand and sole of the foot, where they are from  $110\ \mu$  to  $220\ \mu$  long. Here they rest upon ridges of the corium, which are nearly always arranged in double rows. According to whether the papillæ contain blood-vessels alone, or special nerve-endings also, they are known as *vascular* or *tactile* papillæ.

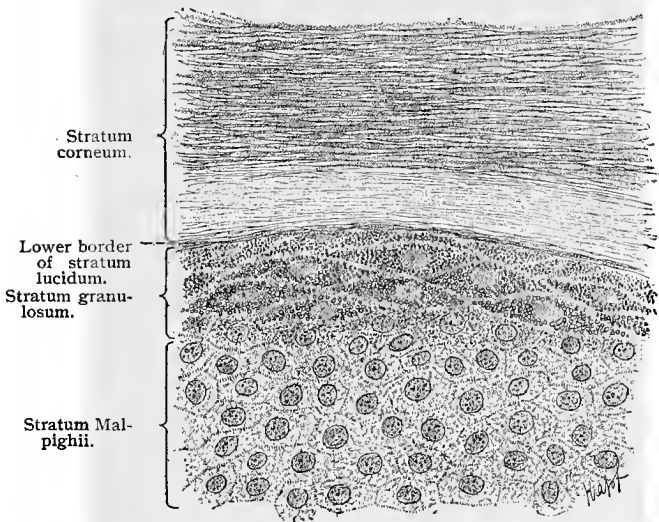


Fig. 289.—Cross-section of human epidermis; the deeper layers of the stratum Malpighii are not represented;  $\times 750$ .

The smallest papillæ are found in the mammæ and scrotum—from  $30\ \mu$  to  $50\ \mu$  long. The surface of the pars papillaris is covered by an extremely delicate membrane—the basement membrane. According to most authors, the basal cells of the epidermis are simply cemented to this structure. Others believe that the epithelial cells are provided with short basilar processes which penetrate into the basement membrane and meet here with similar structures from the connective-tissue cells of the corium. This would give the basement membrane a fibrillar structure (Schuberg).

The subcutaneous layer contains numerous more or less vertical strands of connective tissue, containing numerous large elastic-tissue fibers and joining the stratum reticulare of the corium to the

superficial fascia of the body or underlying structure, whatever that may be. These strands are the *retinacula cutis*, and inclose in their meshes masses of fatty tissue which form the *panniculus adiposus*. The latter varies greatly in thickness in different parts of the body. The vertically arranged cords of connective tissue are accompanied by blood-vessels, nerves, and the excretory ducts of glands.

Smooth muscle-fibers are also present in the skin, and around the hair follicles are grouped into bundles. Nearly continuous layers of smooth muscle tissue are found in the subcutaneous layer of the scrotum (forming here the *tunica dartos*), in the perineum, in the areolæ of the mammæ, etc. In the face and neck striated muscle-fibers also extend outward into the corium.

Even in the white race certain regions of the epidermis always contain pigment—as, for instance, the areolæ and mammillæ of the

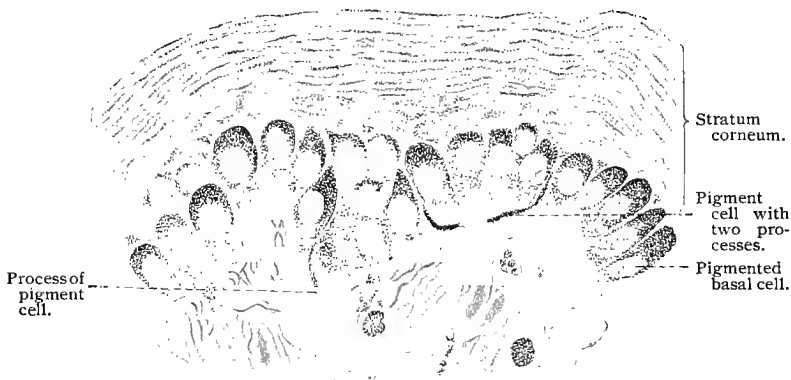

Fig. 290.—Cross-section of negro's skin, showing the intimate relationship of the pigment cells of the corium to the basilar cells of the epidermis. The latter are more deeply pigmented at their outer ends. The pigment granules may be traced into the outermost layers of the stratum corneum;  $\times 525$ .

mammary glands, the scrotum, labia majora, around the anus, etc. In these regions the epithelial cells and the connective-tissue cells of the pars papillaris corii contain a variable number of small pigment granules. The latter occur chiefly in the basal cells of the epidermis and diminish perceptibly in the cells of the overlying layers, so that in those of the stratum corneum few, if any, are left. In negroes and other colored races the deep pigmentation is due to a similar distribution of the pigment granules in the entire epidermis; but even here the pigmentation decreases toward the surface, although the uppermost cells of the stratum corneum always contain some pigment. The nuclei of the cells are always free from the coloring-matter. The question as to the origin of the pigment is as yet unsolved. This much is known: that in those regions where pigment is present certain branched and deeply pigmented connec-

tive-tissue cells are found immediately beneath the epidermis, sending out processes which may be traced outward between the cells of the stratum Malpighii (Aeby). This fact has led some authors to believe that the connective tissue is in reality the source of the pigment, and that by some unknown process the latter is taken up and conveyed to the cells of the epidermis. This theory would preclude a direct production of pigment granules in the epidermal cells. But although it can not be denied that the pigment may be derived from the connective tissue, it is hardly logical to assume *a priori* that epithelial cells are not capable of pigment production, since, in other regions of the body, pigment formation may be observed in cells of undoubted epithelial origin, as, for instance, in ganglion cells and in the pigment epithelium of the retina. An interesting proof that the processes of pigmented connective-tissue cells actually penetrate the epidermis is afforded by the case reported by Karg, of transplantation of a piece of skin from a white man to a negro. After some time the piece of white skin became pigmented. Reinke has demonstrated that the pigment in certain cells is in combination with certain definite bodies. The latter have been given the botanical name of *trophoplasts*. If the pigment be removed, colorless trophoplasts are left. They may be tinged with certain stains. In the epidermis of the white race trophoplasts are also constantly present, although they are only slightly or not at all pigmented (Barlow).

The following may be said concerning the *vascular system* of the skin: The arteries which supply the skin with nutriment penetrate the corium and form a characteristic network in its lowest stratum. They also anastomose freely in the fascia and the subcutaneous layer. From this plexus branches pass outward to form a second or subpapillary plexus. From the latter, branches are again given off which, without further anastomoses, pass along beneath the rows of papillæ and supply each separate papilla with capillary twigs. These in turn pass over into venous capillaries which unite and also form several plexuses, corresponding in general to those of the arterial system. The uppermost venous plexus lies beneath the papillæ, each venule corresponding to a single row of papillæ and anastomosing with its neighbors. The second plexus is found immediately beneath the first, the third in the lower portion of the corium, and the fourth at the junction of the cutis and subcutis. Near the middle of the subcutis the arteries show a circular musculature, but the veins are already thus provided in the network between the cutis and subcutis, where they also seem to possess valves. As already stated, the subcutaneous fat is divided into lobes by transverse and longitudinal bundles of connective tissue; a second system of bundles midway between the cutis and fascia separates the panniculus adiposus into an upper and a lower layer. The former is supplied by direct arterial branches; the latter, by branches passing backward from the cutaneous network. Those regions which are subjected to great external pressure are supplied by

a greater number of afferent vessels the caliber of which is increased. In regions where the skin is very mobile the arteries are greatly convoluted. All these vascular peculiarities are present in the newborn (Spalteholz).

The *lymph-vessels* of the true skin are also distributed in two layers—a deep and wide-meshed plexus in the subcutis, and a superficial narrow-meshed plexus immediately beneath the papillæ. Into the latter empty the lymph-vessels coming from the papillæ. After treating the skin by certain methods, a fine precipitate may be noticed here and there in the papillary region of the corium, a proof that lymph clefts are present. These are regarded as the beginnings of the cutaneous lymphatic system. They may also be

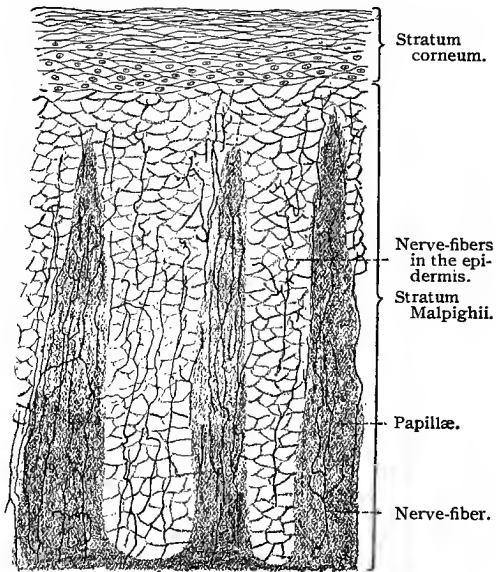


Fig. 291.—Nerves of epidermis and papillæ from ball of cat's foot ;  $\times 75$ .

traced into the epithelium, where they are in direct communication with the interspinal spaces between the epithelial cells (Unna). Cells are also met with in the interspinal spaces of the epidermis; these are migratory cells, or cells of Langerhans.

The skin owes its great sensitiveness to the numerous *nerves* and special *nerve-endings* present, not only in the epithelium, but also in the corium and subcutis. In certain regions of the skin the nerves have been traced into the epithelium. In the finger-tip, for instance, numerous nerves are seen in the epidermis, where they branch and end in telodendria with or without small terminal swellings. There is no direct communication between the terminal

nerve filaments and the epithelial cells. (Fig. 291.) In certain peculiarly sensitive regions, as the end of the pig's snout, the nerve-fibers end in distinct saucer-like discs (tactile menisci) which, as a rule, clasp the lower ends of the basal Malpighian cells.

The special sensory nerve-endings are situated in the corium and subcutis. Of these, we may mention, the tactile corpuscles Meissner, the end-bulbs of Krause, the Pacinian corpuscles, Ruffini's nerve-endings, and the Golgi-Mazzoni corpuscles. All these special sensory nerve-endings with the exception of the two last mentioned have been discussed in a former chapter (p. 154). Meissner's tactile corpuscles are situated in the tactile papillæ of the true skin. They are especially numerous in the hand and foot. In the distal phalanx of the index-finger every fourth papilla is a tactile papilla, containing one or sometimes two corpuscles of

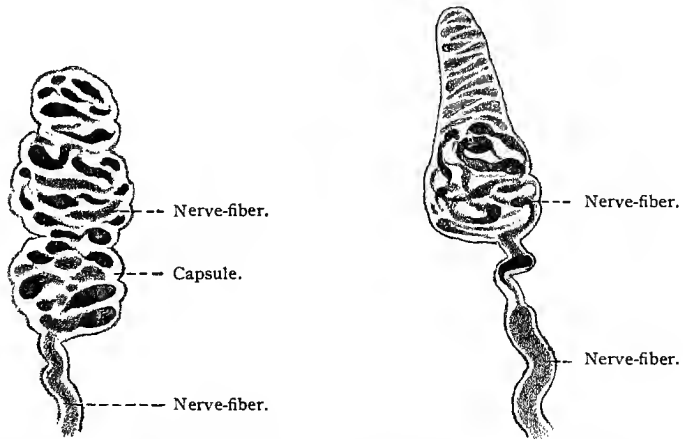


Fig. 292.—Meissner's corpuscle from man ;  $\times 750$ . Technic No. 295.      Fig. 293.—Meissner's corpuscle from man ;  $\times 750$ . Technic No. 295.

Meissner. They are, however, not nearly so numerous in other parts of the hand or in the foot. These corpuscles are further found on the dorsal surface of the hand and volar surface of the forearm, in the nipple and external genitals, in the eyelids (border), and in the lips. In figures 292 and 293 are shown two Meissner's corpuscles, giving the appearance presented by these end-organs when not stained with special reference to nerve terminations. For the latter see figure 132.

The Krause's end-bulbs, both spheric and cylindric, are, as a rule, situated a short distance below the papillary layer, although they are frequently found in the papillæ. They occur in man in the conjunctiva, lips, and external genitals, and in the mucous membranes previously mentioned (p. 154). See page 154 and figure 131 for their structure.

In the palm of the hand and sole of the foot, the subcutaneous connective tissue contains numerous Pacinian corpuscles. They occur also along the nerve-fibers of the joints and in the periosteum of the extremities. (See Fig. 135.)

Very recently Ruffini demonstrated in the human corium the existence of peculiar nerve end-organs, which consist of a connective-tissue framework supporting a rich arborization of telodendria. They occur side by side with the Pacinian corpuscles and in apparently equal numbers. These nerve terminations resemble in many respects the neurotendinous spindles (see Fig. 140), although they present certain structural differences. Instead of intrafusal tendon fasciculi, the Ruffini end-organ is composed of white fibrous and elastic tissue. In this end-organ the medullated nerves make long and tortuous turns before becoming nonmedullated, and the

terminations of these nerve-fibers occupy the whole of the cross-section.

The Golgi-Mazzoni corpuscle resembles in structure the Pacinian corpuscle, although it possesses fewer lamellæ and a relatively larger core, and the nerve-fibers terminating therein are more extensively branched than in the Pacinian corpuscle. Ruffini has found these nerve-endings in the subcutaneous tissue of the fingertips.

The blood-vessels of the skin are richly supplied with vasomotor nerves, which terminate in the non-striated muscle of the vessel walls.

These vasomotor nerve-fibers are neuraxes of sympathetic neurones.

In aquatic birds, and more especially in ducks, the waxy skin of

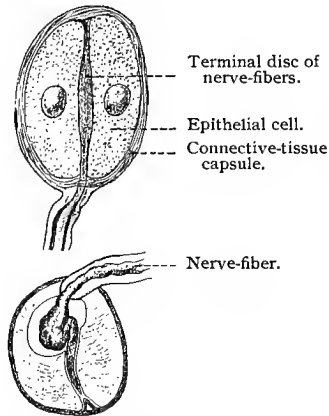


Fig. 294.—Grandry's corpuscles from bill of duck;  $\times 500$ . Technic No. 296.

the beak and the cornified portion of the tongue contain the so-called corpuscles of Herbst, which resemble the Pacinian corpuscles in general structure, but have cubical cells in the core. In the same tissues are also found the corpuscles of Grandry,  $60 \mu$  long and  $40 \mu$  broad. They consist of a thin connective-tissue capsule, containing two or three large cells. The nerve-fiber retains its medullary sheath for some distance within the capsule. The axis-cylinder ends in discs situated between the cells inclosed by the capsule.

## B. THE HAIR.

The hair and nails are regarded as special differentiations of the skin. Hair is found distributed over almost the entire extent of the skin, varying, however, in quantity and arrangement in different

regions. None whatever is present in the palm of the hand and sole of the foot. In the third fetal month small papillary elevations of the skin are seen to develop in those areas in which the hairy growth later appears. Under each of these elevations there occurs a proliferation of the cells of the Malpighian layer downward into the corium. Although the elevations soon disappear, the epithelial ingrowth continues and finally forms the *hair germ*. This is soon surrounded by a connective-tissue sheath from the corium, in which two layers may be distinguished. At the lower end of the hair germ the corium is pushed upward, forming a papilla which penetrates into the thickened bulb of the germ. This is called the *hair papilla*. In the mean time the hair germ itself is undergoing marked differentiation. An axial portion, forming later the hair and inner root-sheath, and a peripheral, constituting later the outer root-sheath, are developed. From the latter are derived also the first traces of the sebaceous glands, which in the adult state are in close relationship to the hair and empty their secretion into the space between the hair and its sheath. As soon as the various layers of the hair are complete it grows outward, breaking through the overlying layers of the epidermis.

The visible portion of the hair is called the *hair shaft*, and that portion below the skin is the *hair root*. The lower portion of the hair resting upon the papilla is known as the *hair bulb*, and the sheaths encircling the root and bulb are called the *root-sheaths*, the entire structure constituting the *hair follicle*.

The adult hair is covered by a thin *cuticle*, consisting of overlying plate-like cells, 1.1  $\mu$  thick, most of which possess no nuclei. Beneath the cuticle is the *cortical layer*, composed of several strata of long, flattened cells from 4.5  $\mu$  to 11  $\mu$  broad and provided with nuclei. These are also known as the cortical fibers of the hair. Upon treatment with ammonia the fibers separate into delicate fibrils, the hair fibrils (Waldeyer, 82). Scattered between and within the cells of the cortical layer are varying quantities of pigment granules. The axial region of the hair is occupied by the *medullary substance*, from 16  $\mu$  to 20  $\mu$  in diameter. This may be lacking; but if present, consists of from 2 to 4 strata of polygonal, nucleated and pigmented cells. The hair shaft often contains air vesicles.

The *inner root-sheath* consists of three concentric layers—first, of an outer single layer of clear nonnucleated cells, the so-called *layer of Henle*; second, of a thicker middle layer, made up of two strata of nucleated cells containing eleidin, the *layer of Huxley*; and, third, of an *inner cuticle*, bordering upon the hair.

The *outer root-sheath* is made up of elements from the stratum germinativum. Here we have to do with prickle cells, surrounded by an outer layer of columnar elements. The connective-tissue portion of the hair follicle is composed of an outer, looser layer of longitudinal fibrous bundles; of an inner, compacter layer of circu-

lar fibers ; and of an innermost well-developed basement membrane—the *glassy membrane*.

At a certain distance above the root bulb all the layers of the

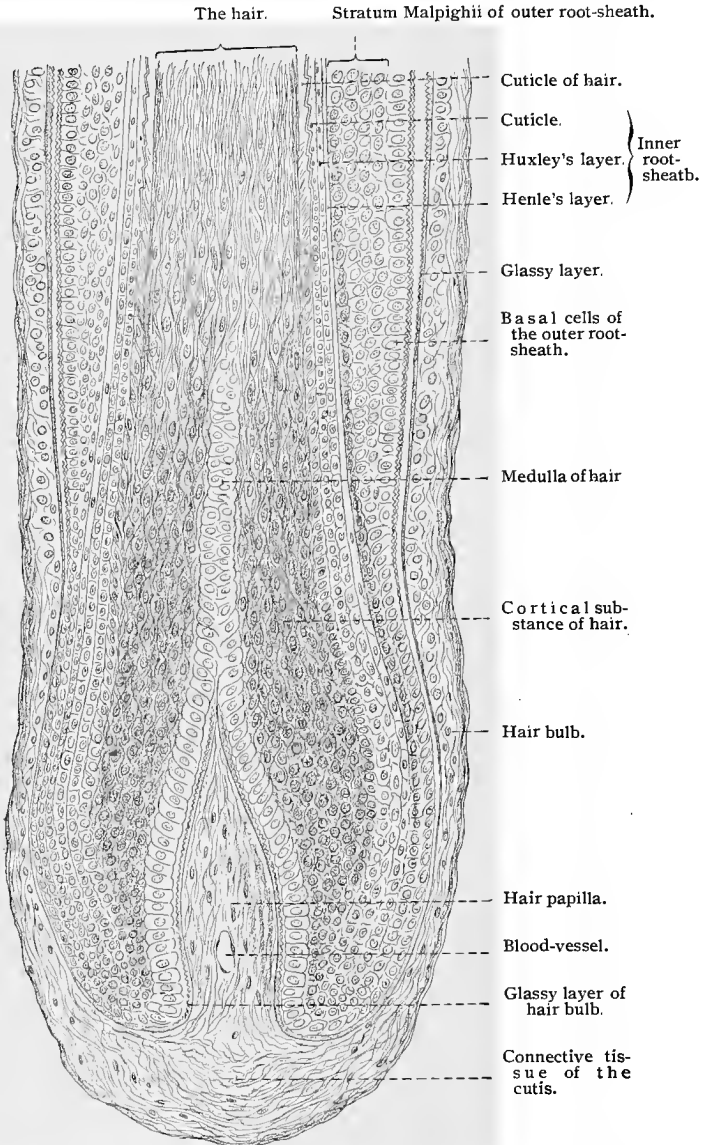


Fig. 295.—Longitudinal section of human hair and its follicle ; X about 300.

epithelial portion of the hair follicle are well developed and distinct from each other. This condition changes toward the hair papilla

as well as toward the hair shaft. Below, in the region of the thickened hair bulb, the root-sheaths begin to lessen in thickness, their layers becoming more and more indistinct toward the base of the hair papilla. Finally, all differentiation is lost in the region where they encircle the neck of the papilla. Toward the shaft of the hair, the root-sheath also undergoes changes. In the region into which the sebaceous glands empty, the inner root-sheath disappears, while the outer becomes continuous with the stratum germinativum of the epidermis; the outer layers of the latter—the stratum granulosum, stratum lucidum, and stratum corneum—push downward between the outer root-sheath and the hair to the openings of the sebaceous glands.

Regarding the *growth of the hair*, two theories are prevalent.

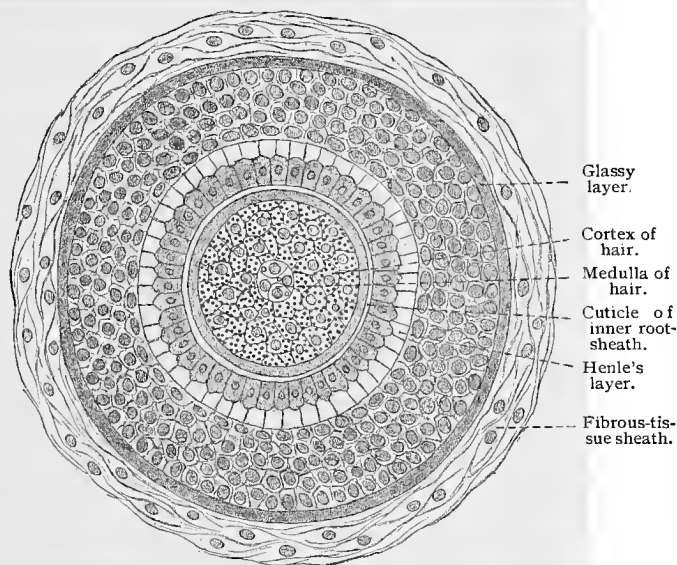


Fig. 296.—Cross-section of human hair with its follicle;  $\times$  about 300.

The one theory assumes that the elements destined to form the epithelial root-sheaths are derived from the epidermis by a constant process of invagination. The component parts of the hair would thus be continuous with the layers of the root-sheaths, and consequently with those of the epidermis. Thus the basal cells of the external root-sheath would extend over the papilla, and be continuous with the cells of the medulla of the hair (these relations are especially well defined in the rabbit), and the stratum spinosum (middle layer of stratum Malpighii) of the outer root-sheath would be continuous with the cortical substance of the hair. According to this theory also, the layer of Henle would correspond to the stratum lucidum of the epidermis, and at the base of the hair

would become its cuticle, while the layer of Huxley would form the cuticle of the inner root-sheath (Mertsching). The other theory assumes that the hair is derived from a matrix, consisting of proliferating cells situated on the surface of the papilla. From these germinal cells would be derived the medullary and cortical substance of the hair, its cuticle, and the inner root-sheath (Unna).

The *shedding of hair* is common to all mammalia, a phenomenon occurring periodically in the majority of species. In man the process is continuous. Microscopic examination shows that the hair destined to be shed becomes loosened from its papilla by a cornification of the cells of its bulb. At the same time the cortical portion of the hair bulb breaks up into a brush-like mass. Such hairs are called *bulb hairs*, in contradistinction to papillary hairs. In the

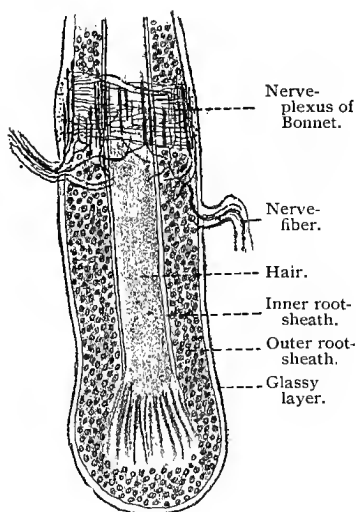


Fig. 297.—Longitudinal section through hair and hair follicle of cat;  $\times 160$ . Technic No. 291.

region of the former papilla there arises, by a proliferation of the external root-sheath, a bud which grows downward, from which a new hair with its sheaths and connective-tissue papilla is developed. The result is that the developing new hair gradually pushes the old hair outward until the latter finally drops out. The exact details of this process have given rise to considerable discussion (*vid.* Götte and Stieda, 87).

Adjacent to the hair follicles are bundles of smooth muscle-fibers, known as the *arrectores pilorum*. They originate from the papillary layer of the corium and extend to the lower part of the connective-tissue sheath of the hair follicles. In their course they not infrequently encircle the sebaceous glands of the follicle. Since

the hair follicles have a direction oblique to the skin surface, forming with it an acute and an obtuse angle, and since the muscle is situated within the obtuse angle, its function may easily be conceived as being that of an erector of the hair. The hair papillæ are very vascular.

The *nerve-fibers* of the hair follicles have recently been studied by a number of investigators, with both the Golgi and the methylene-blue methods. It has been shown that the hair follicles receive their nerve supply from the nerve-fibers which terminate in the immediate skin area. Each follicle receives, as a rule, only one nerve-fiber, which reaches the follicle a short distance below the mouth of the sebaceous gland. The nerve-fiber, on reaching the

follicle, loses its medullary sheath and divides into two branches, which surround it in the form of a ring. From this complete or partial ring of nerve-fibers numerous varicose fibers proceed upward parallel to the axis of the follicle for a distance about equal to the cross-diameter of the follicle, to terminate, it would seem, largely outside of the glassy layer (Retzius). In certain mammalia the nerve-fibers end in tactile discs, found in the external root-sheaths of the so-called tactile hairs. The muscles of the hairs receive their innervation through the neuraxes of sympathetic neurones, which reach the periphery from the chain ganglia through the gray rami communicantes. These nerves are known as *pilomotor nerves*, and when stimulated, excite contraction of the erector muscles of the hairs, causing these to assume an upright position and producing the appearance termed goose skin, or *cutis anserina*. Langley and Sherrington have made interesting and important observations on the course and distribution of the pilomotor nerves.

### C. THE NAILS.

The nails are a peculiar modification of the epidermis. The external arched portion is called the *body of the nail*; that area upon

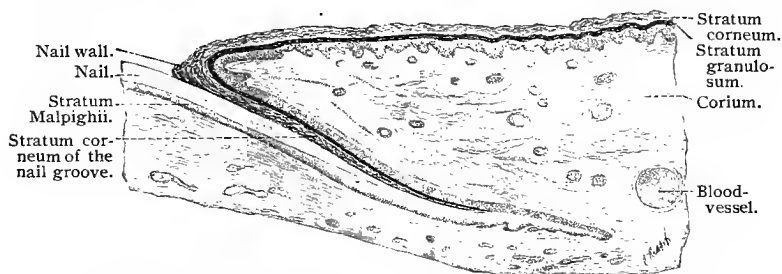


Fig. 298.—Longitudinal section through human nail and its nail groove (sulcus);  $\times 34$ .

which the latter rests, the *nail bed*, or *matrix*; and the two folds of epidermis which overlap the nail, the *nail walls*. The groove which exists between the nail wall and nail bed is known as the *sulcus of the matrix*, and the proximal imbedded portion of the nail as the *nail root*, since all growth of the nail takes place in this region. The nail bed consists of the corium, which is here made up of a dense felt-work of coarse connective-tissue fibers. Immediately beneath the nail the corium is raised into a number of more or less symmetric longitudinal ridges, which again become continuous with the connective-tissue papillæ of the skin at the line where the nail projects beyond its bed.

The depressions between the ridges are occupied by epidermal cells, which also form a thin covering over the ridges themselves.

These cells correspond here to the basilar layer of the stratum Malpighii. The stratum granulosum is not uniformly present, although occurring as isolated areas in the region of the nail root and *lunula*, the white area of demilunar shape at the proximal portion of the nail. Unna has demonstrated that the pale color of the lunula and root of the nail is due to the presence of keratohyalin. Formerly, this peculiarity was attributed to a difference in the distribution of the vessels in the various portions of the nail bed. The body of the nail, with the exception of the lunula, is transparent—a condition which may be explained by the fact that the elements of the nail correspond to those of the stratum lucidum. As a consequence, the vessels of the matrix shine through, except at the lunula, where the keratohyalin granules render the nail opaque.

The nail itself consists of elements homologous to those of the stratum lucidum. They are flat, transparent cells, closely approximated, and all contain nuclei. The cells overlap each other like tiles, and are so arranged that each succeeding lower layer projects

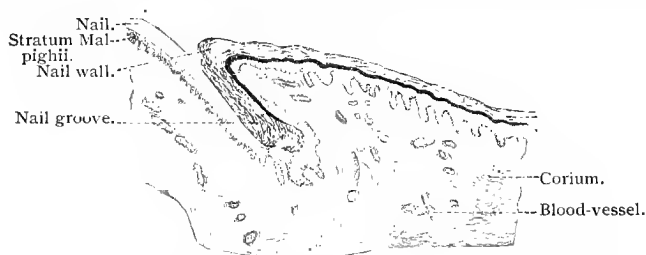

Fig. 299.—Transverse section through human nail and its sulcus;  $\times 34$ .

a little further distalward than the preceding. At the period when the nails are formed, about the fourth month of fetal life, sulci are already present. The first trace of the nail is seen as a marked thickening of the stratum lucidum in the region which later becomes the body of the nail; in this stage the structure is still covered by the remaining layers of the stratum corneum, constituting the *eponychium*. The embryonal nail then spreads in all directions until it finally reaches the sulcus. Henceforward the growth is uniform. The eleidin normally present in the stratum lucidum of the skin also occurs in the nail, and is derived, as we have already seen, from the keratohyalin. It may readily be conceived that later, when growth is confined to the root of the nail, keratohyalin is also present. As soon as the nail begins to grow forward, in the ninth month, the greater part of the eponychium is thrown off; but during the entire extrauterine life, a portion of the eponychium is retained at the nail wall, and as hyponychium on the anterior and under surface of the nail.

### D. THE GLANDS OF THE SKIN.

The glands in the skin are of two kinds—sweat-glands and sebaceous glands. A modification of the latter is seen in the mammary glands.

**1. The Sweat-glands.**—The sweat-glands, or sudoriparous glands, are distributed throughout the entire skin, but are especially numerous in certain regions—as, for instance, the axilla, palm of the hand, and sole of the foot. They lie imbedded either in the adipose tissue of the true skin, or still deeper in the subcutaneous connective tissue (axilla). To this group of glands belong also the *ceruminous glands* of the ear, the glands of Moll in the eyelid, and the *circumanal glands*.

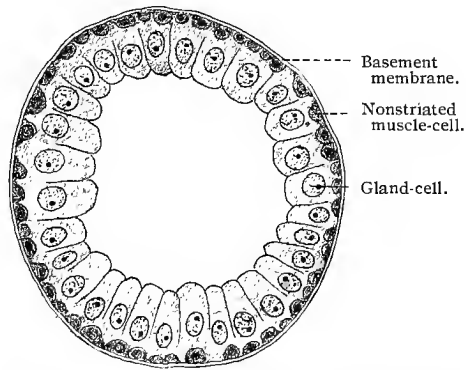


Fig. 300. — Cross-section of tubule of coiled portion of sweat-gland from human axilla. Fixation with sublimate;  $\times 600$ .

The sweat-glands are simple tubular in type, and their secreting portion is coiled; hence the name *coil-glands*. The coil is, as a rule, 0.3 or 0.4 mm. in diameter, but in the axilla reaches from 3 to 7 mm.

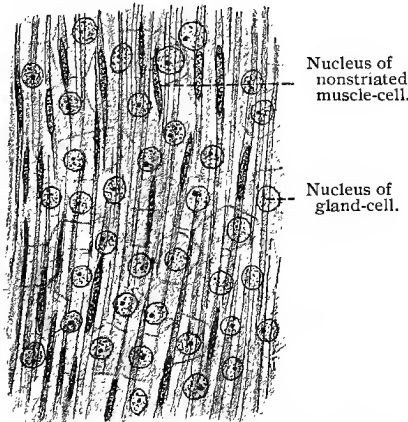


Fig. 301. — Tangential section through coiled portion of sweat-gland from human axilla. Sublimate fixation;  $\times 700$ .

The excretory duct (the sudoriferous duct) is nearly straight during its course upward through the corium, and always enters the epidermis between two papillæ of the corium. From here on, its course is spiral, and it should be borne in mind that in its passage through the epidermis it has no other wall than the epidermal cells of the various layers through which it passes, although these cells are arranged concentrically around the lumen

of the duct. The lining of the secretory or coiled portion of the sweat-gland consists of cubical cells with finely granular protoplasm and round or oval nuclei possessing one or two nucleoli. In the excre-

tory segments, the cells are arranged in two layers. The membrana propria is very delicate, and in both regions of the gland apparently structureless. External to the basement membrane is a fine connective-tissue sheath. A marked peculiarity of the secretory portion of the gland consists in a longitudinal layer of smooth muscle-fibers between the membrana propria and the glandular epithelium. The presence of this structure can be accounted for only by assuming that it is an epithelial derivative.

The changes in the gland cells during secretion have not been sufficiently studied, but this much is certain, that the secretory phenomena are not similar to those in the sebaceous glands (see below). To the glandular secretion must be added also the serum-like fluid oozing from the canalicular lymph-spaces in the stratum Malpighii into the epidermal portion of the excretory duct (Unna).

The development of the sweat-glands begins in the fifth month of fetal life. At first solid cords grow from the stratum germinativum of the epidermis into the corium. Later, in the seventh month, these become hollow.

Capillary networks surround the secreting portions of the sweat-glands.

The nerves of the sweat-glands have been studied with the aid of the methylene-blue method by Ostroumow, working under Arnstein's direction. These glands receive their innervation through the neuraxes of sympathetic neurones, the terminal branches of which form an intricate network just outside of the basement membrane, known as the *epilamellar plexus*. From this plexus fine, varicose nerve-fibers pass through the basement membrane, and, after coursing a shorter or longer distance with or without further division, end on the gland-cells, often in clusters of small terminal granules united by delicate threads.

**2. The Sebaceous Glands.**—The distribution of the sebaceous glands in the skin is closely connected with that of the hair follicles into which they pour their contents. Exceptions to this rule occur in only a few regions of the body, as, for instance, in the glans penis and foreskin (Tyson's glands), in the labia minora, angle of the mouth, glandulæ tarsales, and the Meibomian glands of the eyelids, etc. As a rule the sebaceous gland empties by a wide excretory duct into the upper third of the hair follicle. The walls of the duct also produce secretion, and can therefore hardly be differentiated from the rest of the gland. At its base the duct widens and is provided with a number of simple or branched alveoli. The sebaceous glands are therefore of the type of compound alveolar glands, varying in length from 0.2 mm. to 5 mm. They are surrounded by connective-tissue sheaths, which at the same time cover the hair follicles. Inside of the sheath is the membrana propria, which is a continuation of the glassy membrane of the follicle. The two or three basal strata of glandular cells must be regarded as a direct continuation of the elements of the external root-sheath. In the

more centrally placed strata the cells are distinctly changed in character; their contents consist of fat globules, varying in size and distributed throughout the protoplasm, giving this a reticular appearance, while the nuclei suffer compression from the accumulation of the fat globules and gradually become smaller and more angular. Finally, the cells change directly into secretion, which is then poured into the hair follicle as sebum. It is thus seen that in the secretion of sebum the cells are consumed and must be replaced. This renewal takes place by the constant proliferation of the basilar cells, which push the remains of the secreting cells upward and finally take their places. The final disintegration of the cells occurs either within the gland itself or between the hair follicle and the hair. The secretion contains fatty globules of varying size, which occur either free or attached to cellular detritus.

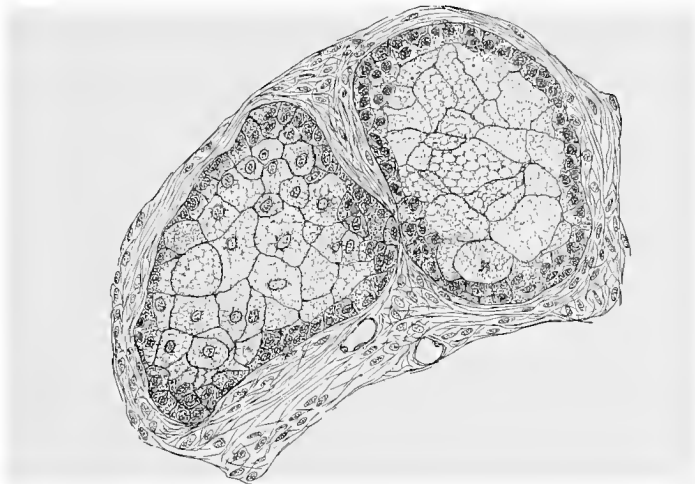


Fig. 302.—Section of alveoli from sebaceous gland of human scalp.

**3. The Mammary Glands.**—The mammary glands are also included among the cutaneous glandular structures. They are developed early, but not until the fifth month is it possible to distinguish a solid central portion, with radially arranged tubules terminating in dilatations. The structures are all derived from the basal layers of the epidermis. From birth to the age of puberty the organs are in a state of constant growth, and are early surrounded by a connective-tissue sheath. The alveoli, which have been developed in the mean time, are still solid and relatively small. Up to the twelfth year the glands remain identical in structure in boys and girls. In the female the mammary glands continue to develop from the age of puberty; in the male, on the other hand, they undergo a retrograde metamorphosis, ending, finally, in the atrophy of all except the excretory ducts. The mammary glands

do not attain their full stage of development in women until the last months of pregnancy, and are functionally active at parturition.

The human mammary gland when fully developed has the following structure: It consists of about twenty lobes, separated from each other by connective-tissue septa. These lobes are again divided into a larger number of lobules, and these in turn are composed of numerous alveoli, which, as in the case of the lung, present lateral sacculations. The alveoli are provided with small excretory passages, which unite and finally form the larger ducts. Shortly before terminating at the surface of the mamilla, each

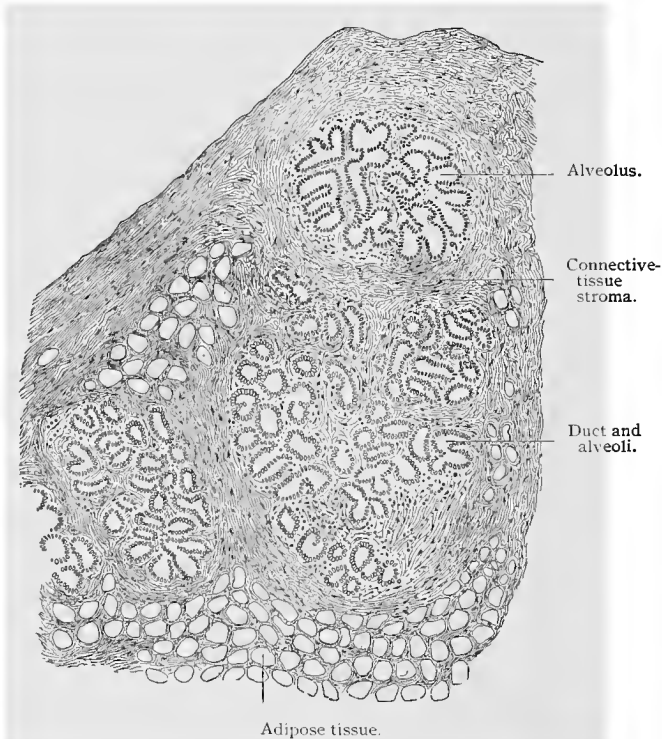


Fig. 303.—From section of mammary gland of nullipara. (From Nagel's "Die weiblichen Geschlechtsorgane," in "Handbuchs der Anatomie des Menschen," 1896.)

mammary duct widens into a vesicle, the *sinus lactiferus*. The number of excretory ducts corresponds to that of the larger lobes. The ducts are lined by simple cubical epithelium, except near the termination in the nipple, where they are lined by stratified pavement epithelium, and surrounded by a fibrous tissue sheath.

The epithelium of the alveoli differs according to the state of functional activity. In a state of rest it consists of a single layer of glandular cells of nearly cubical shape which stain deeply, the internal surfaces projecting into the lumen. At the beginning

of secretion the cells increase in length and fat globules make their appearance in their distal ends. At the same time a corresponding increase in size occurs throughout the entire alveolus. Finally, the free ends of the cells, which contain the most fat globules, are constricted off, after which the fat globules are freed in the lumen. The secretory portion of the alveolus is then composed of low epithelial cells, in which the process begins anew. The process of milk secretion therefore consists in throwing off the inner halves of the cells containing the fat globules, and in regeneration of the cells from the nucleated remains of the glandular epithelium. Whether a karyokinetic division of the nuclei occurs in this process is not known, and how often the process of regeneration may be repeated in a single cell is not capable of demonstration. It is certain, however, that entire cells are destroyed, to be replaced later by new elements. The *membrana propria* of the alveoli appears homogeneous. Between it and the glandular cells are so-called basket cells, similar to those in the salivary glands. Benda regards the basket cells as nonstriated muscle elements, having a longitudinal direction, making the structure of the alveoli of the mammary gland similar in this respect to that of the secreting portion of the sweat-glands.

The skin of the *mammilla* is pigmented, and the *papillæ* of its *corium* are very narrow and long. In the *corium* are also found large numbers of smooth muscle-fibers, which form circular bundles around the excretory ducts. In the *areolæ* of the *mammæ* are the so-called *glands of Montgomery*, which very probably represent accessory mammary glands. These are especially noticeable during lactation.

The mammary glands possess many lymphatics. These are especially numerous in the connective-tissue stroma between the lobules and alveoli. The vessels form capillary networks surrounding the alveoli. The lymph-vessels collect to form two or three larger vessels, which empty into the axillary glands. The mammary gland receives its nerve supply from the sympathetic and cerebrospinal nervous systems through the fourth, fifth, and sixth intercostal nerves. The terminations of the nerves in the mammary gland have been studied by means of the methylene-blue method by Dmitrewsky, working in the Arnstein laboratory, who finds that the terminal branches form epilamellar plexuses outside of the basement membrane of the alveoli, from which fine nerve branches pass through the basement membrane and end on the gland cells in clusters of terminal granules united by fine filaments. The nipple has a rich sensory nerve supply. In the connective-tissue *papillæ* are found tactile corpuscles of Meissner.

The *milk* consists of fat globules of varying size, which, however, do not coalesce—an attribute due to the presence of albuminous haptogenic membranes surrounding the globules. Shortly before, and for some days after, parturition the milk contains true

nucleated cells in which are fat globules; these are known as the *colostrum corpuscles*. They probably represent cast-off glandular cells in a state of fatty degeneration. Some authors regard them as leucocytes which have migrated into the lumen of the gland and there undergone fatty degeneration. This milk is known as *colostrum*.

#### TECHNIC.

**287.** Good general views of the skin can be obtained only from sections. Any fixation method may be employed, although alcohol is preferable on account of the better subsequent staining. For detail work Flemming's solution, corrosive sublimate, or osmic acid is the best. Sectioning of the skin is attended with many difficulties, and large pieces can be cut only in celloidin. Small and medium-sized pieces may be cut in paraffin; but even in this case the skin must be rapidly imbedded in the paraffin—*i. e.*, it must not remain too long in either alcohol or toluol—and the paraffin must have only the consistency necessary to cut well (about 50° C. melting-point). In order to obtain good paraffin sections of the skin the following procedure is recommended: Pieces fixed in Flemming's solution or osmic acid are kept in 96% alcohol, then placed for not more than twenty-four hours in absolute alcohol and imbedded in paraffin by means of the chloroform method. In the chloroform, chloroform-paraffin, and pure of paraffin they remain for one hour each. The paraffin used should consist two parts paraffin of 42° C., and one part paraffin of 50° C. melting-point. The thermostat must be kept at 50° C. (R. Barlow). The sections should not be mounted by the water-albumen method.

**288.** In sections of epidermis which have been freshly fixed with osmic acid, the stratum corneum may be clearly differentiated into three layers (probably because of the defective penetration of the reagent)—into a blackened superficial, a middle transparent, and a still lower black layer (*vid.* Fig. 304).

**289.** In tissue fixed in alcohol or corrosive sublimate the stratum lucidum stains yellow with picrocarmin, but is very weakly colored by basic anilin stains. In unstained preparations the stratum lucidum is glass-like and transparent. Eleidin is diffusely scattered throughout both the stratum lucidum and stratum corneum. Like keratohyalin, it stains with osmic acid and also with picrocarmin, but not with hematoxylin. Nigrosin stains eleidin, but not keratohyalin.

**290.** Keratohyalin is insoluble in boiling water and is not attacked by weak organic acids. It dissolves, however, in boiling acetic acid, but is not changed by the action of pepsin or trypsin. The keratohyalin granules of the stratum granulosum swell in from 1% to 5% potassium-hydrate solution; under the influence of heat these granules together with the cells containing them are finally dissolved. They are not attacked by ammonia, and remain unaffected for a long time in strong acetic acid. As ammonia and acetic acid render the remaining portions of the tissue transparent, these reagents may be employed for the rapid identification of keratohyalin. The larger flakes of keratohyalin swell in sodium carbonate solution (1%), but not the smaller granules, and it would seem that the larger granules have less power of resistance than the smaller. Keratohyalin remains unchanged in alcohol, chloroform, and ether, but

is digested in trypsin and pepsin (not, however, the keratin). Keratohyalin can be stained with hematoxylin and most of the basic anilin dyes.

**291.** The prickles of the cells composing the stratum Malpighii may be seen in very thin sections (not over  $3\mu$  in thickness) of skin previously fixed in osmic acid. In this case it is best to employ not Canada balsam, but glycerin, which does not have so strong a clearing action. Isolation of the prickle cells is best accomplished as follows (Schiefferdecker): A fresh piece of epidermis is macerated for a few hours in a filtered, cold-saturated, aqueous solution of dry pancreatin; the whole may then be preserved for any length of time in equal parts of glycerin,

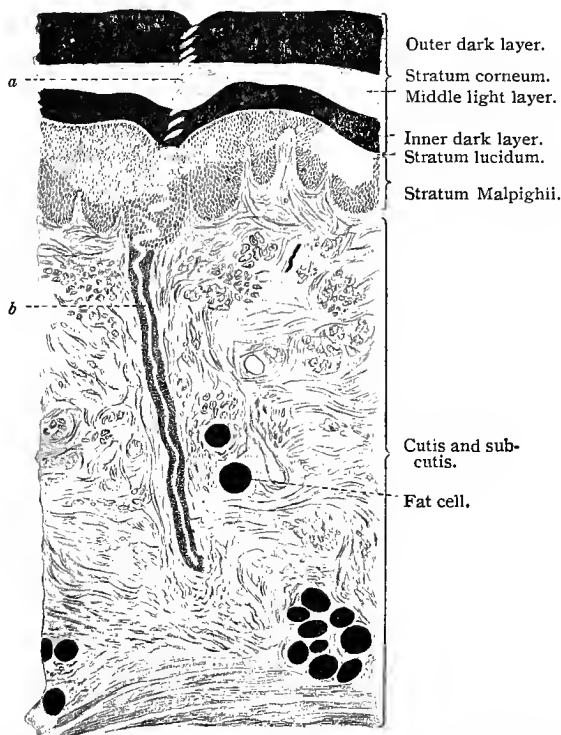


Fig. 304.—Transverse section through the human skin. Treated with osmic acid;  $\times 30$ : *a*, Part of the tortuous duct of a sweat-gland in the epidermis; *b*, duct of same sweat-gland in the corium.

water, and alcohol. Small pieces taken from such specimens are readily teased and show both isolated and small groups of attached prickle cells.

**292.** The distribution of the pigment in the skin is best studied in unstained sections. With a nearly closed diaphragm and under medium magnification the pigment granules appear darker on raising the tube and lighter upon lowering it.

**293.** In sections of skin treated with Flemming's fluid, the structure of the cutis also may be studied. The medullary sheaths of the nerve-fibers and the fat appear black. In preparations stained with safranin the

elastic fibers are colored red and are very distinct (Stöhr and O. Schultze). For the orcein method according to Unna, see T. 138.

294. Hair may be examined in water without further manipulation. The cuticle is then seen to consist of polygonal areas, the border-lines of which correspond to the limits of the flattened cells. By slightly lowering the objective the cortical substance comes into view with its indistinct striation and occasional pigmentation. The medullary substance, if present, may also be seen with its vesicles containing air. Both the cortical and cuticular cells may be isolated, the process consisting in treating the hairs for several days with 33 % potassium hydrate solution at room temperature, or in heating the whole for a few minutes. Concentrated or weak sulphuric acid produces the same result. On warming a hair in sulphuric acid until it begins to curl and then examining it in water, we find that the cortical and medullary layers as well as the cuticle are separated into their elements. Treatment of the skin with Müller's fluid, alcohol, or sublimate is recommended for the examination of hair and hair follicles. The orientation of the specimen should be very precise, in order to obtain exact longitudinal or cross-sections of the hair. There is hardly a structure of the body which is more suitable for staining with the numerous coal-tar colors than the hair and its follicle (Merkel).

295. The corpuscles of Meissner may be best obtained from the end of the finger. After boiling a piece of fresh skin from the finger-tip for about a quarter of an hour, the epidermis may be easily removed; the papillæ are now seen on the free surface of the cutis. A portion of the latter is cut away with a razor and examined in a 3% solution of acetic acid. The corpuscles are readily distinguished. Their relations to the nerves should be studied in specimens fixed with osmic acid or gold chlorid. The terminations of the nerves in these end-organs are best seen in preparations stained after the *intra vitam* methylene-blue method.

296. The corpuscles of Herbst and Grandry are found in the waxy skin covering the bill, and in the palate of the duck (especially numerous in the tongue of the woodpecker). For the study of the nervous elements the following method is useful: Pieces of the waxy skin are removed with a razor and placed for twenty minutes in 50% formic acid. After washing the specimens for a short time in distilled water they are transferred to a small quantity of 1% gold chlorid solution (twenty minutes), then again rinsed in distilled water, and placed for from twenty-four to thirty-six hours in the dark in a large quantity ( $\frac{1}{3}$  liter) of Pichard's solution (amyl alcohol 1 part, formic acid 1 part, water 100 parts). After again washing in water the specimens are transferred to alcohols of gradually increasing strengths and finally imbedded in celloidin or celloidin-paraffin.

297. The Pacinian corpuscles occur in the mesentery of the cat and may be examined in physiologic saline solution.

298. The nerves of the epidermis are demonstrated by the gold-chlorid method (see p. 166). But even here the chrome-silver method and the *intra vitam* methylene-blue method yield extremely good results, and may be used with great advantage in the study of the nerves in the cutis.

299. The so-called tactile menisci are very numerous in the snout of the pig and the mole. Bonnet recommends for these structures fixation in 0.33% chromic acid solution (*vid.* T. 26), overstaining with hematoxylin, and differentiation in an alcoholic solution of potassium ferricyanid.

## VII. THE CENTRAL NERVOUS SYSTEM.

In a study of the minute anatomy of the central nervous system consideration should be given to the arrangement of the nerve-cells and nerve-fibers in the various regions, and to the mutual relations which the elements of the nervous system bear to one another. In a text-book of this scope, however, we shall be unable to enter into the consideration of these subjects in detail, but must content ourselves with a very general discussion of the structure of certain regions of the central nervous system and an account of a few typical examples illustrating the mutual relationship of the nerve-elements to one another. We shall, therefore, give a general description of the structure of the spinal cord, cerebellum, cerebrum, olfactory lobes, and ganglia. In this description we have drawn freely from the results of the researches of Golgi (94), Ramón y Cajal (93, 1), von Lenhossék (95), Kölliker (93), and van Gehuchten (96).

### A. THE SPINAL CORD.

The spinal cord extends from the upper border of the atlas to about the lower border of the first lumbar vertebra. It has the form of a cylindric column, which at its lower end becomes quite abruptly smaller, to form the *conus medullaris*, and terminates in an attenuated portion—the *filum terminale*. It presents two fusiform enlargements, known as the cervical and lumbar enlargements respectively. The spinal cord is partly divided into two symmetric halves by an *anterior median fissure* and by a septum of connective tissue, extending into the substance of the cord from the pia mater (one of the fibrous tissue membranes surrounding the cord), and known as the *posterior median septum*. Structurally considered, the spinal cord consists of white matter (mainly medullated nerve-fibers) and gray matter (mainly nerve-cells and medullated nerve-fibers). The white and the gray matter present essentially the same general features at all levels of the spinal cord, although the relative proportion of the two substances varies somewhat at different levels. The different portions of the cord present also certain structural peculiarities.

The distribution of the gray and the white substances of the spinal cord is best seen in transverse sections.

The varying shape of the spinal cord in the several regions and the changing relations of the gray to the white substance are shown in the illustrations of cross-sections of the adult human spinal cord (see p. 366).

The gray substance is arranged in the form of two crescents, one in each half of the cord, united by a median portion extending from one half of the cord to the other, the whole presenting somewhat the form of an **H**. The horizontal part contains the commis-

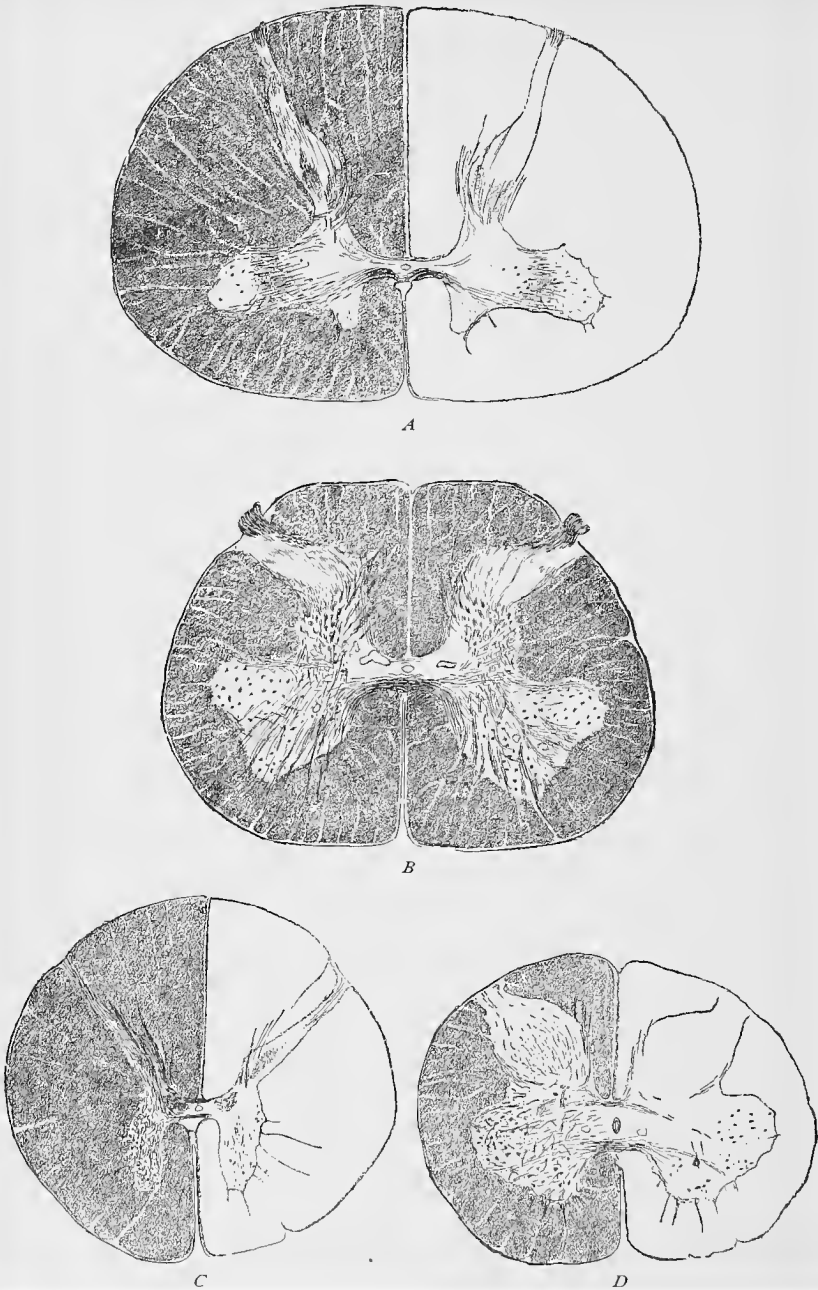


Fig. 305.—Four cross-sections of the human spinal cord;  $\times 7$ : *A*, Cervical region in the plane of the sixth spinal nerve-root; *B*, lumbar region; *C*, thoracic region; *D*, sacral region (compare with Fig. 306). (From preparations of H. Schmaus.)

tures and the central canal of the spinal cord, while the vertical limbs or crescents extend to the ventral and dorsal nerve-roots, forming the anterior and posterior horns. The former are, as a rule, the larger, and at their sides (laterally) the so-called lateral horns may be seen, varying in size in different regions. In each anterior horn are three main groups of ganglion cells: the **ventrolateral**, made up of root or motor nerve-cells; the **ventromesial**, composed of commissural cells; and the **lateral** (in the lateral horn), containing column cells. At the median side of the base of each posterior horn we find a group of cells and fibers known as the **column of Clark**, most clearly defined in the dorsal region, while in the posterior horn itself is the **gelatinous substance of Rolando**. Aside from these, numerous cells and fibers are scattered throughout the entire gray substance.

The motor nerve-cells lie in the ventrolateral portion of the anterior horn, their neuraxes extending into the anterior nerve-root. Their dendrites are distributed in a lateral, dorsal, and mesial direction, the two former groups ending in the anterior and lateral columns, the mesial in the region of the anterior commissure. Some of the mesial dendrites extend beyond the median line and form a sort of commissure with the corresponding processes of the other side. The commissural cells lie principally in the mesial group of the anterior horn, but occur here and there in other portions of the gray substance. Their neuraxes form the anterior gray commissure with the corresponding processes from the other side. After entering the white substance of the other side, these neuraxes undergo a T-shaped division, one branch passing upward and the other downward. The column cells are small multipolar elements, represented by the cells of the lateral horns, although they are also found throughout the entire gray mass. Their neuraxes pass directly into the anterior, lateral, and posterior horns.

The cells of the column of Clark, or *nucleus dorsalis*, are of two kinds—those in which the neuraxes pass to the anterior commissure (commissural cells) and those in which the neuraxes pass into the direct cerebellar tract of the same side. The plurifunicular cells are cells the neuraxes of which divide two or three times in the gray substance, the branches then passing to different columns of the white matter on the same or opposite side of the cord. In the latter case the branches must necessarily extend through the commissure. The cells of the *substantia gelatinosa* (Rolando) are cells with short, freely branching neuraxes, which end after a short course in the gray mass (Golgi's cells). The posterior horn contains marginal cells, spindle-shaped cells, and stellate cells. The first are situated superficially near the extremity of the posterior horn, their neuraxes extending for some distance through the gelatinous substance of Rolando and then into the lateral column. The spindle-shaped cells are the smallest in the spinal cord and possess a rich arborization of dendrites extending to the nerve-root of the pos-

terior horn. Their neuraxes, which originate either from the cell-body or from a dendrite, pass over into the posterior column. The stellate cells are supplied with dendrites, which either branch in the substance of Rolando or extend into the column of Burdach.

The gray matter contains, further, numerous medullated nerve-fibers, in part the neuraxes of the nerve-cells previously mentioned, and in part collateral and terminal branches of the nerve-fibers of the white matter with their telodendria; also supporting cells, known as neuroglial cells (to be discussed later), and blood-vessels.

The white matter of the spinal cord consists of medullated fibers, which are devoid of a neurilemma, of neuroglial tissue, and of fibrous connective tissue.

In each half of the cord the white substance, which surrounds the gray, is separated by the gray matter and its nerve-roots into

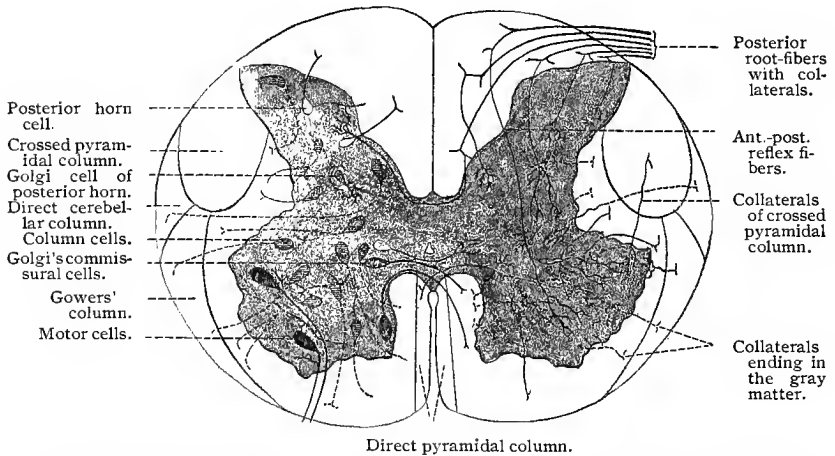


Fig. 306.—Schematic diagram of the spinal cord in cross-section after von Lenhossek, showing in the left half the cells of the gray matter, in the right half the collateral branches ending in the gray matter.

three main divisions or columns: The first division, lying between the anterior median fissure and the anterior horn, is the anterior column; the second, lying between the anterior and posterior horns, is the lateral column (since the anterior and lateral columns belong genetically to each other, the term anterolateral column is often used); and the third, lying between the posterior nerve-root and the posterior median septum, is the posterior column.

By means of certain methods it has been possible to separate the white substance into still smaller divisions, the most important of which may here be described.

In each anterior column is found a narrow median zone extending along the entire length of the anterior median fissure and con-

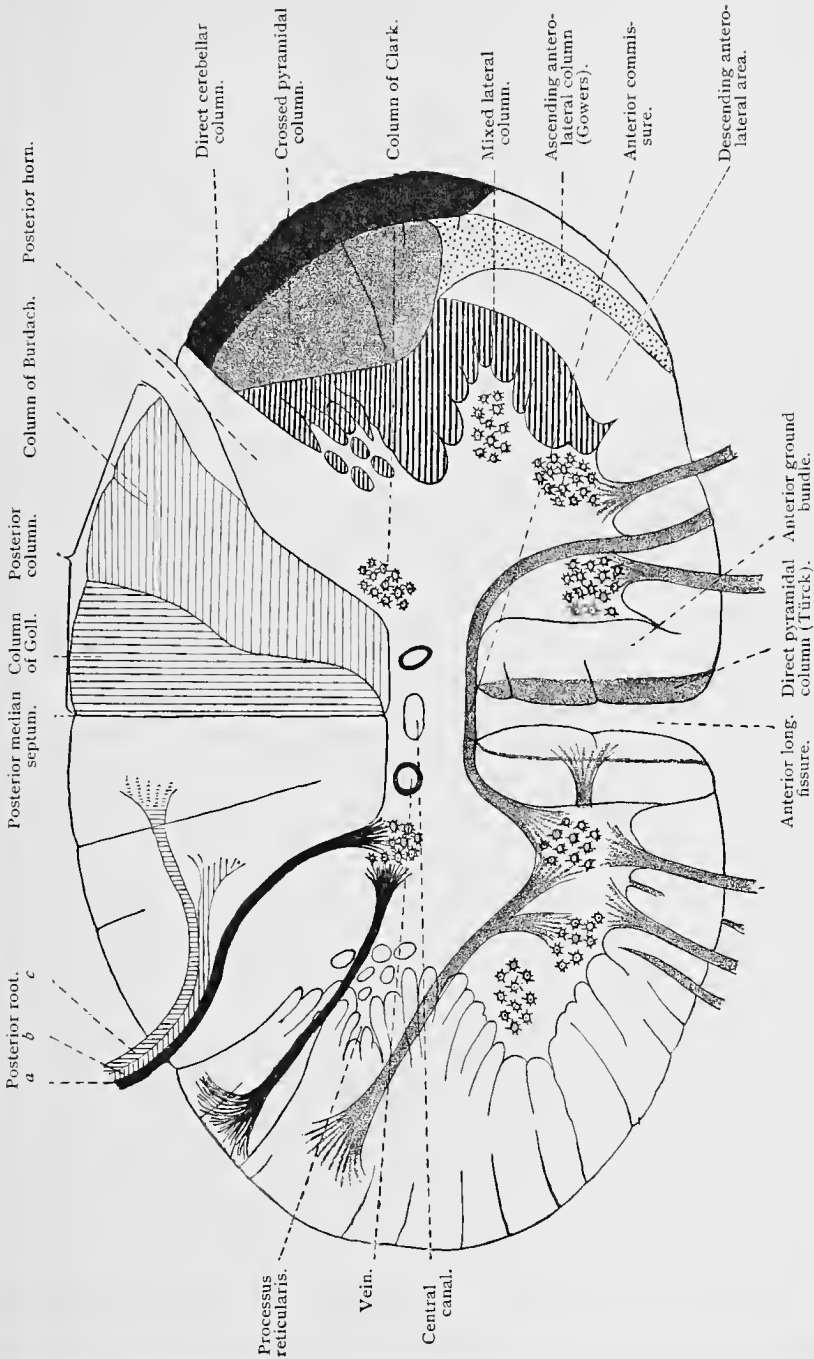


Fig. 307.—Schematic cross-section of the spinal cord, after Professor Ziehen (from von Bardeleben and H. Haackel) : *a*, *b*, and *c*, bundles of the posterior nerve-root.

taining nerve-fibers which come from the pyramids of the medulla. The majority of the pyramidal fibers cross from one side of the cord to the other in the lower portion of the medulla, at the crossing of the pyramids, and form a large bundle of nerve-fibers found in each lateral column, which will receive attention later. Some of the pyramidal fibers descend into the cord on the same side, to cross to the opposite side at different levels in the cord. These latter fibers constitute the narrow median zone, on each side of the anterior median fissure previously mentioned, forming the anterior or **direct pyramidal tract**, or the column of Türck. Between the direct pyramidal tract and the anterior horn lies the **anterior ground bundle**.

In the lateral columns are found a number of secondary columns, which may now be mentioned. In front of and by the side of the posterior horn in each lateral column lies a large group of nerve-fibers, forming a bundle which varies somewhat in size and shape in the several regions of the spinal cord, but which has in general an irregularly oval outline. These nerve-fibers are the pyramidal fibers, previously mentioned, which in the lower part of the medulla cross from one side to the other, and for this reason are known as the crossed pyramidal fibers, forming the **crossed pyramidal columns**. External to these columns and to the posterior horns, and extending from the posterior horns half-way around the periphery of the lateral columns, lie the **direct cerebellar columns**, consisting of the neuraxes of the cells of the columns of Clark, which have an ascending course. Lying just external to and between the anterior and posterior horns is a somewhat irregular zone, the **mixed lateral column**, containing several short bundles of fibers, the anterior of which are probably motor; the posterior, sensory. In the ventrolateral portions of the lateral columns, between the mixed lateral and the direct cerebellar columns and extending as far backward as the crossed pyramidal columns, lie two not well-defined columns, known as the **ascending anterolateral** or **Gowers's columns** and the **descending anterolateral columns**; the former are nearer the outer portion of the cord.

In the posterior column we distinguish a median and a lateral column. The former lies along the posterior median septum, and may even be distinguished externally by an indentation; its upper portion tapers into the *fasciculus gracilis*. This is the **column of Goll**, and it contains ascending or centripetal fibers. The lateral tract lies between the column of Goll and the posterior horn, and is known as the **column of Burdach**, posterior ground-bundle, or posterolateral column. It contains principally the shorter tracts, or bundles of longitudinal fibers connecting the adjacent parts of the spinal cord with one another.

Many of the nerve-fibers of the posterior column are the neuraxes of spinal ganglion cells which enter the spinal cord through the posterior roots. The cell-bodies of the spinal ganglion or sen-

sory neurones are situated in the spinal ganglia found on the posterior roots of the spinal nerves. In the embryo they are distinctly bipolar, but during further development their two processes approach each other, and then fuse for a certain distance, forming finally single processes which branch like the letter T. In reality, then, there are two processes which are fused for a certain distance from the cell-body of each neurone. The peripherally directed process is regarded as the dendrite of the cell, and the proximal as the neuraxis passing to the spinal cord. The neuraxes enter the spinal cord through the posterior roots and pass to the posterior columns, where they divide, Y-shaped, into ascending and much shorter descending branches, from each of which numerous collateral branches are given off.

From the preceding account of the white matter of the spinal cord, it may be seen that it consists of longitudinally directed neuraxes arranged in so-called short and long tracts or columns. The neuraxes constituting the former, after a short course through the gray matter, emerge from it, and after giving off various collaterals, again penetrate into the gray matter, where their telodendria enter into contact with the ganglion cells. The long columns consist of the neuraxes of neurones the cell-bodies of which are situated in the cerebrum or cerebellum, and of neurones the cell-bodies of which are in the spinal cord or spinal ganglia and the neuraxes of which terminate in the medulla or cerebellum. The nerve-fibers of the various columns give off numerous collaterals which enter the gray matter to end in telodendria. The collaterals of the posterior columns end: (1) between the cells of the gelatinous substance of the posterior horns; (2) in the columns of Clark; (3) in the anterior horns, these constituting the principal portion of the so-called reflex bundles; (4) in the posterior horn of the opposite side. The collaterals of the lateral columns pass horizontally toward the central canal, some ending in the anterior horn, others closely arranged near the columns of Clark, and some arching around the central canal, forming with the corresponding fibers of the other side the anterior bundles of the posterior commissure. The collaterals of the anterior columns form well-marked plexuses in the anterior horns of the same and opposite sides.

We have still to describe the two **commissures**. The anterior consists of: first, neuraxes from the commissural cells; second, dendrites from the lateral group of the anterior horn cells; and, third, the collaterals of the anterolateral column, which end in the gray substance of the other side of the cord. The posterior commissure is probably composed of the collaterals from all the remaining columns. The posterior bundle of this commissure comes from the posterior column; the middle, from the posterior portion of the lateral column; and the anterior, or least developed, from the anterior portion of the lateral column, possibly also from the anterior column.

In the gray commissure, nearer its anterior border, is situated the central canal of the spinal cord, continuous above with the ventricular cavity of the medulla and terminating caudally in the filum terminale. This canal is not patent in the majority of adults, being occluded from place to place. The canal is lined by a layer of columnar cells, developed from columnar cells, known as spongioblasts, lining the relatively larger canal of the embryonic spinal cord. In young individuals these cells are ciliated and their basal portions terminate in long, slender processes.

## B. THE CEREBELLAR CORTEX.

In the cerebellar cortex we distinguish three general layers—the outer molecular, the middle granular (rust-colored layer), and the inner medullary tract.

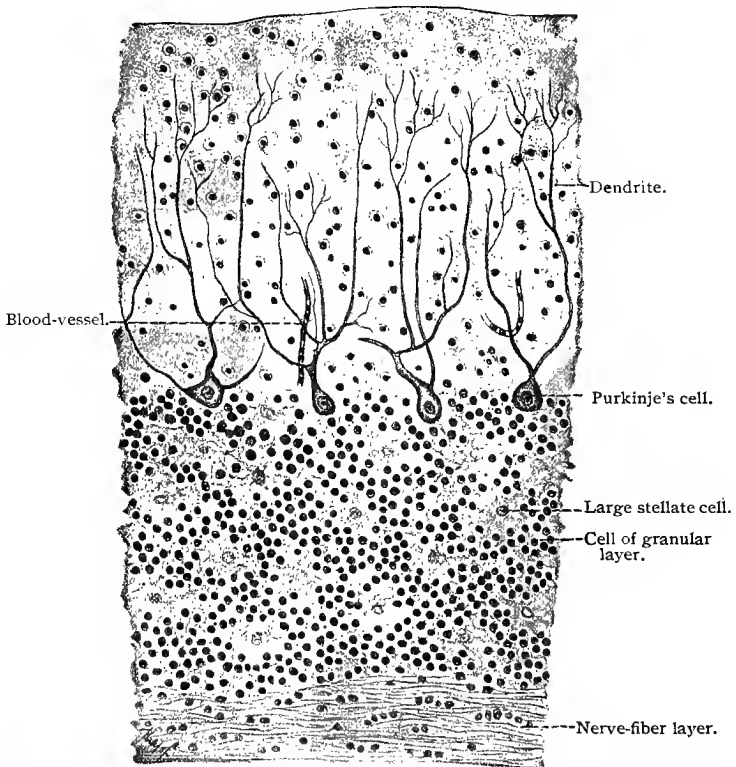


Fig. 308.—Section through the human cerebellar cortex vertical to the surface of the convolution. Treatment with Müller's fluid;  $\times 115$ .

The **molecular layer** contains three varieties of nerve-cells, those of Purkinje, which border upon the granular layer, the stel-



Stellate cell.

Large stellate cell.

Neuraxis of cell of granular layer. Telodendrition of collateral of climbing fiber.

Stellate cell.

Molecular layer.

Granular layer.

Medullary layer.

Moss fiber. Cell of granular layer. Neuraxis of cell of granular layer. Climbing fiber.

Fig. 309.—Schematic diagram of the cerebellar cortex: *A*, By ordinary nuclear staining (omitting the layer of Purkinje's cells); *B*, vertical to the surface of the convolution; *C*, longitudinal section through the convolution. *B* and *C*, by the chrome-silver method.

late cells, and the small cortical cells. The **cells of Purkinje** possess a large flask-shaped body (about  $60 \mu$  in diameter), from which one or more well-developed dendrites pass toward the periphery. The latter branch freely and the main arborization has in each case the general shape of a pair of deer's antlers. These dendrites extend nearly to the periphery of the cerebellar cortex. In a section horizontal to the surface of the organ the dendrites of the Purkinje's cells are seen to lie in a plane very nearly vertical to the surface of the convolutions, so that a longitudinal section through the latter would show a profile view of the cells. In other words, they have an appearance much like that of a vine trained upon a trellis. The neuraxes of the cells of Purkinje arise from their basal

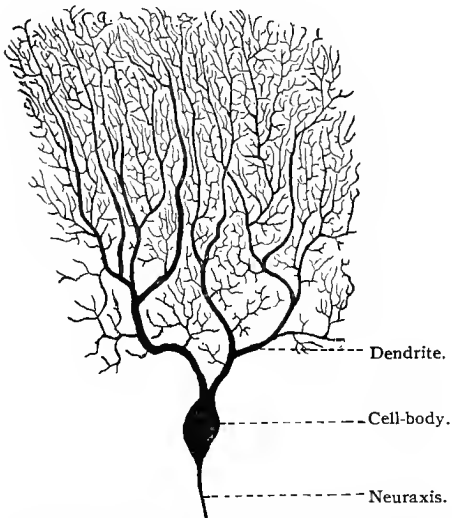


Fig. 310.—Cell of Purkinje from the human cerebellar cortex. Chrome-silver method;  $\times 120$ .

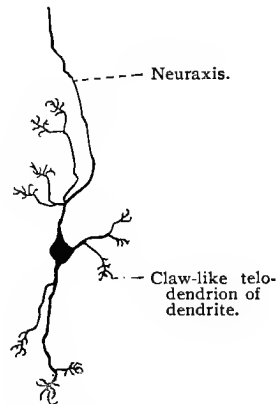


Fig. 311.—Granular cell from the granular layer of the human cerebellar cortex. Chrome-silver method;  $\times 100$ .

(inner) ends and extend through the granular layer into the medullary substance. During their course they give off a few collaterals, which pass backward to the molecular layer and end in telodendria near the bodies of the cells of Purkinje. The **stellate cells** lie in various planes of the molecular layer. Their peculiar interest lies in the character of their neuraxes. The latter are situated in the same plane as the dendrites of the cells of Purkinje, run parallel to the surface of the convolution, and possess two types of collaterals. Those of the first are short and branched; those of the second branch at a level with the cells of Purkinje, and form, together with their telodendria, basket-like nets around the bodies of these cells. The **small cortical cells** of the molecular layer are found

in all parts of this layer, but are more numerous in its peripheral portion. They are multipolar cells with neuraxes which are not readily stained and concerning the fate of which little is known.

The **granular layer** contains two varieties of ganglion elements, the so-called granular cells (small ganglion cells) and the large stellate cells. The dendrites of the **granular cells** are short, few in number (from three to six), branch but slightly, and end in short, claw-like telodendria. Their neuraxes ascend vertically to the surface and reach the molecular layer. At various points some of them are seen to undergo a T-shaped division, the two branches then running parallel to the surface of the cerebellum in a plane vertical to that of the dendrites of the cells of Purkinje. Large numbers of these T-shaped neuraxes produce the striation of the molecular layer of the cerebellum. It is very probable that during their course these parallel fibers come in contact with the dendrites of the cells of Purkinje. The **large stellate cells** are fewer in number and lie close to the molecular layer, some of them even within this layer. Their dendrites branch in all directions, but extend principally into the molecular layer. Their short neuraxes give off numerous collaterals which end in telodendria among the granular cells.

The **medullary substance** is composed of the centrifugal neuraxes of the cells of Purkinje and of two types of centripetal neuraxes, the mossy and the climbing fibers. The position of their corresponding nerve-cells is not definitely known. The **mossy fibers** branch in the granular layer into numerous twigs, and are not uniform in diameter, but are provided at different points with typical nodular swellings. These fibers do not extend beyond the granular layer. The **climbing fibers** pass horizontally through the granular layer, giving off in their course numbers of collaterals, which extend to the cells of Purkinje, up the dendrites of which they seem to climb.

In the medullary portion of the cerebellum are found a number of groups of ganglion cells known as central gray nuclei. The nerve-cells of these nuclei are multipolar, with numerous, oft-branching dendrites and a single neuraxis.

### C. THE CEREBRAL CORTEX.

The cell-bodies of the neurones of the cerebrum are grouped in a thin layer of gray matter, varying in thickness from 2 to 4 mm.,—which, as a continuous sheet, completely covers the white matter of the hemispheres,—and in larger and smaller masses of gray matter, known as basal nuclei. In our account of the histologic structure of the cerebral hemispheres we shall confine ourselves in the main to a consideration of the cerebral cortex, the thin layer of gray matter investing the white matter.

From without inward the following layers may be differentiated in the cerebral cortex: (1) a molecular layer; (2) a layer of small pyramidal cells; (3) a layer of large pyramidal cells; (4) a layer of polymorphous cells; and (5) medullary substance or underlying nerve-fibers.

Aside from neuroglial tissue, we find in the **molecular layer** a large number of nerve-fibers, which cross one another in all directions, but, as a whole, have a direction parallel with the surface of the brain. Within this layer there are found: (1) the tuft-like telodendria of the chief dendritic processes of the pyramidal cells; (2) the terminations of the ascending neuraxes, arising mostly from the polymorphous cells; and (3) autochthonous fibers—*i. e.*, those which arise from the cells of the molecular layer and terminate in this layer. The cells of the molecular layer may be classed in three general types—polygonal cells, spindle-shaped cells, and triangular or stellate cells. The **polygonal cells** have from four to six dendrites, which branch out into the molecular layer and may even penetrate into the underlying layer of small pyramidal cells. Their neuraxes originate either from the bodies of the cells or from one of their dendrites, and take a horizontal or an oblique direction, giving off in their course a large number of branching collaterals, which terminate in knob-like thickenings. The **spindle-shaped cells** give off from their long pointed ends dendrites which extend for some distance parallel with the surface of the brain. These branch, their offshoots leaving them at nearly right angles, the majority passing upward, assuming as they go the characteristics of neuraxes having collaterals. The arborization is entirely within the molecular layer. The **triangular** or **stellate cells** are similar to those just described, but possess not two, but three, dendrites. The triangular and spindle-shaped cells, with their numerous dendritic processes resembling neuraxes, are characteristic of the cerebral cortex.

The elements which are peculiar to the second and third layers of the cerebral cortex are the **small** (about  $10\ \mu$  in diameter) and **large pyramidal cells** (from  $20\ \mu$  to  $30\ \mu$  in diameter). They are composed of a triangular body, the base of the triangle being downward and parallel to the surface of the brain, of a chief, principal, or primordial dendrite ascending toward the brain-surface, of several basilar dendrites arising from the basal surface of the cell-body, and of a neuraxis which passes toward the medullary substance and which has its origin either from the base of the cell or from one of the basilar dendrites. The ascending or chief dendrite gives off a number of lateral offshoots which branch freely and end in terminal filaments. The main stem of the dendrite extends upward to the molecular layer, in which its final branches spread out in the form of a tuft. The neuraxis, during its course to the white substance, gives off in the gray substance from six to twelve collaterals, which divide two or three times before terminating.

Aside from the fact that the **layer of polymorphous cells** contains a few large pyramidal cells, it consists principally of (1) multipolar cells with short neuraxes (Golgi's cells) and (2) of cells with only slightly branched dendrites and with neuraxes passing toward the surface of the brain (Martinotti's cells). Both these types of cells are, however, not found exclusively in the layer of polymorphous cells, but may be met with here and there in the layers of the small and large pyramidal cells. The dendrites of the **cells of Golgi** are

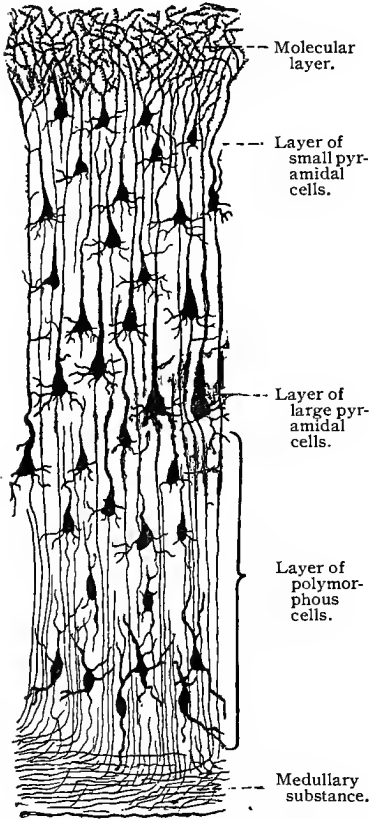


Fig. 312.—Schematic diagram of the cerebral cortex, after Golgi and Ramón y Cajal.

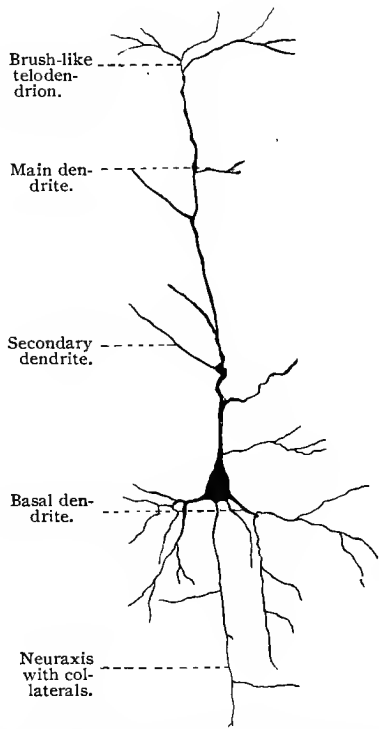


Fig. 313.—Large pyramidal cell from the human cerebral cortex. Chrome-silver method;  $\times 150$ .

projected in all directions, those in the neighborhood of the medullary substance even penetrating into this layer. The neuraxes break up into numerous collaterals, the telodendria of which lie adjacent to the neighboring ganglion cells. The **cells of Martinotti**, which, as we have seen, occur also in the second and third layers, are either triangular or spindle-shaped. The neuraxis of each cell originates either from the cell-body or from one of its dendrites, and

ascends (giving off collaterals) to the molecular layer, in which it finally divides into two or three main branches ending in telodendria. Occasionally it divides in a similar manner in the layer of small pyramidal cells.

In the **medullary substance** the following four classes of fibers are recognized: (1) The **projection fibers** (centrifugal)—*i. e.*, those which indirectly connect the elements of the cerebral cortex with the periphery of the body; their course may or may not be interrupted during their passage through the basal nuclei; (2) the **commissural fibers**,

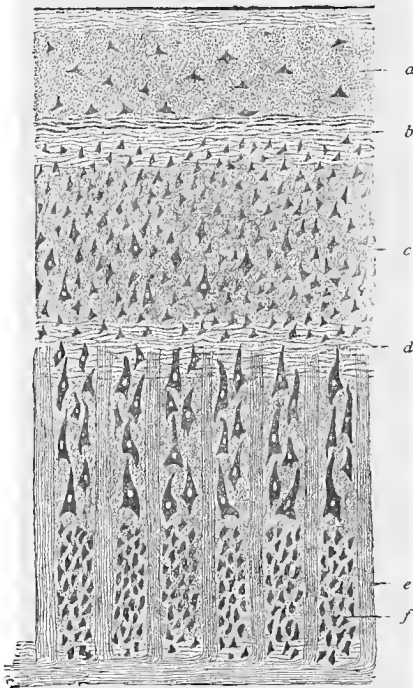


Fig. 314.—Schematic diagram of the cerebral cortex: *a*, Molecular layer with superficial (tangential) fibers; *b*, striation of Bechtereff-Kaes; *c*, layer of small pyramidal cells; *d*, stripe of Bailyarger; *e*, radial bundles of the medullary substance; *f*, layer of polymorphous cells.

**fibers**, which, according to the original definition, pass through the corpus callosum and anterior commissure, thus joining corresponding parts of the two hemispheres; (3) the **association fibers**, which connect different parts of the gray substance of the same hemispheres; and (4) the **centripetal** or **terminal fibers**—*i. e.*, the terminal arborizations of those neuraxes, the cells of which lie in some other region of the same or opposite hemisphere, or even in some more distant portion of the nervous system. The projection fibers originate from the pyramidal cells, some of them perhaps from the polymorphous cells. The commissural fibers are also derived from the pyramidal cells, and lie somewhat deeper in the white substance than the association fibers. With the exception of those which join the

cunei and those which lie in the anterior commissure, all the commissural fibers are situated in the corpus callosum. They give off during their passage through the hemispheres large numbers of collaterals, which penetrate at various points into the gray substance and end there in terminal filaments. In this respect their arborization is contrary to the old definition of these fibers, and the latter must be completed by the statement that, besides joining symmetric points of the two hemispheres, they also, by means of

their collaterals, may connect other areas of the gray substance with the peripheral regions supplied by their end-tufts (Ramòn y Cajal, 93). The association fibers have their origin also in the pyramidal cells. In the medullary substance their neuraxes divide T-shaped, and after a longer or shorter course penetrate into the gray substance of the same hemisphere, where they end as terminal fibers. A few collaterals are, however, previously given off, which also terminate in the same manner in the gray substance. The association fibers form the bulk of the medullary rays.

On examining a vertical section through one of the cerebral convolutions a number of successive striations may be seen. These are more or less distinct, according to the region, and consist of strands of medullated nerve-fibers between the layers of cells, and parallel with the surface of the convolution. The most superficial form a layer of tangential fibers. Between the molecular layer and the layer of small pyramidal cells is the **striation of Bechtereff and Kaes**, and in the region of the large pyramidal cells the **striation of Baillarger** (Gennari) corresponding to the striation of Vicq d'Azyr in the cuneus. In figure 314 the medullary substance is seen below, with rays, composed of parallel bundles of fibers, passing upward into the gray substance; in reality these fibers penetrate much higher than is shown in the illustration.

#### D. THE OLFACTORY BULB.

The olfactory bulb is composed of five layers, which are especially well marked on its ventral side: first, the layer of peripheral nerve-fibers; second, the layer of olfactory glomeruli; third, the stratum gelatinosum, or molecular layer; fourth, the layer of pyramidal cells (mitral cells); and, fifth, the granular layer with the deeper nerve-fibers.

The **layer of peripheral fibers** is composed of the nerve-bundles of the olfactory nerve which cross one another in various directions and form a nerve-plexus. The **glomerular layer** contains peculiar, regularly arranged, round or oval, and sharply defined structures, which were first accurately studied by Golgi. They are known as glomeruli (from 100  $\mu$  to 300  $\mu$  in diameter), and are in reality complexes of intertwining telodendria. As we shall see, the epithelial cells of the olfactory region of the nose must be regarded as peripheral ganglion cells and their centripetal (basal) processes as neuraxes. The telodendria of these neuraxes, together with those of the dendrites from the mitral or other cells, come in contact with each other within the olfactory glomeruli. The **molecular layer** consists of small, spindle-shaped ganglion cells. Their neuraxes enter the fifth layer and their short dendrites end in terminal ramifications in the glomeruli. The **mitral cells** give off neuraxes from their dorsal surfaces which also enter the granular

layer, but the majority of their dendrites break up into terminal ramifications in the olfactory glomeruli, as just described. The **granular layer** (absent in the illustration) is made up of nerve-cells and nerve-fibers; but, aside from these, we find also large numbers of peculiar cells with a long peripherally and several short centrally directed dendrites. No neuraxes can be demonstrated in these cells (granular cells). This layer also contains the stellate ganglion cells. The latter are not numerous, but lie scattered, and each possesses several short dendrites and a peripherally directed neuraxis which ends in the molecular layer in a rich arborization. The deep nerve-fibers are grouped into bundles which inclose between them the granular and stellate cells just mentioned. These nerve-fibers

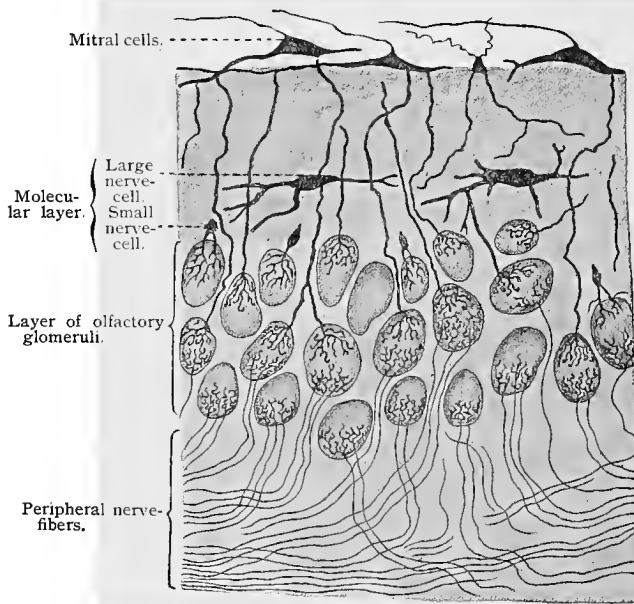


Fig. 315.—The olfactory bulb, after Golgi and Ramón y Cajal. The granular layer is not shown.

are derived partly from the neuraxes of the pyramidal or mitral cells and partly from the cells of the molecular layer, while some of them are centripetal fibers from the periphery, which end between the granules of the fifth layer.

### E. EPIPHYSIS AND HYPOPHYSIS.

In mammalia the **epiphysis**, or pineal gland, consists of a fibrous capsule derived from the pia mater, from which numerous fibrous tissue septa and processes pass into the gland, uniting to form quite regular round or oval compartments in which closed follicles or alveoli, whose walls consist of epithelial cells, are found.

The epithelial cells forming the walls of the follicles are of cubic or short columnar shape, and may be arranged in a single layer or may be pseudostratified or stratified. Follicles completely filled with cellular elements are found. Other follicles contain peculiar concretions, known as brain-sand or **acervulus**, of irregular round or oval or mulberry shape. Medullated nerve-fibers have been traced into the epiphysis, but their mode of termination is not known.

The **hypophysis**, or pituitary body, consists of two lobes. The posterior or infundibular lobe is developed from the floor of the first primary brain-vesicle, and remains attached to the floor of the third ventricle by a stalk, known as the infundibulum; the anterior or glandular lobe develops from a bud derived from the primary oral ectoderm, known as Rathke's pouch. The distal end of this pouch comes in contact with the anterior surface of the lower portion of the infundibulum, and becomes loosely attached to it. As the bones at the base of the skull develop, the attenuated oral end of Rathke's pouch atrophies, the distal end becoming finally completely severed from the buccal cavity.

In the infundibular lobe of the hypophysis of the dog, Berkley (94) described three portions presenting different microscopic structure. His account will here be followed: (1) An outer stratum consisting of three or four layers of cells resembling ependymal cells, which are separated into groups by thin strands of fibrous tissue entering from the fibrous covering of this lobe. (2) A zone consisting of glandular epithelial cells which in certain places are arranged in the form of alveoli, often containing a colloid substance. This zone merges into the central portion, (3), containing variously shaped cells and connective-tissue partitions with blood-vessels. In this portion neuroglial cells (see these) and nerve-cells were stained by the chrome-silver method.

The glandular or anterior lobe resembles slightly in structure the parathyroid. This lobe is surrounded by a fibrous tissue capsule and within it are found variously shaped alveoli or follicles, or, again, columns or trabeculæ of cells separated by a very vascular connective tissue. In the alveoli or columns of cells are found two varieties of glandular cells, which may be differentiated more by their staining reaction than by their size and structure, although they present slight structural differences. One variety of cells possesses a protoplasm which shows affinity for acid stains; these are known as **chromophilic cells**. They are of nearly round or oval shape, with nuclei centrally placed, and have a protoplasm presenting coarse granules. The other variety of cells, known as **chief cells**, are more numerous than the chromophilic. They are of cubic or short columnar shape, with nuclei placed in the basal portions of the cells and with protoplasm showing a fine granulation and with an affinity for basic stains. Now and then alveoli containing a colloid substance, similar to that found in the alveoli of the thyroid gland, may be observed. The blood-vessels of the glandular

portion are relatively large, the majority of them having only an endothelial lining. In the glandular portion of the hypophysis of the dog, Berkley (94) found small varicose nerve-fibers belonging to the sympathetic system. From the larger bundles, which follow the blood-vessels, are given off single fibers or small bundles of such, which end on the glandular elements in numerous small nodules.

## F. GANGLIA.

In the course of peripheral nerves are found numerous larger and smaller groups of nerve-cells, known as ganglia. The neurones of these ganglia are in intimate relation with the neurones of the cen-

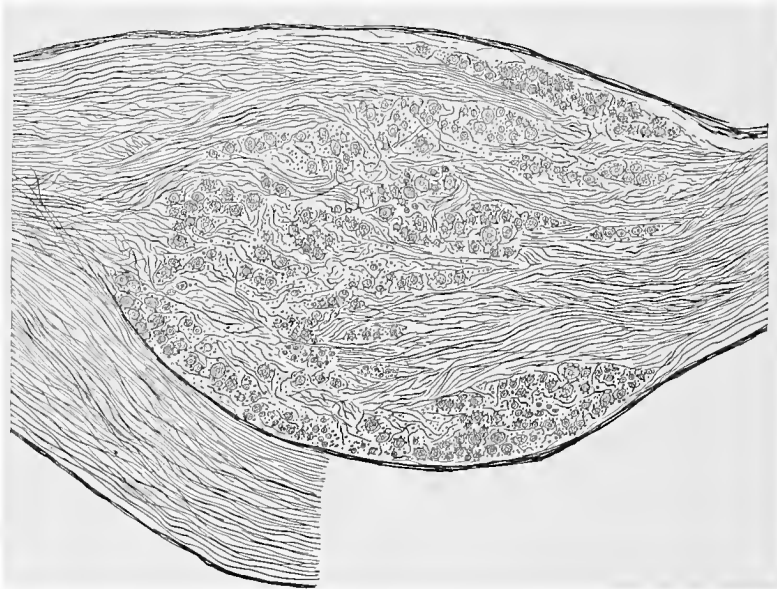


Fig. 316.—Longitudinal section of spinal ganglion of cat.

tral nervous system, and may, therefore, be discussed with the latter. According to the structure and function of their neurones, the ganglia are divided into two groups—(1) spinal or sensory ganglia and (2) sympathetic ganglia.

The **spinal ganglia** are situated on the posterior roots of the spinal nerves. Certain cranial ganglia—namely, the Gasserian, geniculate, and auditory ganglia, the jugular and petrosal ganglia of the glossopharyngeal nerves, and the root and trunk ganglia of the vagi—are classed with the spinal ganglia, since they present the same structure. The spinal and sensory cranial ganglia are surrounded by firm connective-tissue capsules, continuous with the perineural sheaths of the incoming and outgoing nerve-roots. From

these capsules connective-tissue septa and trabeculæ pass into the interior of the ganglia, giving support to the nerve-elements. The cell-bodies (ganglion cells) of the neurones constituting these ganglia are arranged in layers under the capsule and in rows and groups or clusters between the nerve-fibers in the interior of the ganglia. More recent investigations have shown that several types of neurones are to be found in the spinal and cranial sensory ganglia; of these, we may mention the following: (1) Large and small unipolar cells with T- or Y-shaped division of the process. These neurones, which constitute the greater number of all the neurones of the ganglia under discussion, consist of a round or oval cell-body, from which arises by means of an implantation cone

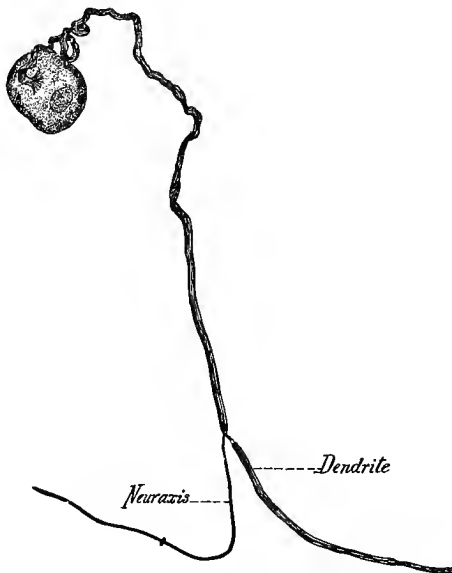


Fig. 317.—Ganglion cell from the Gasserian ganglion of a rabbit; stained in methylene-blue (*intra vitam*).

a single process, which, soon after it leaves the cell, becomes invested with a medullary sheath and usually makes a variable number of spiral turns near the cell-body. According to Dogiel, this process divides into two branches, usually at the second or third node of Ranvier, sometimes not until the seventh node is reached. Of these two branches, the peripheral is the larger, and enters a peripheral nerve-trunk as a medullated sensory nerve-fiber, terminating in one of the peripheral sensory nerve-endings previously described. The central process, the smaller of the two, becomes a medullated nerve-fiber, which enters the spinal cord or medulla in a manner described in a former section. The cell-body of each of these neurones is surrounded by a nucleated capsule, continuous with

the neurilemma of the single process. (2) Type II spinal ganglion cell of Dogiel. Dogiel has recently described a second type of spinal ganglion cell which differs materially from the type just described. The cell-bodies of these neurones resemble closely those of the typical spinal ganglion neurones. Their single medullated processes divide, however, soon after leaving the cells into branches which divide further and which do not pass beyond the bounds of the ganglia but terminate, after losing their medullary sheaths, in complicated pericapsular and pericellular end-plexuses surrounding the capsules and cell-bodies of the typical spinal ganglion cells. (3) Multipolar ganglion cells; in nearly all spinal and cranial ganglia there are found a few multipolar nerve-cells, which in shape and structure resemble the nerve-cells of the sympathetic system.




Fig. 318.—Diagram showing the relations of the neurones of a spinal ganglion; *p. r.*, posterior root; *a. r.*, anterior root; *p. s.*, posterior branch and *a. s.*, anterior branch of spinal nerve; *w. r.*, white ramus communicans; *a*, large, and *b*, small spinal ganglion cells with T-shaped division of process; *c*, type II spinal ganglion cells (Dogiel); *s*, multipolar cell; *d*, nerve-fiber from sympathetic ganglion terminating in pericellular plexuses (slightly modified from diagram given by Dogiel).

Entering the spinal ganglia from the periphery are found a relatively small number of small, medullated or nonmedullated nerve-fibers, probably derived from sympathetic ganglia. These nerve-fibers, medullated and nonmedullated, the former losing their medullary sheaths within the ganglia, approach a spinal ganglion cell, and after making a few spiral turns about its process, terminate in pericapsular and pericellular end-plexuses. Dogiel believes that the cell-bodies and capsules thus surrounded by the terminal branches of the sympathetic fibers terminating in the spinal ganglia belong to the spinal ganglion cells of the second type first described by him. In figure 318 is represented by way of diagram the structure of a spinal ganglion.

In the medium-sized cells (from 30  $\mu$  to 45  $\mu$  in diameter) of the

spinal ganglia of the frog, von Lenhossék (95) found centrosomes surrounded by a clear substance (centrospheres). The entire structure lay in a depression of the nucleus and contained more than twelve extremely minute granules (centrosomes), which showed a staining reaction different from that of the numerous concentrically laminated granules present in the protoplasm. This observation is interesting in that it proves that centrosome and sphere occur also in the protoplasm of cells which have not for a long time undergone division and in which there is no prospect of future division.

**Sympathetic Ganglia.**—The ganglia of the sympathetic nervous system comprise those of the two great ganglionated cords, found on each side of the vertebral column and extending from its cephalic to its caudal end, with which may be grouped certain cranial ganglia having the same structure,—namely, the sphenopalatine, otic, ciliary, sublingual, and submaxillary ganglia; also three un-

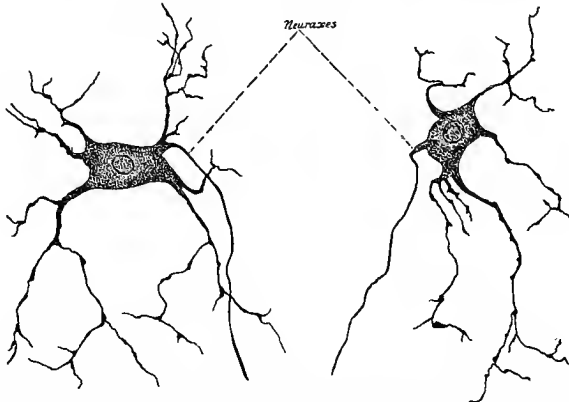


Fig. 319.—Neurone from inferior cervical sympathetic ganglion of a rabbit; methylene-blue stain.

paired aggregations of ganglia, found in front of the spinal column, of which the cardiac is in the thorax, the semilunar in the abdomen, and the hypogastric in the pelvis; and further, large numbers of smaller ganglia, the greater number of which are of microscopic size and are found in the walls of the intestinal canal and bladder, in the respiratory passages, in the heart, and in or near the majority of the glands of the body.

The sympathetic ganglia are inclosed in fibrous tissue capsules continuous with the perineural sheaths of their nerve-roots. The thickness of the capsule bears relation to the size of the ganglion, being thicker in the larger and thinner in the smaller ones. From these capsules thin connective-tissue septa or processes pass into the interior of the ganglia, supporting the nerve elements.

The sympathetic neurones, the cell-bodies and dendritic processes of which are grouped to form the sympathetic ganglia, are variously

shaped unipolar, bipolar, and multipolar cells, the cell-bodies of which are surrounded by nucleated capsules, continuous with the neurilemma of their neuraxes. In the sympathetic ganglia of mammalia and birds the great majority of sympathetic neurones are multipolar, although in nearly all ganglia a small number of bipolar and unipolar cells are to be found, usually near the poles of the ganglia.

The dendrites of the sympathetic neurones in any one ganglion branch repeatedly. Of these branches, some extend to the periphery of the ganglion, where they interlace to form a peripheral subcapsular plexus, while others interlace to form plexuses between the cell-bodies of the neurones in the interior of the ganglion—**pericellular plexuses**. These pericellular plexuses are external to the capsules surrounding the cell-bodies of the sympathetic neurones.

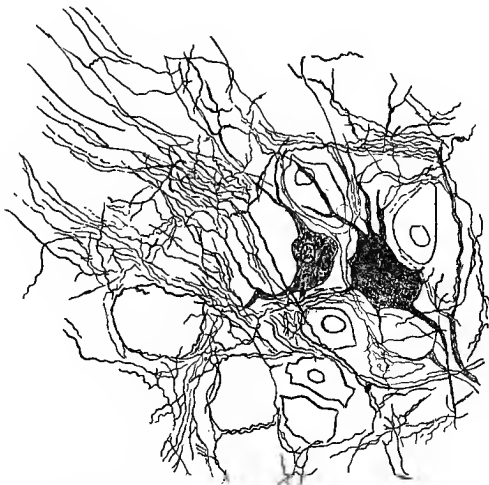


Fig. 320.—From section of semilunar ganglion of cat; stained in methylene-blue, *intra vitam* (Huber, *Journal of Morphology*, 1899).

The neuraxes of the sympathetic neurones, the majority of which are nonmedullated, the remainder surrounded by delicate medullary sheaths, arise from the cell-bodies either from implantation cones or from dendrites at variable distances from the cell-bodies, leave the ganglion by way of one of its nerve-roots, and terminate in heart muscle tissue, nonstriated muscle, and glandular tissue, and to some extent in other ganglia, both sympathetic and spinal. Terminating in all sympathetic ganglia are found certain small medullated nerve-fibers, varying in size from about  $1.5 \mu$  to  $3 \mu$ . The researches of Gaskell, Langley, and Sherrington have shown that these small medullated nerve-fibers leave the spinal cord through the anterior roots of the spinal nerves from the first dorsal to the third or fourth lumbar and reach the sympathetic

ganglia through the *white rami communicantes*. Similar small medullated nerve-fibers are found in certain cranial nerves. These small medullated nerve-fibers, which may be spoken of as *white rami fibers*, after a longer or shorter course, in which they may pass through one or several ganglia without making special connection with the neurones contained therein, terminate in some sympathetic ganglion in a very characteristic manner. After entering the sympathetic ganglion in which they terminate, they branch repeatedly while yet medullated. The resulting branches then lose their medullary sheaths and divide into numerous small, varicose nerve-fibers, which interlace to form **intracapsular plexuses**, which surround the cell-bodies of the sympathetic neurones. In the sympathetic ganglia of mammalia such intracapsular pericellular

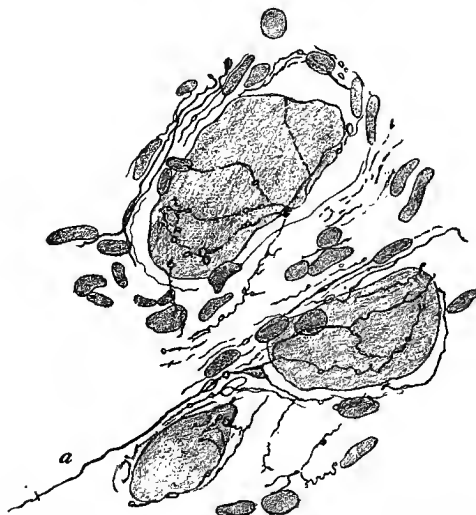

Fig. 321.—From section of stellate ganglion of dog, stained in methylene-blue and alum carmin: *a*, white ramus fiber (Huber, *Journal of Morphology*, 1899).

plexuses may be very simple, consisting of only a few varicose nerve-fibers, or very complicated, consisting of many such fibers. In the sympathetic ganglia of reptilia, in which are found very large sympathetic neurones, the white rami fibers are wound spirally about the cell-bodies of such neurones before terminating in complicated pericellular plexuses. In the frog and other amphibia the sympathetic neurones are unipolar nerve-cells. The white rami fibers terminating in the sympathetic ganglia of amphibia are wound spirally about the single processes of these unipolar cells while yet medullated fibers, but they lose their medullary sheaths before terminating in the intracapsular pericellular plexuses. From what has been said concerning the white rami fibers and their relation to the sympathetic neurones, it is evident that the sympathetic neu-

rones, the cell-bodies and dendrites of which are grouped to form the sympathetic ganglia, form terminal links in nerve or neurone chains; the second link of these chains is formed by neurones the cell-bodies of which are situated in the spinal cord or medulla, the

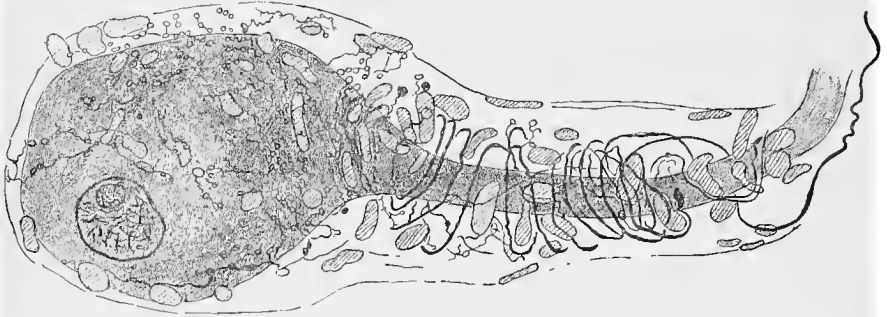


Fig. 322.—From section of sympathetic ganglion of turtle, showing white rami fibers wound spirally about a large process of a unipolar cell, and ending in pericellular plexus (Huber, *Journal of Morphology*, 1899).

neuraxes leaving the cerebrospinal axis through the white rami as small medullated nerve-fibers, which terminate in pericellular plexuses inclosing the cell-bodies of the sympathetic neurones.

Large medullated nerve-fibers, the dendrites of spinal ganglion neurones, reach the sympathetic ganglia through the white rami.

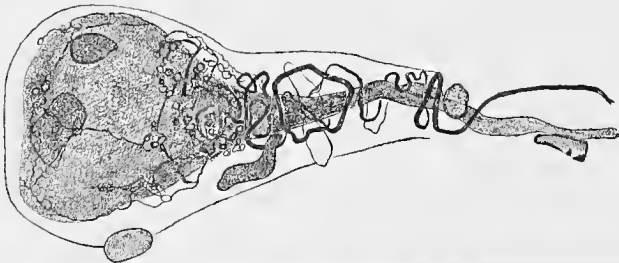


Fig. 323.—From section of sympathetic ganglion of frog, showing spiral fiber (white ramus fiber) and pericellular plexus (Huber, *Journal of Morphology*, 1899).

They make, however, no connection with the sympathetic neurones, but pass through the ganglia to reach the viscera, where they terminate in special sensory nerve-endings or in free sensory nerve-endings.

## G. GENERAL SURVEY OF THE RELATIONS OF THE NEURONES TO ONE ANOTHER IN THE CENTRAL NERVOUS SYSTEM.

The following figures illustrate the modern theories with regard to the relationship of the neurones in a sensorimotor reflex cycle. The pathway along which the impulse from the stimulated area of the body is transmitted to the motor nerve end-organ traverses two neurones (primary neurones) which are in contact by means of their telodendria situated within the gray matter of the spinal cord. The cell-body of the sensory neurone lies within the spinal ganglion; that of the motor neurone, in the anterior horn of the spinal cord. The dendrite of the sensory neurone commences

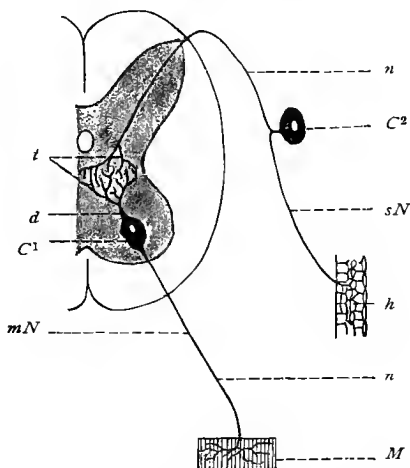


Fig. 324.—Schematic diagram of a sensorimotor reflex arc according to the modern neurone theory; transverse section of spinal cord:  $mN$ , Motor neurone;  $sN$ , sensory neurone;  $C^1$ , nerve-cell of the motor neurone;  $C^2$ , nerve-cell of the sensory neurone;  $d$ , dendrite;  $n$ , neuraxis of both neurones;  $t$ , telodendria;  $M$ , muscle-fiber;  $h$ , skin with peripheral telodendrium of sensory neurone.

as a telodendrium in the skin and transmits a cellulipetal impulse, while its cellulifugal neuraxis and telodendrium (the latter in the gray matter of the cord) transfer the impulse to the cellulipetal telodendrium of the motor neurone. The cellulifugal neuraxis of the latter finally ends as a telodendrium in the muscle. (Figs. 324 and 325.)

In the case of longer tracts the conditions are somewhat more complicated, as, for instance, in tracing the impulse along the sensory fibers to the cortex of the brain, and from there along the motor fibers to the responding muscle. In such cases secondary neurones are called into play by means of their telodendria, which are necessarily in contact with the primary neurones just described.

When we take into consideration the simplest possible case, that of the motor segment of such a neurone-chain, we find, for instance (Fig. 326), that the neuraxis of a pyramidal cell in the brain cortex (psychic cell) enters the white substance and traverses it as a nerve-fiber through the peduncle and the pyramid into the crossed pyramidal tract of the opposite side. Here its telodendria come in contact with those of the motor neurone of the anterior horn.

In the foregoing instance the motor nerve tract is composed of two neurones—of a motor neurone of the first order, extending from the cortex of the brain to the anterior cornua of the spinal cord, and of a motor neurone of the second order, the elements of which extend from the anterior cornua to the telodendria in the muscle.

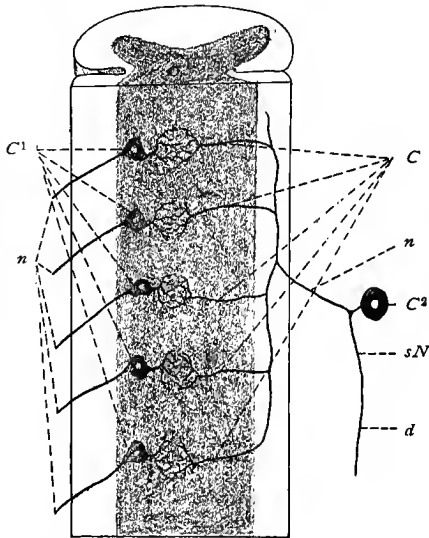


Fig. 325.—Schematic diagram of a sensorimotor reflex cycle; sagittal section of the spinal cord:  $C^1$ , Motor cells of the anterior cornua;  $n, n$ , neuraxes;  $sN$ , sensory neurone;  $C^2$ , spinal ganglion cell;  $C$ , collaterals of the sensory neuraxes;  $d$ , dendrite of sensory neurone; the broken lines at the cells on the left indicate their dendrites.

The sensory tract may likewise be composed of neurones of the first and second orders. The cellulifugal neuraxis arising from a cell of the spinal ganglion passes to the posterior column of the cord, gives off collaterals to the latter, and then passes upward by means of its ascending branch through the posterior column to the medulla. Although here the relationship is not so clearly defined as in the motor tract, it may nevertheless be assumed that the cellulifugal (but centripetally conducting) neuraxis at some point or other terminates in telodendria (sensory neurone of the first order), which enter into contact with the corresponding structures of a cell of the spinal cord or medulla oblongata. These cells would then

constitute the sensory neurones of the second order. Exactly how their cellulifugal neuraxes end has not as yet been fully determined, but it is very probable that in this case the telodendria are represented by the coarse end-fibers which penetrate into the brain cortex, and here seem to come in contact with the dendrites of the pyramidal cells.

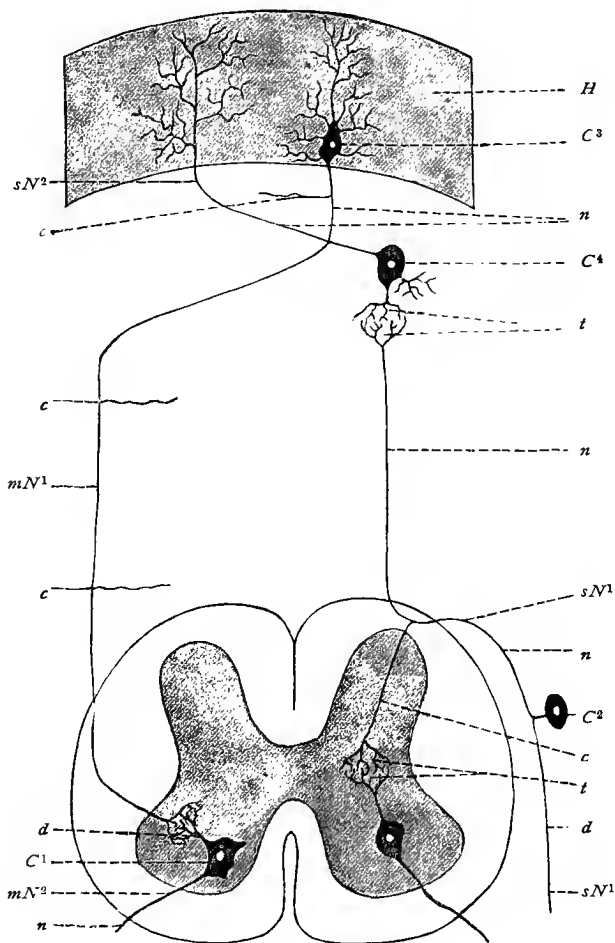


Fig. 326.—Schematic diagram of the reflex tracts between a peripheral organ and the brain cortex: *H*, Cerebral cortex; *mN*<sup>1</sup>, motor neurone of the first, *sN*<sup>2</sup>, sensory neurone of the second, degree; *C*<sup>1</sup>, motor cell of the spinal cord; *C*<sup>2</sup>, sensory cell of a spinal ganglion; *C*<sup>3</sup>, pyramidal cell of the brain cortex (psychic cell); *C*<sup>4</sup>, nerve-cell of a sensory neurone of the second degree; *n*, *n*, *n*, *n*, neuraxes; *d*, *d*, dendrites; *c*, *c*, *c*, *c*, collaterals; *t*, *t*, telodendria; *sN*<sup>1</sup>, sensory neurone first degree; *mN*<sup>2</sup>, motor neurone second degree.

## H. THE NEUROGLIA.

We may now consider the **neuroglia**, a tissue distributed throughout the central nervous system and looked upon as a supporting tissue. Its relation to the other tissues has long been a matter of controversy, but modern observers have shown conclusively that the neuroglia is of ectodermic origin, at least so far as its cellular elements are concerned.

At an early stage of embryonic development there are seen in the spinal cord, and also in the brain, elements radially disposed around the neural canal, which upon closer observation appear to be processes emanating from the epithelial cells lining the neural canal. These processes may undergo repeated dichotomous division,

ending finally in a swelling near the periphery of the cord.

These cells are known as **ependymal cells**, and are differentiated from ectodermal cells, called **spongioblasts**.

In later stages the radial arrangement is still preserved, but the cell-bodies no longer all border upon the central canal, many being found at varying distances from the latter.

At this stage in the development of the spinal cord, the elements retaining their original characteristics are situated only in the region of the ventral and dorsal fissures of the spinal cord, and during further development increase in number.

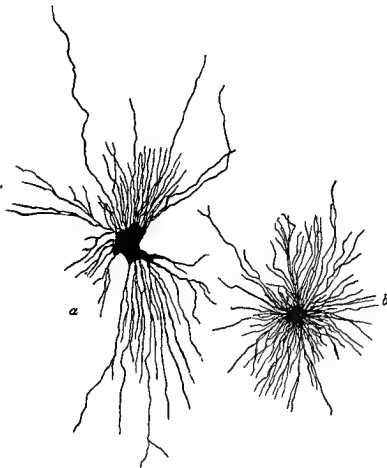


Fig. 327.—Neuroglial cells: *a*, From spinal cord of embryo cat; *b*, from brain of adult cat; stained in chrome-silver.

These observations would seem to indicate that at least a portion of the neuroglial cells, which develop from the ependymal cells previously mentioned, originate from the epithelium of the central canal, and that from here they are gradually pushed toward the periphery of the cord. This assumption is still further strengthened by the fact that later the epithelial cells of the central canal still continue to divide. Later observations (Schaper, 97) show, however, that neuroglial cells develop also from certain undifferentiated germinal cells of the neural canal, of ectodermic origin, which wander from their position near the neural canal toward the periphery of the medullary tube, where they develop into neuroglial cells.

In the adult the epithelium of the central canal and that of the brain cavities (the ependyma) is of the pseudostratified variety with

two or three strata of nuclei. The basilar processes of the cells are very long, may be branched, and, as a rule, describe a tortuous course.

The shape and structure of the neuroglial cells (spider-cells) vary somewhat in different parts of the central nervous system. From the bodies of these cells numerous delicate processes are sent out, which in the one variety of cell—that occurring principally in the white matter—do not branch. Similar cells, with shorter but occasionally dividing processes, are situated for the most part in the gray matter. Other neuroglial cells may be distinguished from the varieties just described by the smaller number of their processes and by their correspondingly larger bodies.

A large proportion of the fine fibers found in the gray and the white matter are processes of the neuroglial cells. Whether the spinal cord contains other similar cellular and fibrillar elements of *mesodermic* origin is an unsettled question. There seems to be no doubt, however, that connective tissue (other than that composing the pial processes) always accompanies the numerous blood-vessels penetrating into the spinal cord.

The majority of investigators have described the various fibers and fibrils brought to view by certain methods as processes of the neuroglial cells. Weigert (95) and Mallory have demonstrated, by means of special methods, the existence of neuroglia-fibers in the adult human brain which are nowhere connected with cellular elements, although they frequently group themselves around a cell as an axis, and thus simulate with the latter the “spider-cells” of some authors. The neuroglial elements of the embryo and fetus have as yet never been demonstrated by Weigert’s method, but have, as a rule, been studied by means of Golgi’s method. Reinke (97) has very recently found in the white matter of the adult human spinal cord neuroglial cells with processes and neuroglia-fibers having no connection with cells.

## I. THE MEMBRANES OF THE CENTRAL NERVOUS SYSTEM.

The membranes of the central nervous system (meninges) are three in number: the outer, or *dura mater*; the middle, or *arachnoid*; and the inner, or *pia mater*.

Around the brain the **dura mater** is very intimately connected with the periosteum and presents a smooth inner surface. It consists of an inner and an outer layer, the two being separated from each other only in certain regions. At such points either the inner layer is pushed inward to form a duplicature, as in the falx cerebri and falx cerebelli, tentorium, and diaphragma sellæ, or the outer layer is pushed outward to form small, blindly ending sacs. The venous and lymphatic sinuses lie between the two layers. The outer

layer of the dura is continued some distance along the cerebrospinal nerves.

The dura mater of the spinal cord does not form the periosteum for the bones forming the vertebral canal; these possess their own periosteum. The spinal dura mater is covered on its outer surface by a layer of endothelial cells and is separated from the wall of the vertebral canal by the *epidural space*, containing a venous plexus imbedded in loose areolar connective tissue and adipose tissue.

The dura consists chiefly of connective-tissue bundles having a longitudinal direction along the spinal cord. Within the cranium, however, the bundles of the inner and outer layers cross each other; those of the outer having a lateral direction anteriorly and a mesial posteriorly; those of the inner, a mesial direction anteriorly and a lateral posteriorly. In the falx cerebri, tentorium, etc., the fibers are arranged radially, extending from their origin toward their borders. The shape and size of the connective-tissue cells vary greatly, and their processes form a network around the bundles of connective tissue. Few elastic fibers are present, and, according to K. Schultz, these are entirely absent in the new-born; they are somewhat more numerous in the dura of the spinal cord. The dura is very rich in blood-capillaries, and the presence of lymphatic channels in communication with the subdural space may be demonstrated by means of puncture-injections. The inner surface of the dura mater is covered by a layer of endothelial cells.

The dura mater is quite richly supplied with nerves, especially in certain regions. These are of two varieties: (1) Vasomotor fibers, which form plexuses in the adventitial coat of the arteries, and would seem to terminate in the muscular coat of the arteries; (2) medullated nerve-fibers, which either accompany the blood-vessels in the form of larger or smaller bundles or have a course independent of the vessels. After repeated division these medullated nerve-fibers lose their medullary sheaths and terminate between the connective-tissue bundles in fine varicose fibrils, which may often be traced for long distances (Huber, 99).

The **arachnoid** is separated from the dura by a space which is regarded as belonging to the lymphatic system—the *subdural space*. The outer boundary of the arachnoid consists, as does the inner lining of the dura, of a layer of flattened endothelial cells. The arachnoid is made up of a feltwork of loosely arranged connective-tissue trabeculæ, which also penetrate into the lymph-space between it and the pia—the *subarachnoid space*. For a short distance from their points of origin the cerebrospinal nerves are accompanied by arachnoid tissue. In the brain the arachnoid covers the convolutions and penetrates with its processes into the sulci. These processes are especially well developed in the so-called cisterns; in the cisterna cerebellomedullaris, fossæ Sylvii, etc. In the spinal cord the subarachnoid space is separated by the ligamenta denticulata into two large communicating spaces—a dorsal and a ven-

tral. The dorsal space is further divided by the *septum posticum*, best developed in the cervical region.

At certain points, usually along the superior longitudinal sinus, the outer surface of the arachnoid is raised into villi, which are covered by the inner layer of the dura, and form with the latter the **Pacchionian bodies** or granulations. These villi are connected with the arachnoid by pedicles so delicate that they often seem to be suspended free in the venous current of the sinus.

The subarachnoid space contains numerous blood-vessels, some of which are free and others attached to the arachnoid. Their adventitia is covered by endothelium; hence the subarachnoid space would seem to assume here the character of a perivascular space.

The trabeculæ and membranes composing the arachnoid tissue show a great similarity to those of the mesentery, and especially to those of the omentum. The whole constitutes a typical areolar connective tissue, interrupted at numerous points and covered by a continuous layer of endothelial cells. Large numbers of spiral fibers are found here twining around single or groups of connective-tissue fibers.

The **pia mater** covers the entire surface of the brain and spinal cord, dipping down into every fissure and crevice. In the spinal cord it consists of an outer and an inner lamella, the former being composed of bundles of connective tissue containing elastic fibers. As a rule, the course of the fibers is longitudinal. Externally this layer is covered by a layer of endothelium. The blood-vessels lie between the outer and inner layers of the pia. The inner layer (*pia intima*) is made up of much finer elements, and is covered on both sides by endothelium. It is this layer which accompanies the blood-vessels penetrating into the spinal cord, surrounding their adventitia and forming with the latter the limits of their perivascular spaces. These are in communication with the

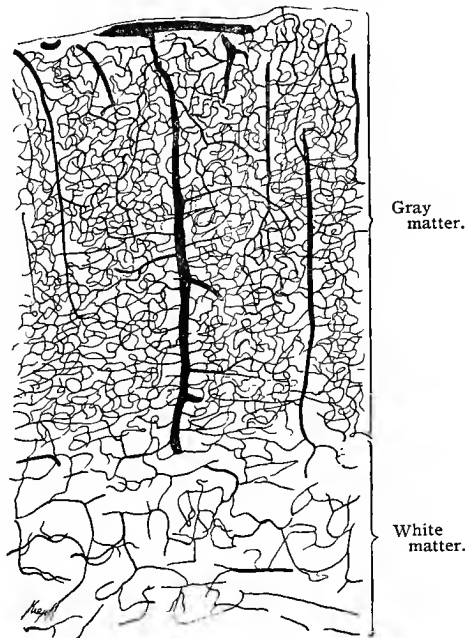


Fig. 328.—Section through the cerebral cortex of a rabbit. The blood-vessels are injected;  $\times 40$ .

interstitial spaces, and, by means of the adventitia of the blood-vessels, with the subarachnoid space. Aside from those just described, numerous fine, nonvascular, connective-tissue septa penetrate from the pia mater into the substance of the spinal cord. Wherever the pia mater penetrates the spinal cord, the latter is hollowed out, forming the so-called *pial funnels*.

The pia does not everywhere lie in direct contact with the surface of the spinal cord; for between the cord and the pia there is generally found a neuroglial covering, formed by the expanded ends of the radial processes from the neuroglial cells (glia covering or subpia). The posterior longitudinal septum of the spinal cord consists (in the thoracic region) exclusively of neuroglial elements, but in the cervical and lumbar regions the pia also enters into its peripheral formation.

In the brain, however, the conditions are somewhat different. Here the external layer of the pia disappears, leaving only a single layer analogous to the pia intima of the spinal cord.

The pia mater enters into the formation of the **choroid plexus**. This structure consists of numerous freely anastomosing blood-vessels, which form villus-like processes, the surfaces of which are covered by squamous or cubic epithelial cells. This epithelium is regarded as a continuation of the ventricular epithelium, and is ciliated, at least in embryonic life and in the lower classes of vertebrates. From an embryologic point of view the whole structure represents the brain-wall reduced to a single layer of epithelium (internal epithelial investment) pushed forward into the ventricle by the vessels and pia mater.

Since the dura and arachnoid accompany the cerebrospinal nerves for some distance, it is obvious that the lymph-vessels of the nasal mucous membrane (see these) may also be injected from the subarachnoid space (compare also Key and Retzius).

The pia mater, like the dura mater, receives two varieties of nerve-fibers: (1) Vasomotor fibers, which form plexuses in the adventitial coat of the arteries and terminate in the muscular layer of the arteries. These may be traced to the small precapillary branches of the vessels. (2) Larger and smaller bundles of relatively large, medullated nerve-fibers, which accompany the larger pial vessels, forming loose plexuses in or on the adventitial coat of the vessels. After repeated divisions these medullated nerves lose their medullary sheaths and terminate, in the adventitia of the vessels, in long, varicose fibrils or in groups of such fibrils (Huber, 99).

## J. BLOOD-VESSELS OF THE CENTRAL NERVOUS SYSTEM.

The blood-vessels of the central nervous system present certain peculiarities, which deserve special consideration.

In the spinal cord the arteries, surrounded by pial tissue (connective-tissue septa), extend as far as the gray matter, but give off numerous lateral branches during their course through the white matter. The capillaries form a much closer meshwork in the gray matter than in the white.

The perivascular spaces throughout the central nervous system are separated from the substance of the brain and spinal cord by an endothelial membrane, the internal endothelial layer of the pia intima (Key and Retzius), and are easily injected from the pia.

In the cerebral cortex the capillaries are particularly numerous, and are closely meshed wherever groups of ganglion cells occur. In the medullary substance they are somewhat less closely arranged, their meshes being oblong.

In the cerebellum the arrangement is analogous. Of all the layers composing the cerebellum the granular is the most vascular; within it the capillaries are also densely arranged, and form a close network.

### TECHNIC.

**300.** The organs of the central nervous system are best fixed in Müller's fluid (*vid.* T. 27), washed with water, cut in celloidin, and stained with carmin. Such preparations are suitable for general topographic work.

**301.** Special structures—as, for instance, the medullary sheaths of the nerve-fibers, the ganglion cells, the relations of the different neurones and dendrites to one another, etc.—require different treatment.

**302.** The medullary sheath may be demonstrated as follows (Weigert): Pieces of tissue (spinal cord, for instance), fixed as usual in Müller's or Erlicki's fluid (*vid.* T. 27 and 29), are transferred without washing to alcohol, imbedded in celloidin, and cut. Before staining the sections it is necessary to subject them to the mordant action of a neutral copper acetate solution (a saturated solution of the salt diluted with an equal volume of water). The sections may be subjected to the mordant action of this solution, but the following procedure is more convenient: The specimens, imbedded in celloidin and fastened to a cork or a block of wood, are placed for one or two days in the copper solution just described. At the expiration of this time the pieces of tissue will have become dark, and the surrounding celloidin light green. They are then placed in 80% alcohol, in which they may be preserved for any length of time. The sections are then stained in the following solution: 1 gm. of hematoxylin is dissolved in 10 c.c. absolute alcohol, and 90 c.c. of distilled water are then added (the fluid must remain exposed to the air for a few days); the addition of an alkali—as, for instance, a cold saturated solution of lithium bicarbonate (1 c.c. to 100 c.c. of hematoxylin solution)—brings out the staining power of the solution at once. In

this stain the sections are placed (at room-temperature) for a day, and then in a thermostat (40° C.) for a few hours. The sections, now quite dark, are washed in distilled water and then placed in the so-called differentiating fluid. The latter consists of borax 2 gm., ferrocyanid of potassium 2.5 gm., and distilled water 100 gm. In this fluid the color of the sections is differentiated by virtue of the circumstance that the medullary sheath retains the dark stain, while the remaining structures, such as the ganglion cells, etc., are bleached to a pale yellow. The time required for this differentiation varies, but it is usually complete at the end of a few minutes. The sections are then washed in distilled water, dehydrated in alcohol, cleared in carbol-xylol (carbolic acid 1 part, xylol 3 parts) and mounted in balsam.

303. Weigert's new method is more complicated, but fruitful of correspondingly better results. The preliminary treatment remains the same. After the tissues have been imbedded in celloidin and this hardened in 80% alcohol, they are transferred to a mixture composed of equal parts of a cold saturated aqueous solution of neutral copper acetate and 10% aqueous solution of sodium and potassium tartrate, and the whole is placed in the thermostat. Larger pieces—as, for instance, the pons Varolii of man—may remain in the solution longer than twenty-four hours, after which time, however, the mixture must be changed; but in no case should the specimens be permitted to remain longer than forty-eight hours in this solution. The temperature in the thermostat should not be high, otherwise the specimens will become brittle. The objects are now placed in a simple aqueous solution of neutral copper acetate, either saturated or half diluted with water, and again put in the oven. They are then rinsed in distilled water and placed in 80% alcohol; after remaining in this for one hour, they are in a condition to cut, but may be preserved still longer if desired. Cut and stain in the customary manner. The staining solution is prepared as follows: (*a*) lithium carbonate 7 c.c. and distilled water 93 c.c. (saturated aqueous solution); (*b*) hematoxylin 1 gm., absolute alcohol 10 c.c.; both *a* and *b* keep for some time, and may be kept on hand as stock solutions. Shortly before using, 9 parts of *a* and 1 part of *b* are mixed. After remaining in this solution for from four to five hours at room-temperature the sections are well stained, but do not overstain even if allowed to remain in the solution for twenty-four hours. In the case of loose celloidin sections the use of the differentiating fluid is superfluous. Hence this method is particularly advantageous when the gray and the white matter can not be distinguished macroscopically. Finally, the sections are washed in water, placed in 95% alcohol, cleared with carbol-xylol or anilin-xylol (in the latter case carefully washed with xylol), and mounted in xylol-balsam. The medullated fibers appear dark blue to black, the background pale or light pink, and the celloidin occasionally bluish. In order to remove the latter color, it is only necessary to wash the sections in 0.5% acetic acid instead of ordinary water; a process, however, not to be recommended in the case of very delicate preparations—as, for instance, the cerebral cortex. In applying Weigert's methods a certain thickness of section (not exceeding 25  $\mu$ ) is essential, since in thicker sections the medullary sheaths are not sharply differentiated from the surrounding tissue.

For thick sections the modified Weigert method, or **Pal's method**, is employed. After the specimens have been treated according to Wei-

gert's method up to the point of staining with hematoxylin, they are placed for from twenty to thirty minutes in a 0.25% solution of potassium permanganate. As differentiating fluid a solution of oxalic acid 1 gm., potassium sulphite 1 gm., and water 200 c.c. is used, care being taken, as in the case of Weigert's differentiating fluid, that the gray matter is thoroughly bleached (here entirely colorless) and the white matter dark. By this method the medullary sheaths are stained blue, while the rest of the structure remains colorless. The staining is very precise, but not so intense as by Weigert's method. Hence its adaptability for thicker sections.

**Benda's method** is a modification of the Weigert-Pal methods. The tissues are hardened in Müller's or Erlicki's fluid, imbedded in celloidin, and cut. The sections are then subjected to the action of the following mordant for from twelve to twenty-four hours: liquor ferri ter sulphatis 1 part, distilled water 2 parts. They are then thoroughly rinsed in two tap-waters and one distilled water and then stained in the following hematoxylin solution: hematoxylin 1 gm., absolute alcohol 10 c.c., distilled water 90 c.c.; in which they remain for twenty-four hours. They are next washed in tap-water for from ten to fifteen minutes and treated with a 0.25% aqueous solution of permanganate of potassium until the gray and the white matter are differentiated, after which they are rinsed in distilled water and bleached in the following solution until the gray matter has a light yellow color: hydric sulphite 5 to 10 parts, distilled water 100 parts. The sections are then washed in tap-water for from one to two hours, rinsed in distilled water, dehydrated, cleared in carbol-xytol, and mounted in balsam. Medullary sheaths will be stained a bluish-black; other structures, a light yellow. Sections stained after the Weigert, Pal, or Benda method may be counterstained in Van Gieson's picric-acid-fuchsin stain (1% aqueous solution of acid fuchsin, 15 parts; saturated aqueous solution of picric acid, 50 parts; distilled water, 50 parts). The fibrous connective tissue in the sections and degenerated areas stains a light red.

304. Two important methods have lately been devised for the demonstration of ganglion cells with their processes and fibrils. They are Golgi's chrome-silver method and Ehrlich's methylene-blue method.

305. Golgi's methods will perhaps be better understood if we first give a short historic sketch of their development.

In the year 1875 Golgi applied his method as follows: He fixed (olfactory bulb) in Müller's fluid, and increased the percentage of bichromate on changing the fluid (up to 4%). Fixation lasted five or six weeks in summer and three or four months or more in winter. He then took out pieces of the tissue every four or five days and treated them experimentally with a 0.5% to 1% silver nitrate solution. In summer this process took about twenty-four hours, and in winter forty-eight hours, although a longer treatment was not found to be detrimental. This method must be regarded as very uncertain, since the length of time during which the specimens remain in Müller's fluid must be very closely calculated, as it depends largely upon the temperature of the medium. As soon as the silver reaction was established, the pieces were preserved either in the silver solution itself or in alcohol. The sections were finally washed in absolute alcohol, cleared with creosote, and mounted in Canada balsam. The impregnation disappeared in a short time. In the year 1885 Golgi made a further announcement regarding his method, recommending for fixation the pure bichromate of potassium, as well as Müller's fluid. Pieces of the brain and spinal cord (from 1 to 1.5 c.c. in size) from a freshly killed animal were used, and the reaction sometimes took place in from twenty-four to forty-eight hours after death. For fixing, potassium bichromate solution in gradually ascending strengths (1% to 5%) was employed, large amounts of the fluid being used and placed

in well-sealed receptacles. The fluid was repeatedly changed, and camphor or salicylic acid was added in order to prevent the growth of fungi. Since it is difficult to determine exactly when fixation in potassium bichromate reaches the precise point favorable to subsequent treatment with nitrate of silver, because the process depends entirely upon the temperature and quantity of the fluid, it becomes necessary, after about six weeks' treatment with the bichromate, to experiment every eight days or so to see whether the silver nitrate gives good results. The strength of the latter should be about 0.66% and the quantity about 200 c.c. to a 1 c.c. object. At first a plentiful precipitate is thrown down, in which case the solution should be changed, and this probably repeated once more after a few hours. After twenty-four hours, at the most forty-eight hours, this process is usually completed, and the tissues may be sectioned. The sections must then be carefully dehydrated with absolute alcohol, cleared in creosote and mounted without a cover-glass in Canada balsam (the section is mounted on a cover-glass with Canada balsam, and the cover-slip then fastened over the opening of a perforated slide with the specimen downward).

306. In order to obtain a uniform penetration of the objects by the potassium bichromate, the latter may be first injected into the vessels. Golgi uses potassium bichromate-gelatin (2.5% of the salt, based on the amount of the softened gelatin; compare Golgi, 93). After the injection and cooling of the specimen the latter is cut in small pieces and treated in the manner previously described. Instead of Müller's fluid, that of Erlicki may be used, the time of treatment being then shorter (from five to eight days).

The objects may also be treated with a potassium bichromate-osmic acid solution (2.5% solution of potassium bichromate, 8 vols.; 1% osmic acid, 2 vols.), the sections thus treated being ready for immersion in silver nitrate after two or three days. It is advisable to treat the objects with the potassium bichromate solution first, and then with the potassium bichromate-osmic mixture. By this method the specimens remain under the control of the investigator; they may be examined either at once, or after an interval varying between three or four and twenty-five to thirty days after immersion. If then one or several pieces of tissue are taken, at intervals of two, three, or four days, from the potassium bichromate solution and placed in the potassium bichromate-osmic acid mixture, and then in the silver nitrate solution, various combinations of the fluids result, and the investigator is usually rewarded with at least some sections giving most excellent results.

307. Another one of Golgi's methods consists in successive treatment with potassium bichromate and bichlorid of mercury. After remaining in the potassium bichromate for from three to four weeks (a longer period is allowable), the objects are placed in a 0.25% to 1% solution of corrosive sublimate. In the latter the specimens blacken much more slowly than in the silver nitrate solution—eight to ten days for smaller pieces; for larger ones, two months, and in some cases even longer. Before mounting the preparations in glycerin or Canada balsam they must be carefully washed; otherwise pin-shaped crystals form within the sections and distort the whole view. The metallic white of the preparation may be changed to black by placing the celloidin section in a photographer's toning solution consisting of: (a) sodium hyposulphite 175 gm., alum 20 gm., ammonium sulphocyanid 10 gm., sodium chlorid 40 gm., and water 1000 gm. (the mixture must stand for eight days and then be filtered); (b) a 1% gold chlorid solution. The specimen is placed for a few minutes in a solution composed of 60 c.c. of a and 7 c.c. of b, washed again in distilled water, dehydrated with alcohol, and mounted in Canada balsam. After toning and washing, the sections may still be stained.

Golgi's methods are extremely inconstant in their results. When successful, however, only a few elements are blackened each time, an advantage not to be underestimated; for if all nerves should stain equally well, discrimination between the various elements in the preparation would be very difficult. Neither are the same structures always impregnated; sometimes it is the ganglion cells and fibers, at other times the neuroglial cells, and occasionally only the vessels.

After the foregoing explanation of Golgi's methods as applied by himself, we shall append a description of these methods as modified and employed at the present time (Ramón y Cajal, Kölliker, von Lenhossék and others).

Golgi's methods are classified as the slow, the mixed, and the rapid.

The **slow method** requires a preliminary treatment. Pieces of tissue from 1 to 2 cm. in diameter are placed for from three to five weeks

in a 2% potassium bichromate solution; they are then transferred for from twenty-four to forty-eight hours to a 0.75% silver nitrate solution, or for a much longer time to a 0.5% solution of corrosive sublimate.

In the **mixed method** the specimens are allowed to remain for four or five days in a 2% aqueous potassium bichromate solution; then for from twenty-four to thirty hours in a mixture consisting of 1% osmic acid 1 vol., and 2% potassium bichromate solution 4 vols. They are then treated with a 0.75% silver nitrate solution for one or two days.

When the **rapid method** is employed, the specimens are immediately placed in a mixture consisting of 1 vol. of 1% osmic acid and 4 vols. of a 3.5% potassium bichromate solution, and, finally, for one or two days in a 0.75% silver nitrate solution, to every 200 c.c. of which one drop of formic acid has been added.

When employing these methods, and more particularly the one last described (which seems to be the most efficient), the following conditions must be carefully observed: If possible, the material should be absolutely fresh, the specimens must not exceed 3 or 4 mm. in thickness, and for every piece of tissue treated about 10 c.c. of the osmium-potassium bichromate mixture should be employed, the specimens remaining in the latter (in the dark) at a temperature of 25° C. for a length of time varying according to the result desired (two or three days for the neuroglial cells, from three to five days for the ganglion cells, and from five to seven days for the nerve-fibers of the spinal cord). The objects are now dried with blotting-paper or washed quickly in distilled water and then placed for two or three days in a 0.75% silver nitrate solution at room-temperature. In this they may remain for four or five days without damage, but not longer, as otherwise the precipitate becomes markedly granular (*vid. v. Lenhossék, 92*).

**308.** If Golgi's method be unsuccessful (this applies to all its modifications), the preparations may be transferred from the silver nitrate solution back into a potassium bichromate-osmic acid mixture containing less osmic acid, in which they remain several days, and are then again placed in the silver nitrate solution for from twenty-four to forty-eight hours. This procedure may even be repeated.

**309.** Cox obtains a precipitate in both cells and fibers by treating small pieces of the central nervous organs with a mixture composed of potassium bichromate 20 parts, 5% corrosive sublimate 20 parts, distilled water 30 to 40 parts, and 5% potassium chromate of strong alkaline reaction 16 parts. The specimens remain in this mixture from one to three months, according to the temperature, and are then further treated according to Golgi's method.

As the chrome-silver preparations are not permanent, and can not, therefore, be subsequently stained, Kallius has suggested that the chrome-silver precipitate be reduced to metallic silver by treatment with the "quintuple hydroquinon developer" (hydroquinon 5 gm., sodium sulphite 40 gm., potassium carbonate 75 gm., and distilled water 250 gm.). For this purpose 20 c.c. of the solution are diluted with 230 c.c. of distilled water; this mixture may be preserved in the dark for some time if desired. Before using this latter solution, it should be mixed with  $\frac{1}{3}$ , or at the most  $\frac{1}{2}$ , of its volume of absolute alcohol. The sections are placed in a watch-crystal containing some of the latter mixture until they turn black (a few minutes). As soon as the silver salt is completely

reduced, the sections are placed for from ten to fifteen minutes in 70% alcohol, then for five minutes in a 20% solution of sodium hyposulphite and, finally, washed for some time in distilled water, after which they may be stained, and even treated with acid alcohol and potassium hydrate.

The following simple method for permanently mounting Golgi preparations under a cover-glass has been recommended by Huber.

After impregnation with chrome-silver the tissues are hastily dehydrated, imbedded in celloidin, and cut in sections varying from 25  $\mu$  to 100  $\mu$  in thickness. The sections are then dehydrated and placed for from ten to fifteen minutes in creosote, from which they are carried into xylol, where they remain another ten minutes. The sections are then removed to the slide. The xylol is then removed by pressing several layers of filter-paper over the section. On removing the filter-paper the sections are quickly covered by a large drop of xylol balsam and the slide is carefully heated over a flame for from three to five minutes. Before the balsam cools the preparation is covered with a large cover-glass, warmed by passing several times through the flame.

**310.** Kopsch (96) places specimens in a solution composed of 10 c.c. of formalin (40% formaldehyd) and 40 c.c. of a 3.5% solution of potassium bichromate. For objects 2 c.c. in size 50 c.c. of the fluid are employed; but if the specimens be large, the mixture must be changed in twelve hours. At the end of twenty-four hours this fluid is replaced by a fresh 3.5% potassium bichromate solution, and the specimens are then transferred to a 0.75% solution of silver nitrate (after two days, if the tissue be the liver or stomach; and after from three to six days, if retina or central nervous system). After this treatment the objects are carried over into 40% alcohol and, finally, into absolute alcohol, imbedded as rapidly as possible, and cut. The sections are mounted in balsam without a cover-glass.

**311.** Ehrlich's methylene-blue method consists in an *intra vitam* staining of ganglion cells, nerve-fibers, and nerve-endings. The method is much more applicable to the staining of peripheral ganglia (spinal and sympathetic ganglia), peripheral nerves, and nerve-endings than to staining the elements of the central nervous system, although the latter may also be stained by means of this method.

Two methods for bringing the stain in contact with the nerve-tissues are now in use: (1) injecting the methylene-blue solution into the living tissues through the blood-vessels; (2) adding a few drops of the stain to small pieces of perfectly fresh tissues removed from the body. The solution used for injecting the tissues is prepared as follows: 1 gm. of methylene-blue<sup>1</sup> is mixed in a small flask with 100 c.c. of normal salt solution and heated over a flame until the solution becomes hot. It is then allowed to cool; when filtered, it is ready for use. A cannula is tied into the main artery of the part in which it is desired to stain the nerve elements, and sufficient of the foregoing methylene-blue solution injected to give the part a decidedly blue color. After the injection the part to be studied remains undisturbed for about one-half hour, after which time small, or at least thin, pieces of the tissue to be studied are removed to a slide moistened in normal salt solution, and exposed to the air. The tissues remain on the slide until the nerve-cells, nerve-fibers, or nerve-

<sup>1</sup> Methyleneblau, rectificiert nach Ehrlich, Grübler, Leipzig.

endings seem satisfactorily stained. After placing the tissues on the slide, they are examined under the microscope (without covering with a cover-glass) every two or three minutes, until such examination shows blue color in the neuraxes of the nerve-fibers and their terminations, or in the nerve-cells, if there be any in the tissues examined. Care should be taken not to miss the time when the staining has reached its full development, as the blue color usually fades again and only inferior preparations are obtained.

Tissues thus stained may be fixed by one of two methods (or modifications of these methods), the selection of the method depending somewhat on the results desired. If it is desired to gain preparations giving the general course of nerves, the formation of nerve-plexuses, the relations of afferent and efferent nerves to the nerve-cells in ganglia, or the general arrangement of the terminal branches of nerve-fibers in nerve end-organs, the tissues are placed in a saturated aqueous solution of ammonium picrate (Dogiel) in which the blue color of the tissues is in a short time changed to a purplish color. In this solution the tissues remain for from twelve to twenty-four hours, and are then transferred to a mixture consisting of equal parts of a saturated aqueous solution of ammonium picrate and glycerin, in which they remain another twenty-four hours; they may, however, without detriment remain in the mixture several days. The tissues are then mounted in this ammonium picrate-glycerin mixture.

If, on the other hand, it is desired to section tissues stained *intra vitam* in methylene-blue, the following method, slightly modified from that given by Bethe, is suggested. The following fixative is prepared: Ammonium molybdate, 1 gm.; distilled water, 10 c.c.; hydrochloric acid, 1 drop. The solution is prepared by grinding the ammonium molybdate to a fine powder, removing it to a flask, and adding the required quantity of water. The flask is now heated until the ammonium molybdate is entirely dissolved, when the hydrochloric acid is added. Before using this fixative it is necessary to cool it to 2°–5° C. It is, therefore, well to prepare it before the injection is made, and surround it with an ice mixture. In this fixative the tissues remain for from twelve to twenty-four hours. After the first six to eight hours it is not necessary to keep the fixative below ordinary room-temperature. After fixation the tissues are washed for an hour in distilled water. They are then hardened and dehydrated in absolute alcohol. It is advisable to hasten this step as much as possible, though not at the risk of imperfect dehydration. The tissues are then transferred to xylol and imbedded in paraffin, sectioned, fixed to the slide or cover-glass with albumin fixative, and may be double stained in alum-carmin or alum-cochineal. After staining in either of these stains, the sections are thoroughly dehydrated and cleared in oil of bergamot. The oil is washed off with xylol and the sections are mounted in Canada balsam.

**312.** In staining nerve-fibers with methylene-blue by local application of the stain to the tissues, the tissues to be studied are removed from an animal which has just been killed, divided in small pieces, and placed on a slide moistened with normal salt solution. A few drops of a  $\frac{1}{20}$ % to  $\frac{1}{10}$ % solution of methylene-blue in normal salt solution are added from time to time,—sufficient to keep the tissues moistened by the solution, but not enough to cover them. The preparations are examined from time to

time, under the microscope, to see whether the nerve elements are stained. The length of time required for staining by this method varies. Sometimes the nerve elements are stained in half an hour; again, it may require two and one-half hours; on an average, about one hour. As soon as the tissues seem well stained they are fixed as previously directed. Dogiel has found that sympathetic ganglia and sensory nerve-fibers of the heart removed from the human body several hours after death may be stained by means of the foregoing method.

In order to obviate the necessity for the low temperature of the previous method, Bethe (96) has recommended the following procedure: According to the method of Smirnow and Dogiel, he first employs as a preliminary fixing agent a concentrated aqueous solution of ammonium picrate. In this he places the tissue, previously treated with methylene-blue, for from ten to fifteen minutes. Without further washing the larger objects are immersed in a mixture composed of ammonium molybdate (or sodium phosphomolybdate) 1 gm., distilled water 20 c.c., and pure hydrochloric acid 1 drop. The following mixtures may also be employed for the same purpose: ammonium molybdate (or sodium phosphomolybdate) 1 gm., distilled water 10 c.c., 2% solution of chromic acid 10 c.c., and hydrochloric acid 1 drop; or, for very thin gross specimens or sections, ammonium molybdate (or sodium phosphomolybdate) 1 gm., distilled water, 10 c.c., 0.5% osmic acid 10 c.c., and hydrochloric acid 1 drop. Small objects are permitted to remain no longer than from three quarters of an hour to one hour in either of the first two mixtures, and not more than from four to twelve hours in the third. After fixing, the specimens are washed with water, carried over into alcohol, then into xylol, and finally imbedded in paraffin. Subsequent staining with alum-carmin, alum-cochineal, or one of the neutral anilin dyes gives good results.

**313.** A very promising method recommended by Meyer (95) consists in injecting subcutaneously about 20 c.c. of normal salt solution containing from 1% to 4% of methylene-blue into a young rabbit, and repeating the operation in one to two hours. Within the next two hours the animal usually dies and the central nervous organs are then removed and small pieces fixed according to Bethe's method.

**314.** Apáthy (97) demonstrates the fibrillar elements of the nervous system in invertebrates and vertebrates by means of his gold method. Fresh tissue may be used, or tissue already fixed. In the first case thin membranes are placed for at least two hours in a 1% solution of yellow chlorid of gold in the dark, then carried over without washing into a 1% solution of formic acid (sp. gr. 1.223), and finally exposed for from six to eight hours to the light (the formic acid may have to be changed). These specimens are best mounted directly in syrup of acacia or in concentrated glycerin. In his second method Apáthy fixes vertebrate tissues for twenty-four hours in sublimate-osmic acid (1 vol. saturated solution of corrosive sublimate in 0.5% sodium chlorid solution combined with 1 vol. 1% osmic acid solution), washes repeatedly in water, and places for twelve hours in an aqueous iodo-iodid of potassium solution (potassium iodid 1% and iodin 0.5%). The further treatment is the same as after ordinary corrosive sublimate fixation. Finally, the specimens are imbedded in paraffin with the aid of chloroform, cut, and mounted by the water method. The whole process, up to the point of imbedding in paraffin, is carried out in the dark. The sections are then passed through chloro-

form and alcohol into water, where they are allowed to remain for at least six hours; or they may be washed in water, placed for one minute in 1% formic acid, again washed in water, immersed for twenty-four hours in a 1% solution of gold chlorid, rinsed in water, and finally placed in a 1% formic acid solution and exposed to the light. For the latter purpose glass tubes are employed in which the slides are placed obliquely, with the sections downward. A uniform illumination of the section with "as intense a light and low a temperature" as possible are conditions indispensable to the attainment of successful results. The sections are then again washed in water and mounted in glycerin or syrup of acacia, or in Canada balsam after being dehydrated. Thin membranes are stretched upon small frames of linden wood especially prepared for this purpose. Their further treatment is then the same as that of sections fixed to the slide. If successful, the nerve-fibrils appear dark violet to black. The large ganglia in the spinal cord of lophius, the calf, etc., are especially recommended as appropriate vertebrate material.

Bethe (1900) has recommended the following method for staining neurofibrils and Golgi-nets in the central nervous system of vertebrates:

The perfectly fresh tissue is cut in thin lamellæ, varying in thickness from 4 to 10 mm. These are placed on pieces of filter-paper and then in 3 to 7.5% nitric acid, in which they remain twenty-four hours. From the hardening fluid the pieces of tissue are transferred into 96% alcohol, where they remain for from twelve to twenty-four hours. They are then placed in a solution of ammonium-alcohol,—ammonium (sp. gr. 0.95 to 0.96), 1 part; distilled water, 3 parts; 96% alcohol, 8 parts,—in which they remain for from twelve to twenty-four hours. The temperature of this solution should not exceed 20° C. The tissues are then placed for from six to twelve hours in 96% alcohol, and next in a hydrochloric acid-alcohol solution,—concentrated hydrochloric acid (sp. gr. 1.18—37%), 1 part; distilled water, 3 parts; and 96% alcohol, 8 to 12 parts,—in which they remain for several hours. The temperature of this solution should not exceed 20° C. The tissues are then again placed in 96% alcohol for from ten to twenty-four hours, and next in distilled water for from two to six hours. The tissues are now placed for twenty-four hours in a 4% aqueous solution of ammonium molybdate. (This solution should be kept at a temperature varying from 10° to 15° C., if it is desired to stain the neurofibrils; or at a temperature varying from 10° to 30° C., if it is desired to bring out the Golgi-nets.) After the ammonium molybdate treatment, the tissues are rinsed in distilled water, placed in 96% alcohol for from ten to twenty-four hours, then in absolute alcohol for a like period, cleared in xylol or toluol, and imbedded in paraffin. Sections having a thickness of 10  $\mu$  are now cut and fixed to slides with Mayer's albumin-glycerin. Since the various solutions used in the fixation and further treatment of the tissues do not act with the same intensity on all parts of the piece of tissue to be studied, and since the differentiation and staining depend on a relative proportion (not yet fully determined) of the mordant (ammonium molybdate) and the stain in a given section, it is advised by Bethe to cut large numbers of sections and fix to each slide about three sections from different parts of the series. After fixation of the sections to the slide the paraffin is removed with xylol; and they are then carried through absolute alcohol into distilled water, in which, however, the sections remain only long enough to re-

move the alcohol. The slides (with the sections fixed to them) are then taken from the water and rinsed with distilled water from a water-bottle. The slide is then wiped dry on its under surface and edges with a clean cloth, and about 1 c.c. to 1.5 c.c. of distilled water placed on the slide over the sections. The slides are now placed in a warm oven with a temperature of 55° C. to 60° C. for a period of time varying from two to ten minutes. No definite time can here be given; sections from each block of tissue need to be tested until the right stay in the warm oven is ascertained. The slides are then taken from the warm oven and rinsed two or three times in distilled water and again dried as previously directed. They are then covered with the following staining solution and again placed in the warm oven for about ten minutes: toluidin-blue, 1 part; distilled water, 3000 parts. The stain is washed off with distilled water and the sections are placed in 96% alcohol until no more stain is given off—usually for from three-fourths to two minutes. They are then dehydrated in absolute alcohol, passed through xylol twice, and mounted in xylol balsam. For a fuller discussion of this method the reader is referred to Bethe's account in "Zeitsch. f. Wissensch. Mikrosk.," vol. xvii, 1900.

315. For staining **neuroglia** Weigert (95) has recommended a method, from which we give the following: A solution is made consisting of 5% neutral acetate of copper, 5% ordinary acetic acid, and 2.5% chrome-alum in water. The chrome-alum and water are first boiled together, the acetic acid then added, and finally the finely pulverized neutral copper acetate, after which the mixture is thoroughly stirred and allowed to cool. To this solution 10% formalin may be added. Objects not over 0.5 cm. in diameter are placed in this fluid for eight days, the mixture being changed at the end of a few days. By this means the pieces of tissue are at the same time fixed and prepared for subsequent staining by the action of the mordant. If separation of the two processes be desired, the specimens are fixed for about four days in a 10% formalin solution (which is changed in a few days), and then placed in the chrome-alum mixture without the addition of formalin. Specimens thus fixed may be preserved for years without disadvantage, and may then be subjected to further treatment by other methods, Golgi's for instance. Washing with water, dehydration in alcohol, and imbedding in celloidin are the next steps. The sections are then placed for about ten minutes in a 0.33% solution of potassium permanganate, washed by pouring water over them, and placed in the reducing fluid (5% chromogen and 5% formic acid of a specific gravity of 1.20; then filter carefully, and add 10 c.c. of a 10% solution of sodium sulphite to 90 c.c. of the fluid). The sections, rendered brown by the potassium permanganate, readily decolorize in a few minutes, but it is better to leave them for from two to four hours in the solution. If it be desirable to decolorize entirely the connective tissue, no further steps need be taken preliminary to staining; if not, the reducing fluid is poured off and the sections are rinsed twice in water and then placed in an ordinary saturated solution of chromogen (5% chromogen in distilled water, carefully filtered). The sections are left in this solution overnight, and the longer they remain in it, the more marked will be the contrast, as far as stain is concerned, between the connective and nervous tissues; then water is again twice poured upon the sections and they are ready for staining. This process consists in a

modified fibrin stain (*vid.* Technic). The iodo-iodid of potassium solution is the same (saturated solution of iodine in a 5% iodid of potassium solution). Instead of the customary gentian-violet solution, a hot saturated alcoholic (70% to 80% alcohol) solution of methyl-violet is made, and, after cooling, the clear portion decanted off; to every 100 c.c. of this fluid 5 c.c. of a 5% aqueous solution of oxalic acid is added. The staining takes place in a very short time. The sections are then rinsed and normal salt solution and the iodo-iodid of potassium solution poured over them (5% iodid of potassium solution saturated with iodine), and washed off with water and dried with filter-paper and decolorized in the anilin oil-xylol solution in the proportion of 1:1. The reactions are rapid, and the thickness of the section should not exceed 20  $\mu$ . This method is best adapted to the central nervous system of the human adult; it has as yet not been sufficiently tested for other vertebrates.

## VIII. THE EYE.

### A. GENERAL STRUCTURE.

THE organ of vision consists of the eyeball, or **bulbus oculi**, and the entering **optic nerve**.

In the eyeball we distinguish three tunics: (1) a dense external coat, the **tunica fibrosa** or **externa**, which may be regarded as a continuation of the dura mater, consisting of an anterior transparent structure, called the *cornea*, and the remaining portion, known as the *tunica sclerotica*, or, briefly, the *sclera*; (2) within the tunica fibrosa a vascular tunic, the **tunica vasculosa** or **media**, subdivided into the *choroid*, *ciliary body*, and *iris*; (3) an inner coat, the **tunica interna**, which consists of two layers, the inner being the *retina*; the outer, the *pigment membrane*. The latter lines the internal surface of the tunica vasculosa throughout. Within the eyeball are the *aqueous humor*, the *lens*, and the *vitreous body*. The lens is attached to the ciliary body by a special accessory apparatus—the *zonula ciliaris*. These two structures—the lens and its fixation apparatus—divide the cavity of the eyeball into two principal chambers, the one containing the aqueous humor and the other the vitreous. The former is further subdivided by the iris into an anterior and a posterior chamber. During life the latter is only a narrow capillary cleft.

### B. DEVELOPMENT OF THE EYE.

In man the eyes begin to develop during the fourth week of embryonic life, and at first consist of a pair of ventrolateral diverticula, projecting from the anterior brain vesicle. These evaginations gradually push outward toward the ectoderm, and are then known as the *primary optic vesicles*. The slender commissural segments

connecting the vesicles with the developing brain are termed the *optic stalks*.

Very soon a process of invagination takes place; that portion of the vesicular wall nearest the ectoderm is pushed inward, thus forming a double-walled cup—the *secondary optic vesicle*, or *optic cup*. An internal and an external wall may now be differentiated, continuous at the margin of the cup. At the same time a disc-like thickening of the adjacent ectoderm sinks inward toward the mouth of the cup-shaped optic vesicle, forming the first trace of the lens.

During the development of the secondary optic vesicle a groove

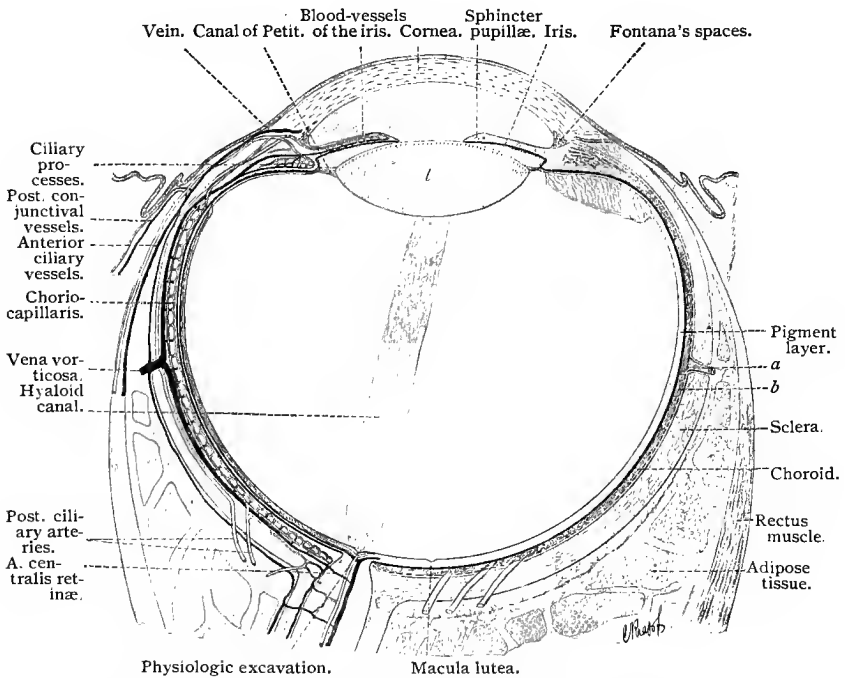


Fig. 329.—Schematic diagram of the eye (after Leber and Flemming): *a*, Vena vorticiosa; *b*, choroid; *l*, lens.

is formed on its ventral side, extending from the marginal ring into the optic stalk. This is the embryonic optic fissure, or the *choroidal fissure*. At the edges of the groove the two layers of the optic cup are continuous. This groove serves for the penetration of mesoblastic tissue and blood-vessels into the interior of the optic cup, and in its wall the fibers of the optic nerve develop.

The outer layer of the secondary optic vesicle becomes the *pigment membrane*; the inner, the *retina*. The optic nerve-fibers consist not only of the centripetal neuraxes of certain ganglion cells in

the retina, but also of centrifugal neuraxes, which pass out from the brain (Froriep).

The invaginating ectoderm which later constitutes the lens is constricted off from the remaining ectoderm in the shape of a vesicle, the mesial half of which forms the lens fibers by a longitudinal growth of its cells, while the lateral portion forms the thin anterior epithelial capsule of the lens. The epithelium of the ectoderm external to the lens differentiates later into the external epithelium of the cornea and conjunctiva, neither of which structures is at this stage sharply defined from the remaining ectoderm. It is only during the development of the eyelids that a distinct demarcation is established. All the remaining portions of the eye, as the vitreous body, the vascular tunic with the iris, the sclera with the substantia propria of the cornea and the cells of Descemet's layer, are products of the mesoderm.

## C. TUNICA FIBROSA OCULI.

### 1. THE SCLERA.

The **sclera** is the dense fibrous tissue covering of the eyeball, and is directly continuous with the transparent cornea. At the posterior mesial portion of the eyeball, the sclera is perforated for the entrance of the optic nerve, this region being known as the **lamina cribrosa**. The sclera consists of bundles of connective-tissue fibers arranged in equatorial and meridional layers. At the external scleral sulcus, in the vicinity of the cornea, the arrangement of the fibers is principally equatorial. The tendons of the ocular muscles are continuous with the scleral fibers in such a manner that those of the straight muscles fuse with the meridional fibers, while those of the oblique muscles are continuous with the equatorial fibers. In the sclera are many lymph-channels communicating with those of the cornea. They are much coarser and more irregularly arranged than those of the cornea, and in this respect simulate the lymph-channels found in aponeuroses. Pigmentation is constantly present at the corneal margin, in the vicinity of the optic nerve entrance, and also on the surface next the choroid. The innermost pigment layer of the sclera is lined by a layer of flattened endothelial cells, and is regarded by some as a separate membrane, known as the **lamina fusca**. The external surface of the sclera also presents a layer of flattened endothelial cells, belonging to the **capsule of Tenon**. Anteriorly, the mobile **scleral conjunctiva** is attached to the sclera by a loose connective tissue containing elastic fibers.

The cornea is inserted into the sclera very much as a watch-crystal is fitted into its frame. At the sclerocorneal junction is found an annular venous sinus, the **canal of Schlemm**, which may appear as a single canal or as several canals separated by incomplete fibrous septa. Anteriorly and externally this canal is bounded

by the cornea and sclera; internally, it is partly bounded by the origin of the ciliary muscle. The sclera comprises, therefore, one-half of the canal-wall, and presents a corresponding circular sulcus, the so-called **inner scleral sulcus**.

The blood-vessels of the sclera are derived from the anterior ciliary vessels. The capillaries enter either into the ciliary veins or into the venæ vorticosæ. The numerous remaining vessels traverse the sclera, extending to the choroid, iris, or scleral margin. At the corneal margin the capillaries form loops.

## 2. THE CORNEA.

The **cornea** is made up of the following layers: (1) the anterior or corneal epithelium; (2) the anterior elastic membrane, or Bowman's membrane; (3) the ground-substance of the cornea, or substantia propria; (4) Descemet's membrane; (5) the endothelium of Descemet's membrane.

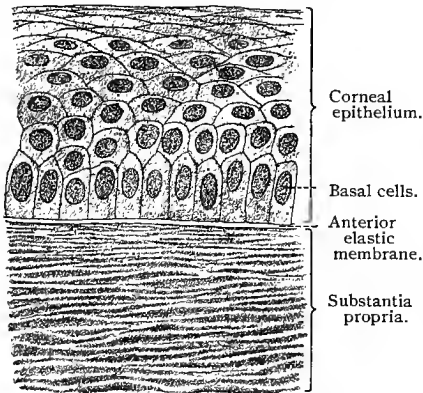


Fig. 330.—Section through the anterior portion of human cornea;  $\times 500$ .

At the center of the human cornea the epithelium consists of from six to eight layers of cells, being somewhat thicker near the corneal margin. Its basilar surface is smooth and there are no connective-tissue papillæ. The basal epithelial layer is composed of cylindrical cells of irregular height; the following layers contain irregular polygonal cells, while the two or three most superficial layers consist of

flattened cells. The cells of the corneal epithelium are all provided with short prickles, which are, however, very difficult to demonstrate, and between are found lymph-canaliculi. The lower surfaces of the basal cells also possess short processes which penetrate into the anterior basement membrane.

In man the **anterior elastic** or **Bowman's membrane** is quite thick and apparently homogeneous, but may be separated into fibrils by means of certain reagents. In structure it belongs neither to the elastic nor to the white fibrous type of connective tissue, and must be regarded as forming a class by itself. Numerous nerve-fibers penetrate its pores to enter the epithelium. The thickness of this membrane decreases toward the sclera, and it finally disappears about 1 mm. from the latter.

The **substantia propria** consists of connective-tissue fibrils

grouped into bundles and lamellæ. Chemically they do not differ from true connective-tissue fibers (Morochowetz), but are doubly refracting. There are about sixty lamellæ in the human cornea. The fibrils composing each lamella are cemented together and run parallel to one another as well as to the surface of the cornea, but they are so arranged that the fibrils of each lamella cross those of the immediately preceding one at an angle of about twelve degrees. The lamellæ themselves are likewise closely cemented to one another. The most superficial lamella, lying immediately beneath the anterior elastic membrane, is composed of finer fibers, the course of which is oblique to the surface of the cornea. Between the anterior and posterior elastic membranes are bundles of fibers, which perforate the various lamellæ of the cornea and are consequently known as the **perforating** or **arcuate fibers**.

Between the lamellæ are peculiar, flattened cells, possessing irregular or lamella-like processes, the **corneal corpuscles**; these lie in special cavities in the ground substance of the substantia propria, which are known as **corneal spaces**. By means of various methods (*vid.* T. 319 and 320), these corneal spaces may be shown to be part of a complicated lymphatic system, comparable to the lymph-canalicular system of fibrous connective tissue. This system of canals is also in communication with the lymph-channels at the corneal margin.

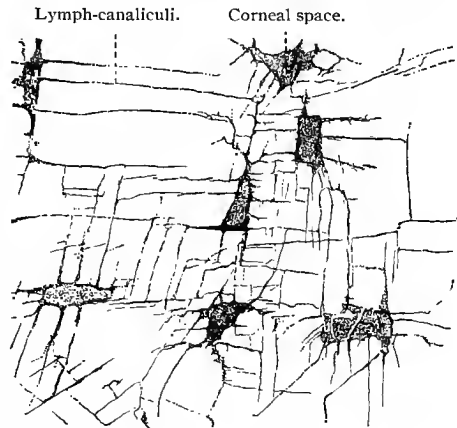


Fig. 331.—Corneal spaces of a dog;  $\times 640$   
(Technic No. 320).

The **posterior elastic** or **Descemet's membrane** is not so intimately connected with the substantia propria as Bowman's membrane. It is thinnest at the center of the cornea, and becomes thicker toward the margin. It may be separated into finer lamellæ, is very elastic, resists acids and alkalies, but is digested by trypsin.

The endothelium of Descemet's membrane consists of low, quite regular, hexagonal cells, which in certain vertebrates (dove, duck, rabbit) are peculiar in that a fibrillar structure may be seen in that portion of each cell nearest the posterior elastic membrane. By means of these fibers, not only adjacent cells, but also those further apart, are joined together. Thus we have here to a marked degree the formation of fibers which penetrate the cells and connect them with one another, conditions already met with in the prickle-cells of the epidermis. (Fig. 288.)

The cornea is nonvascular. In fetal life, however, the capillaries from the anterior ciliary arteries form a precorneal vascular network immediately beneath the epithelium, a structure which is obliterated shortly before birth and only rarely seen in the newborn. Its remains are found at the corneal limbus either as an episcleral or conjunctival network of marginal capillary loops. Fine branches of the anterior ciliary arteries extend superficially along the sclera to the corneal margin, and form here a network of capillaries also ending in loops, from which numerous veins arise, constituting a corresponding network emptying into the anterior ciliary veins. The conjunctival vessels likewise form a network of marginal loops at the corneal limbus, and are connected with the episcleral vessels (Leber). Under pathologic conditions the cornea may become vascularized from the marginal episcleral network.

The **nerves** of the cornea are derived from the sensory fibers of the ciliary nerves, which form a plexus at the corneal margin; from this, nonmedullated fibers penetrate the cornea itself and form two plexuses, a *superficial* and a *ground plexus*; the latter is distributed throughout the whole substantia propria with the exception of its inner third (Ranvier, 81). The two plexuses are connected by numerous anastomoses. At one time it was supposed that direct communication existed between the corneal corpuscles and the nerve-fibers of both plexuses. This view, however, contradicts the generally accepted neurone theory.

Nerve-fibers from the superficial plexus pass through the anterior elastic membrane and form a plexus over the posterior surface of the epithelium, known as the *subepithelial plexus*. From the latter nerve-fibers extend between the epithelial cells, terminating in telodendria with long slender nerve-fibrils, which end in small nodules. Many of the fibrils reach almost to the surface of the epithelium (Rollett, 71; Ranvier, 81).

## D. THE VASCULAR TUNIC OF THE EYE.

### THE CHOROID, THE CILIARY BODY, AND THE IRIS.

From without inward the following layers may be differentiated in the **choroid**: (1) the *lamina suprachoroidea*; (2) the *lamina vasculosa Halleri*; (3) the *lamina choriocapillaris*; and (3) the *glassy layer*, or *vitreous membrane*.

The **lamina suprachoroidea** consists of a number of loosely arranged, branching and anastomosing bundles and lamellæ of fibrous tissue, joined directly to the lamina fusca of the sclera. These bundles and lamellæ consist of white fibrous connective tissue containing numerous elastic fibers, among which a few connective-tissue cells are distributed. Pigment cells are also present in varying numbers. The bundles and lamellæ are covered by endothelial

cells, and the spaces and clefts between them, and between the lamina suprachoroidea and the lamina fusca, constitute a system of lymph-channels—the *perichoroidal lymph-spaces*.

The **lamina vasculosa** of the choroid is also composed of similar lamellæ, which, however, are more closely arranged. The blood-vessels constitute the principal portion of this layer, the vessels being of considerable caliber, not capillaries. They are so distributed that the larger vessels, the veins, occupy the outer layer of the lamina vasculosa. The venous vessels converge toward four points of the eyeball, forming at the center of each quadrant one of the four *venæ vorticosæ*. The arteries, on the other hand, describe a more meridional course.

In the inner portion of this layer is found a narrow zone,—in the human eye only about 10  $\mu$  in thickness,—consisting largely

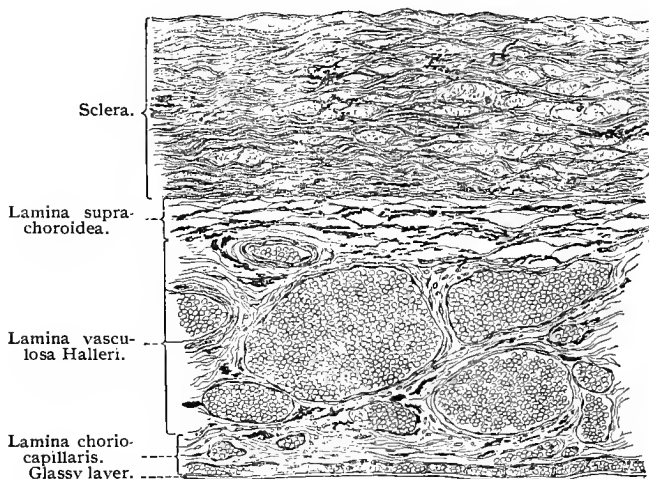


Fig. 332.—Section through the human choroid;  $\times 130$ .

of elastic fibers and free from pigment cells, known as the *boundary zone*. This zone is somewhat thicker in many mammals, and in some of these presents a characteristic structure. In the eyes of ruminants and horses this zone consists of several layers of connective-tissue bundles, and is known as the *tapetum fibrosum*. It gives the peculiar luster often seen in the eyes of these animals. In the eyes of carnivora this zone consists of several layers of endothelioid cells, containing in their protoplasm numerous small crystals and forming the iridescent layer known as the *tapetum cellulosum*.

The **lamina choriocapillaris** contains no pigment and consists principally of capillary vessels, which form an especially dense network in the neighborhood of the macula lutea. As the venous capillaries become confluent and form smaller veins, the latter arrange

themselves in long, radially directed networks, and form in this way the more or less pronounced *stellula vasculosa* (Winslowii).

The **vitreous** or **glassy membrane** is a very thin ( $2 \mu$ ) homogeneous membrane which shows on its outer surface the impressions of the vessels composing the lamina choriocapillaris, and on its inner surface those of the pigment epithelium of the retina.

At the ora serrata the choroid changes in character; from this region forward, the choroidal tissue assumes more the appearance of ordinary connective tissue, and the choriocapillary layer is wanting.

The region of the vascular coat extending from the ora serrata to the base of the iris is known as the **ciliary body**. Its posterior portion, about 4 mm. broad, the *orbiculus ciliaris*, is slightly thicker than the choroid, and presents on its inner surface numerous small folds, meridionally placed, consisting of connective tissue and blood-vessels. Anterior to the orbiculus ciliaris the ciliary body is thickened by a development of nonstriated muscle—the ciliary muscle (see below); and on the inner surface of this annular thickening are placed about seventy triangular folds, meridionally arranged—the **ciliary processes**. The attached border of these processes measures from 2 to 3 mm. The anterior border attains a height of about 1 mm. On and between these folds are found numerous small secondary folds or processes of irregular shape. The ciliary processes consist of fibrous connective tissue and numerous smaller and larger vessels, which have in the main a meridional arrangement. The vitreous membrane extends over the ciliary body, attaining in the region of the ciliary processes a thickness of  $3 \mu$  or  $4 \mu$ . Internal to the vitreous membrane, the ciliary body is covered by a double layer of epithelial cells, the continuation forward of the retina (*pars ciliaris retinae*). Of these, the outer layer is composed of cells, which are deeply pigmented, and are of cubic or short columnar shape, and derived from the outer layer of the secondary optic vesicle, while the cells of the inner layer are nonpigmented and of columnar shape, and are developed from the inner layer of the secondary optic vesicle. In the region of the ciliary processes their epithelial lining presents here and there evaginations of glandular appearance, lined by the unpigmented cells. These evaginations are known as **ciliary glands**, and to them is attributed—in part, at least—the secretion of the fluid found in the anterior chamber of the eye.

The **ciliary muscle** is bounded anteriorly (toward the anterior chamber) by the ligamentum pectinatum iridis, externally by the cornea and sclera, posteriorly by the orbiculus ciliaris, and internally by the ciliary processes. It consists of nonstriated muscle-fibers in the majority of vertebrates. This muscle is divided into three portions. The outer or *meridional division* extends from the posterior elastic lamina of the cornea and its continuation, forming the inner wall of the sinus venosus sclerae, to the posterior portion of the ciliary ring. The origin of the *middle division* is identical with

that of the outer, but its fibers (assuming that we have before us a meridional section) spread out like a fan, and occupy a large area at their insertion into the ciliary ring and ciliary processes. The radial course of these fibers is interrupted by circular bundles. The *third* or *inner division* (*fibræ circulares, fibers of Müller*) is situated between the ligamentum pectinatum, the ciliary processes, and the middle portion of the muscle just mentioned, and is thus near the base of the iris.

Between the ciliary muscle and the posterior elastic membrane of the cornea is an intermediate, richly cellular tissue, which may be regarded as a continuation of this elastic membrane, and which forms a part of the wall of the sinus venosus. Another structure internal to the foregoing and directed posteriorly is the *ligamentum pectinatum iridis*, which encircles the anterior chamber and is a continuation of Descemet's membrane to the base of the iris. It con-

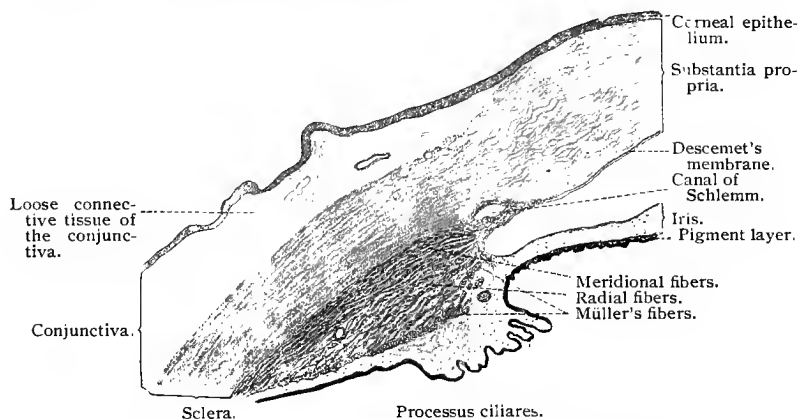


Fig. 333.—Meridional section of the human ciliary body;  $\times 20$ .

sists of fibers and lamellæ lined by endothelial cells, and bounds certain intercommunicating spaces lying in the ligament, known as the **spaces of Fontana**. The latter communicate on the one side with the perivascular spaces of the sinus venosus scleræ (canal of Schlemm), and on the other with the anterior chamber.

The **iris** must be looked upon as a continuation of the choroid, the vitreous layer of which is directly continuous with the posterior vitreous lamella of the iris, or Bruch's membrane. The iris is also connected at its anterior peripheral portion with the ligamentum pectinatum.

The iris possesses the following layers, beginning anteriorly: (1) the anterior endothelium; (2) the ground-layer, or stroma of iris, together with the sphincter muscle of the pupil; (3) the posterior vitreous layer, or the membrane of Bruch; and (4) the two-layered, pigmented epithelium—the *pars iridica retinae*.

The **anterior endothelium** is a single layer of irregularly polygonal, nonpigmented cells, and is directly continuous with the endothelium of the pectinate ligament.

The ground-layer or **stroma of iris** consists anteriorly of a fine reticulate tissue rich in cellular elements (reticulate layer). The remaining strata which form the bulk of the ground-layer constitute its vascular layer. The vessels are here peculiar in that they are covered by coarse, circular, connective-tissue fibers forming vascular sheaths. There is also an entire absence of muscular tissue in the vessel walls. The nerves, too, are enveloped by a dense connective tissue. In all eyes (except the albinotic) pigment is found in the connective tissue.

On the posterior inner surface of the ground-layer is a band of smooth muscle-fibers encircling the pupil—the *sphincter muscle of the pupil*.

The **membrane of Bruch** is a structureless hyaline sheath. At its anterior surface and closely connected with it is a layer of spindle-shaped cells having a radial arrangement and containing pigment. Closer microscopic inspection reveals the fact that in all probability these elements represent muscular tissue. Here, therefore, we have to deal with a *dilator muscle* of the pupil.

The **posterior epithelium** is the direct continuation of the two epithelial layers of the ciliary body, and represents the anterior portion of the secondary optic vesicle, the two layers being continuous at the margin of the pupil. In the iris both layers of cells are pigmented. (Compare Retzius, 93.)

The **arteries of the choroid** are derived from the short posterior ciliary, the long ciliary, and the anterior ciliary arteries. The short posterior ciliary arteries penetrate the sclera in the vicinity of the optic nerve, mingle with the retinal vessels, and spread through the choroid, where they form the choriocapillary layer. The long posterior ciliary arteries (a mesial and a lateral) penetrate the sclera and course forward between choroid and sclera to the ciliary body, forming there the *circulus arteriosus iridis major*; they also supply the ciliary muscle, the ciliary processes, and the iris, and anastomose in the ciliary ring with the branches of the short posterior and anterior ciliary arteries. The latter lie beside and partly within the straight ocular muscles, penetrating the latter at the anterior margin of the sclera; they give off branches to the *circulus arteriosus iridis major* and to the ciliary muscles, anastomosing at the same time with the posterior ciliary arteries. (Compare Figs. 329 and 334.) Within the iris the blood-vessels generally take a radial direction, but also anastomose with one another, forming capillaries, and subsequently the *circulus arteriosus iridis minor* at the inner pupillary margin. From the region supplied by the posterior ciliary arteries most of the blood is carried toward the vorticosse veins. The anterior ciliary veins convey the blood coming from the arteries of the same name. Into these veins is also

poured the blood from the veins lying in the canal of Schlemm, the canal itself being in reality an open venous sinus. Besides this, these veins convey also venous blood from the conjunctiva (Leber).

The nonstriated muscle of the ciliary body and iris receives its innervation through sympathetic nerve-fibers, neuraxes of sympathetic neurones, the cell-bodies of which are situated either in the ciliary ganglia or in the superior cervical ganglia. The neuraxes of the sympathetic cells forming the ciliary ganglia form the short ciliary nerves, which pierce the sclera in the neighborhood of the optic nerve and pass forward, to terminate in the muscle of the ciliary body and the sphincter muscle of the pupil. Stimulation of these nerves causes a contraction of the ciliary muscle and a closure of the pupil. The cell-bodies of the sympathetic neurones forming the ciliary ganglia are surrounded by pericellular plexuses, the terminations of small medullated nerve-fibers (white rami fibers) which reach the ciliary ganglia through the oculomotor nerves. Neuraxes of sympathetic neurones, the cell-bodies of which are situated in the superior cervical ganglia, reach the eye through the cavernous plexuses, to terminate, it is thought,—in part, at least,—in the dilator of the iris, since stimulation of these nerves causes a dilatation of the pupils. The cell-bodies of these sympathetic neurones are surrounded by pericellular plexuses, the terminations of white rami fibers which leave the spinal cord through the first, second, and third thoracic nerves (Langley), and which reach the superior cervical ganglia through the cervical sympathetic.

Melkirch and Agababow have shown that numerous sensory nerves terminate in free sensory endings in the connective tissue of the ciliary body and iris. The sensory nerve-supply of the iris is especially rich.

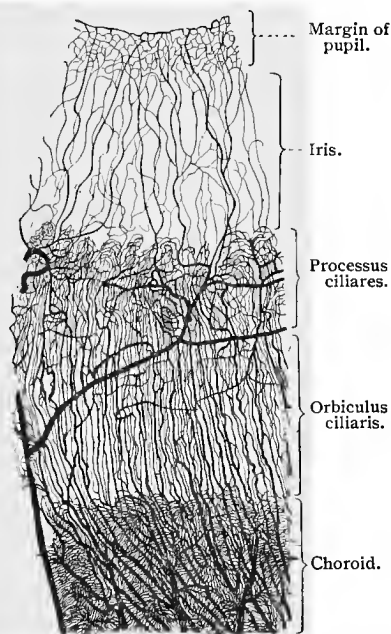


Fig. 334.—Injected blood-vessels of the human choroid and iris;  $\times 7$ .

## E. THE INTERNAL OR NERVOUS TUNIC OF THE EYE.

This tunic is composed of two layers : the outer, or *stratum pigmenti* ; and the inner, or *retina*.

### 1. THE PIGMENT LAYER.

The pigment layer develops, as we have seen, from the outer layer of the secondary optic vesicle. It consists of regular hexagonal cells,  $12\ \mu$  to  $18\ \mu$  in length and  $9\ \mu$  in breadth, which contain black pigment in the form of granules. The inner surfaces of these cells possess long, thread-like and fringe-like processes, between which project the external segments of the rods and cones of the retina, yet to be described. The nuclei of the pigment cells lie in the outer ends of the cells, the so-called basal plates, and are not pigmented. The distribution of the pigment varies according to the illumination of the retina. If the latter be darkened, the pigment collects at the outer portion of each cell ; if illuminated, the pigment is evenly distributed throughout the whole cell. The pigment granules are therefore mobile (Kühne, 79).

### 2. THE RETINA.

The retina has not the same structure throughout. In certain areas peculiarities are noticeable which must be described in detail ; such areas are : (1) the macula lutea ; (2) the region of the papilla (papilla nervi optici) ; (3) the ora serrata ; (4) the pars ciliaris retinæ ; and (5) the pars iridica retinæ.

We shall begin with the consideration of that portion of the retina lying between the ora serrata and the optic papilla (exclusive of the macula lutea).

From without inward, we differentiate : (1) the layer of visual cells, including the outer nuclear layer ; (2) the outer molecular (plexiform) layer ; (3) the inner nuclear or granular layer ; (4) the inner molecular (plexiform) layer ; (5) the ganglion-cell layer ; (6) the nerve-fiber layer. Besides these, we must also consider the supporting tissue of the retina and Müller's fibers, together with the internal and external limiting membranes.

The **visual cells** are either *rod-visual cells* or *cone-visual cells*. The **rod-visual cells** consist of a rod and a rod-fiber with its nucleus. The *rod* ( $40\ \mu$  to  $50\ \mu$  in length) consists of two segments, an outer and an inner, the former of which is doubly refractive and may be separated into numerous transverse discs by the action of certain reagents. The inner is less transparent than the outer segment, and its inner end shows a fine superficial longitudinal striation due to impressions from the fiber-baskets formed by Müller's fibers. In the lower classes of vertebrates a rod-ellipsoid

(a fibrillar structure) may easily be demonstrated in the outer region of each inner portion; in many mammalia and in man the demonstration of this is more difficult. This structure is a planoconvex, longitudinally striated body, the plane surface of which is coincident with the external surface of the inner segment, its inner convex surface lying at the junction of the outer and middle thirds of the inner segment. The *rod-fibers* extend as far as the outer molecular layer of the retina, where they end in small spheric swellings. The nuclei of the rod-visual cells are found at varying points within the rod-fibers, but rarely close to the inner segment. When treated with certain fixing agents and stains, the rod-nuclei are seen to show several zones, which stain alternately light and dark (striation of the rod-nuclei).

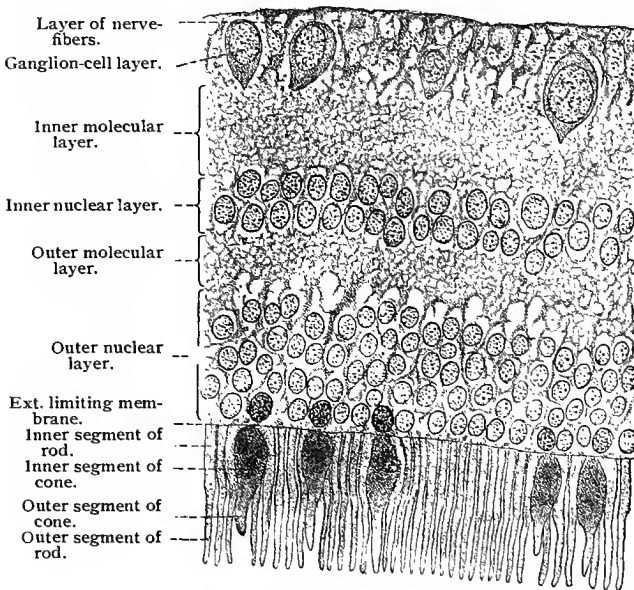


Fig. 335.—Section of the human retina;  $\times 700$ .

The **cone-visual cells** consist, similarly to the rod-visual cells, of a cone and a cone-fiber with its nucleus. The *conc* ( $15\ \mu$  to  $25\ \mu$  in length) is, as a whole, shorter than the rod, and its inner segment is considerably broader than that of the rod. The cone ellipsoid comprises the outer two-thirds of the inner segment, and the outer segment has a more conical shape. The *conc-fiber* likewise extends as far as the outer molecular layer, where it ends in a branched basal plate. Its somewhat larger nucleus is always found in the vicinity of the inner segment of the cone. The inner surfaces of the inner segments, not only of the cone-cells, but also of the rod-visual cells, lie in one plane, corresponding to the

*external limiting membrane*, a structure composed of the sustentacular fibers of Müller. The rod-fibers and cone-fibers, with the nuclei of the rod- and cone-visual cells, lie between the external limiting membrane and the outer molecular layer. It will be observed, therefore, that the visual cells include the layer of rods and cones and the outer nuclear layer.

The **outer molecular layer** consists: (1) of the ramifications of Müller's fibers; (2) of the knob and tuft-like endings of the visual cells; and (3) of the dendritic processes of the bipolar cells of the inner nuclear layer. These structures will be considered more in detail in discussing the relations of the elements comprising the retina.

The **inner nuclear layer** contains: (1) the nucleated stratum of Müller's sustentacular fibers; (2) ganglion cells situated in the outer region of the layer and extending in a horizontal direction; (3) bipolar ganglion cells with oval nuclei, densely placed at various depths of the layer and vertical to it; (4) amacrine cells (neurones, apparently without neuraxes) lying close to the inner margin of the layer and forming with their larger nuclei a nearly continuous layer of so-called spongioblasts. The numerous processes of these spongioblasts lie in the *inner molecular layer*, the composition of which will be further discussed later.

The **ganglion-cell layer** of the optic nerve consists, aside from centrifugal neuraxes and the fibers of Müller, which are here present, of multipolar ganglion cells, the dendrites of which extend outward and the neuraxes of which are directed toward the optic nerve-fiber layer. These cells vary in size, and their nuclei are typical, being relatively large, deficient in chromatin, and always provided with large, distinct nucleoli. In man the optic nerve-fibers of the retina are nonmedullated.

All these structures are typical of that portion of the retina lying behind the ora serrata. The retina in the vicinity of the optic papilla and macula lutea must be taken up separately.

### 3. REGION OF THE OPTIC PAPILLA.

The **optic papilla** is the point of entrance of the optic nerve into the retina. At the center of the papilla, in the region where the nerve-fibers spread out radially in order to supply the various areas of the retina, is a small, funnel-shaped depression, the *physiologic excavation*. The fibers of the optic nerve lose their medullary sheaths during their passage through the sclera and choroid, and then continue, penetrating the various layers of the retina, to the inner surface of the latter, over which they spread in a layer which gradually becomes thinner toward the ora serrata. On account of the deflection of the nerve-fibers, and because, during their passage through the sclera, they lose their medullary sheaths at one and the same point, the optic nerve becomes suddenly thinner. The result is a

deeply indented circular depression in this region. On this depression border the three ocular tunics. At this point the retina is interrupted, the outer layers extending to the bottom of the depression, while the inner cease at its margin. In many cases the outer layers of the retina are separated from the optic nerve by a thin lamina of supporting tissue (intermediate tissue).

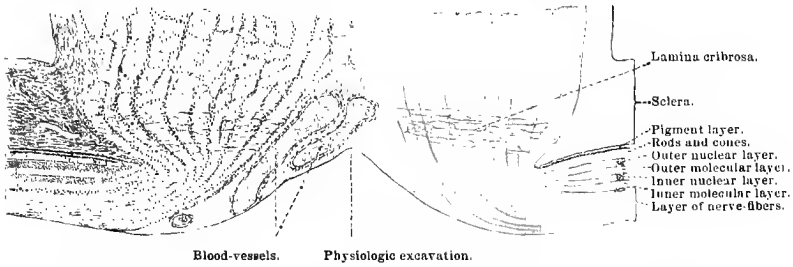


Fig. 336.—Section through point of entrance of human optic nerve;  $\times 40$ .

4. REGION OF THE MACULA LUTEA.

At the center of the **macula lutea** is a trough-like depression, the **fovea centralis**, the deepest part of which, the *fundus*, lies very close to the visual axis. Here the layers of the retina are practically reduced to the cone-visual cells. The margin of this depression is somewhat thickened, owing to an increase in the thickness of the nerve-fiber and ganglion-cell layers. Toward the fundus of the fovea

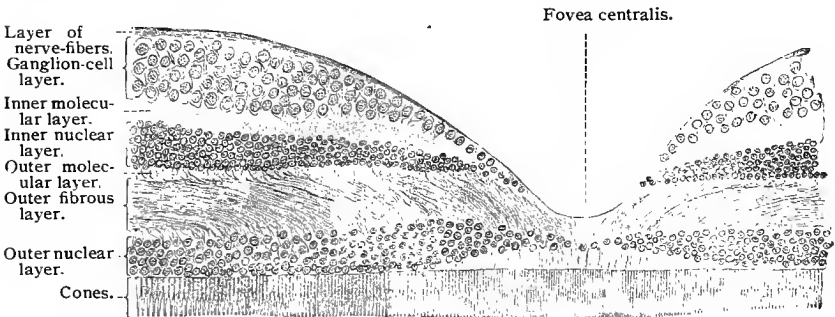


Fig. 337.—Section through human macula lutea and fovea centralis;  $\times 150$ . As a result of treatment with certain reagents, the fovea centralis is deeper and the margin more precipitous than during life.

each of the four inner retinal layers becomes reduced in thickness, the inner layer first and the three others in their order: the inner molecular layer, however, seems to extend as far as the fundus. As we have seen, only the cone-visual cells are found in the fovea centralis, there being an entire absence of the rod-visual cells. Since the nuclei of the cone-visual cells are in the immediate neighborhood

of the cones, and since the cone-fibers, in order to reach the outer molecular layer, must here describe a curve, there arises a peculiar layer, composed of obliquely directed fibers, known as the *outer fiber-layer*. In other words, the fibers of this region are more distinctly seen because they are not covered by the rod-nuclei and rod-fibers.

The yellowish color of the fovea centralis is due to pigment held in solution within the layers of the retina. The cone-visual cells themselves contain no pigment.

### 5. ORA SERRATA, PARS CILIARIS RETINAE, AND PARS IRIDICA RETINAE.

In the region of the *ora serrata* the retina suddenly becomes thinner. As seen from the inner surface of the retina, its decrease presents the appearance of an irregular curve rather than of the segment of a sphere. Shortly before the retina terminates, its layers become markedly reduced, certain ones disappearing entirely; first the nerve-fiber layer, then the ganglion-cell layer and cone- and rod-visual cells, their place being taken by an indifferent epithelium. The inner molecular layer of the retina gradually loses the processes which penetrate inward. In the region of the *ora serrata* the sustentacular fibers are markedly developed.

The *pars ciliaris retinæ* consists essentially of two simple layers of cells, of which the external represents the pigment layer and the internal the inner epithelium of the secondary optic vesicle. In the *pars iridica retinæ* the arrangement is similar; here both layers are pigmented.

### 6. MÜLLER'S FIBERS OF THE RETINA.

Genetically, the sustentacular fibers, or *fibers of Müller*, in the retina are, like the whole retina, of ectodermic origin, and represent a highly developed form of neuroglial tissue. They penetrate the retina from within and extend as far as the inner segments of the rods and cones. Each fiber represents a long, greatly modified epithelial cell, terminating in one or more broad basal plates, which come in contact with those of adjacent fibers, thus forming a sort of membrane—the *internal limiting membrane*. Owing to its marked plasticity, each fiber presents certain peculiarities within the various layers of the retina through which it penetrates. Thus, within the molecular layers the fiber is provided with transversely directed processes and platelets. Within the nuclear layers, on the other hand, are numerous lateral indentations, which correspond to the impressions produced by the cells of these layers. At the inner surface of the cones and rods the fibers terminate in end-plates, which represent cuticular formations, and, blending with one another, form a single membrane—the *external limiting membrane*.

This membrane is perforated by the rod-fibers and cone-fibers. The end-plates of the fibers give off externally short, inflexible fibrils, which form the *fiber-baskets* containing the basilar portions of the inner segments of the rods and cones. (*Vid.* Fig. 338.)

## 7. THE RELATIONS OF THE ELEMENTS OF THE RETINA TO ONE ANOTHER.

We shall now take up the relationships existing between the various elements of the retinal strata, giving the theories now generally accepted and based on observations made with the Golgi and methylene-blue methods, and more particularly on the investigations of Ramón y Cajal (see diagram, Fig. 338):

1. The inner processes of the rod-visual cells end, as a rule, in small expansions within the *outer molecular layer*, in which also the processes of the cone-visual cells terminate in broader branched pedicles. In this layer also are situated the terminal arborizations of the dendrites and neuraxes of certain cells belonging to the inner nuclear layer.

2. The *inner nuclear layer* consists, as we have seen, (*a*) of bipolar cells, which constitute the principal portion of this layer, (*b*) of horizontally placed cells lying immediately beneath the outer molecular layer, and (*c*) of the layer of spongioblasts situated at the junction of the inner nuclear with the inner molecular layer. The *bipolar cells* comprise the following: (*a*) *Bipolar cells of the rod-visual cells* the dendrites of which intertwine around the basilar portions of the rod-visual cells, and the neuraxes of which end in telodendria in the neighborhood of the cell-bodies of the nerve-cells of the ganglion-cell layer. (*β*) *Bipolar cells of the cone-visual cells*. The dendrites of these cells, which also end in the outer molecular layer, are there in relation to the basilar processes of the cone-fibers. Their neuraxes come in contact, by means of terminal arborizations, with the dendrites of the ganglion cells of the ganglion-cell layer at varying depths of the inner molecular layer. (*γ*) Besides these, there are also bipolar cells which, as in the case of *a* and *β*, form contact with the rod- and cone-visual cells, but end on the cell-bodies of the ganglion cells of the ganglion-cell layer. The *horizontal cells* send their dendrites into the outer molecular layer, while their neuraxes extend horizontally and give off numerous collaterals to the same layer, ending there in telodendria. These cells are of two varieties: the smaller, indirectly connecting the cone-visual cells with one another by means of their dendrites and neuraxes; and the larger, more deeply situated cells, connecting in a similar manner the basilar ends of the rod-visual cells. A few cells of the second variety give off one or two dendrites each, which penetrate through the inner nuclear layer into the inner molecular layer.

3. The *inner molecular layer*. This is composed of five strata. The majority of the spongioblasts in the inner nuclear layer send

their processes upward into the inner molecular layer, in which some end in fine arborizations in the first, others in the second, and still others in the third interstice, separating the strata of the inner molecular layer from one another. Besides these so-called *stratum spongioblasts*, there are also others in the inner nuclear layer, the *diffuse spongioblasts*, whose ramifications end simultaneously in sev-

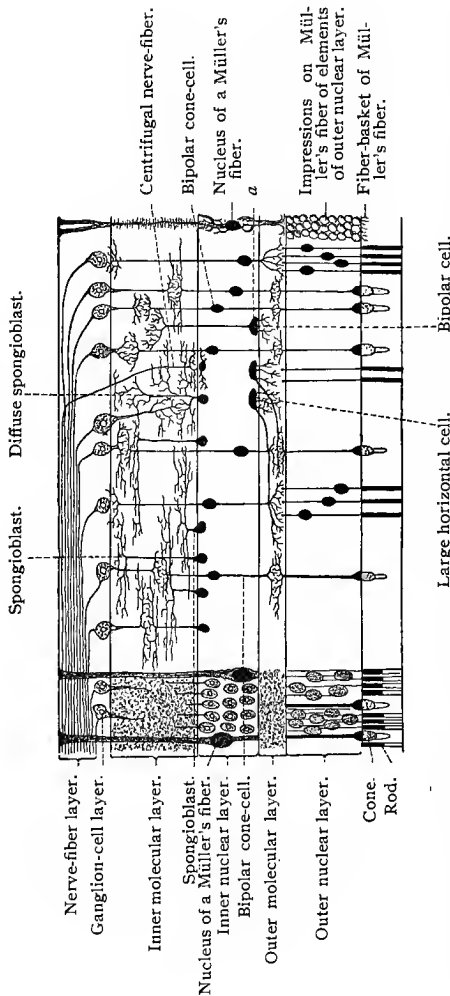


Fig. 338.—Schematic diagram of the retina according to Ramón y Cajal: The line *a*, after passing through a Müller's fiber, crosses a bipolar rod-cell, then two bipolar cone-cells, and finally ends in the body of a bipolar cone-cell.

eral or in all of the strata of the inner molecular layer. Besides the ramifications of the spongioblasts just mentioned, autochthonous cells are also present. These lie in one of the interstices of the molecular layer, their ramifications spreading out in a horizontal direction. Besides all these structures the dendrites of the cells

in the ganglion-cell layer also ramify throughout the inner molecular layer.

4. The *ganglion-cell layer*. The cell-bodies are irregularly oval; their dendrites extend into the inner molecular layer, and their neuraxes into the nerve-fiber layer. According to the manner of their dendritic termination, the ganglion cells may be divided into three groups: (1) those the dendrites of which extend into but one stratum of the molecular layer; (2) those the dendrites of which extend into several strata of the molecular layer; and (3) those the dendrites of which are distributed throughout the entire thickness of the molecular layer. Thus, these three groups are made up of the so-called *mono-stratified*, *poly-stratified*, and *diffuse* cells; by means of their dendrites they come in contact with one or several of the neuraxes of the bipolar cells of the inner nuclear layer.

5. The *nerve-fiber layer* of the retina. This layer consists of centripetal neuraxes from the ganglion cells of the ganglion-cell layer, and of centrifugal nerve-fibers ending in various layers of the retina, including the outer molecular layer.

### 8. THE OPTIC NERVE.

Within the orbit the optic nerve possesses an external sheath, which is an extension of the dura mater and is continuous with the scleral tissue, and an inner sheath, which is a prolongation of the pia mater. Between these two sheaths is a fissure, divided into two smaller clefts by a continuation of the arachnoid. Both these clefts are traversed by connective-tissue trabeculæ. The inner cleft communicates with the subarachnoid space; and the outer narrower cleft, with the subdural space.

The fibers of the optic nerve are medullated, but there is no neurilemma (sheath of Schwann), the latter being represented by the neuroglia. In the region of the sclera and choroid the optic nerve-fibers lose their myelin, and the septa of the inner or pial sheath become better developed and relatively more numerous. Connective-tissue fibers from the sclera and choroid also traverse this region of the optic nerve, giving rise to what is known as the *lamina cribrosa*. At from  $1\frac{1}{2}$  to 2 cm. from the eyeball there enter into the optic nerve laterally and ventrally (according to J. Deyl, mesially) the central artery and vein of the retina, which very soon come to lie within the axis of the nerve. Here they are surrounded by a common connective-tissue sheath which is in direct connection with the perineurium. The optic nerve-fibers extend through the lamina cribrosa into the retina, where they spread out as the nerve-fiber layer in the manner previously described.

### 9. BLOOD-VESSELS OF THE OPTIC NERVE AND RETINA.

The blood-vessels of the optic nerve are principally derived from the vessels of the pial sheath. In that portion of the nerve containing the central vessels of the retina the latter anastomose with the pial vessels, so that this portion of the optic nerve is also supplied by the central vessels. At their entrance through the sclera the short posterior ciliary arteries form a plexus around the optic nerve, the *arterial circle of Zinn*, which communicates, on the one hand, with the vessels of the pial sheath, and, on the other, with those of the optic nerve. At the level of the choroid the vessels of the latter communicate by means of capillaries with the central vessels of the optic nerve.

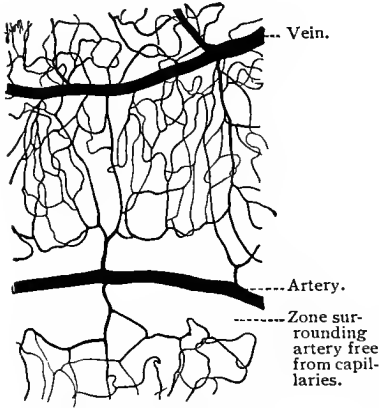


Fig. 339.—Injected blood-vessels of the human retina; surface preparation;  $\times 18$ .

the retina at the optic papilla, dividing here, or even within the nerve itself, into the *superior and inferior papillary artery and*

The *central artery and vein* of the retina enter and leave the retina at the optic papilla, dividing here, or even within the nerve itself, into the *superior and inferior papillary artery and*

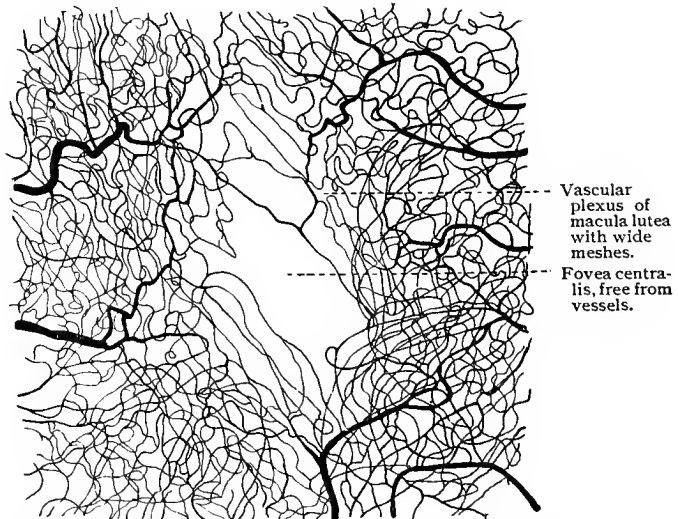


Fig. 340.—Injected blood-vessels of human macula lutea; surface preparation;  $\times 28$ .

*vein.* Both the latter again divide into two branches, the nasal and temporal arteriole and venule, known, according to their posi-

tions, as the *superior and inferior nasal and temporal artery and vein*.

Besides these vessels, two small arteries also arise from the trunk of the central artery itself, and extend to the macula. Two similar vessels extend toward the nasal side as the superior and inferior median branches. Within the retina itself the larger vessels spread out in the nerve-fiber layer, forming there a coarsely meshed capillary network connected by numerous branches with a finer and more closely meshed network lying within the inner nuclear layer. The venous capillaries of this network return as small venous branches to the nerve-fiber layer, in which they form a venous plexus, side by side with the arterial plexus.

The arteries of the retina are of smaller caliber than the veins. The larger arteries possess a muscular layer; the smaller, only an adventitia. All the vessels possess highly developed perivascular sheaths. The visual-cell layer is nonvascular, as are also the fovea centralis and the rudimentary retinal layers lying anterior to the ora serrata.

The arteries of the retina anastomose with one another solely by means of capillaries (end-arteries), and it is only in the ora serrata that coarser venous anastomoses exist.

## F. THE VITREOUS BODY.

The **vitreous body** consists of a semifluid tissue containing very few fixed cellular elements and only a small number of leucocytes. The latter are found only on the surface of the vitreous humor, between it and the retina. Thin structureless lamellæ and fibers occur throughout the entire vitreous body, with the exception of the hyaloid canal. These are particularly numerous at the periphery and especially in the region of the ciliary body. The outer or **hyaloid membrane** of the vitreous body, separating the latter from the retina, is somewhat thicker in the region of its close attachment around the physiologic excavation of the optic nerve and to the external limiting membrane of the retina in the ciliary region. In the latter region the hyaloid membrane is closely connected with the epithelium of the pars ciliaris retinae. It does not, however, penetrate into and between the ciliary processes, but extends like a bridge over the furrows between them. This arrangement gives rise to spaces, the *recessus camerae posterioris*, which form a division of the posterior chamber, and are inclosed between the hyaloid membrane, the ciliary processes, the suspensory ligament of the lens, and the lens itself; these spaces are filled with aqueous humor. In the region of the ciliary processes the hyaloid membrane splits up into numerous fibers, which diverge fan-like toward the lens and become blended with the outer lamella of the lens-capsule. Those coming from the free ends of the ciliary processes become attached

along the equator of the lens and to the adjacent posterior portion of the lens-capsule. On the other hand, the fibers originating between the ciliary processes attach themselves to the anterior surface of the lens-capsule in the immediate vicinity of the equator. Together these fibers constitute the *zonula ciliaris*, *zonule of Zinn*, or the **suspensory ligament of the lens**. Between these fibers of the zonula and the lens itself there is, consequently, a circular canal divided by septa, the **canal of Petit**, which communicates by openings with the anterior chamber.

### G. THE CRYSTALLINE LENS.

As we have already seen, the **crystalline lens** originates as an ectodermic invagination, which then frees itself from the remaining ectoderm in the shape of a vesicle and becomes transformed into the finished lens. In this process the cells of the inner wall of the vesicle become the lens-fibers, while those of the outer portion remain as the anterior epithelium of the lens. The lens is surrounded on all sides by the lens-capsule.

The **lens capsule** is a homogeneous membrane, nearly twice as thick on the anterior surface of the lens as on the posterior. Its chemic reactions differ from those of connective tissue, and in this respect it may be compared with the *membranæ propriæ* of glands. In sections the lens capsule appears to possess a tangential striation; under the influence of certain reagents, and under proper preliminary treatment, lamellæ may be detached from its surface which are found to be directly connected with the fibers of the suspensory ligament.

The **anterior epithelium** consists, in the fetus, of columnar cells; in children, of cells approaching the cubic type; and in the adult, of decidedly flattened cells. Toward the equator of the lens, in the so-called transitional zone, the cells increase in height and gradually pass over into the lens fibers.

The **lens fibers** are also derivatives of epithelial cells; they are long, flattened, hexagonal prisms, which extend through the entire thickness of the lens. In the adult the lens may be differentiated into a resistant peripheral and a softer axial substance. The surfaces of the fibers present irregularities, and it is with the help of these serrations and a cement substance that the fibers are bound together. Each fiber possesses one or more nuclei, which, although they have no constant position, are usually found in the middle of the fibers situated near the lens-axis, and in the anterior third of those at some distance from the axis. The course of the fibers in the lens is extremely complicated.

## H. THE FETAL BLOOD-VESSELS OF THE EYE.

In the eye of the embryo the vitreous body and the capsule of the lens contain blood-vessels. The vessel which later becomes the central artery of the retina passes through the space subsequently occupied by the vitreous body as far as the posterior surface of the lens (anterior hyaloid artery) and branches in the region of the posterior and anterior lens-capsule. The anterior vascular membrane of the lens capsule of the embryo is known as the *membrana capsulopupillaris*, and that portion corresponding to the pupil, as the *membrana pupillaris*. In the embryo numerous other vessels arise at the papilla and extend over the surface of the vitreous body close to the hyaloid membrane; these are the *posterior hyaloid arteries*. These vessels later disappear. In place of the anterior hyaloid artery there remains in the vitreous humor a transparent cylindrical cord containing no fibers nor lamellæ, as is the case in the remaining portion of the vitreous body, and consisting of a more fluid substance; this is the *hyaloid canal*, or the *canal of Cloquet*.

With regard to the posterior hyaloid vessels, the generally accepted theory is that they later enter into the formation of the retinal vessels. Little is known as to the details of this process; but the fact remains that, in the rabbit, for instance, the larger branches of the retinal vessels are internal to the inner limiting membrane, and, therefore, within the vitreous body, and that they send smaller branches into the retina (His, 80).

## I. INTERCHANGE OF FLUIDS IN THE EYEBALL.

The **anterior lymph-channels** of the eye comprise (1) the lymph-canalculi of the cornea, which communicate with similar structures in the sclera; (2) the system of the anterior chamber, which is indirectly connected, on the one hand, with the canal of Schlemm by means of the spaces of Fontana, and with the stroma iridis, into which the ligamentum pectinatum extends; while, on the other hand, it communicates with the posterior chamber and its recesses, and with the canal of Petit.

In the posterior region of the eyeball are the lymph-channels of the retina (the perivascular spaces), those of the optic nerve, the space between the pigment layer and the remaining portion of the retina (interlaminar space, Rauber), and the lymph-spaces of the choroid and sclera. The influx and efflux of intraocular fluid occur principally by means of filtration. The influx takes place through the ciliary processes; that the choroid has to do with this process is very improbable. The efflux takes place through the veins of the canal of Schlemm, into which the fluid filters through the cement lines of the endothelial lining of the canal of Schlemm,

finally emptying into the anterior ciliary veins. A posterior efflux from the vitreous body probably does not exist, or at least occurs to a very limited extent. The anterior chamber possesses no efferent lymph-vessels (Leber, 95).

## J. THE PROTECTIVE ORGANS OF THE EYE.

### 1. THE LIDS AND THE CONJUNCTIVA.

At the end of the second month of embryonic life the eyelids begin to develop in the shape of two folds of skin. At the end of the third month these folds come in contact in the region of what is later the palpebral fissure, and grow together at their outer epithelial margins. Shortly before birth the two lids again separate and the definitive palpebral fissure is formed.

The eyelids show three distinct layers: (1) the external cutis, which presents special structures at its free margin and continues about 1 mm. inward from the inner border of the free margin; (2) the mucous membrane, or palpebral conjunctiva, beginning from this line and covering the entire internal surface; and (3) a middle layer.

1. The **cuticular portion** of the eyelid consists of a thin epidermis and a dermis poorly supplied with papillæ. Fine lanugo-like hairs with small sebaceous glands and a few sweat-glands are distributed over its entire surface. The cutaneous connective tissue is very loose, contains very few elastic fibers, and is supplied with pigment cells in the superficial layers. At the *lid-margin* the papillæ are well developed and the epidermis is somewhat thickened. The anterior margin supports several rows of larger hairs, the *cilia*, the posterior row of which possesses, besides the sebaceous glands, modified sweat-glands, the *ciliary glands of Moll*, which also empty into the hair follicles. The eyelids are further provided with numerous glands, known as the Meibomian or tarsal glands. About thirty of these glands are found in the upper, a slightly smaller number in the lower, lids. They lie within the tissue of the tarsus vertical to the palpebral margin. Each gland consists of a tubular duct, lined by stratified squamous epithelium, beset with numerous simple or branched alveoli lined by a stratified, cubic epithelium in every respect similar to that lining the alveoli of sebaceous glands. The ducts of these glands terminate at the palpebral margin posterior to the cilia.

2. The **conjunctival portion** of the eyelids is lined by a simple pseudostratified columnar epithelium, possessing two strata of nuclei. This is continuous with the bulbar conjunctiva at the conjunctival fornix, and is characterized by the occasional presence of folds and sulci. Longitudinal folds in the upper portion of the upper lid running parallel with the lid-margin are frequently present. Goblet cells are usually found in the epithelium. According to W. Pfitz-

ner (97), the epithelium of the conjunctiva consists of two or three strata of cells, of which the more superficial possess a cuticular margin. Certain structures which have always been regarded as goblet cells are in all probability similar to the *cells of Leydig*—*i. e.*, mucous cells, which do not pour their secretion out over the surface of the epithelium. Some lymphoid tissue is always found in the stratum proprium of the mucous membrane, and occasionally it

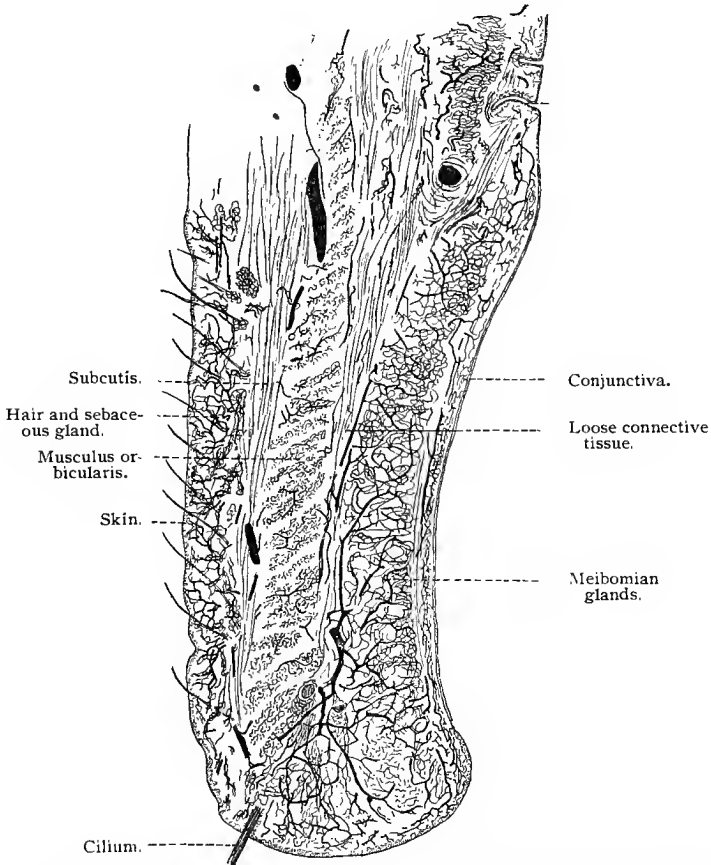


Fig. 341.—Cross-section of upper eyelid of man; the blood-vessels injected. By reason of the characteristic arrangement of the capillaries in the several layers of tissue, the extent and arrangement of these may be readily ascertained.

is seen to form true lymph-nodules. It is of some interest to note that a marked production of these lymph-nodules occurs in certain diseases. Such lymph-nodules are usually associated with epithelial crypts, which fact led Henle to regard them as glandular formations. Small glands with a structure similar to that of the lacrimal glands are also present in the palpebral conjunctiva; they are found

in the upper eyelid, at the outer angle of the conjunctival fornix. Similar glands occur also at the mesial angle of the fornix.

3. Besides the *tarsus* (fibrocartilage) the **middle layer of the eyelid** contains: (1) The musculus orbicularis oculi, which lies beneath the subcutaneous tissue. At the margin of the lid this structure gives off the musculus ciliaris Riolani, which is composed of two fasciculi separated by the tarsus. (2) The connective tissue between the bundles of the musculus orbicularis oculi. (3) The connective tissue lying behind the latter and the tarsus. In the upper lid the connective tissue mentioned under 2 and 3 is connected with the tendon of the musculus palpebralis superior. The latter is composed of smooth muscle-fibers, and is regarded as a continuation of the middle portion of the striated, voluntary musculus levator palpebræ superioris. The middle layer of the lower lid is structurally analogous, except that here the inferior rectus muscle takes the place of the levator palpebræ.

The blood-vessels of the eyelid lie directly in front of the tarsus, and from this region supply adjacent parts; they reach the posterior portion of the lid either by penetrating the tarsus or by encircling it (Waldeyer, 74).

The "third eyelid," the plica semilunaris, contains, when well developed, a small plate of hyaline cartilage.

At the fornix the epithelium of the palpebral conjunctiva becomes continuous with the two- or three-layered squamous epithelium of the conjunctiva bulbi. Beneath this epithelium is found a loose fibro-elastic connective tissue, presenting subepithelial papillæ, and quite vascular. In it are found medullated nerve-fibers, some of which terminate in free sensory nerve-endings in the conjunctival epithelium; others terminate, especially near the corneal margin, in end-bulbs of Krause; and still others may be traced to the cornea, to terminate in a manner previously described.

## 2. THE LACRIMAL APPARATUS.

The lacrimal apparatus consists of the lacrimal glands, their excretory ducts, the lacrimal puncta and canaliculi, the lacrimal sac, and the nasal duct.

The **lacrimal gland** is separated into two portions, of which the one lies laterally against the orbit and the other close to the upper lateral portion of the superior conjunctival fornix. The structure of the gland is, on the whole, that of a serous gland (parotid), with the difference that the intralobular ducts are not lined by a striated epithelium such as is found in the salivary tubules, and that those cells which are wedged in between the secretory elements and functionate as sustentacular cells (basket-cells) are here much more highly developed.

The excretory ducts of the orbital division generally pass by the conjunctival half of the gland, taking up a few ducts from the latter

as they go, and finally empty on the surface of the conjunctiva. Aside from these, the lateral portion of the gland possesses also independent ducts. All the excretory ducts are lined by columnar epithelium and surrounded by a relatively thick connective-tissue wall having inner longitudinal and outer circular fibers. From the lateral portion of the conjunctival culdesac, into which the secretion is brought by the excretory ducts of the lacrimal gland, the secretion passes into the capillary space of the sac, and is then evenly distributed by means of the sulci and papillæ over the conjunctival surface of the lid. In this manner the secretion reaches the mesial angle of the lid, whence it passes through the lacrimal puncta into the lacrimal canals.

The nerve supply of the lacrimal glands is from the sympathetic nervous system. The neuraxes of sympathetic neurones accompany the gland ducts and form plexuses about the alveoli, the terminal branches of which may be traced to the gland cells.

The lacrimal canals are lined by stratified squamous epithelium, and possess a basement membrane as well as a connective-tissue layer containing circularly disposed elastic elements. Externally we find a layer of transversely striated muscle-fibers.

The **lacrimal sac** is provided with a simple pseudostratified columnar epithelium having two strata of nuclei. In it goblet cells are also found. The **nasal duct** is lined by a similar epithelium. The connective-tissue wall of the latter and that of the lacrimal sac come in contact with the periosteum; between them is a well-developed vascular plexus. Stratified squamous and ciliated epithelium have been described as being present in the nasal duct, as well as mucous glands in both nasal duct and lacrimal sac. (See works of M. Schultze, 72; Schwalbe, 87.)

#### TECHNIC.

**316.** The eyes of the larger animals, after having been previously cleaned by removing the muscles and loose connective tissue, are placed in the fixing fluid and cut into two equal parts by means of an equatorial incision. Smaller eyes with thin walls may be fixed whole.

Müller's fluid (T. 27), nitric acid (T. 25), and Flemming's fluid (T. 17) are usually employed as fixing agents. After fixing in one of these fluids, different parts of the eyeball are imbedded in celloidin or celloidin-paraffin and then sectioned.

**317.** The corneal epithelium is best macerated in 33% alcohol; the membrane of Descemet may be impregnated with silver. In order to bring the fibers of the latter into view, Nuel recommends an injection of 1% to 2% formic acid into the anterior chamber of the eye of a dove or a rabbit, after having drawn off the aqueous humor. The cornea is then cut out, and fixed for from three to five minutes in osmic acid.

**318.** The substantia propria is examined either by means of sections or by means of teased preparations from a cornea macerated in lime-water or potassium permanganate. The sections are stained with picro-

carmin (Ranvier). The corneal spaces and canaliculi may be demonstrated in two ways with the aid of silver nitrate; either the fresh cornea of a small animal is stripped of its epithelium, cauterized with a solid stick of silver nitrate, and then examined in water, in which case the corneal spaces and their canaliculi show light upon a dark ground (negative impregnation); or the corneæ of larger animals are treated in the same manner, after which tangential sections are made with a razor, and placed in water for a few days; in this case the corneal spaces and their canaliculi show dark upon a light ground (positive impregnation, Ranvier, 89).

**319.** By means of Altmann's oil method (T. 112) casts of the corneal spaces and their canaliculi may be made. Treatment by the gold method often brings out not only the nerves, but also the corneal corpuscles and their processes.

**320.** Ranvier (89) especially recommends a 1% solution of the double chlorid of gold and potassium for the corneal nerves. The cornea of the frog is treated for five minutes with lemon-juice, then for a quarter of an hour with 1% potassium-gold chlorid solution, and, finally, for one or two days with water weakly acidulated with acetic acid (2 drops to 30 c.c. of water), the whole process taking place in the light. Golgi's method may also be used, but the gold method is more certain.

**321.** The sclera is treated in a similar manner.

**322.** The pigmentation of the vascular layer interferes with examination, and albinotic animals should therefore be selected; or the pigment may be removed from the previously fixed eyeball with hydrogen peroxid or nascent chlorin. The latter method is applied exactly as in cases where the removal of osmic acid is desired (T. 144).

**323.** The adult lens is sectioned with difficulty, as it becomes very hard in all fixing fluids. The anterior capsule of the lens may be removed from previously fixed specimens and examined by itself. The lens-fibers are demonstrated by maceration in  $\frac{1}{3}$  alcohol (twenty-four hours) or in strong nitric acid. Before immersion the lens-capsule is opened by a puncture.

**324.** The retina can rarely be kept unwrinkled in eyes that have been fixed whole. The eyeball should therefore be opened in the fixing fluid and the latter permitted to act internally; or the external tunics are removed, thereby enabling the fixing fluid to act externally.

**325.** Ranvier recommends subjecting the eyes of smaller animals (mouse, triton) for a quarter or half hour to the action of osmic acid fumes (*vid.* T. 16), after which the eyes are opened in  $\frac{1}{3}$  alcohol with the scissors. At the end of three or four hours the posterior half of the eye is stained for some time in picrocarmin (T. 67), then carried over into 1% osmic acid for twelve hours, washed with water, treated with alcohol, and cut.

In osmic acid preparations the rod-nuclei show dark transverse bands, a condition due to the fact that the end-regions of the nuclei stain more deeply.

The retina is a good object for differential staining, as, for instance, with hematoxylin-eosin, hematoxylin-orange G, etc. The latter combination is particularly successful in staining the rod- and cone-ellipsoids. The examination of tangential sections should not be omitted.

**326.** With the retina the best results are obtained by means of Golgi's method. Attention must be called to the fact that the supporting structures of the retina are more easily impregnated than the nervous elements, and that the latter can be demonstrated to any extent only in very young eyes.

**327.** Ramón y Cajal (94) recommends the following method, modified after Golgi: After the removal of the vitreous humor the posterior half of the eyeball is placed for one or two days in a mixture containing 3% potassium bichromate 20 c.c. and 1% osmic acid 5 or 6 c.c. The pieces are then dried with tissue paper and placed in a 0.75% silver nitrate solution for an equal length of time. Without washing, the pieces are immersed for from twenty-four to thirty-six hours in a mixture containing 3% potassium bichromate 20 c.c., and 1% osmic acid 2 or 3 c.c., and then again carried over into a 0.75% silver nitrate solution for twenty-four hours. In order to prevent precipitation it is advisable to roll up the retina before treating, and to cover it with a thin layer of a thin celloidin solution, which prevents it from again unrolling.

**328.** The methylene-blue method (T. 312) will also bring out the nervous elements of the retina, although the results are not quite so satisfactory as those obtained by Golgi's method.

## IX. THE ORGAN OF HEARING.

THE ear, the organ of hearing, consists of three parts: (1) The external ear, including the pinna or auricle and the external auditory canal; (2) the middle ear, tympanum, or tympanic cavity, containing the small ear bones and separated from the external auditory canal by the tympanic membrane, but communicating with the pharynx by means of the Eustachian tube; (3) the inner ear, or labyrinth, consisting of a bony and a membranous portion, the latter lined by epithelial cells, especially differentiated in certain regions to form a neuro-epithelium, in which the auditory nerves terminate. The first two parts serve for the collection and transmission of the sound-waves; the complicated labyrinth, with its differentiated neuro-epithelium, for the perception of the same. Figure 342 presents in a schematic way the relationships of the parts here mentioned.

### A. THE EXTERNAL EAR.

The cartilage of the ear, including that of the external auditory passage, is of the elastic variety, but differs from typical elastic cartilage in that it contains areas entirely free from elastic fibers. The elastic reticulum is, however, never absent near the perichondrium. The skin covering the pinna is thin, and in it are found hairs with relatively large sebaceous glands; sweat-glands are found on the outer surface.

The skin lining the cartilaginous portion of the external auditory canal possesses very few pronounced papillæ, and is characterized by the presence of so-called *ceruminous glands*, which represent modified and very highly differentiated sweat-glands. Two or three of the latter sometimes become confluent, and then possess only a single excretory duct, which, as a rule, empties into a hair follicle near the surface of the skin. The corium is somewhat mobile.

The skin lining the osseous portion of the external auditory canal is supplied with neither hair nor glands, and possesses slender papillæ, especially in the neighborhood of the tympanic membrane. The corium is closely attached to the periosteum.

The tympanic membrane consists of a tense and a flaccid portion.

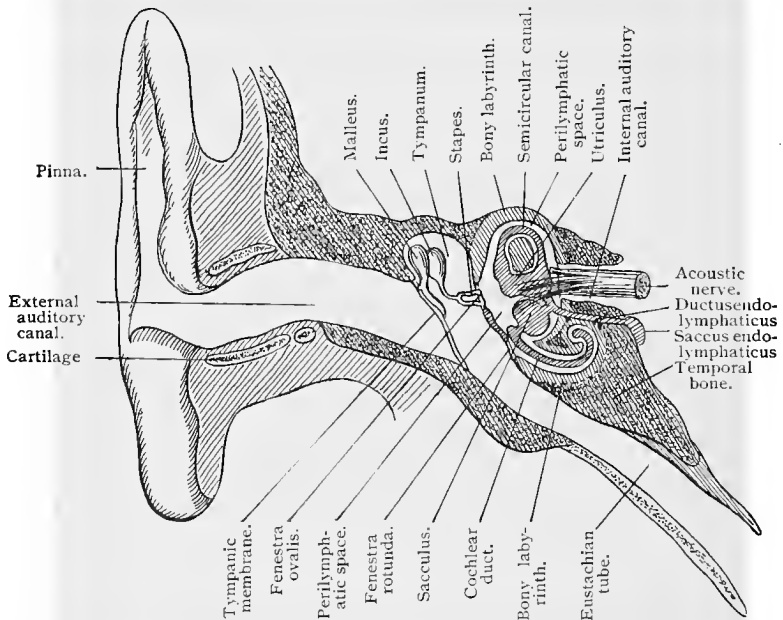


Fig. 342.—Schematic representation of the complete auditory apparatus (Schwalbe).

It forms a part of both the external and the middle ear. From without inward, the following layers may be differentiated: (1) the cutaneous layer; (2) the lamina propria; and (3) the mucous layer.

The epidermis of the cutaneous layer is identical in structure with that of the outer skin, except that the superficial layers of the stratum corneum contain nucleated cells. The corium is very thin, except along the course of the manubrium of the malleus, where it is thickened, forming the so-called *cuticular ridge*, which possesses papillæ and is supplied with vessels and nerves.

The lamina propria ends peripherally in a thickened ring of fibrocartilaginous tissue, the *annulus fibrosus*, which unites at the sulcus

tympanicus with the periosteum of the latter. The lamina propria is composed of connective-tissue fibers, in which two layers may be distinguished—externally, the radiate fibers, the *stratum radiatum*, and internally, the circular fibers, the *stratum circulare*. The external radiate layer extends from the annulus to the umbo and manubrium, and is interrupted in the flaccid portion of the tympanic membrane by the upper fourth of the manubrium and the short process of the malleus; it gradually thins out toward the center until it finally disappears in the vicinity of the umbo. The fibers of the inner (circular) layer are circularly disposed. This layer is thickest at the periphery of the tympanic membrane, becoming gradually thinner toward the lower end of the manubrium, where it disappears. Between the two layers of the lamina propria is a small quantity of loose connective tissue. The manubrium of the malleus is inclosed within the tympanic membrane. This is due to the union of the fibers of the radial layer with the outer strata of the manubrial perichondrium, the handle of the malleus being here covered by a thin layer of cartilage. In the posterior upper quadrant of the tympanic membrane the two layers of the lamina propria intermingle, forming irregularly disposed bundles and trabeculæ, the *dendritic fibrous structures of Gruber*.

The mucous layer of the tympanic membrane consists of simple squamous epithelium separated from the lamina propria by a thin connective-tissue layer containing but few cells. It likewise extends over the handle of the malleus. In the flaccid portion of the tympanic membrane the lamina propria disappears, so that in this region the cutaneous layer and the mucous membrane are in direct contact.

## B. THE MIDDLE EAR.

The middle ear, or tympanum, is a small irregular cavity, filled with air, situated in the petrous portion of the temporal bone between the bony wall of the inner ear and the tympanic membrane, and communicates with the pharynx through the Eustachian tube. It contains the small bones of the ear, their ligamentous attachments, and, in part, the muscular apparatus moving them.

The mucous membrane lining the tympanic cavity is folded over the ossicles and ligaments of the tympanum and is joined to that of the tympanic membrane and the Eustachian tube, the line of junction with the former being marked by the presence of papilla-like elevations.

The epithelium of this mucous membrane is a simple pseudostratified ciliated epithelium, having two strata of nuclei. Cilia are, however, lacking on the surface of the auditory ossicles, on their ligaments, and on the promontory of the inner wall, as well as on the tympanic membrane. The mucosa of the mucous membrane is intimately connected with the periosteum, and contains short isolated

alveolar glands, especially in the neighborhood of the opening of the Eustachian tube.

The "auditory ossicles" are true bones with Haversian canals and lamellæ; with the exception of the stapes, they contain no marrow-cavity. Very distinct perivascular spaces are seen surrounding the vessels in the canals (Rauber). The malleus articulates with the incus, both articular surfaces being covered with hyaline cartilage. Within this articulation we find a fibrocartilaginous meniscus, and at the summit of the short limb of the incus another small cartilage plate. Between the lenticular process of the incus and the capitulum of the stapes is another articulation, also provided with cartilaginous articular surfaces. The basal plate of

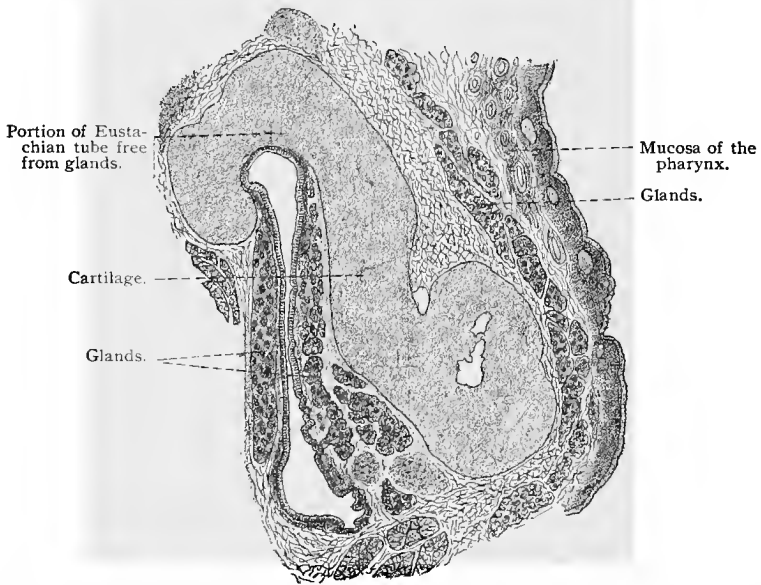


Fig. 343.—Cross-section of the Eustachian tube with its surrounding parts;  $\times 12$  (from a preparation by Professor Rüdinger).

the stapes is covered both below and at its edges with cartilage, as are also the margins of the fenestra ovalis (fenestra vestibuli). The basal plate is held in place within the fenestra by an articulation, provided with tense ligamentous structures on the tympanic and vestibular sides. Between these the connective tissue is quite loose. All the cartilaginous portions of the auditory ossicles, with the exception of the articular cartilages, rest on the periosteum (Rüdinger, 70).

The *fenestra rotunda* (fenestra cochleæ) is closed by the secondary or inner tympanic membrane, a connective-tissue membrane containing vessels and nerves, the outer wall of which is covered by

ciliated epithelium, the inner (the surface toward the scala tympani) by flattened endothelial cells.

In the antrum and mastoid cells, the mucosa of the mucous membrane is immovably fixed to the periosteum. The epithelium is of the simple squamous variety and is nonciliated.

The mucous membrane of the osseous portion of the Eustachian tube is very thin, and its mucosa is intimately connected with the periosteum. Its epithelium is of the simple pseudostratified ciliated variety, having two strata of nuclei. There are no glands. The mucous membrane of the cartilaginous portion of the Eustachian tube is thicker, and its epithelium, which is of the stratified ciliated variety, is higher, and often contains goblet-cells. Lymphoid tissue may be demonstrated in the mucosa of this portion, and occasionally structures resembling lymph-nodules are found, especially in the vicinity of the pharyngeal opening of the tube. In the cartilaginous portion of the tube are mucous glands, which are particularly numerous in the vicinity of the pharyngeal opening (Rüdinger, 72, 2).

### C. THE INTERNAL EAR.

The internal ear consists of an osseous and a membranous portion, the *osseous* and the *membranous labyrinth*; the latter is contained within the former, and, although smaller, presents the same

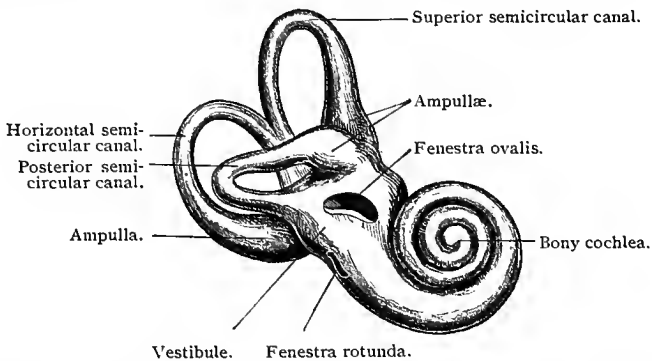


Fig. 344.—Right bony labyrinth, viewed from outer side: The figure represents the appearance produced by removing the petrous portion of the temporal bone down to the denser layer immediately surrounding the labyrinth (from Quain, after Sömmering).

general shape. The two structures are separated by a lymph-space containing the perilymph.

In the *bony labyrinth* we recognize a central portion of ovoid shape, known as the *vestibule*, the outer wall of which forms the inner wall of the tympanum and presents two openings, the fenestra ovalis and the fenestra rotunda, separated by a ridge known as the promontory. This ridge becomes continuous with the lower portion

of the bony cochlea, anterior and mesial to the vestibule and having the shape of a blunt cone. From the posterior portion of the vestibule arise three semicircular canals, known respectively as the *external* or *horizontal semicircular canal*, the *anterior superior vertical*, and the *posterior inferior vertical semicircular canals*. The canals communicate with the vestibule by means of five openings, the superior contiguous portions of the anterior and posterior canals uniting to form the *canalis communis* before reaching the vestibule. The three canals present near their origin from the vestibule enlargements known as the osseous ampullæ. The osseous labyrinth is lined throughout by a thin layer of periosteum, covered by a layer of endothelial cells.

The **membranous labyrinth** differs in shape from the osseous

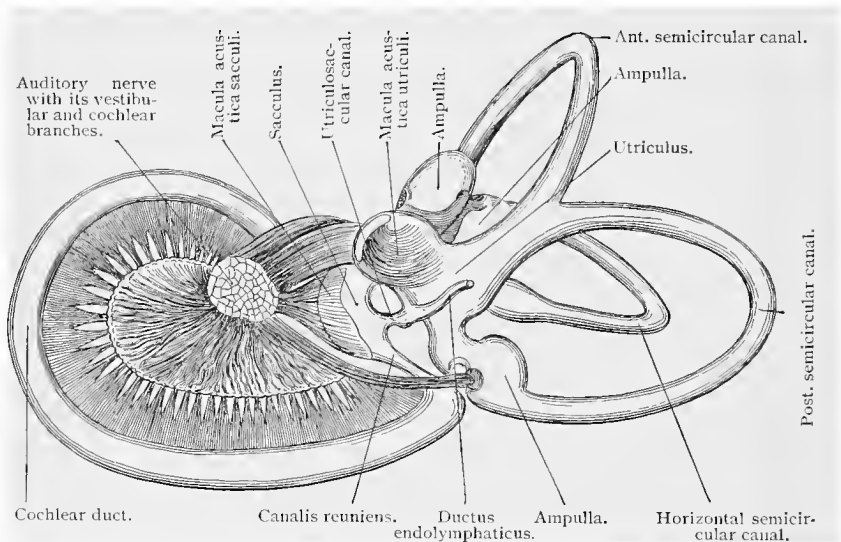


Fig. 345.—Membranous labyrinth of the right ear from five-month human embryo (from Schwalbe, after Retzius).

labyrinth in that, in place of the single chamber (vestibule) of the latter, the membranous labyrinth presents two sacs, the **utricle** and the **sacculus**, united by a narrow duct, the **utriculosaccular duct**. The utricle is the larger, and from it arise the membranous semicircular canals. These present ampullæ, situated within the osseous ampullæ previously mentioned. The sacculus communicates with the cochlear duct by means of the *canalis reuniens* (Hensen). From the utriculosaccular duct arises the *ductus endolymphaticus*, which passes through the *aqueductus vestibuli* and ends in a subdural *saccus endolymphaticus* on the posterior surface of the petrous portion of the temporal bone.

In the membranous labyrinth the nerves are distributed over certain areas known as the *maculae*, *cristae*, and *papilla spiralis*.

There is a macula within the recess of the utriculus, the *macula acustica utriculi*; and another within the sacculus, the *macula acustica sacculi*; cristæ are present in the ampullæ of the upper, posterior, and lateral semicircular canals, the *cristæ ampullares sup., post., et lat.* Besides these, we have the terminal arborization of the acoustic nerve in the membranous cochlea, the *papilla spiralis cochleæ*, or the organ of Corti.

### 1. UTRICULUS AND SACCULUS.

Only the inner wall of the utriculus is connected with the periosteum of the vestibule. In this region lies the corresponding

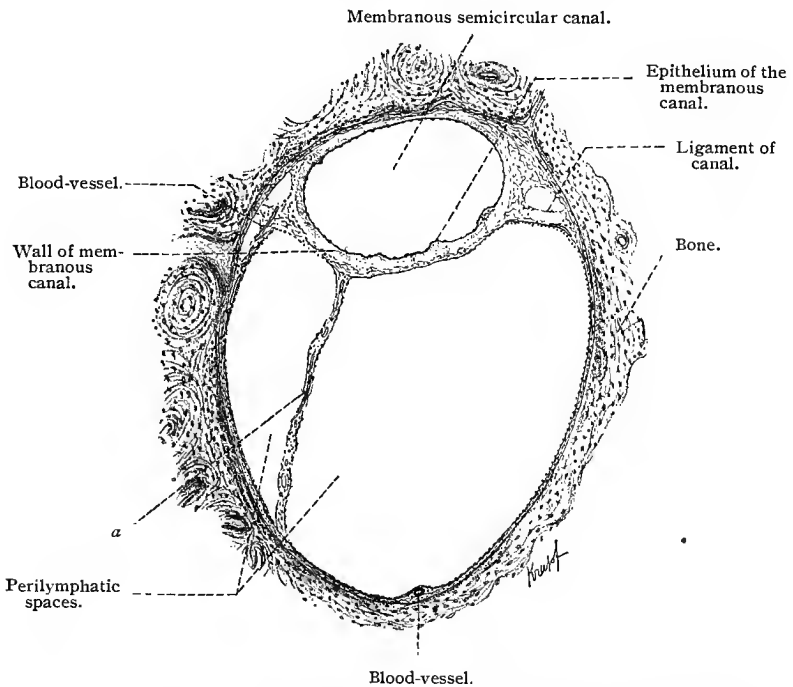


Fig. 346.—Transverse section through an osseous and membranous semicircular canal of an adult human being;  $\times 50$  (after a preparation by Dr. Scheibe): *a*, Connective-tissue strand representing a remnant of the embryonic gelatinous connective tissue. Such strands serve to connect the membranous canal with the osseous wall.

macula cribrosa, through which the nerves penetrate to the macula of the utriculus. The utriculus and sacculus fill only a part of the inner cavity of the osseous vestibule. Between the osseous and membranous portions remains a space traversed by anastomosing connective-tissue trabeculæ, and lined by endothelium, which also forms an investing membrane around the trabeculæ. These trabeculæ pass on the one side into the periosteum lining the vestibule,

and on the other, into the wall of the utriculus and sacculus. The cavity which they thus traverse represents a perilymphatic space. (Compare Fig. 346, which shows analogous relations in the semicircular canals.)

The wall of the utriculus, especially its inner portion, consists of dense fibrous connective tissue, most highly developed in the region of the macula acustica. In the immediate vicinity of the macula utriculi the epithelium of the utriculus is high columnar in type; in the remaining portion it consists of a single layer of low columnar cells, with a distinct basement membrane; the epithelium of the macula itself is also high, and is composed of two kinds of elements—of sustentacular elements and of the so-called auditory hair-cells. The *sustentacular cells* are tall epithelial cells resting on the basement membrane by means of their single or cleft basal plates. Each possesses an oval nucleus lying at or beneath the center of the cell. The *hair-cells* are peculiar cylindric elements with somewhat thickened and rounded bases. One end extends to the surface of the epithelium, while the other, which contains the nucleus, extends only to the center of the epithelial layer. The free end is provided with a cuticular zone supporting a number of long, stiff hairs, which often coalesce to form single threads. On the surface of the epithelium, which must be regarded as a neuro-epithelium, are crystals of calcium carbonate, known as *otoliths*, each of which incloses a minute central vacuole (Schwalbe). The otoliths are inclosed in a homogeneous substance, the *otolithic membrane*, which coagulates in a network of filaments when subjected to the action of fixing agents.

The *nerve-fibers* going to the macula penetrate the wall, and, under the epithelium, undergo dichotomous division, and, after further division, form, in the region of the basilar ends of the auditory cells, a plexus consisting of fine ramifications, and embracing the lower ends of the auditory cells. A few fibers extend still further upward, where their telodendria enter into intimate relations with the acoustic cells (v. Lenhossék, 94, 1).

The structure of the sacculus is in every respect like that of the utriculus, and a further description of it is therefore unnecessary.

## 2. THE SEMICIRCULAR CANALS.

The membranous semicircular canals are attached at their convex surfaces to the periosteum of the bony canals, which they only partly fill, the remaining cavity being occupied by an eccentrically situated perilymphatic space traversed by connective-tissue trabeculae. The walls of the perilymphatic spaces of the semicircular canals, like those surrounding the utriculus and the sacculus, are lined by endothelium, which covers, on the one hand, the periosteal surface of the bony semicircular canals, and, on the other hand, the outer wall of the membranous canals, together with the connective-tissue

trabeculæ. The connective-tissue walls of the membranous canals are structurally similar to those of the utricle and saccule. Hensen compares their structure to that of the substantia propria of the cornea. In the adult, the inner layer of the wall of the canals supports here and there papillary elevations, which, however, disappear along its attachment to the bony semicircular canal (Rüdinger, 72, 88).

The epithelium lining the membranous semicircular canals is simple squamous in character and very evenly distributed over the entire inner surface, including the papillæ previously mentioned. On the concave side of each semicircular canal the epithelial cells are somewhat narrower and higher. This inner and higher epithelium (raphé), extending along the concave side into the ampullæ, marks the region at which the semicircular canals were constricted off from the pocket-like anlagen. The epithelium of the ampullæ (Fig. 347), with the exception of that in the region of the raphé, is of the squamous type. At the cristæ of the ampullæ, however, there is found a neuro-epithelium similar to that of the maculæ. The cells adjoining both ends of the cristæ are high columnar, and to these the squamous epithelium is joined. The columnar cells just mentioned form the so-called *semilunar fold*. Otoliths are also present upon the neuro-epithelium of the cristæ. Here the structure corresponding to the otolithic membrane of the utricle and saccule is called the *cupula*. In preserved specimens it presents the appearance of a coagulum, showing a faint striation; in the fresh condition, it has never been recognized as a distinct structure, at least in the lower classes of vertebrates.

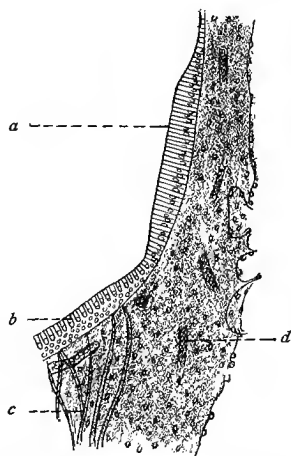


Fig. 347.—Part of a vertical section through the anterior ampulla, showing the membranous wall, a portion of the “crista acustica,” and the “planum semilunatum” (after Retzius): *a*, Semilunar fold; *b*, crista acustica; *c*, nerve-fibers; *d*, blood-vessels.

### 3. THE COCHLEA.

The cochlea consists of an osseous portion, the *bony cochlea*, a membranous portion, the *cochlear duct*, and two perilymphatic canals. The bony cochlea consists of a central bony axis of conical shape, the *modiolus*, around which is wound a spiral bony canal, having in man a little over two and one-half turns, the modiolus forming the inner wall of this canal. The summit of the cochlea, which has the shape of a blunt cone, is formed by the blind end of this bony canal, and is known as the *cupola*. The modiolus further

gives support to a spiral plate of bone, the *lamina spiralis ossea*, which extends from the lower part of the modiolus, and, forming two and one-half spiral turns, reaches its top, where it ends in a hook-like process, the *hamulus*. This bony spiral lamina partly divides the bony cochlear canal into two parts, the division being completed by a fibrous tissue membrane, the *lamina spiralis membranacea*, which extends from the free edge of the osseous spiral lamina to a thickened periosteal ridge, the *ligamentum spirale*, lining the outer wall of the bony cochlear canal. The canal above the lamina spiralis (bony and membranous) is known as the *scala vestibuli*, that below as the *scala tympani*. Both are perilymphatic canals, and communicate in the region of the last half-turn of the cochlea, by means of a narrow canal, the *helicotrema*, partly surrounded by the termination of the bony spiral lamina, the hamulus. The scala vestibuli is in free communication with the perilymphatic space of the vestibule; while the scala tympani communicates with perivascular spaces surrounding the veins of the cochlear aqueduct, which latter empty into the jugular veins. The scala tympani terminates at the secondary tympanic membrane, closing the fenestra rotunda.

The *cochlear duct*, which, as will be remembered, communicates with the sacculus by means of the canalis reuniens, is a long tube closed at both ends, the one end representing the vestibular sac, or *cæcum vestibulare*, and the other the cupolar extremity, or *cæcum cupolare*, also known as the lagena. The cochlear duct forms about two and three-fourths spiral turns, its length being about 3.5 mm. Its diameter gradually increases from its lower to its upper or distal extremity. The cochlear duct lies above the lamina spiralis, and, in a section of the cochlea parallel to the long axis of the modiolus, it is of nearly triangular shape, with the somewhat rounded apex of the triangle attached to the osseous lamina spiralis. In the cochlear duct we may distinguish the following parts: (1) the outer wall, which is intimately connected with the periosteum of the bony cochlear canal; (2) the tympanal wall, resting on the membranous basilar membrane, with its highly differentiated neuro-epithelium, the spiral organ of Corti; and (3) the vestibular wall, bordering on the scala vestibuli, the intervening structures forming a very delicate membrane—the *vestibular* or *Reissner's membrane*.

From the account given thus far, it may be seen that within the bony cochlear canal there are found three membranous canals, running parallel with one another and with the osseous lamina spiralis about which they are grouped. Two of these membranous canals, the scala vestibuli and the scala tympani, are perilymphatic spaces, and are consequently lined by endothelial cells; between them is found the cochlear duct, from its position known also as the *scala media*, lined by epithelial cells. These three membranous canals retain their relative position in their spiral course about the modiolus, and, in a section through the cochlea parallel to the bony

axis of the modiolus, would be met with at each turn, and at each turn present essentially the same relative position and structure. Figure 348 is sketched from such a section, and shows the appearance presented by a section through one of the turns of the bony cochlear canal as well as a section of the contained osseous lamina spiralis, the scalæ, and the cochlear duct. We may now proceed with a fuller consideration of the structures mentioned.

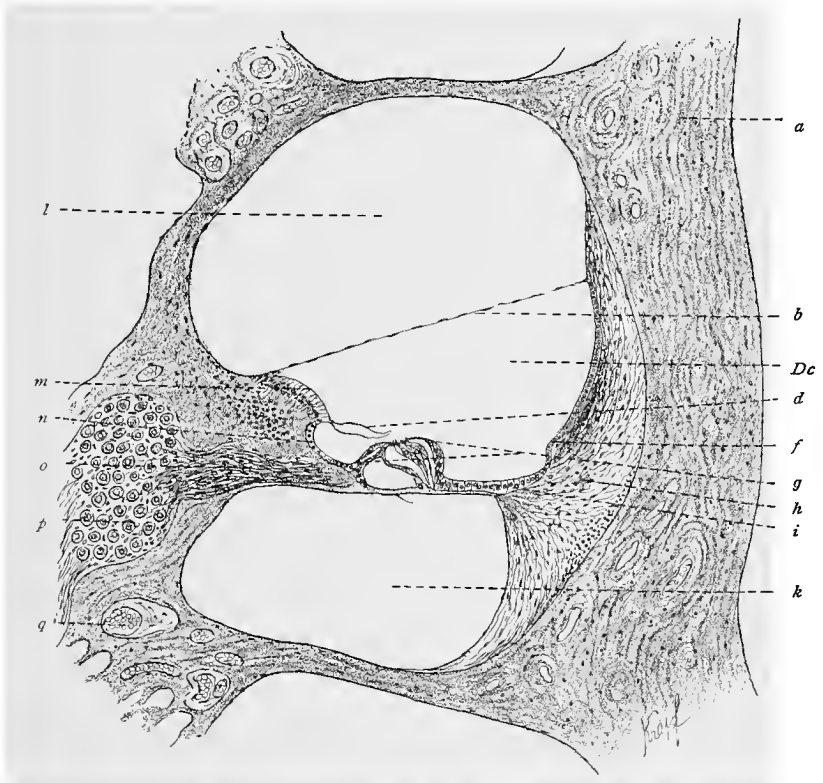


Fig. 348.—Section through one of the turns of the osseous and membranous cochlear ducts of the cochlea of a guinea-pig;  $\times 90$ : *l*, Scala vestibuli; *m*, labium vestibulare of the limbus; *n*, sulcus spiralis internus; *o*, nerve-fibers lying in the lamina spiralis; *p*, ganglion cells; *q*, blood-vessels; *a*, bone; *b*, Reissner's membrane; *Dc*, ductus cochlearis; *d*, Corti's membrane; *f*, prominentia spiralis; *g*, organ of Corti; *h*, ligamentum spirale; *i*, crista basilaris; *k*, scala tympani.

The **lamina spiralis ossea** consists of two bony plates which in-close between them the ramifications of the cochlear nerve. The vestibular surface of the osseous lamina spiralis is covered by periosteum, which is continuous with a peculiar tissue, known as *limbus spiralis*. The latter begins at the point of attachment of Reissner's membrane, extends peripherally (externally), and ends in two sharp ridges, of which the shorter, the *labium vestibulare*, projects

into the inner space of the cochlear duct and continues into the tectorial membrane; while the other and longer, the *labium tympanicum*, becomes attached to the wall of the scala tympani and continues into the basilar membrane. Between the two ridges is a sulcus, the *sulcus spiralis internus*. (Fig. 348.) The limbus spiralis is a connective-tissue formation in the region of the cochlear duct connected with the periosteum of the osseous spiral lamina and extending from the point of attachment of Reissner's membrane to the labium tympanicum. The tissue of the limbus spiralis is dense and richly cellular, and simulates in its structure the substantia propria of the cornea. A casual view would seem to disclose a high columnar epithelium, but upon closer observation, it is seen that the cellular elements are interspersed with fibers which extend to the surface. Some investigators regard this tissue as fibrocartilage; others, again, as a tissue *sui generis*, consisting of epithelial cells mingled with connective-tissue fibers. If the labium vestibulare of the limbus spiralis be examined from the vestibular surface, a number of irregular tubercles are seen at its inner portion (near Reissner's membrane), while at its outer portion long, radially disposed ridges may be observed, the so-called *auditory teeth* of Huschke. The connective-tissue wall of the sulcus spiralis internus consists of a nonnucleated fibrillar tissue which is continued into the labium tympanicum. The latter is perforated by nerves, thus giving rise at this point to the *foramina nervosa*.

Between the point of attachment of Reissner's membrane and the labium vestibulare, the superficial epithelium of the limbus spiralis is flat, and lines the auditory teeth and the depressions between them in a continuous layer. The epithelium of the sulcus spiralis internus is somewhat higher.

The **ligamentum spirale** forms the thickened periosteum of the outer wall of the osseous cochlear canal. It presents two inwardly projecting ridges, the *crista basilaris*, to which the membranous lamina spiralis is attached, and the *prominentia spiralis*, which contains one or several blood-vessels; between the two ridges lies the sulcus spiralis externus. The portion of the ligamentum spirale forming the periosteum of the bony cochlear canal consists of a fibrous tissue containing many nuclei, but changes internally into a looser connective tissue. The connective tissue lying external to the outer wall of the cochlear duct is very dense and rich in cellular elements and blood-vessels, but in the crista basilaris it changes to a hyaline, noncellular tissue, continuous with the lamina basilaris. That portion of the spiral ligament lying between the prominentia spiralis and the attachment of Reissner's membrane is known as the *stria vascularis*. The epithelium covering this area (a portion of the epithelium lining the cochlear duct) consists of cubic, darkly granulated cells, which show no distinct demarcation from the underlying connective tissue, and consequently appear to have blood-capillaries extending into the epithelium itself.

The membranous lamina spiralis, or the **basilar membrane**, extends from the tympanic lip of the osseous spiral lamina to the crista basilaris of the ligamentum spirale.

As already stated, the tissue composing the labium tympanicum of the limbus extends into the basilar membrane. In this membrane the surface toward the cochlear duct is known as the cochlear surface, that toward the scala tympani as the tympanic surface. Two layers are differentiated in the basilar membrane, the *lamina basilaris propria* and the *tympanic investing layer*. The lamina propria consists, in turn, of (1) radially arranged basilar fibers, or acoustic strings; (2) two thin strata of a homogeneous substance, one above and the other below the layer of basilar fibers, the upper of which is the thicker and nucleated; and (3) a fine cuticula, of epithelial origin, lying on the cochlear side. The *tympanic investing layer* is highly developed in youth, but later becomes thinner, and may then be differentiated into a connective-tissue layer, regarded as a periosteal continuation of the tympanic portion of the osseous lamina spiralis, and an endothelial cell layer belonging to the lining of the perilymphatic space or the scala tympani. In the vicinity of the labium tympanicum is a blood-vessel situated within the tympanic investing layer of the basilar membrane—the *vas spirale*.

**Reissner's membrane** consists of an exceedingly thin connective-tissue lamella, lined on the side of the cochlear duct by a layer of flattened epithelial cells and on the vestibular side by a layer of endothelial cells. The epithelium lining the cochlear duct is occasionally raised into small villus-like projections.

**The Organ of Corti.**—In the region of the labium tympanicum of the limbus spiralis and in the greater portion of the adjoining basilar membrane, the epithelium of the cochlear duct is peculiarly modified, forming here a neuro-epithelium, which receives the terminal ramifications of the cochlear nerve and is known as the **spiral organ of Corti**.

Passing from the labium tympanicum to the ligamentum spirale, the following three regions may be recognized in the organ of Corti: An inner region, composed of the inner sustentacular cells and the inner auditory cells; a middle region, consisting of the arches of Corti; and an outer region, in which are found the outer auditory cells and the outer sustentacular cells or Deiters's cells. Two cuticular membranes are in close relationship to the organ of Corti: namely, the *lamina reticularis* and the *membrana tectoria*, or membrane of Corti.

In figure 349, a sketch of the organ of Corti and adjacent structures, it may be observed that the epithelium lining the sulcus spiralis internus (at the right of the figure) is of the pavement variety, and that the epithelium becomes gradually thicker until the organ of Corti is reached, where it becomes suddenly elevated in the form of a wall. In this, two varieties of cells are distinguished

—sustentacular cells and inner auditory cells. The sustentacular cells, which follow the flattened cells, become gradually higher from within outward and occupy three or four rows. Next come the inner auditory cells, cylindrical elements, somewhat rounded and thickened at their nucleated basilar ends. The latter do not extend to the basilar membrane but end at about the level of the center of the inner pillars. At the free end of each cell is an elliptic cuticular zone, somewhat broader than the end-surface of the corresponding cell. In man about twenty rigid filaments, known as **auditory hairs**, are found resting on each elliptic cuticular zone. These are either arranged in a straight row or they describe a slight curve.

The middle division of the organ of Corti, the **arches of Corti**, consists of long slender structures, known as **pillar cells**, or, briefly, pillars, resting firmly upon the basilar membrane and forming an arch at the vestibular side of the latter. They surround, by the

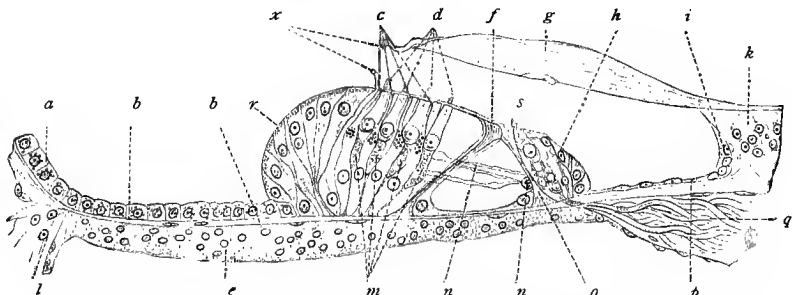


Fig. 349.—Organ of Corti: At *x* the tectorial membrane is raised; *c*, outer sustentacular cells; *d*, outer auditory cells; *f*, outer pillar cells; *g*, tectorial membrane; *h*, inner sustentacular cells; *i*, *p*, epithelium of the sulcus spiralis internus; *k*, labium vestibulare; *e*, tympenic investing layer; *m*, *n*, outer auditory cells; *n*, *n*, nerve-fibers which extend through the tunnel of Corti; *o*, inner pillar cell; *g*, nerve-fibers; *b*, *b*, basilar membrane; *a*, epithelium of the sulcus spiralis externus; *r*, cells of Hensen; *s*, inner auditory cell; *l*, ligamentum spirale (after Retzius).

union of their free ends, a space which, as seen in figure 349, appears triangular in section. This is the tunnel of Corti.

According to their position, we distinguish *inner* and *outer pillars*, the inner being more numerous than the outer. Including the entire extent of the lamina spiralis membranacea, we find that there are about 6000 of the inner and 4500 of the outer pillar cells.

Each pillar cell originates from an epithelial cell, and is found to be composed of a protoplasmic portion containing the nucleus, which may be regarded as a remnant of the primitive cell, and of a cuticular formation derived from the primitive cell, forming the elongated body of the pillar cell—the pillar. The free adjoining ends are called the *heads of the pillars*. The head of the inner pillar is provided with a flattened process, the head-plate, which extends outward and forms an obtuse angle with the axis of the

pillar. Under this plate, and at the outer side of the head of the inner pillar, is a depression into which fits the head of the outer pillar. The latter also extends outward in the shape of a *phalangeal plate*, with a thinner process, the *phalangeal process*, at its end. The phalangeal plate and process lie under the head-plate of the inner pillar, the process extending a little beyond this, forming an acute angle with the head of the outer pillar. At the inner side of the head of the outer pillar is a convex articular surface, with which, as a rule, two, and occasionally even three, articular surfaces of the inner pillars come in contact. The outer and inner pillars appear to possess an indistinct longitudinal striation, and their basilar plates are continuous with the extremely fine cuticula covering the basilar membrane. The inner margins of the basilar plates belonging to the inner pillars border on the foramina nervosa; while the outer margins of the basilar plates belonging to the outer pillars come in contact with the basal end of the innermost row of the cells of Deiters in the outer region of Corti's organ. The protoplasmic portions of the pillar cells, constituting what are known as basal cells, lie against the basilar plates of the corresponding pillars,—*i. e.*, on the basilar membrane,—and partly cover the bodies of the pillars, especially the surfaces toward the tunnel.

In order to comprehend the relative position of the inner auditory cells to the inner pillars, it may be stated that one auditory cell rests upon every two inner pillars.

The outer region of Corti's organ is joined directly to the outer pillar cells, and consists of four rows of auditory cells alternating with an equal number of sustentacular cells or **Deiters's cells**. Following these structures and in contact with them are the outermost sustentacular cells, known as **Hensen's cells**.

The **outer auditory cells** have a structure similar to that of the inner auditory cells, but possess a more slender body. They do not extend as far as the basilar membrane, but end at a distance from the latter equal to about double their own length. The cuticular zone of each outer auditory cell likewise assumes the form of an ellipse, with its long axis pointing radially. The surface of this zone also is provided with about twenty stiff auditory hairs, arranged in the form of a decidedly convex arch, the convexity of which points outward. At a short distance from the cuticular zone of each outer auditory cell is a peculiar round body, found only in these cells, the significance of which is unknown.

**Deiters's cells** rest on the basilar membrane, and in shape resemble a flask with a narrow neck, known as the *phalangeal process*, the latter lying between the auditory cells. The nuclei of Deiters's cells lie in the upper parts of the thickened basal portions of these cells.

With each Deiters's cell there is associated a cuticular structure, which extends along the surface of each cell in the form of a thin

fiber, the *sustentacular fiber*, and which is found partly within and partly without the cell. The sustentacular fiber begins near the center of the thicker basal portion of the cell-body and extends first into the cell itself, then passes to the surface, and, entering the phalangeal process, passes to the top of the cell and expands as a plate, to which the name *phalangeal plate* has been given. The latter is broader than the phalangeal process, and since, as we shall see, the phalangeal plates are joined to one another, as well as to the elliptically shaped cuticular zones of the outer auditory cells, there remains a space between the cells of Deiters and the auditory cells, as also between the outer pillars and the innermost of the outer auditory cells, known as *Nuel's space*. To the basal regions of the inner row of the cells of Deiters is joined the basal plate of the outer pillars of the arches of Corti.

Next to the outer row of Deiters's cells are the **cells of Hensen**, arranged in about eight radially disposed rows. They form an eminence which is high internally, but gradually decreases in height externally. The somewhat narrowed bases of Hensen's cells probably extend, without exception, to the basilar membrane. The free surfaces of these cells are likewise covered by a thin cuticular membrane. In man the cells of Hensen usually contain yellow pigment; in the guinea-pig, as a rule, fat; and in the rabbit, generally rudiments of sustentacular fibers. Externally the cells of Hensen gradually change into elements of a more cuboid type—the **cells of Claudius**, of which there are about ten rows, radially disposed. The surfaces of the latter also possess a cuticular margin; the nucleus is at the center of each cell and pigment is also present. Darker elements with more basally situated nuclei sometimes occur between these cells, giving rise to the appearance of a double-layered epithelium (Böttcher's cells).

Thus far we have considered in detail the cells comprising the organ of Corti, and described their relative positions and sequence from within outward. In order to give a clearer understanding of the mutual relations of these cells, from within outward and in the direction of the spiral turning of the cochlea, we shall now consider the appearance presented in a surface view of the organ of Corti.

From within outward a surface view of the organ of Corti presents the following characteristics: The somewhat broadened hexagonal outlines of the inner sustentacular cells adjoin the epithelial elements of the sulcus spiralis internus and terminate externally in a spiral undulating line (if seen for only a short distance, this line appears straight). On this line border the contours of the cuticular zones belonging to the inner auditory cells. The outer margins of the cuticular zones come in contact with the head-plates of the inner pillars, the cuticular zone of one inner auditory cell coming in contact with at least two head-plates. The externally directed processes of the head-plates belonging to the inner pillars come in contact with one another and end in a spiral line which for a short

distance is apparently straight. The head-plates of the inner pillars cover the head-plates of the outer pillars (which also come in contact with each other), also their phalangeal plates, but not their phalangeal processes, which thus project beyond the line formed by the outer borders of the head-plates of the inner pillars. It should be mentioned that about three head-plates belonging to the inner pillar cells are in apposition to every two head-plates and their phalangeal processes of the outer pillar cells. The succeeding four rows, from within outward, are made up of alternately placed cuticular zones of the outer hair cells and the phalangeal plates of the Deiters's cells, alternating like the squares of a chess-board. This regular arrangement is lost in the outer row of Deiters's cells. The cells of Hensen adjoin this row, and when viewed from the surface, present the appearance of irregular polygons.

This arrangement is, however, seldom found to be as typical as that just described; although the relations of the cells to one another always correspond in general to the foregoing scheme.

In the cupular and vestibular sacs the neuro-epithelium changes into an epithelium of an indifferent type.

The **lamina reticularis** is formed by the cementing together of the phalangeal processes of the outer pillars and the phalangeal plates of Deiters's cells, and is continued externally by a cuticular membrane which covers the cells of Hensen and, as a much thinner cuticular membrane, extends over the cells of Claudius. In this membrane there are found three or four rows of small apertures, into which the outer hair cells project.

The **membrana tectoria Cortii** is attached to the limbus spiralis, but becomes free at the margin of the labium vestibulare and thickens considerably, again becoming thinner toward its free end.

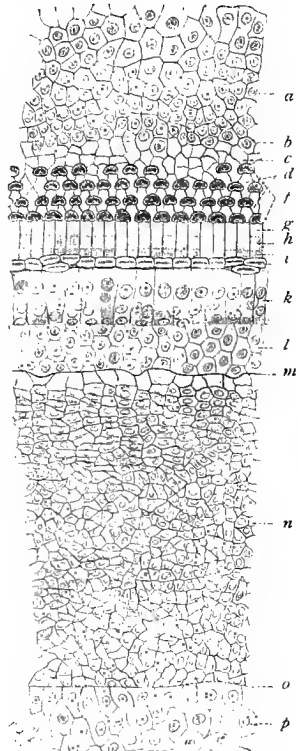


Fig. 350.—Surface of the organ of Corti, with the surrounding structures, from the basal turn of the cochlea of a new-born child; the original drawing reduced one-half (after Retzius, 84): *a*, Epithelium of the sulcus spiralis externus; *b*, Hensen's cells; *c*, terminal frame; *d*, phalanges; *e*, outer auditory cells; *f*, flattened processes of the outer pillar cells; *g*, flattened processes of the inner pillar cells; *h*, inner auditory cells; *i*, inner sustentacular cells; *l*, epithelium of the sulcus spiralis internus; *m*, margin of the labium vestibulare; *n*, epithelium of the limbus laminae spiralis; *o*, line of attachment of the membrana Reissneri; *p*, epithelium of the membrana Reissneri, the latter inverted.

Hence an inner attached and an outer free zone may be differentiated. This membrane has no nuclei, and shows a fine radial striation. Its free portion bridges over the sulcus spiralis internus and rests upon the organ of Corti. Its outer margin extends as far as the cells of Hensen. The development of this membrane is not thoroughly understood, although it very probably represents a displaced cuticular formation belonging to the cells of the limbus spiralis. This acceptance has recently been confirmed (Exner).

The **auditory nerve** gives off, soon after entering the internal auditory meatus, vestibular branches to the maculæ in the utriculus and sacculus and to the cristæ in the semicircular canals, and a cochlear branch, which passes up through the modiolus in anastomosing bony canals. From this centrally placed column of nerve-fibers, a continuous sheet of nerve-fibers, arranged in the form of anastomosing bundles, passes radially into the osseous spiral lamina and thence to the organ of Corti. Near the base of the osseous spiral lamina, along the entire length of this sheet of nerve-fibers, there is situated in a special bony canal a ganglion, known as the *spiral ganglion* of the cochlea. The ganglion cells of this ganglion are bipolar, one of the processes of each cell, the dendrite, extending outward through the osseous spiral lamina to the organ of Corti, the other process, the neuraxis, passing through the bony canal in the modiolus, through the internal auditory meatus, and thence to the medulla. The dendritic processes of the nerve-cells of the spiral ganglion form bundles of medullated nerve-fibers, which pass outward within the osseous spiral lamina, forming, in the outer portion of the latter, a closely meshed plexus, from which small bundles of nerve-fibers proceed through the foramina nervosa of the labium tympanicum to the organ of Corti; immediately before passing through these foramina, the medullated nerve-fibers lose their medullary sheaths and neurilemma.

These nonmedullated fibers, with or without further dividing, are then arranged in small bundles, which, for a certain distance, have a spiral course: that is to say, parallel to the tunnel of Corti. One such spiral bundle is situated on the inner side of the inner pillars, under the inner row of hair cells; another, on the outer side of the inner pillars, in the tunnel of Corti. Other fibers pass through the tunnel of Corti, so-called *tunnel-fibers*, to reach the outer side of the arches of Corti, where they are arranged in three or four spiral bundles, at the outer side of the outer pillars and between the rows of the cells of Deiters. From the nerve-fibers of these spirally arranged bundles, terminal branches are given off, which terminate, after further division, *on* the inner and outer hair cells.

Regarding the blood-vessels of the membranous labyrinth, it should be mentioned that the *internal auditory artery* is a branch of the basilar artery, and divides into the *rami vestibulares* and *rami cochleares*. The branches of the former accompany those of the auditory nerve as far as the utriculus and sacculus. At the maculæ



under the dura in a *saccus endolymphaticus*. In connection with the latter are epithelial tubules bordering upon lymph-channels, with which they probably communicate by means of interepithelial (intercellular) spaces (Rüdinger, 88). The efferent channels for the *perilymph* of the vestibule extend along the nerve sheaths of those nerves supplying the maculæ and cristæ; these passageways finally communicate with the subdural or subarachnoid spaces. The *perilymph* of the cochlea is carried off by the adventitious tissue of the vena aqueductus cochleæ, the lymph-vessels of which empty into certain subperiosteal lymph-channels near the inner margin of the jugular fossa.

#### 4. ON THE DEVELOPMENT OF THE LABYRINTH.

In man the epithelium lining the membranous labyrinth originates from the ectoderm as a single-layered epithelial vesicle, the auditory vesicle or the otocyst, during the fourth week of embryonic life. After being constricted off from the ectoderm, this vesicle lies in the vicinity of the epencephalon and is surrounded by mesenchyme. The auditory vesicle then develops a dorsomesial evagination, which gradually grows larger and finally becomes the *ductus endolymphaticus*. An evagination also occurs in the ventral wall of the vesicle, the *recessus cochleæ*. At the same time the mesial wall is pushed inward, thus incompletely dividing the vesicle into two smaller sacs—the dorsal *utriculus* and the ventral *sacculus*. From the utricular portion there arises a horizontal evagination, flat and quite broad—the first trace of the lateral or horizontal semicircular canal; soon after, another evagination, vertical and still broader than the first, is seen—the anlage of the other two canals. The outer portion of these pouches gradually expands, while in the middle, the two layers of each evagination come in contact with each other and coalesce, finally becoming absorbed. In the vertical evagination two such areas of adherence are found, thus forming a superior and a posterior canal, both having a common crus at one end.

The *recessus cochleæ* grows both in a longitudinal and in a spiral direction, forming the cochlear duct.

In the immediate vicinity of the membranous labyrinth, the mesenchyme is differentiated into a connective-tissue wall for the former. The successive layers of mesenchyme, except in those areas where the membranous labyrinth later becomes adherent to the osseous, are transformed into a mucous connective tissue. The latter is surrounded by a more compact tissue, from which are derived, first, cartilage; then bone and periosteum, and thus, finally, the osseous labyrinth. By a peculiar process of regressive metamorphosis most of the mucous connective tissue later disappears. In the adult it is replaced by the perilymphatic spaces of the labyrinth (compare Retzius, 84; Schwalbe, 87).

## TECHNIC.

**329.** In the treatment of the external and middle ear the usual methods are employed. For the study of the epithelium in conjunction with the adjacent bone the tissue is fixed and then decalcified, or subjected to those fixing methods which accomplish both processes at the same time. The latter method, however, can be applied only to very small objects.

**330.** The manipulation of the membranous labyrinth, especially that of the adult, is a very difficult technical problem. Its isolation from the petrous portion of the temporal bone without injury can be accomplished only in well-advanced fetuses and in children, and even here a thorough knowledge of the situation of the parts in the petrous portion of the temporal bone is essential. Smaller animals, especially rodents, afford better specimens. In the latter, the semicircular canals and cochlea give rise to more or less distinct projections into the tympanic cavity. If the latter be opened, the situation of the parts may be ascertained from without. In the rabbit and guinea-pig, the entire cochlea projects into the tympanic cavity, and may be easily removed in toto with a strong knife, and, as the bony cochlea in these animals has very thin walls, it offers very little resistance to the decalcifying fluid (use, for instance, 3% nitric acid).

**331.** According to Ranvier's method (80), the cochlea is opened with a scalpel in a 2% solution of osmic acid in normal salt solution. After twelve hours the cochlea is placed for decalcification in 2% chromic acid, which is frequently changed. In guinea-pigs, for instance, decalcification is accomplished in a week.

**332.** According to the method of Retzius (84), the opened cochlea is treated for half an hour with a 0.5% aqueous solution of osmic acid, and then for the same length of time with a 0.5% aqueous solution of gold chlorid. The organ of Corti is then dissected out and examined as a whole, or cut after carefully removing the bone.

**333.** The labyrinth of the human adult is usually prepared as follows: The apex of the petrous portion of the temporal bone is removed and the upper semicircular canal, together with the cochlea, opened in Müller's fluid; in this solution the pyramid is left for three weeks; during the first week the fluid is changed daily, and every two days during the following weeks. The specimen is then washed for twenty-four hours in running water, placed in 80% alcohol for two weeks, and finally in 96% alcohol for two days. The preparation is now ready for decalcification. This is done with 5% nitric acid, which is to be changed daily (ten days to two weeks). Then follows washing for two days in running water, carrying over into 80% alcohol for twenty-four hours, then into 96% alcohol for from six to eight days, and, finally, infiltration and imbedding in celloidin (A. Scheibe).

**334.** The following method may also be employed with good results: The isolated pyramid with opened semicircular canal and cochlea is treated with Müller's fluid for two days at room-temperature, and then for three weeks in a thermostat at 23° C. During the latter period, the fluid should be changed. The specimen is then washed for forty-eight hours in running water, treated for fourteen days with 80% alcohol, then for eight days with 96% alcohol, decalcified, and further treated as in the preceding method.

335. Up to the present time it has been customary to cut sections in celloidin; but the combined celloidin-paraffin method may also be employed with good results, and even the paraffin method, if great care be exercised in imbedding the tissue.

336. The nerve-fibers and nerve-endings of the cochlea may be stained with the chrome-silver method. For this purpose it is recommended to employ embryos or young fetuses.

## X. THE ORGAN OF SMELL.

THE nasal cavity consists of the vestibule, the respiratory region with the accessory cavities, and the olfactory region.

The **vestibule** is lined by stratified squamous epithelium. In the region of the anterior nares are hairs, the sebaceous glands of which are markedly developed, while at the level of the cartilage mucous glands are also present. The stratified squamous epithelium ceases at the anterior end of the inner turbinate bone and at the inferior nasal duct.

The **respiratory region** possesses a simple pseudostratified, ciliated epithelium having two strata of nuclei and provided with goblet cells; the direction of the ciliate movement is toward the posterior nares. Numerous leucocytes are usually found in the epithelium and in the underlying mucosa. Branched alveolar glands, having mucous and serous alveoli, are here present. Within the mucosa are highly developed vascular plexuses, more especially of a venous character. The *accessory cavities* are likewise lined by ciliated epithelium, the ciliate movement being directed externally.

The **olfactory region** is principally confined to the superior turbinate bone and to the nasal septum lying opposite, although in the immediate vicinity of the olfactory region a few small islands of the same epithelial type are found, either entirely isolated or connected with the principal region by narrow bridges. In a fresh condition the olfactory region may be differentiated from the surrounding tissue by its color, which is distinctly yellow in man. Its pigment is contained within the sustentacular cells described on the next page.

The epithelium of the olfactory region is of the columnar pseudostratified type, with several strata of nuclei, and consequently closely simulates a stratified columnar epithelium. Here we distinguish olfactory cells and sustentacular cells.

The **olfactory cells** occupy a peculiar position among the cells of special sense in that they represent true ganglion cells (von Lenhossék). Within the epithelial layer they appear as spindle-shaped cells, with a spheric nucleus provided with a large nucleolus lying in the thickest portion of each cell. The nuclei of the different cells lie at varying levels in the middle stratum of the epithelial

layer. Toward the nasal cavity, the cells terminate in blunt cones, upon each of which are several stiff hairs, the *olfactory hairs*. The basilar ends form true centripetal nerve-processes, neuraxes, which end in the peculiar telodendria constituting the glomeruli of the olfactory bulb. (See p. 379.)

The nuclei of the sustentacular cells are more oval and are situated at nearly the same level. Toward the surface, each cell is provided with a narrow cuticular zone, while toward the basement membrane, it terminates in two or more pedicles. Between the basilar ends of these cells we find a layer of elements the broad nucleated bodies of which rest on the basement membrane, while their upper extremities terminate in short superficial processes.

The mucosa contains a large number of leucocytes as well as numerous branched alveolar glands, the so-called *glands of Bowman*. In man these are albuminous (serous) glands, and their cells sometimes contain pigment.

Jacobson's organ contains no typical olfactory cells in the human being.

The capillaries spread out immediately beneath the basement membrane of the epithelium. In the submucous connective tissue, we find a relatively well developed vascular plexus, rich in venous vessels; this plexus is especially marked at the posterior portion of the inferior turbinate bone, forming here a tissue which resembles erectile tissue.

A dense network of lymphatics ramifies throughout the mucous membrane, carrying the lymph to the pharynx and palate. These lymph-vessels may be injected through the subarachnoid space (Key and Retzius).

The nerves (trigeminal) are widely distributed in the epithelium, ramifying through both the respiratory and olfactory regions. After repeated divisions these nerves lose their medullary sheaths, and end in telodendria which are usually provided with terminal nodules, although some are found which end in mere filaments.

#### TECHNIC.

337. The nasal mucous membrane is fixed *in situ* with osmic acid or one of its mixtures, after which small pieces are removed. It should be mentioned that the nonmedullated fibers of the olfactory nerve assume a brownish color under this treatment, while the fibers of Remak do not (Ranvier, 89).

338. In order to isolate the epithelial elements, pieces of the mucous membrane are treated with the  $\frac{1}{3}$  alcohol of Ranvier. But since the prolongations of the olfactory cells (neuraxes) shrivel and curl in this fluid, Ranvier recommends that, after the epithelial cells have been macerated in  $\frac{1}{3}$  alcohol for one or two hours, they be treated with 1% osmic acid for a quarter of an hour. If shreds be now placed in water and teased, the cells, together with their prolongations, may be isolated without the curling of the latter.

339. The chrome-silver method applied to the nasal mucous membrane of young animals and fetuses has been the means of establishing the important fact that the olfactory cells of the olfactory region are in reality peripherally situated ganglion cells.

## XI. GENERAL CONSIDERATION OF THE SPECIAL SENSE-ORGANS.

THE special sense-organs present, in their fully developed condition, a very complicated structure, and not until quite recently has it been possible to demonstrate any relationship existing between them, nor has it been possible to reduce them to simple schemata. Within recent years, however, the researches of a number of prominent investigators have enabled us to study all the special sense-organs from a common point of view. As is generally the case, the primitive conditions, both ontogenetic and phylogenetic, have aided materially in the comprehension of structures which later become extremely complicated.

Thus, von Lenhossék (92, 1) has shown that in the earth-worm (*Lumbricus*) certain cells occur between the elements of the single-layered epidermis which functionate as ganglion cells: *i. e.*, possess a basilar centripetal process simulating a neuraxis in its relations to the central nervous system (in this case the funiculus abdominalis); the telodendria of this neuraxis come in contact with the dendrites of the funicular cells by means of terminal ramifications. Here, therefore, we have a peripherally situated ganglion cell which, after receiving an impulse, transmits it to the central organ. This is the simplest structural condition by means of which an external impression may be transmitted to the central organ.

A slight modification of this occurs when the ganglion cell is withdrawn to some extent below the epidermal layer, leaving behind it a peripherally directed process still in contact with the epithelial elements. The external impression is then first taken up by this process, passed to the cell-body, and then to the central organ by means of the neuraxis of the cell. Here the peripheral process of the cell (cellulipetal process) may be compared to a dendrite. This condition prevails in other annelids (*Nereis*).

In the olfactory organ of the higher vertebrates the primitive structure is retained. Thus, in the nasal mucous membrane, the olfactory cells must be regarded as peripheral ganglion cells, since they give off neuraxes the telodendria of which come in contact with the dendritic processes of the mitral cells in the glomeruli olfactorii.

Even if we look upon the epidermal cells of the skin as elements not specially adapted to the reception of an impression, we are still confronted with relations similar to those in *Nereis*, with

the difference that in this case the ganglion cell receiving the impression is removed a long distance from the surface, lying in the spinal ganglion, but possessing a dendrite ramifying within the epidermis.

When the relations are such that the nerve-cell, through its terminations, not only receives the physical impression from without, but also transmits it as a nerve-impulse centripetally, the special sense-organ may be regarded as of the *primary type*. But if certain structures are found in the external epithelium which transmute the physical impression into impulses which are then transmitted, the special sense-organ becomes one which may be looked upon as *secondary* in type. In the latter case the ganglion cell first receiving the impression becomes merely a conducting apparatus, since by means of its dendrites it comes in contact with a cell of special sense, neuro-epithelial cell, developed from an epithelial cell. Such an arrangement exists in the higher organs of special sense, in the organs of taste, hearing, and sight. In the first, the terminal ramifications of the dendrites of the nerve-cells belonging to the glossopharyngeal nerve come in contact with the special sense cells, the gustatory cells, in the taste-buds. In the cochlea, as also in the ampullæ, it may be assumed that the dendrites from the auditory ganglion encircle the auditory cells (cells of special sense). In other words, the cells of the glossopharyngeal and auditory ganglia conduct the respective impressions to centrally placed neurones.

Some difficulty is encountered in considering the retina; this may be best overcome by regarding the visual cells as the cells of special sense which receive the impression, and the bipolar cells of the inner granular layer as the conducting elements. The cells of the nerve-cell layer of the retina may, therefore, be regarded as the cells lying nearest to the central organ (compare Retzius, 92, 2).



## REFERENCES TO LITERATURE.

The following list includes the titles of articles and works referred to in the text. Authors' names, arranged in alphabetic order, are followed by the date of publication of the works referred to, the two last figures of the year of publication alone being given. If reference has been made to more than one of an author's publications appearing in the same year, the date is followed by a single number to designate this fact. In this respect we follow Minot, 94. The abbreviation of titles of journals here followed is the same as that in use in the "Zoologischen Jahresbericht."

- Affanassiew, M., 84**, Ueber den dritten Formbestandtheil des Blutes in normalen und pathologischen Zustand, u.s.w., in Arb. Med.-Klin. Inst. Univers. München., Bd. I, 2. Heft, S. 556-592, T. 15.
- Altmann, R., 79**, Ueber die Verwerthbarkeit der Corrosion in der mikroskopischen Anatomie, in Arch. mikr. Anat., Bd. XVI, S. 471-507, T. 21-23.
- **92**, Ein Beitrag zur Granulalehre, in Verh. Anat. Ges., 6. Vers., S. 220-223.
- **94**, Die Elementarorganismen und ihre Beziehungen zu den Zellen, S. 1-160, 9 Fig. und 35 T., 2. Aufl., Leipzig.
- Andres, A., W. Giesbrecht, und P. Mayer, 83**, Neuerungen in der Schneidetechnik, in Mitth. Z. Station Neapel, Bd. IV, S. 229-236, 2 Fig.
- Apáthy, Stefan, 86-87**, Methode zur Verfertigung längerer Schnittserien mit Celloidin, in *ibid.*, Bd. VII, S. 742-748.
- **97**, Das leitende Element des Nervensystems und seine Beziehungen zu den Zellen, 1. Mitth. in Mitth. Zool. Station Neapel, Bd. XII, S. 495-748, T. 23-32.
- Arnold, Julius, 83**, Beobachtungen über Keim- und Kernteilungen in den Zellen des Knochenmarkes, in Arch. path. Anat., Bd. XLIII, S. 1.
- **87**, Ueber Theilungsvorgänge an den Wanderzellen, ihre progressiven und regressiven Metamorphosen, in Arch. mikr. Anat., Bd. XXX, S. 205-310, T. 12-16.
- **96**, Zur Morphologie und Biologie der rothen Blutkörperchen, in Arch. path. Anat., Bd. CXLV, S. 1-29, T. 1-2.
- Arnstein, 95**, Zur Morphologie der sekretorischen Nervenendapparate, Anat. Anzeig., Bd. X, S. 410.
- Auerbach, L., 90**, Ueber die Blutkörperchen der Batrachier, in Anat. Anzeiger., 5. Jahrg., S. 570-578, 2 Fig.
- Balfour, F. M.** Vergl. Foster.
- Ballowitz, E., 88**, Untersuchungen über die Struktur der Spermatozoen, zugleich ein Beitrag zur Lehre vom feineren Bau der contractilen Elemente, Theil I; Die Spermatozoen der Vögel, in Arch. mikr. Anat., Bd. XXXII, S. 402-473, T. 14-18.
- **90, 1**, Das Retzius'sche Endstück der Säugethier-Spermatozoen, in Internat. Monatsschr. Anat. Phys., Bd. VII, S. 211-223, T. 11.
- **90, 2**, Untersuchungen über die Struktur der Spermatozoen, 3. Fische, Amphibien, und Reptilien, in Arch. mikr. Anat., Bd. XXXVI, S. 225-290, T. 11, 12.
- **91**, Weitere Beobachtungen über den feineren Bau der Säugethier-Spermatozoen, in Zeit. Wiss. Z., Bd. LII, S. 217-293, T. 13-15.

- Bardeleben**, Karl von, und **Haeckel**, Heinrich, **94**, Atlas der topographischen Anatomie des Menschen, 128 T., Jena.
- Barfurth**, D., **91**, Ueber Zellbrücken glatter Muskelfasern, in Arch. mikr. Anat., Bd. xxxviii, S. 38–51, T. 3.
- **96**, Zelllücken und Zellbrücken im Uterusepithel nach der Geburt, in Verh. Anat. Ges., 10. Vers., S. 23–26.
- Barlow**, Richard, **95**, Mittheilungen über Reduktion der Ueberosmiumsäure durch das Pigment der menschlichen Haut, in Bibliotheca med., Abth. D. II, Dermatol. und Syphilis, H. 5, S. 10, T. 1, 2.
- Benda**, C., **87**, Untersuchungen über den Bau des funktionirenden Samenkanälchens einiger Säugethiere und Folgerungen für die Spermatogenese dieser Wirbelthierklasse, in Arch. mikr. Anat., Bd. xxx, S. 49–110, T. 5–7.
- Beneden**, Ed. van, **83**, Recherches sur la maturation de l'oeuf et la fécondation, in Arch. Biol., Tome IV, pp. 265–758, T. 10–19.
- and A. **Neyt**, **87**, Nouvelles recherches sur la fécondation et la division mitotique chez l'Ascaride mégalocéphale, in Bull. Acad. Belg. (3), Tome XIV, pp. 214–295, T. 1–6.
- Bergh**, R. S., **94**, Vorlesungen über die Zelle und die einfachen Gewebe des thierischen Körpers, S. x und 1–262, 138 Fig., Wiesbaden.
- Berkley**, Henry J., **93**, **1**, The Nerves and Nerve-endings of the Mucous Layer of the Ileum, Shown by the Rapid Golgi Method, in Anat. Anzeiger, 8. Jahrg., S. 12–19, 4 Fig.
- **93**, **2**, Studies in the Histology of the Liver, in Anat. Anzeiger, 8. Jahrg., S. 769–792, 22 Fig.
- **94**, The Intrinsic Pulmonary Nerves in Mammalia, Johns Hopkins Hospital Reports, vol. IV, No. 4, 5. Report on Neurology, II.
- **94**, The Intrinsic Nerves of the Thyroid Gland of the Dog, *ibid.*
- **94**, The Nerve Elements of the Pituitary Gland, *ibid.*
- Berten**, J., **95**, Hypoplasie des Schmelzes, in D. Monatsschr. Zahnheilkunde, 13. Jahrg., S. 425–439, 533–548, 587–600, T. 3.
- Bethe**, Albrecht, **95**, Studien über das Centralnervensystem von *Carcinus Mænas*, nebst Angaben über ein neues Verfahren der Methylenblaufixation, in Arch. mikr. Anat., Bd. XLIV, S. 579–622.
- **96**, Eine neue Methode der Methylenblaufixation, in Anat. Anzeiger, Bd. XII, S. 438–446.
- **98**, Ueber die Primitivfibrillen in den Ganglienzellen vom Menschen und anderen Wirbelthieren, Morphol. Arb., Jena, Bd. VIII, S. 95–116.
- **1900**, Das Molybdänverfahren zur Darstellung der Neurofibrillen und Golginetze im Centralnervensystem, Zeitsch. f. Wis. Mik., Bd. XVII, S. 13–35.
- Bethe**, Martin, **91**, Beiträge zur Kenntniss der Zahl- und Maassverhältnisse der rothen Blutkörperchen, in Morph. Arb., Schwalbe, Bd. 1, S. 207–240, 2 T.
- Bidder**, Alfred, **77**, Experimentelle Beiträge und anatomische Untersuchungen zur Lehre von der Regeneration des Knochengewebes, u.s.w., in Archiv für klinische Chirurgie, Bd. XXII, S. 1–62, T. 1.
- Bidder**, F., und C. **Kupffer**, **57**, Untersuchungen über die Textur des Rückenmarkes, S. x und 1–122, 5 T., Leipzig.
- Biondi**, D., **85**, Die Entwicklung der Spermatozoiden, in Arch. mikr. Anat., Bd. xxv, S. 594–620, T. 26, 27, 1 Fig.
- Bizzozero**, G., **68**, Sulla funzione ematopoetica dell midollo delle ossa, Gazzette med. Ital. Lomb., N. 48.
- **82**, Ueber einen neuen Formbestandtheil des Blutes und dessen Rolle bei der Thrombose und der Blutgerinnung, in Arch. Path., Virchow, Bd. xc, S. 261–332, 1 T.

- Bizzozero, G., 84**, Sur les plaquettes du Sang des Mammifères, Gazzette degli ospedali, Ciurt in Arch. Biol. Ital., Tome XVI, pp. 375-392, 1891.
- **89**, Ueber die schlauchförmigen Drüsen des Magendarmkanals und die Beziehungen ihres Epithels zu dem Oberflächenepithel der Schleimhaut, 1. Mitth. in Arch. mikr. Anat., Bd. XXXIII, S. 216-246, T. 14.
- **91**, Nouvelles recherches sur la moëlle des os chez les oiseaux, in Arch. Ital. Biol., Tome XVI, pp. 293-332, Pl.
- **92, 1**, Ueber die schlauchförmigen Drüsen des Magendarmkanals und die Beziehungen ihres Epithels zu dem Oberflächenepithel der Schleimhaut, 2. Mitth. in Arch. mikr. Anat., Bd. XL, S. 325-375, T. 18, 19.
- **92, 2**, Ueber die Blutplättchen, in Internat. Beitr. Wiss. Med., Bd. 1, S. 457-477; also in Arch. Ital. Biol., Tome XVI, pp. 375-392.
- Böhm, A., und A. Oppel, 96**, Taschenbuch der mikroskopischen Technik, 3. Aufl., S. 1-IV und 1-224, 1 Fig., München.
- Bonnet, R., 78**, Studien über die Innervation der Haarbälge der Hausthiere, in Morph. Jahrb., Bd. IV, S. 329-398, T. 17-19.
- **95**, Ueber "Schlussleisten" der Epithelien, in D. med. Wochenschr., 1895.
- **96**, Ueber den Bau der Arterienwand, in D. med. Wochenschr., Nr. 1.
- Born, G., 94**, Die Struktur des Keimbläschens im Ovarialei von *Triton teniatus*, in Arch. mikr. Anat., Bd. XLIII, S. 1-79, T. 1-4.
- Boveri, Th., 85**, Beiträge zur Kenntniss der Nervenfasern, in Abh. Akad. München, Bd. XV, S. 421-495, 2 T.
- **87, 1**, Ueber die Befruchtung der Eier von *Ascaris megalcephala*, in Sitz.-Ber. Ges. Morph. Phys., München, Bd. III, S. 71-80.
- **87, 2-88**, Zellenstudien, in Jena. Zeit. Naturw., Bd. XXI, S. 423 515, T. 25-28, und Bd. XXII, S. 685-882, T. 19-23.
- **88**, Die Vorgänge der Befruchtung und Zelltheilung in ihrer Beziehung zur Vererbungsfrage, in Verh. Anthropol. Ges., München, 30. November, S. 13 (Separatum), T. 13, 14.
- **96**, Ueber das Verhalten der Centrosomen bei der Befruchtung des Seeigel-Eies nebst allgemeinen Bemerkungen über Centrosomen und Verwandtes, in Verh. Physik. Med. Ges., Würzburg, N. F., Bd. XXIX, S. 1-75, 1 Fig.
- Brauer, August, 93**, Zur Kenntniss der Spermatogenese von *Ascaris megalcephala*, in Arch. mikr. Anat., Bd. XLII, S. 153-213, T. 12, 13.
- Brown, Robert, 29**, Mikroskopische Beobachtungen, u. s. w., aus dem Englischen übersetzt von Beilschmied, Nürnberg.
- Brunn, A. v., 84**, Beiträge zur Kenntniss der Samenkörper und ihrer Entwicklung bei Säugethieren und Vögeln, in Arch. mikr. Anat., Bd. XXIII, S. 108-132, T. 7 A.
- **92**, Beiträge zur mikroskopischen Anatomie der menschlichen Nasenhöhle, in Arch. mikr. Anat., Bd. XXXIX, S. 632-651, T. 29, 30.
- Budge, A., 77**, Die Saftbahnen im hyalinen Knorpel, in Arch. mikr. Anat., Bd. XIV, S. 65-73, T. 5 B.
- **79**, Weitere Mittheilungen über die Saftbahnen im hyalinen Knorpel, in *ibid.*, Bd. XVI, S. 1-15, T. 1.
- Bühler, A., 94**, Beiträge zur Kenntniss der Eibildung beim Kaninchen und der Markstränge des Eierstockes beim Fuchs und Menschen, in Zeit. Wiss. Z., Bd. LVIII, S. 314-339, T. 18, 19.
- Büngner, Otto v., 91**, Ueber die Degenerations- und Regenerationsvorgänge am Nerven nach Verletzungen, in Beitr. path. Anat., Ziegler, Bd. X, S. 321-393, T. 16, 17.
- Bütschli, O., 92**, Untersuchungen über mikroskopische Schäume und das Protoplasma, Versuche und Beobachtungen zur Lösung der Frage nach den physikalischen Be-

- dingungen der Lebenserscheinungen, 234 Sn., 23 Fig., 6 T., Separat-Atlas von 19 Mikrophotographien, Leipzig.
- Carrière, J.**, 82, Kurze Mittheilungen zur Kenntniss der Herbst'schen und Grandry'schen Körperchen in dem Schnabel der Ente, in Arch. mikr. Anat., Bd. XXI, S. 146-164, T. 6.
- Ciacio, 90**, Sur les plaques nerveuses finales dans les tendons des vertébrés, Archives Ital. de Biologie, Tome XIV, p. 31.
- Clark, J. G.**, 99, Origin, Development, and Degeneration of the Blood-vessels of the Ovary, Bul. Johns Hopkins Hosp., vol. X, pp. 40-44.
- Cohnheim, J.**, 65, Ueber den feineren Bau der quergestreiften Muskelfaser, in Arch. Path., Virchow, Bd. XXXIV, S. 606-622, T. 14.
- 67, 1, Ueber Entzündung und Eiterung, in *ibid.*, Bd. XL, S. 1-79.
- 67, 2, Ueber die Endigungen der sensiblen Nerven in der Hornhaut, in Arch. Path., Virchow, Bd. XXXVIII, S. 343-386, 2 T.
- Councilman, W. T.**, 99, The Lobule of the Lung, and its Relation to the Lymphatics, Jour. Boston Soc. of Med. Sciences, vol. IV, p. 165.
- Cox, W. H.**, 91, Imprägnation des centralen Nervensystems mit Quecksilbersalzen, in Arch. mikr. Anat., Bd. XXXVII, S. 16-21, T. 2.
- Daddi, Lamberto**, 96, Nouvelle méthode pour colorer la graisse dans les tissus, Arch. Ital. Biol., Tome XXVI, pp. 142-146.
- Davidoff, M.** von, 87, Untersuchungen über Beziehungen des Darmepithels zum lymphoiden Gewebe, in Arch. mikr. Anat., Bd. XXIX, S. 495-525, T. 30, 31.
- Deiters, Otto**, 65, Untersuchung über Gehirn und Rückenmark des Menschen und der Säugethiere, Nach dem Tode des Verf.'s herausgegeben von Max Schultze, S. XX und 1-318, 6 T., Braunschweig.
- Dekhuyzen, M. Č.**, 91, Ueber Emigration und Leukocyten, in Verh. Anat. Ges., 5. Vers., München, S. 231-241.
- Demoor, Jean**, 93, Contribution à l'étude de la physiologie de la cellule (indépendance fonctionnelle du protoplasme et du noyau), in Arch. Biol., Tome XIII, pp. 163-244, Pl. 9, 10.
- Demoor, L.**, 93, Recherches sur la structure du Tissu réticulé, Arch. Biol., Tome XIII, pp. 1-40, Pl. 1, 2.
- Dippel, L.**, 82, Das Mikroskop und seine Anwendung, 1. Th., Handb. allg. Mikroskopie, 2. Aufl., Braunschweig.
- Disse, J.**, 92, Ueber die Veränderungen der Nierenepithelien bei der Sekretion, in Anat. Hefte, 1. Abth., Bd. II, S. 141-171, T. 10.
- Dogiel, Alexander**, 85, Ueber die Drüsen der Regio olfactoria, in Arch. mikr. Anat., Bd. XXVI, 50-60, T. 3.
- Dogiel, A. S.**, 91, Die Nervenendkörperchen in der Cornea und Conjunctiva bulbi des Menschen, Arch. f. mikr. Anat., Bd. XXXVII, S. 602.
- 92, Die Nervenendigungen in Meissner'schen Tastkörperchen, Internat. Monats. f. Anat. und Phys., Bd. IX, S. 76.
- 93, Die Nervenendigungen in der Haut der äusseren Genitalorgane des Menschen, Arch. f. mikr. Anat., Bd. XL, S. 585.
- 95, Zur Frage über die Ganglien der Darmgeflechte bei den Säugethieren, Anat. Anzeig., Bd. X, S. 516.
- 95, Zur Frage über den feineren Bau des sympathischen Nervensystems bei den Säugethieren, Arch. f. mikr. Anat., Bd. XLVI, S. 305.
- 96, Zwei Arten sympathischer Nervenzellen, Anat. Anzeiger, Bd. XI, S. 679.
- 97, Zur Frage über den feineren Bau der Spinalganglien und deren Zellen bei Säugethieren, Internat. Monat. f. Anat. u. Phys., Bd. XIV, S. 73.
- 97, Die Nerven der Lymphgefäße, Archiv mikr. Anat., Bd. XLIX, S. 791.

- Dogiel**, A. S., **98**, Zur Frage über den feineren Bau der Herzganglien des Menschen und der Säugethiere, *Archiv f. mikr. Anat.*, Bd. LIII, S. 237.
- **98**, Die sensiblen Nervenendigungen im Herzen und in den Blutgefäßen der Säugethiere, *Archiv f. mikr. Anat.*, Bd. LII, S. 44.
- **99**, Ueber den Bau der Ganglien in den Geflechten des Darmes und der Gallenblase des Menschen und der Säugethiere, *Archiv f. Anat. und Phys.*, 1899.
- Eberth**, C. J., **71, 1**, Die Nebennieren, in *Handb. Lehre von den Geweben*, Stricker, S. 505–516, 10 Fig., Leipzig.
- **71, 2**, Von den Blutgefäßen, in *ibid.*, S. 191–213, 13 Fig.
- Ebner**, V. von, **72**, Ueber die Anfänge der Speichelgänge in den Alveolen der Speicheldrüsen, in *Arch. mikr. Anat.*, Bd. VIII, S. 481–513, T. 20.
- **75**, Ueber den feineren Bau der Knochensubstanz, in *Sitz.-Ber. Akad. Wien*, Bd. LXXII, 3. Abth., S. 1–90, T. 1–4.
- **88**, Zur Spermatogenese bei den Säugethieren, in *Arch. mikr. Anat.*, Bd. XXXI, S. 236–292, T. 15–18.
- **91**, Histologie mit Einschluss der Histogenese, in *Handb. Zahnheilkunde*, von J. Scheff, Jr., Bd. I, S. 209–262, Fig. 85–107, Wien.
- **97**, Ueber die Spitzen der Geschmacksknospen, in *Sitz.-Ber. Akad. Wien*, 3. Abth., Bd. CVI, S. 73–82, 1 T.
- Ehrlich**, P., **91**, Farbenanalytische Untersuchungen zur Histologie und Klinik des Blutes, 1. Theil, S. IV und 1–137. (Enthält gesammelte Abhandlungen von ihm und Arbeiten seiner Schüler, Westphal, Spilling, Schwarze.)
- Eichler**, Oswald, **94**, Die Wege des Blutstromes durch den Vorhof und die Bogengänge des Menschen, in *Ahh. math.-phys. Cl. Sächs. Ges. Wiss.*, Bd. XXI, 8 Sn., T. 1.
- Enderlen**, Eugen, **91**, Fasern im Knochenmarke, in *Anat. Anzeiger*, 6. Jahrg., S. 489 und 490, 2 Fig.
- Ewald**, A., und W. Kühne, **74**, Die Verdauung als histologische Methode, in *Verh. Naturhist. Ver., Heidelberg (N. F.)*, Bd. I, S. 451–456.
- Exner**, Sigm., **97**, Mittheilung über Beitrag zur Entwicklungsgeschichte der Corti'schen Membran, von Ignaz Czinner und Viktor Hammerschlag, in *Sitz.-Ber. Akad. Wien*, Abth. 2a, Heft. 3 und 4, S. 183 und 184.
- Felix**, Walther, **89**, Ueber Wachstum der quergestreiften Muskulatur nach Beobachtungen am Menschen, in *Zeit. Wiss. Z.*, Bd. XLVIII, S. 224–258, T. 15, 16.
- Fick**, R., **93**, Ueber die Reifung und Befruchtung des Axolotleies, in *Zeit. Wiss. Z.*, Bd. LVI, S. 529–614, T. 27–30.
- Fischer**, Alfred, **94**, Zur Kritik der Fixirungsmethoden und der Granula, in *Anat. Anzeiger*, Bd. IX, S. 678–680.
- Fischer**, E., **76**, Eosin als Tinktionsmittel für mikroskopische Präparate, in *Arch. mikr. Anat.*, Bd. XII, S. 349–352.
- Fleischl**, E., **74**, Ueber die Beschaffenheit des Achsencylinders, in *Beiträge Anat. u. Phys.*, Festgabe für Karl Ludwig, S. 51–55, 1 T., Leipzig.
- Flemming**, W., **82**, Zellsuhstanz, Kern und Zelltheilung, S. VIII und 1–424, 24 Fig. und 8 T., Leipzig.
- **84**, Mittheilungen zur Färbetechnik, in *Zeitschr. Wiss. Mikroskopie*, Bd. I, S. 349–361.
- **85, 1**, Ueber die Bildung von Richtungsfiguren in Säugethiereiern beim Untergang Graaf'scher Follikel, in *Arch. Anat. u. Phys.*, Anat. Abth., S. 221–244, T. 10, 11.
- **85, 2**, Studien über Regeneration der Gewebe, in *Arch. mikr. Anat.*, Bd. XXIV, S. 50–91, T. 4.
- W., **87**, Neue Beiträge zur Kenntniss der Zellen, in *ibid.*, Bd. XXIX, S. 389–463, T. 23–26.

- Flemming**, W., 88, Weitere Beobachtungen über die Entwicklung der Spermatozoen bei *Salamandra maculosa*, in *ibid.*, xxxi, S. 71-97, T. 7.
- 89, 1, Ueber die Löslichkeit osmirten Fettes und Myelins in Terpentinöl, in Zeitschr. Wiss. Mikroskopie, Bd. vi, S. 39, 40.
- 89, 2, Weiteres über die Entfärbung osmirten Fettes in Terpentin und anderen Substanzen, *ibid.*, 178-181.
- 91, 1, Neue Beiträge zur Kenntniss der Zelle, 2. Theil, in Arch. mikr. Anat., Bd. xxxvii, S. 685-751, T. 38-40.
- 91, 2, Zur Entwicklungsgeschichte der Bindegewebsfibrillen, in Internat. Beitr. wiss. Med., Bd. I, S. 213-222, T. 9.
- 91, 3, Ueber Theilung und Kernformen bei Leukocyten und über deren Attraktionssphären, in Arch. mikr. Anat., Bd. xxxvii, S. 249-298, T. 13, 14.
- 95, Zur Färbung mit sehr verdünntem Hämatoxylin, in Anat. Anzeiger, Bd. xi, S. 504.
- 98, Ueber die Chromosomenzahl beim Menschen, Anat. Anzeiger, Bd. xiv, S. 171.
- Flesch**, Max, 80, Untersuchungen über die Grundsubstanz des hyalinen Knorpels, S. 1-102, 5 T., Würzburg.
- Flint**, J. M., 1900, The Blood-vessels, Angiogenesis, Organogenesis, Reticulum, and Histology of the Adrenal, Contributions to the Science of Medicine, pp. 153-228, Johns Hopkins Press, 1900.
- Fol**, Hermann, 84, Lehrbuch der vergleichenden mikroskopischen Anatomie, u. s. w., I. Lief; Die mikroskopisch-anatomische Technik, S. 1-208, 84 Fig. (2. Lief, S. 209-452, 136 Fig., ist von M. Bedot, 96, herausgegeben.) Leipzig.
- Foster**, M., und F. M. **Balfour**, 74, The Elements of Embryology, London, I. Theil (Hühnchen), Deutsch von N. Kleinenberg, 267 Sn., 71 Fig., Leipzig, 1876.
- Föttinger**, Alex., 80, Sur les terminaisons des nerfs dans les insectes, Arch. Biol., Tome I, pp. 279-304, T. 10.
- Frommel**, R., 86, Beitrag zur Histologie der Eileiter, in Münchener med. Wochenschr., 33. Jahrg., Nr. 26.
- Fürbringer**, Max, 77, Ueber das Gewebe des Kopfkorpels der Cephalopoden, in Morph. Jahrb., Bd. III, S. 653-658, 1 Fig.
- Fusari**, R., 91, De la terminaison des fibres nerveuses, dans les capsules surrenales des Mammifères, in Arch. Ital. Biol., Tome xvi, pp. 262-275, 1 Pl.
- Gad**, J., 95, Ueber eine leichte and sichere Methode (von Chr. Sihler) die Nervenendigung an Muskelfasern und Gefässen nachzuweisen, Verh. Phys. Ges., Berlin, in Arch. Anat. u. Phys., Phys. Abth., S. 202-208.
- Gardner**, M., 97, Zur Frage über die Histogenese des elastischen Gewebes, in Biol. Centralbl., Bd. xvii, S. 394-418.
- Gaule**, J., 81, Das Flimmerepithel der *Aricia fatida*, in Arch. Anat. u. Phys., Phys. Abth., S. 153-159, 1 T.
- Gawronski**, N. von, 94, Ueber Verbreitung und Endigung der Nerven in den weiblichen Genitalien, Vorläufige Mittheilung, in Centralbl. Gynäk., Nr. 11.
- Geberg**, A., 85, Ueber direkte Anastomosen zwischen den Arterien und Venen in der Nierenkapsel, in Internat. Monatsschr. Anat. Hist., Bd. II, S. 223-229, T. 13, 14. (Die Tafelerklärung bezieht sich fälschlich auf: T. 15 und die T. 13 und 14 tragen die Nummern des I. Bandes der Zeitschrift.)
- Gegenbaur**, C., 64, Ueber die Bildung des Knochengewebes, in Jena. Zeitschr. Naturw., Bd. I, S. 363-369, 1 T.
- 67, Ueber die Bildung des Knochengewebes, in *ibid.*, Bd. III, S. 206-246, 2 T.
- Gehuchten**, A. van, 93, Les terminaisons nerveuses intra-épidermiques chez quelques mammifères, in La Cellule, Tome ix, pp. 301-331, 2 Pl.

- Gehuchten**, A. van, **97**, Le Système nerveux de l'homme, pp. xxvi und 941, 619 Fig., Louvain (2. Auflage).
- Gensch**, H., **81**, Die Blutbildung auf dem Dottersack bei Knochenfischen, in Arch. mikr. Anat., Bd. xix, S. 144-146.
- Gerlach**, J., **58**, Mikroskopische Studien aus dem Gebiete der menschlichen Morphologie, S. vi und 1-72, 8 T., Erlangen.
- **71, 72**, Von dem Rückenmark, in Handbuch, Lehre von den Geweben, Stricker, S. 665-693, Fig. 217-229, Leipzig.
- Gerota**, D., **96**, Ueber Lymphscheiden des Auerbach'schen Plexus myentericus der Darmwand, in Sitz-Ber. Akad. Berlin, S. 887 und 888.
- Gibbes**, Heneage, **80**, On the Structure of the Spermatozoon, in Quart. Journ. Micr. Sc. (N. S.), Nr. 63, pp. 320, 321, 1 Fig.
- Giesbrecht**, W. Vergl. Andres.
- Golgi**, Camillo, **89**, Annotazioni intorno all' istologia dei reni dell' uomo e di altri mammiferi e sull' istogenesi dei canalicoli uriniferi, in Atti. Accad. Lincei Rend. (4) vol. v, sem. 1, pp. 324-342, 3 Fig.
- **93**, Sur la fine organisation des glandes peptiques des Mammifères, in Arch. Ital. Biol., Tome xix, pp. 448-453, 7 Fig., auch in Gazz. Med. Pavia, Anno 2, pp. 241, 247.
- **94**, Untersuchungen über den feineren Bau des centralen und peripherischen Nervensystems, S. 1-272, 30 T., Deutsch v. R. Teuscher, Jena (enthält sämtliche Untersuchungen Golgi's über das obige Thema seit 1871).
- Golubew**, W. Z., **93**, Ueber die Blutgefäße in der Niere der Säugethiere und des Menschen, in Internat. Monatsschr. Anat. u. Phys., Bd. x, S. 541-598, T. 22-24.
- Göppert**, E., **94**, Ueber die Herkunft des Wisberg'schen Knorpels, Ein Beitrag zur vergleichenden Anatomie des Säugethierkehlkopfes, in Morph. Jahrb., Bd. xxi, S. 68-151, T. 3 und 4, 13 Textfig.
- Götte**, Alexander, **68**, Zur Morphologie der Haare, in Arch. mikr. Anat., Bd. iv, S. 273-322, T. 19, 20.
- Gottschau**, M., **83**, Struktur und embryonale Entwicklung der Nebennieren bei Säugethiern, in Arch. Anat. u. Phys., Anat. Abth., S. 412-458, 2 T.
- Grenacher**, M., **79**, Einige Notizen zur Tinktionstechnik, besonders zur Kernfärbung, in Arch. mikr. Anat., Bd. xvi, S. 463-471.
- Grünstein**, **99**, Zur Innervation der Harnblase, Arch. mikr. Anat., Bd. lv.
- Gscheidlen**, Richard, **76-79**, Physiologische Methodik, Ein Handbuch der praktischen Physiologie, Braunschweig, S. 1-640, 462 Fig. (nicht vollendet).
- Haeckel**, Heinrich, **94**. Vergl. Bardeleben.
- Halliburton**, W. D., **93**, Lehrbuch der chemischen Physiologie und Pathologie, S. xii und 1-883, 104 Fig., Deutsch von K. Kaiser, Heidelberg.
- Hamburger**, Ove, **90**, Ueber die Entwicklung der Säugethierniere, in Arch. Anat. u. Phys., Anat. Abth., Suppl. Bd., S. 15-51, T. 3, 4.
- Hammer**, Bernh., **91**, Ueber das Verhalten von Kerntheilungsfiguren in der menschlichen Leiche, Inaug.-Diss., Berlin, 39 Sn.
- Harz**, W., **83**, Beiträge zur Histologie des Ovariums der Säugethiere, in Arch. mikr. Anat., Bd. xxii, S. 374-407, T. 15.
- Hayem**, Georges, **89**, Du sang et de ses altérations anatomiques, pp. xxxvi und 1-1035, 126 Fig., Paris.
- Heidenhain**, M., **92, 1**, Ueber die Riesenzellen des Knochenmarkes und ihre Centrakörper, in Sitz-Ber. Physik.-Med. Ges., Würzburg, S. 130-133.
- **92, 2**, Ueber Kern und Protoplasma, in Festschr., Kölliker, Leipzig, S. 109-166, T. 9-11.

- Heidenhain, M.**, 94, Neue Untersuchungen über die Centralkörper und ihre Beziehungen zum Kern- und Zellprotoplasma, in Arch. mikr. Anat., Bd. XLIII, 423-758, T. 26-31.
- 96, Noch einmal über die Darstellung der Centralkörper durch Eisenhämatoxylin nebst einigen allgemeinen Bemerkungen über die Hämatoxylinfarben, in Zeitschr. Wiss. Mikroskopie, Bd. XIII, S. 186-199.
- Heidenhain, R.**, 69, 70, Untersuchungen über den Bau der Labdrüsen, in Arch. mikr. Anat., Bd. VI, S. 368-406, T. 20, 21, 1870; auch in Sitz.-Ber. Schles. Ges. Vaterl. Kultur, 29. Febr. und 19. Nov., 1869.
- 83, Physiologie der Absonderungsvorgänge, in Hermann, Handb. Physiologie, Bd. v, Th. 1, S. 1-420, 88 Fig., Leipzig.
- 86, Eine Abänderung der Färbung mit Hämatoxylin und chromsauren Salzen, in Arch. mikr. Anat., Bd. XXVII, S. 383 und 384.
- 88, Beiträge zur Histologie und Physiologie der Dünndarmschleimhaut, in Arch. Phys., Pflüger, Bd. XLIII, Suppl., 103 Sn., 4 T.
- Held, Hans**, 97, Beiträge zur Struktur der Nervenzellen und ihrer Fortsätze, in Arch. Anat. u. Phys., Anat. Abth., S. 204-297, T. 9-12.
- Hensen, V.**, 64, Die Entwicklung des Nervensystems, in Arch. Path., Virchow, Bd. xxx, S. 176-186, 1 T.
- 76, Beobachtungen über die Befruchtung und Entwicklung des Kaninchens und Meerschweinchens, in Zeitschr. Anat. Entwicklungsgesch., Bd. 1, S. 213-273, T. 8, 9, und *ibid.*, S. 353-423, T. 10-12.
- Hering, Ewald**, 71, Von der Leber, in Handh. Lehre von den Geweben, Stricker, S. 429-452, 6 Fig., Leipzig.
- Hermann, Friedrich**, 85, Beitrag zur Entwicklungsgeschichte des Geschmacksorgans des Kaninchens, in Arch. mikr. Anat., Bd. XXIV, S. 216-229, T. 13.
- 88, Studien über den feineren Bau des Geschmacksorgans, in Sitz.-Ber. Acad. München, S. 277-318, 2 T.
- 89, 1, Beiträge zur Histologie des Hodens, in Arch. mikr. Anat., Bd. XXXIV, S. 8-106, T. 3, 4.
- 89, 2, Die postfötale Histiogenese des Hodens der Maus, in *ibid.*, XXXIV, S. 429-437, T. 26.
- 91, Beitrag zur Lehre von der Entstehung der karyokinetischen Spindel, in *ibid.*, Bd. XXXVII, S. 569-586, 2 Fig., T. 31.
- 93, 1, Urogenitalsystem, in Ergebnisse von F. Merkel und R. Bonnet, Bd. II, Abth. 2, S. 201-227, 1 T.
- 93, 2, Technik. Methoden zum Studium des Archiplasmas und der Centrosomen thierischer und pflanzlicher Zellen, in *ibid.*, Bd. II, Abth. 2, S. 23-36.
- 97, Beiträge zur Kenntniss der Spermatogenese, in Arch. mikr. Anat., Bd. L, S. 276-315, T. 17.
- Hertwig, O.**, 77, 78, Beiträge zur Kenntniss der Bildung, Befruchtung, und Theilung des thierischen Eies, in Morph. Jahrb., Bd. III, S. 1-86, T. 1-5, und *ibid.*, Bd. IV, S. 156-213, T. 6-11.
- 90, Vergleich der Ei- und Samenbildung bei Nematoden, Eine Grundlage für celluläre Streitfragen, in Arch. mikr. Anat., Bd. XXXVI, S. 1-138, T. 1-4.
- 93, Die Zelle und die Gewebe, Grundzüge der allgemeinen Anatomie und Physiologie, S. XII und 1-296, 168 Fig.
- 96, Lehrbuch der Entwicklungsgeschichte des Menschen und der Wirbelthiere, S. XVI und 612, 384 Fig. und 2 T., 5. Auflage, Jena, Fischer.
- Hertwig, O. und R.**, 81, Die Coelomtheorie, Versuch einer Erklärung des mittleren Keimblattes, in Jena. Zeitschr. Naturw., Bd. XV, S. 1-150, T. 1-3.

- His**, W., **61**, Untersuchungen über den Bau der Lymphdrüsen, in Zeitschr. Wiss. Z., Bd. XI, 24 Sn., T. 8, 9.
- **80**, Abbildungen über das Gefässsystem der menschlichen Netzhaut und derjenigen des Kaninchens, in Arch. Anat. u. Phys., Anat. Abth., S. 224–231, T. 7, 8.
- **86**, Zur Geschichte des menschlichen Rückenmarks und der Nervenwurzeln, in Abh. Sächs. Ges. Wiss. (Math. physische Klasse), Bd. XIII, S. 479–514, 10 Fig., 1 T.
- **87**, Die Entwicklung der ersten Nervenbahnen beim menschlichen Embryo, übersichtliche Darstellung, in Arch. Anat. u. Phys., Anat. Abth., S. 368–392, 27 Fig., 2 T.
- **89**, Die Neuroblasten und deren Entstehung im embryonalen Mark, in Arch. Anat. u. Phys., Anat. Abth., S. 249–300, T. 16–19; auch in Abh. Sächs. Akad. Wiss., Bd. XXVI, S. 311–372, T. 1–4.
- Hoffman**, C. K., **92**, Etude sur le développement de l'appareil urogénital des oiseaux, in Verh. Akad. Amsterdam, (2) I. Deel, Nr. 4, 54 Sn., 7 T.
- **93, 1**, Zur Entwicklungsgeschichte des Herzens und der Blutgefässe bei den Sela-  
chiern, Ein Beitrag zur Kenntniss des unteren Keimblattes, in Morph. Jahrb., Bd. XIX, S. 592–648, T. 22–25, 6 Fig.
- **93, 2**, Untersuchungen über den Ursprung des Blutes und die blutbereitenden Organe, in Verh. Akad. Amsterdam, (2) 3. Deel, Nr. 4, 26 Sn., 4 T.
- Hofmeyer**, M., **93**, Zur Kenntniss der normalen Uterusschleimhaut, in Centralbl. Gynæk., S. 764–766.
- Hoppe-Seyler**, Felix, **93**, Handbuch der physiologisch- und pathologisch-chemischen Analyse, S. VIII und I–548, 15 Fig., 6. Aufl., Berlin.
- Hoyer**, H., **77**, Ueber unmittelbare Einmündung kleinster Arterien in Gefässäste venösen Charakters, in Arch. mikr. Anat., Bd. XIII, S. 603–644, T. 38, 39.
- **90**, Ueber den Nachweis des Mucins in Geweben mittelst der Färbemethode, in *ibid.*, Bd. XXXVI, S. 310–374.
- Huber**, G. Carl, **96**, Observation on the Innervation of the Sublingual and Submaxillary Glands, The Journal of Experimental Med., vol. I.
- **97**, Four Lectures on the Sympathetic System, Jour. Comparat. Neurol., vol. VII.
- **98**, The Innervation of the Tooth-pulp, Dental Cosmos, 1898.
- **99**, Observations on the Innervation of the Intracranial Vessels, Jour. Comparat. Neurol., vol. IX.
- **99**, A Contribution to the Minute Anatomy of the Sympathetic Ganglia of the Different Classes of Vertebrates, Journal of Morphology, vol. XVI.
- **1900**, Observations on Sensory Nerve-fibers in Visceral Nerves, and on Their Mode of Terminating, Jour. Comparat. Neurol., vol. X.
- Huber and De Witt**, **98**, A Contribution on the Motor Nerve-endings and on the Nerve-endings in the Muscle Spindle, Jour. Comparat. Neurol., vol. VII.
- **1900**, A Contribution on the Nerve Termination in Neurotendinous End-organs, Jour. Comparat. Neurol., vol. X.
- Hürthle**, K., **94**, Ueber den Sekretionsvorgang in der Schilddrüse, in Deutsch. med. Wochenschr., Nr. 12, S. 267–270. Dasselbe ausführlich in Arch. Phys., Pflüger, Bd. LVI, S. 1–44, 3 T.
- Izquierdo**, Vicente, **79**, Beiträge zur Kenntniss der Endigung der sensiblen Nerven, Inaug.-Diss., Strassburg, 80 Sn., 3 T.
- Jacobi**, Eduard, **86**, Zum feineren Bau der peripheren markhaltigen Nervenfasern, in Verh. Physik. Med. Ges. Würzburg (2), Bd. XX, S. 25–51, T. 3.
- Jensen**, O. S., **87**, Untersuchungen über die Samenkörper der Säugethiere, Vögel, und Amphibien: I. Säugethiere, in Arch. mikr. Anat., Bd. XXX, S. 379–425, T. 22–25.
- Jobert**, M., **75**, Recherches sur les organes tactiles de l'homme, in Compt. Rend., Bd. LXXX, pp. 274–276.

- Joseph, Max, 88**, Ueber einige Bestandtheile der peripheren markhaltigen Nervenfasern, in Sitz.-Ber. Akad. Berlin, S. 1321-1330; auch in Arch. Anat. u. Phys., Phys. Abth., S. 184-187.
- Kallius, E., 92**, Ein einfaches Verfahren, um Golgi'sche Präparate für die Dauer zu fixiren, in Anat. Hefte, 1. Abth., 5. Heft, S. 271-275.
- Kann, Hugo, 89**, Ueber das Epithel des Ureters, Med. Inaug.-Diss., 26 Sn., 1. T.
- Karg, 88**, Studien über transplantierte Haut, in Arch. Anat. u. Phys., Anat. Abth., S. 369-406, T. 20-22.
- Kerschner, 88**, Bemerkungen über ein besonders Muskelsystem im willkürlichen Muskel, Anat. Anzeiger, Bd. III.
- **88**, Beiträge zur Kenntniss der sensiblen Endorgane, Anat. Anzeiger, Bd. III.
- **93**, Ueber die Fortschritte in der Erkenntniss Muskelspindeln, Anat. Anzeiger, Bd. VIII.
- Key, Axel, und Gustav Retzius, 75, 76**, Studien in der Anatomie des Nervensystems und des Bindegewebes, 1. Hälfte, S. VI und 1-220, 39 T., Stockholm, und 2. Hälfte, 1. Abth., S. IV und 1-228, 36 T., Stockholm.
- Klaatsch, Hermann, 92**, Ueber die Betheiligung von Drüsenbildungen am Aufbau der Peyer'schen Plaques, in Morph. Jahrb., Bd. XIX, S. 548-552, 1 Fig.
- Klein, G., 93**, Entstehung des Hymen, in Sitz.-Ber. Ges. Morph. Phys. München, Bd. IX, S. 59-61.
- Kleinenberg, N., 79** (Picrosulphuric acid), in Quart. Journ. Micr. Sc., April, p. 208.
- Koch, G. von, 78**, Ueber die Herstellung dünner Schläufe von solchen Objekten, welche aus Theilen von sehr verschiedener Konsistenz zusammengesetzt sind, in Z. Anzeiger, 1. Jahrg., S. 36 und 37.
- Kölliker, A. v., 50, 54**, Mikroskopische Anatomie oder Gewebelehre des Menschen, Bd. II, 1. und 2. Hälfte, Leipzig.
- **73**, Die normale Resorption des Knochengewebes und ihre Bedeutung für die Entstehung der typischen Knochenformen, S. VI und 1-86, 8 T., 2 Fig., Leipzig.
- **81**, Zur Kenntniss des Baues der Lunge des Menschen, in Verh. Physik. Med. Ges. Würzburg, Bd. XVI (N. F.), 24 Sn., 4 T.
- **86**, Der feinere Bau des Knochengewebes, in Zeitschr. Wiss. Z., Bd. XLIV, S. 644-680, T. 36-39.
- **89**, Handb. der Gewebelehre des Menschen, 6. Aufl., Bd. I, S. VIII und 1-409, 329 Fig., Leipzig.
- **93**, Bd. II, 1. Hälfte, 372 Sn., Fig. 330-548, Leipzig.
- **96**, 2. Hälfte, S. I-VIII und 373 874, Fig. 549-842.
- Kolossow, A., 92**, Ueber eine neue Methode der Bearbeitung der Gewebe mit Osmiumsäure, in Zeit. Wiss. Mikroskopie, Bd. IX, S. 38-43.
- **93**, Ueber die Struktur des Pleuro-peritoneal- und Gefässepithels (Endothels), in Arch. mikr. Anat., Bd. XLII, S. 318-383, T. 22.
- Kostanecki, K. v., 92, 1**, Ueber Centralspindelkörperchen bei karyokinetischer Zelltheilung, in Anat. Hefte, 1. Abth., Bd. I, S. 205-249, T. 24.
- **92, 2**, Ueber die Schicksale der Centralspindel bei karyokinetischer Zelltheilung, *ibid.*, Bd. II, S. 249-268, T. 14, 15.
- **92, 3**, Die embryonale Leber in ihrer Beziehung zur Blutbildung, in *ibid.*, 1. Abth., Bd. I, S. 301-322.
- Krause, Rudolf, 97**, Beiträge zur Histologie der Speicheldrüsen, in Arch. mikr. Anat., Bd. XLIX, S. 707-769, T. 33, 34.
- Krause, W., 60**, Die terminalen Körperchen der einfach sensiblen Nerven, S. IV und 1-271, 3 Tab. und 4 Taf., Hannover.

- Krause, W., 80**, Die Nervenendigungen in den Muskeln, in *Internat. Monatsschr. Anat. Hist.*, Bd. v, S. 64–80, 97–106, T. 4–6.
- **81**, Zum Spiralsaum der Samenfäden, in *Biol. Centralbl.*, I. Jahrg., S. 25 und 26.
- **84**, Nervenendigungen in den Froschmuskeln, in *Internat. Monatsschr. Anat. Hist.*, Bd. I, S. 192–203, T. 8, 9.
- Krönig, 86**, Einschlusskitt für mikroskopische Präparate, in *Arch. mikr. Anat.*, Bd. xxvii, S. 657 und 658.
- Kuborn, Pierre, 90**, Du développement des vaisseaux et du sang dans le foie de l'embryon, in *Anat. Anzeiger*, 5. Jahrg., S. 277–282.
- Kühne, W., 74**. Vergl. Ewald.
- **79**, Chemische Vorgänge in der Netzhaut, in Hermann, *Handb. Physiologie*, Bd. III, Th. I, S. 236–342, 15 Fig., Leipzig.
- **86**, Neue Untersuchungen über die motorische Nervenendigung, in *Zeitschr. Biol.*, München, Bd. xxiii, I. Heft, 148 Sn., 16 T.
- Kühne, W.**, und A. Sch. **Lea, 74**, Ueber die Absonderung des Pankreas, in *Verh. Naturhist. Ver.*, Heidelberg (N. F.), Bd. I, S. 445–450.
- Kuhnt, Julius, 77**, Die peripherische markhaltige Nervenfasern, in *Arch. mikr. Anat.*, Bd. XIII, S. 427–464, T. 17.
- Kultschitzky, N., 87**, Ueber die Art der Verbindung der glatten Muskelfasern untereinander, in *Biol. Centralbl.*, Bd. VII, S. 572–574.
- Kupffer, C., 57**. Vergl. Bidder.
- **65**, Untersuchungen über die Entwicklung des Harn- und Geschlechtssystems, in *Arch. mikr. Anat.*, Bd. I, S. 233–248, T. 15.
- **73**, Ueber gewisse Strukturverhältnisse der Säugethierleber, in *Tagebl.*, 46. Vers. D. Naturf. Aerzte, Wiesbaden, S. 139.
- **75**, Ueber Differenzierung des Protoplasma in den Zellen thierischer Gewebe, in *Schr. Naturw. Ver. Schleswig-Holstein*, Bd. I, S. 229.
- **76**, Ueber Sternzellen der Leber, in *Arch. mikr. Anat.*, Bd. XII, S. 353–358.
- **78**, Die Entwicklung des Herings im Ei, in *Jahresber. Commiss. Unters. Deutsch. Meere*, Jahrg. 4–6, S. 177–226, T. 1–4.
- **83, 1**, Epithel und Drüsen des menschlichen Magens, in *Festschrift ärztl. Ver. München*, S. 27–46, 2 T.
- **83, 2**, Ueber den "Achsencylinder" markhaltiger Nervenfasern, in *Sitz-Ber. Akad. München*, Bd. XIII, 466–475, 1 T.
- **89**, Ueber den Nachweis der Gallenkapillaren und spezifischen Fasern in den Leberläppchen durch Färbung, in *Sitz.-Ber. Ges. Morph. Phys. München*, Bd. v, S. 82–86.
- **90**, Die Entwicklung von *Petromyzon Planeri*, in *Arch. mikr. Anat.*, Bd. xxxv, S. 469–558, T. 27–32.
- **92**, Ueber die Entwicklung von Milz und Pankreas, in *Münch. med. Abh.*, 7. Reihe, 4. Heft, 17 Sn., 7 Fig.
- **94**, Die Neurenlehre in der Anatomie des Nervensystems, in *München. med. Wochenschr.* (13), 11 Sn. (Separat.), 5 Fig.
- **96**, Ueber Energiden und paraplastische Bildungen, *Rektoratsrede Univers. München*, 29 Sn.
- **99**, Ueber die sogenannten Sternzellen der Säugethierleber, *Archiv mikr. Anat.*, Bd. LIV, S. 254.
- Kytmanow, K. A., 96**, Ueber die Nervenendigungen in den Labdrüsen des Magens bei Wirbelthieren, *Internat. Monatssch. f. Anat.*, Bd. XIII, S. 402.
- Landauer, Armin, 95**, Ueber die Struktur des Nierenepithels, in *Anat. Anzeiger*, Bd. x, S. 645–653, 5 Fig.
- Langendorff, O., 89**, Beiträge zur Kenntniss der Schilddrüse, in *Arch. Anat. u. Phys., Phys. Abth., Suppl. Bd.*, S. 219–242, T. 5.

- Langer**, C. v., 88, Ueber das Verhalten der Darmschleimhaut in der Ileocöcal-Klappe, nebst Bemerkungen über ihre Entwicklung, in Denkschr. Akad. Wien, Bd. LIV, 10 Sn., 2 T.
- Langerhans**, P., 68, Ueber die Nerven der menschlichen Haut, in Arch. path. Anat., Bd. XLVI, S. 325, T. 12.
- 69, Beiträge zur mikroskopischen Anatomie der Bauchspeicheldrüse, 32 Sn., Med. Inaug.-Diss., Berlin.
- Langley**, J. N., 90, On the Physiology of the Salivary Secretion, Journal Phys., vol. XI, p. 123.
- 92, On the Origin from the Spinal Cord of the Cervical and Upper Thoracic Sympathetic Fibers, with some Observations on White and Gray Rami Communicantes, Philosophical Trans., Royal Society, London, vol. CLXXXIII.
- Langley and Sherrington**, 91, On Pilomotor Nerves, Journal Phys., vol. XII.
- Lanterman**, A. J., 77, Ueber den feineren Bau der markhaltigen Nervenfaser, in Arch. mikr. Anat., Bd. XIII, S. 1-8, T. 1.
- Lavdowsky**, M., 93, Blut und Jodsäure und der sogenannte Chemotropismus, in Zeit. Wiss. Mikr., Bd. x, S. 4-35, T. 1, 2.
- Lea**, H. Vergl. Kühne, 74.
- Leber**, Th., 72, Die Blutgefäße des Auges, in Handb. Lehre von den Geweben, Stricker, S. 1049-1062, 2 Fig., Leipzig.
- 95, Der gegenwärtige Stand unserer Kenntnisse vom Flüssigkeitswechsel des Auges, in Ergebnisse, u. s. w., Merkel und Bonnet, Bd. IV, S. 144-196.
- Legge**, F., 97, Sulla distribuzione topographica della fibre elastiche nell' apparecchio digerente, Cagliari, P. Valdés, 20 pp., 1 T.
- Lenhossék**, M. v., 92, Ursprung, Verlauf, und Endigung der sensiblen Nervenfasern bei Lumbricus, Arch. mikr. Anat., Bd. XXXIX, S. 102-136, T. 5.
- 94, 1, Beiträge zur Histologie des Nervensystems und der Sinnesorgane, 190 Sn., 3 T., 15 Fig., Wiesbaden.
- 94, 2, Die Geschmacksknospen in den blattförmigen Papillen der Kaninchenzunge, in Verh. Physik. Med. Ges. Würzburg (N. F.), Bd. XXVII, 67 Sn., 2 T.
- 95, 1, Der feinere Bau des Nervensystems im Lichte neuester Forschungen, 2. Aufl., Berlin, 1895, VII und 409 Sn., 6 T., und 60 Fig. im Text.
- 95, 2, Centrosom und Sphäre in den Spinalganglienzellen des Frosches, in Arch. mikr. Anat., Bd. XLVI, S. 345-369, T. 15, 16.
- Lewaschew**, S. W., 86, Ueber eine eigenthümliche Veränderung der Pankreaszellen warmblütiger Thiere bei starker Absonderungsthätigkeit der Drüse, in *ibid.*, Bd. XXVI, S. 453-485, T. 17.
- Limbeck**, R. R. von, 92, Grundriss einer klinischen Pathologie des Blutes, S. VI und 1-202, 1 T., 25 Fig., Jena.
- London**, B., 81, Das Blasenepithel bei verschiedenen Füllungszuständen der Blase, in Arch. Anat. u. Phys., Phys. Abth., S. 317-330.
- Löwit**, M., 91, Die Anordnung und Neubildung von Leukocyten und Erythroblasten in den Blutzellen bildenden Organen, in Arch. mikr. Anat., Bd. XXXVIII, S. 524-612, T. 32-34.
- Ludwig**, C., 71, Von der Niere, in Handb. Lehre von den Geweben, Stricker, S. 489-507, 16 Fig., Leipzig.
- Lwoff**, Basilius, 89, Ueber die Entwicklung der Fibrillen des Bindegewebes, in Sitz.-Ber. Akad. Wien, Bd. XCVI, 3. Abth., S. 184-210, 2 T.
- Macallum**, A. B., 92, Studies on the Blood of Amphibia, in Trans. Canad. Inst., Toronto, vol. II, S. 45-80, T. 1.
- Mall**, F. P., 87, Die Blut- und Lymphwege in Dünndarm des Hundes, in Abh. Math. Physik. Klass. Sächs. Ges. Wiss., Leipzig, Bd. XIV, S. 153-189, T. 1-6.

- Mall, F. P., 91**, Das retikulirte Gewebe und seine Beziehungen zu den Bindegewebsfibrillen, in *ibid.*, Bd. XVII, S. 299-338, T. 1-11; also in the Johns Hopkins Hospital Reports, vol. 1.
- **98**, Lobule of the Spleen, Bul. of Johns Hopkins Hospital, vol. IX, p. 218.
- **1900**, The Architecture and Blood-vessels of the Dog's Spleen, Zeitsch. f. Morphol. u. Anthropol., Bd. II.
- Martin, A., 89, 1**, Tubenkrankheiten, in Real-Encyclopädie ges. Heilk., Eulenburg, 2. Aufl., Bd. XX, S. 263-286, 20 Fig.
- **89, 2**, Uterus, in *ibid.*, S. 438-532, 17 Fig.
- Maurer, F., 90**, Die erste Anlage der Milz und das erste Auftreten von lymphatischen Zellen bei Amphibien, in Morph. Jahrb., Bd. XVI, S. 203-208, 2 Fig.
- Mayer, Paul, 81**, Ueber die in der zoologischen Station zu Neapel gebräuchlichen Methoden zur mikroskopischen Untersuchung, in Mitth. Z. Station Neapel, Bd. II, S. 1-27.
- **83, 1**, Vergl. Andres.
- **83, 2**, Einfache Methode zum Aufkleben mikroskopischer Schnitte, in *ibid.*, Bd. IV, S. 521 und 522.
- **87, 1**, Ueber die Entwicklung des Herzens und der grossen Gefässstämme bei den Selachiern, in *ibid.*, Bd. VII, S. 338-370, T. II, 12.
- **87, 2**, Aus der Mikrotechnik, in Internat. Monatsschr. Anat. Phys., Bd. IV, S. 37-46.
- **91**, Ueber das Färben mit Hämatoxylin, in Mitth. Z. Station Neapel, Bd. X, S. 170-186.
- **92**, Ueber das Färben mit Karmin, Cochenille, und Hämatein-Thonerde, in *ibid.*, Bd. X, S. 480-504.
- **93**, Ueber die ersten Stadien die Gefässe bei den Selachiern, in Anat. Anzeiger, Bd. IX, S. 185-192.
- **96**, Ueber Schleimfärbung, in Mitth. Z. Station Neapel, Bd. XII, S. 303-330.
- **97**, Ueber Pikrokarmine, in Zeit. Wiss. Mikroskopie, Bd. XIV, S. 18-31.
- Mayer, Sigmund, 94**, Adenologische Mittheilungen, in Anat. Anzeiger, Bd. X, S. 177-191.
- Mercier, A., 94**, Die Zenker'sche Flüssigkeit, eine neue Fixierungsmethode, in Zeit. Wiss. Mikroskopie, Bd. XI, S. 471-478.
- Merkel, Friedrich, 71**, Die Stützzellen des menschlichen Hoden, in Arch. Anat. u. Phys. (Müller's Archiv), S. 1-13, T. 1.
- **83**, Die Speicheldrüsen, Rektoratsprogramm, Rostock, S. IV und 1-28, 2 T., Leipzig.
- Mertsching, A., 87**, Beiträge zur Histologie des Haares und des Haarbalges, in Arch. mikr. Anat., Bd. XXXI, S. 32-53, T. 4, 5.
- Metschnikoff, E., 83**, Untersuchungen über die intracelluläre Verdauung bei wirbellosen Thieren, in Arb. Z. Inst. Wien, Bd. V, S. 141-168, T. 13, 14.
- Meves, Friedr., 93**, Ueber eine Art der Entstehung ringförmiger Kerne und die bei ihnen zu beobachtenden Gestalten und Lagen der Attraktionssphäre, Inaug.-Diss., Kiel, 22 Sn.
- **96**, Ueber die Entwicklung der männlichen Geschlechtszellen von *Salamandra maculosa*, in Arch. mikr. Anat., Bd. XLVIII, S. 1-83, T. 1-5.
- **97**, Ueber Struktur und Histogenese der Samenfäden von *Salamandra maculosa*, in *ibid.*, Bd. I, S. 110-141, T. 7, 8.
- Meynert, Th., 72**, Vom Gehirn der Säugethiere, in Handb. Lehre von den Geweben, Stricker, S. 694-808, 32 Fig., Leipzig.
- Miller, W. S., 93**, The Structure of the Lung, Journ. of Morphol., vol. VIII, pp. 165-186.

- Minot**, Charles Sedgwick, **90**, Zur Morphologie der Blutkörperchen, in Anat. Anzeiger, 5. Jahrg., S. 601-604.
- **92**, Human Embryology, New York, S. XXIV und 1-815, 463 Fig., Deutsche Uebers., 1894, Leipzig.
- **99**, The Classification of Tissues, Journal Bost. Soc. of Med. Sciences, vol. IV, p. 43.
- **1900**, On a Hitherto Unrecognized Form of Blood Circulation without Capillaries in the Organs of Vertebrata, Proc. Bost. Soc. Nat. History, vol. XXIX, No. 10, pp. 185-215.
- Moore**, John E. S., **93**, On the Relationships and Rôle of the Archoplasm during Mitosis in the Larvæ of Salamander, in Quart. Journ. Micr. Sc. (2), vol. XXXIV, pp. 181-197, P. 21.
- Morochowetz**, Leo, **74**, Zur Histochemie des Bindegewebes, in Verh. Naturhist. Ver., Heidelberg (N. F.), Bd. I, S. 480-483.
- Müller**, Erik, **92**, Zur Kenntniss der Labdrüsen der Magenschleimhaut, in Verb. Biol. Ver. Stockholm, Bd. IV, S. 64-73, 7 Fig.
- **92**, Zur Kenntniss der Ausbreitung und Endigungsweise der Magen-, Darm-, und Pankreas-Nerven, Arch. mikr. Anat., Bd. XL.
- **95**, Ueber Sekretkapillaren, in Arch. mikr. Anat., Bd. XLV, S. 463-474, T. 27.
- Müller**, Hermann Franz, **89**, Zur Frage der Blutbildung, in Sitz-Ber. Akad. Wien, Bd. XCVIII, 3. Abth., S. 219-294, 5 T.
- **91**, Zur Leukämie-Frage; zugleich ein Beitrag zur Kenntniss der Zellen und der Zelltheilungen des Knochenmarkes, in D. Arch. klin. Med., Bd. XLVIII, S. 51-99, T. 1.
- **92**, Die Methoden der Blutuntersuchung, Zusammenfassendes Referat, in Centralbl. allg. Path. u. path. Anat., Bd. III, S. 801-820, 851-872.
- **96**, Ueber einen bisher nicht beachteten Formbestandtheil des Blutes, in Centralbl. allg. Path. u. path. Anat., Ziegler, Bd. VII, S. 529-539.
- Müller**, Vitalis, **92**, Ueber die Entwicklungsgeschichte und feinere Anatomie der Bartholini'schen und Cowper'schen Drüsen des Menschen, in Arch. mikr. Anat., Bd. XXXIX, S. 33-55, T. 2.
- Müller**, Wilhelm, **71**, Milz, in Handb. Lehre von den Geweben, Stricker, S. 251-262, 2 Fig., Leipzig.
- Nadler**, J., **97**, Zur Histologie der menschlichen Lippendrüsen, in Arch. mikr. Anat., Bd. I, S. 419-437, T. 22.
- Nagel**, W., **88**, Das menschliche Ei, in Arch. mikr. Anat., Bd. XXXI, S. 342-423, T. 20, 21.
- Neelsen** und **Schiffedercker**, P., **82**, Beitrag zur Verwendung der ätherischen Oele in der histologischen Technik, in Arch. Anat. u. Phys., Anat. Abth., S. 204-206.
- Neumann**, E., **68**, Ueber die Bedeutung des Knochenmarkes für die Blutbildung, Vorl. Mitth. in Centralbl. med. Wiss., Nr. 44, S. 689.
- **69**, Ueber die Bedeutung des Knochenmarkes für die Blutbildung, in Arch. Heilkunde, Bd. X, S. 68-102.
- **76**, Flimmerepithel im Oesophagus menschlicher Embryonen, in Arch. mikr. Anat., Bd. XII, S. 570-574.
- **82**, Das Gesetz der Verbreitung des gelben und rothen Markes in den Extremitätenknochen, in Centralbl. med. Wiss., 20. Jahrg., S. 321-323.
- **90**, Ueber die Entwicklung rother Blutkörperchen im neugebildeten Knochenmark, in Arch. Path., Virchow, Bd. CXXIX, S. 385-389.
- Neyt**, A. Vergl. van Beneden, **87**.
- Nissl**, Franz, **94**, Ueber die sogenannten Granula der Nervenzellen, in Neurol. Centralbl., Nr. 19, 21, und 22, 23 Sn. (Sep.), 7 Fig.
- Notthafft**, Albr. v., **92**, Neue Untersuchungen über den Verlauf der Degenerations-

- und Regenerationsprozesse am verletzten Nerven, in Zeit. Wiss. Z., Bd. LV, S. 134-188, 2 Fig., T. 6.
- Nusbaum**, Josef, **95**, Einige Bemerkungen über das Aufkleben der Paraffinschnitte mit Wasser, in Anat. Anzeiger, Bd. XII, S. 52-54.
- Oppel**, Albert, **89**, Beiträge zur Anatomie des *Proteus anguineus*, in Arch. mikr. Anat., Bd. XXXIV, S. 511-572, T. 28-30.
- **90**, Eine Methode zur Darstellung feinerer Strukturverhältnisse der Leber, in Anat. Anzeiger, 5. Jahrg., S. 143-145.
- **91**, Ueber Gitterfasern der menschlichen Leber und Milz, in *ibid.*, 6. Jahrg., S. 165-173, 4 Fig.
- **92**, Unsere Kenntniss von der Entstehung der rothen und weissen Blutkörperchen, Zusammenfassendes Referat, in Centralbl. allg. Path. u. path. Anat., Bd. III, S. 193-217, 241-249.
- **96**, 1. Vergl. Böhm und Oppel.
- **96**, 2, Lehrbuch der vergleichenden mikroskopischen Anatomie der Wirbelthiere, I. Th., Der Magen, S. I-IV und 1-543, 5 T. und 375 Fig., Jena.
- **97**, 2. Th., Schlund und Darm, S. VIII und 1-682, 4 T. und 343 Fig., Jena.
- Overlach**, Martin, **85**, Die pseudomenstruierende Mucosa uteri nach akuter Phosphorvergiftung, in Arch. mikr. Anat., Bd. XXV, S. 191-235, T. 10, 11.
- Pal**, J., **86**, Ein Beitrag zur Nervenfärbetechnik, in Med. Jahrb., Wien, S. 619-631.
- Paladino**, G., **90**, I ponti intercellulari tra l'uovo ovarico e le cellule follicolari, e la formazione della zona pellucida, in Anat. Anzeiger, 5. Jahrg., S. 254-259, 1 Fig.
- Paneth**, Josef, **88**, Ueber die secernirenden Zellen des Dünndarm-Epithels, in Arch. mikr. Anat., Bd. XXXI, S. 113-191, T. 8-10.
- Pfaundler**, Meinh., **92**, Zur Anatomie der Nebenniere, in Anzeiger Akad. Wien, 29. Jahrg., S. 224 und 225, ausführlich in Sitz.-Ber. Akad. Wien, Bd. CI, 3. Abth., S. 515-533, 2 T.
- Pfeiffer**, Leonhard, **84**, Ueber Sekretvakuolen der Leberzellen im Zusammenhange mit den Gallenkapillaren, in Arch. mikr. Anat., Bd. XXXIII, S. 22-30, T. 2.
- Pfitzner**, Wilh., **97**, Das Epithel der Conjunctiva: Eine histologische Studie, in Zeit. Biol., Bd. XXXIV, S. 397-431, T. 4.
- Pflüger**, E. F. W., **63**, Ueber die Eierstöcke der Säugethiere und des Menschen, 124 Sn., 5 T., Leipzig.
- Piersol**, George A., **93**, Duration of Motion of Human Spermatozoon, in Anat. Anzeiger, 8. Jahrg., S. 299-301.
- Podwysotszki**, W., Jr., **82**, Beiträge zur Kenntniss des feineren Baues der Bauchspeicheldrüse, in Arch. mikr. Anat., Bd. XXI, S. 765-768.
- Podwysotszki**, **87**, Ueber die Beziehungen der quergestreiften Muskeln zum Papillartheil der Lippenhaut, in *ibid.*, Bd. XXX, S. 327-335, T. 17.
- Pratt**, F. H., **98**, The Nutrition of the Heart through the Vessels of Thebesius and the Coronary Veins, The American Journal of Physiology, vol. 1, pp. 86-103.
- Preuschen**, von, **89**, Vagina, in Real-Encyclopädie ges. Heilk., Eulenburg, 2. Aufl., Bd. XX, S. 539-568, 12 Fig.
- Rabl**, C., **85**, Ueber Zelltheilung, in Morph. Jahrb., Bd. X, S. 214-330, T. 7-13.
- **89**, Ueber Zelltheilung, Briefliche Mittheilung an Herrn Geheimrath v. Kölliker, in Anat. Anzeiger, 4. Jahrg., S. 21-30, 2 Fig.
- **90**, Ueber die Prinzipien der Histologie, in Verh. Anat. Ges., 3. Vers., Berlin, S. 39-56.
- Rabl**, Hans, **91**, Die Entwicklung und Struktur der Nebenniere bei den Vögeln, in Arch. mikr. Anat., Bd. XXXVIII, S. 492-523, T. 29-31.
- **96**, Ueber die Kerne der Fettzellen, in *ibid.*, Bd. XLVII, S. 407-415.
- Ramón y Cajal**, S., **93**, 1, Neue Darstellung vom histologischen Bau des Central-

- nervensystems, in Arch. Anat. u. Phys., Anat. Abth., S. 319-428, 35 Fig. (Enthält ein Résumé des gegenwärtigen Standes der Nervenlehre, verbunden mit eine Darstellung der Ergebnisse der Arbeiten des Verf.'s.)
- Ramón y Cajal**, S., **93**, **2**, Manual de Histologia normal y técnica micrográfica, Valenzia, 2 a edición, S. xx und 1-692, 203 Fig.
- **93**, **3**, La rétine des vertébrés, in La Cellule, Tome IX, pp. 121-257.
- **94**, **1**, Die Retina der Wirbelthiere, in La Cellule, Tome IX, pp. 121-257. Deutsch von R. Greeff, Wiesbaden.
- **94**, **2**, Les nouvelles idées sur la Structure du système nerveux chez l'homme et chez les vertébrés, Paris.
- Ranvier**, L., **75**, Des préparations du tissu osseux avec le bleu d'aniline insoluble dans l'eau et soluble dans l'alcool, in Travaux Lab. Histol., S. 16-21, T. 1, Fig. 8, Paris.
- **78**, Leçons sur l'histologie du système nerveux, Bd. I, S. III und 1-352, 4 T., 20 Fig., und Bd. II, 380 Sn., 8 T., 13 Fig.
- **80**, Leçons d'anatomie générale sur le système musculaire, S. 1-466, 99 Fig., Paris.
- **81**, Leçons d'anatomie générale. Terminaisons nerveuses sensitives, Cornée, S. xx und 447, 54 Fig., Paris.
- **89**, Traité technique d'Histologie, 2ème Édit., S. 1-871, 414 Fig., 1 T., Paris.
- Rath**, O. vom, **93**, Beiträge zur Kenntniss der Spermatogenese von *Salamandra maculosa*, in Zeit. Wiss. Z., Bd. LVII, S. 97-185, T. 7-9.
- **95**, Zur Konservirungstechnik, in Anat. Anzeiger, Bd. XI, S. 280-288.
- Rauber**, August, **97**, **98**, Lehrbuch der Anatomie des Menschen, Bd. I und II, Leipzig, 6. Aufl.
- Rawitz**, B., **95**, Ueber eine Modifikation in der substantiven Verwendung des Hämoteins, in Anat. Anzeiger, Bd. XI, S. 301-303.
- Recklinghausen**, F. von, **71**, Das Lymphgefäßsystem, in Handb. Lehre von den Geweben, Stricker, S. 214-250, 7 Fig.
- Reinke**, F., **94**, Zellstudien, in Arch. mikr. Anat., Bd. XLIX, S. 377-422, T. 22-24.
- **95**, Die Japanische Methode zum Aufkleben von Paraffinschnitten, in Zeit. Wiss. Mikroskopie, Bd. XII, S. 21-23.
- **96**, Beiträge zur Histologie des Menschen, in Arch. mikr. Anat., Bd. XLVII, S. 34-44, T. 5.
- **97**, Beiträge zur Histologie des Menschen, 2. Folge, Ueber die Neuroglia in der weissen Substanz des Rückenmarkes vom erwachsenen Menschen, in *ibid.*, Bd. I, S. 1-14, T. 1.
- Remy**, Ch., **89**, Manuel des travaux pratiques d'histologie, Paris, S. 1-421, 399 Fig.
- Retterer**, Ed., **92**, Du tissu angiothélial des amygdales et des plaques de Peyer, in C. R. Soc. Biol. Paris (9), Tome IV, Mém., S. 1-11.
- Retzius**, Gustav, **75**, **76**. Vergl. Key.
- **81**, Zur Kenntniss der Spermatozoen, Biol. Unters., S. 77-88, 1 T.
- **84**, Das Gehörorgan der Wirbelthiere, Bd. II (Reptilien, Vögel, und Säuger), S. VIII und 1-368, T. 39, Stockholm.
- **90**, Die Interellularbrücken des Eierstockseies und der Follikelzellen, sowie über die Entwicklung der Zona pellucida, in Verh. Anat. Ges., 3. Vers., Berlin, S. 10 und 11; ausführlich in Hygiea Festband, S. 1-16, mit T.
- **92**, **1**, Biologische Untersuchungen, N. F., Bd. III, Zur Kenntniss der Nerven der Milz und der Niere, S. 53-55, T. 21, Stockholm, Leipzig.
- **92**, **2**, Ueber die neuen Prinzipien in der Lehre von der Einrichtung des sensiblen Nervensystems, in Biol. Untersuchungen, Retzius, N. F., Bd. IV, S. 49-56, 9 Fig., Berlin.
- **93**, Ueber die Nerven der Ovarien und Hoden, in Biol. Untersuchungen, Retzius, N. F., Bd. V, S. 31-34, T. 15, Berlin.

- Retzius, Gustav, 94**, Ueber das Ganglion ciliare, in Anat. Anzeiger, Bd. IX, S. 633-637, 2 Fig.
- **94**, Zur Kenntniss der Endigungsweise der Nerven in den Zähnen der Säugethiere, Biol. Untersuchungen, Retzius, Neue Folge, Bd. VI, S. 40.
- Rheiner, H., 52, 1**, Die Ausbreitung der Epithelien im Kehlkopfe, in Verh. Physik. Med. Ges., Würzburg, Bd. III, S. 222-226, 1 T.
- **52, 2**, Beiträge zur Histologie des Kehlkopfes, Med. Inaug.-Diss., 44 Sn., Würzburg.
- Riede, Karl, 87**, Untersuchungen zur Entwicklung der bleibenden Niere, 43 Sn., 1 T., Med. Inaug.-Diss., München.
- Riese, H., 91**, Die feinsten Nervenfasern und ihre Endigungen im Ovarium der Säugethiere und des Menschen, in Anat. Anzeiger, 6. Jahrg., S. 401-420, 8 Fig.
- Rindfleisch, G. E., 80**, Ueber Knochenmark und Blutbildung, in Arch. mikr. Anat., Bd. XVII, S. 1-11, T. 1, Fig. 1 und 2, und S. 21-42, T. 3.
- Rollett, Alexander, 70**, Ueber die blinddarmförmigen Drüsen des Magens, in Centralbl. med. Wiss., Nr. 21, 22, S. 325 und 326 und 337-340.
- **71, 1**, Von den Bindesubstanzen, in Handb. Lehre von den Geweben, Stricker, S. 34-107, 16 Fig.
- **71, 2**, Ueber die Hornhaut, in Handb. Lehre von den Geweben, Stricker, S. 1091-1141, 17 Fig., Leipzig.
- **85**, Untersuchungen über den Bau der quergestreiften Muskelfasern, 1. Theil, in Denkschr. Akad. Wien, Math.-naturwiss. Klasse, Bd. XLIX, 1. Abth., S. 81-132, T. 1-4, und 2. Theil, *ibid.*, Bd. LI, 1. Abth., S. 23-68, T. 1-4.
- **89**, Anatomische und physiologische Bemerkungen über die Muskeln der Fledermäuse, in Sitz.-Ber. Akad. Wien, Bd. XCVIII, 3. Abth., S. 169-183, 4 T.
- Rothe, Paul**, Ueber die Sternzellen der Leber, Med. Inaug.-Diss., München, 1882, S. 1-23, 3 T.
- Rückert, J., 85**, Zur Keimblattbildung bei den Selachiern, in Sitz.-Ber. Morph. Physiol. Ges., München, S. 47-104, 7 Fig.
- **88**, Ueber die Entstehung der endothelialen Anlagen des Herzens und der ersten Gefäßstämme bei Selachier-Embryonen, in Biol. Centralbl., Bd. VIII, S. 385-399, 417-430, 18 Fig.
- **92, 1**, Ueber die Verdoppelung der Chromosomen im Keimbläschen des Selachier-ees, *ibid.*, 7. Jahrg., S. 44-52, 2 Fig.
- **92, 2**, Zur Entwicklungsgeschichte des Ovarialeies bei Selachiern, in Anat. Anzeiger, 7. Jahrg., S. 107-158, 6 Fig.
- **94, 1**, Die Chromatinreduktion bei der Reifung der Sexualzellen, in Ergebnisse, u. s. w., Merkel und Bonnet, Bd. III, S. 517-587, 7 Fig.
- **94, 2**, Zur Eireifung der Copepoden, in Anat. Hefte, 1. Abth., Bd. IV, S. 261-351, T. 21-25.
- Rüdinger, N., 70**, Beiträge zur Histologie des Gehörorgans, München.
- **72, 1**, Das häutige Labyrinth, in Handb. Lehre von den Geweben, Stricker, S. 882-914, 23 Fig., Leipzig.
- **72, 2**, Die Ohrtrompete, in *ibid.*, S. 867-881, 9 Fig., Leipzig.
- **79**, Ueber die Muskelanordnung im Pfortner des Magens und am Anus, in Allg. Wiener med. Zeitung, Nr. 1 und 2, 9 Sn.
- **83**, Zur Anatomie der Prostata des Uterus masculinus und der Ductus ejaculatorii, in Festschr. Aerztl. Ver. München, S. 47-67, 3 T.
- **88**, Ueber die Abflusskanäle der Endolymph des inneren Ohres, in Sitz.-Ber. Akad. München, S. 455-476, 3 T.
- **91**, Ueber die Umbildung der Lieberkühn'schen Drüsen durch die Solitäröfollikel im Wurmfortsatz des Menschen, in *ibid.*, Bd. XXI, S. 121-138, T. 5.

- Ruffini**, Angelo, **94**, Sur un nouvel organe nerveux terminal, etc., in Arch. Ital. Biol., Tome XXI, S. 248-265, 3 T.
- Ruge**, Georg, **89**, Vorgänge am Eifollikel der Wirbelthiere, 1. Rückbildung der nicht ausgestossenen Eierstockseier bei Amphibien, in Morph. Jahrb., Bd. xv, S. 491-554, T. 18-21.
- Rühle**, Georg, **97**, Ueber die Membrana propria der Harnkanälchen und ihre Beziehung zu dem interstitiellen Gewebe der Niere, in Arch. Anat. u. Phys., Anat. Abth., S. 153-170, T. 4.
- Sala**, G., **99**, Untersuchungen über die Structur der Pacini'schen Körperchen, Anat. Anzeiger, Bd. XVI, S. 193.
- Sauer**, H., **95**, Neue Untersuchungen über das Nierenepithel und sein Verhalten bei der Harnabsonderung, in Arch. mikr. Anat., Bd. XLVI, S. 109-146, T. 4.
- Schaffer**, J., **91**, Beiträge zur Histologie menschlicher Organe: 1. Duodenum, 2. Dünndarm, 3. Mastdarm, in Sitz.-Ber. Akad. Wien, Bd. c, 3. Abth., S. 440-481, 2 T.
- **92**, Ueber Drüsen im Epithel der Vasa efferentia testis beim Menschen, in Anat. Anzeiger, 7. Jahrg., S. 711-717, 3 Fig.
- **93**, 1, Ueber den feineren Bau der Thymus und deren Beziehungen zur Blutbildung, in Sitz.-Ber. Akad. Wien, Bd. CII, 3. Abth., S. 336-341.
- **93**, 2, Beiträge zur Histologie und Histogenese quergestreiften Muskelfasern des Menschen und einiger Wirbelthiere, in *ibid.*, S. 7-148, 6 T.
- Schaper**, Alfred, **92**, Beiträge zur Histologie der Glandula carotica, in Arch. mikr. Anat., Bd. XI, S. 287-320, T. 16, 17.
- **95**, Ueber die sogenannten Epithelkörper (Glandulae parathyreoidæ) in der seitlichen Nachbarschaft der Schilddrüse und der Umgebung der Arteria carotis der Säuger und des Menschen, Archiv mikr. Anat., Bd. XLVI, S. 239.
- **97**, Die frühesten Differenzirungsvorgänge im Centralnervensystem, Archiv f. Entwick. der Organismen, Bd. v, S. 81.
- Schiefferdecker**, P., **82**, 1. Vergl. Neelsen.
- **82**, 2, Ueber die Verwendung des Celloidins in der anatomischen Technik, in Arch. Anat. u. Phys., Anat. Abth., S. 199-203.
- **86**, Ueber ein neues Mikrotom, in Zeit. Wiss. Mikroskopie, Bd. III, S. 151-164.
- **92**, Ueber zwei von R. Jung gebaute Mikrotome, in *ibid.*, Bd. IX, S. 168-175.
- Schleiden**, M. J., **38**, Beiträge zur Phytogenesis, in Arch. Anat. u. Phys., S. 137-176, T. 3, 4.
- Schmidt**, Martin B., **92**, Ueber Blutzellenbildung in Leber und Milz unter normalen und pathologischen Verhältnissen, in Beitr. path. Anat. allg. Path., Bd. XI, S. 199-233.
- Schoen**, W., **95**, Der Uebergangssaum der Netzhaut, oder die sogenannte Ora serrata, in Arch. Anat. u. Phys., Anat. Abth., S. 417-421, T. 14.
- Schottländer**, J., **91**, Beitrag zur Kenntniss der Follikelatresie nebst einige Bemerkungen über die unveränderten Follikel in den Eierstöcken der Säugethiere, in Arch. mikr. Anat., Bd. XXXVII, S. 192-238, T. 11.
- **93**, Ueber den Graaf'schen Follikel, seine Entstehung beim Menschen und seine Schicksale bei Mensch und Säugethieren, in *ibid.*, Bd. XLI, S. 219-294, T. 15, 16.
- Schuberg**, A., **91**, Ueber den Zusammenhang der Epithel- und Bindegewebszellen, in Sitz.-Ber. Physik. Med. Ges., Würzburg, S. 60-66.
- **93**, Ueber den Zusammenhang verschiedenartiger Gewebszellen im thierischen Organismus, in *ibid.*, S. 44-51.
- Schultze**, Max, **65**, Ein heizbarer Objektisch und seine Verwendung bei Untersuchungen des Blutes, in Arch. mikr. Anat., Bd. 1, S. 1-42, T. 1, 2.
- **72**, Die Retina, in Handb. Lehre von den Geweben, Stricker, Leipzig, S. 977 1034, Fig. 344-361.

- Schulz**, Karl, **95**, Das elastische Gewebe des Periost und Knochen, in Anat. Hefte, Bd. VI, S. 117-152, T. 5, 6.
- Schulze**, F. E., **71**, Die Lungen, in *ibid.*, S. 464-488, 14 Fig., Leipzig.
- **96**, Zellmembran, Pellicula, Cuticula, und Crusta, in Verh. Anat. Ges., 10. Vers., S. 27-32.
- Schwalbe**, G., **72**, Die Lymphbahnen des Auges, in Handb. Lehre von den Geweben, Stricker, S. 1063-1070, 2 Fig., Leipzig.
- **87**, Lehrbuch der Anatomie der Sinnesorgane, in Hoffmann, Lehrbuch der Anatomie des Menschen, Bd. II, 3. Abth., S. 1-570, 199 Fig., Erlangen.
- Schwann**, Th., **39**, Mikroskopische Untersuchungen über die Uebereinstimmung in der Struktur und dem Wachsthum der Thiere und Pflanzen, Berlin, S. XVIII und 240, 4 T.
- Schwartz**, Frank, **87**, Die morphologische und chemische Zusammensetzung des Protoplasmas, in Beiträge zur Biologie der Pflanzen, von F. Cohn, Bd. v, Heft 1, S. 1-244, 8 T.
- Schweigger-Seidel**, F., **65**, Die Nieren des Menschen und der Säugethiere in ihrem feineren Baue, S. 1-92, 4 T., Halle.
- **71**, Das Herz, in Handb. Lehre von den Geweben, Stricker, S. 177-190, 5 Fig., Leipzig.
- Seipp**, Ludwig, **95**, Das elastische Gewebe des Herzens, in Anat. Hefte, Bd. VI, S. 63-116, T. 3, 4.
- Sherrington**, **94**, On the Anatomical Constitution of Nerves of Skeletal Muscles, with Remarks on Recurrent Fibers in the Ventral Spinal Nerve-root, Journ. Phys., vol. XVII.
- Smirnow**, A., **88**, Ueber die Zellen der Descemet'schen Haut der Cornea bei Vögeln, in Protokoll Ges. Naturf. Universität Kasan (Beilage), Nr. 101, 4 Sn. (russisch).
- Smirnow**, **95**, Ueber die sensiblen Nervenendigungen im Herzen bei Amphibien und Säugethiern, Anat. Anzeiger, Bd. x.
- Sobotta**, J., **91**, Beiträge zur vergleichenden Anatomie und Entwicklungsgeschichte der Uterusmuskulatur, in Arch. mikr. Anat., Bd. XXXVIII, S. 52-100, T. 1.
- **96**, Ueber die Bildung des Corpus luteum bei der Maus, in Arch. mikr. Anat., Bd. XLVII, S. 261-308, T. 15-17.
- **97**, Ueber die Bildung des Corpus luteum beim Kaninchen, u.s.w., in Anat. Hefte, 1. Abth., Bd. VIII, S. 471-521, T. 42-48, 1 Textfig.
- Solger**, B., **89**, **1**, Zur Struktur der Pigmentzelle, in Zool. Anzeiger, 12. Jahrg., S. 671-673, 1 Fig.
- **89**, **2**, Ueber Knorpelwachsthum, in Fortschr. Med., Bd. VII, S. 849-855, 1 Fig.; auch in Verh. Anat. Ges., 3. Vers., Berlin, 1890, S. 67-71.
- **89**, **3**, Kohlensaures Ammoniak, ein Mittel zur Darstellung des Sarkolemmas, in Zeit. Wiss. Mikroskopie, Bd. VI, S. 189.
- **91**, Zur Kenntniss der Pigmentzellen, in Anat. Anzeiger, 6. Jahrg., S. 162-165, 2 Fig.
- **92**, Zelle und Zellkern, in Thiermedizin. Vorträge, 61 Sn., 1 T., Leipzig.
- **96**, Ueber den feineren Bau der Glandula submaxillaris beim Menschen, mit besonderer Berücksichtigung der Drüsengranula, in Festschrift f. C. Gegenbaur, Bd. II, S. 181-248, 2 T.
- Spalteholz**, W., **93**, Die Vertheilung der Blutgefäße in der Haut, 1. in Arch. Anat. u. Phys., Anat. Abth., S. 1-54, T. 1-6.
- Spengel**, J. W., **85**, August Becker's Schlittenmikrotom, in Zeit. Wiss. Mikroskopie, Bd. II, S. 453-459.
- Steiner**, Herm., **92**, Ueber das Epithel der ausführungsgänge der grösseren Drüsen des Menschen, in Arch. mikr. Anat., Bd. XL, S. 484-497, T. 27.

- Stieda**, Ludwig, **72**, Die Bildung des Knochengewebes, Festschrift, Leipzig, S. IV und 1-45, 1 T.
- **87**, Ueber Haarwechsel, Biol. Centralbl., Bd. VII, S. 353-363 und 385-394.
- Stöhr**, Ph., **84**, Ueber Mandeln und Balgdrüsen, in Arch. Path., Virchow, Bd. xcVII, S. 211-236, 2 T.
- **87**, Ueber Schleimdrüsen, in Festschrift, Kölliker, Leipzig, S. 421-444, T. 17.
- **89**, Ueber die Lymphknötchen des Darmes, in Arch. mikr. Anat., Bd. xxxIII, S. 255-283, T. 17, 18.
- **96**, **1**, Lehrbuch der Histologie, XII und 383 Sn., 260 Fig., Jena (7. Auflage).
- **96**, **2**, Ueber Randzellen und Sekretkapillaren, in Arch. mikr. Anat., Bd. XLVII, S. 447-461, T. 22.
- Stoss**, A., **91**, Konstruktion eines Kühlmessers, in Zeitschr. Wiss. Mikroskopie, Bd. VIII, S. 310-313, 1 Fig.
- Strasburger**, Eduard, **84**, Die Kontroversen der indirekten Kernteilung, in Arch. mikr. Anat., Bd. xxIII, S. 246-304, T. 13, 14.
- Streiff**, J. J., **97**, Ueber die Form der Schilddrüsen-Follikel des Menschen, in Arch. mikr. Anat., Bd. XLVIII, S. 579-586, T. 27.
- Stricht**, Omer van der, **87**, Recherches sur le Cartilage hyalin, in Arch. Biol., Tome VII, S. 1-92, T. 1-3.
- **92**, Nouvelles recherches sur la genèse des globules rouges et des globules blancs du sang, in *ibid.*, Tome XII, S. 199-344, T. 7-12.
- **93**, Nature et division mitotique des globules blancs des Mammifères, in Verh. Anat. Ges., 7. Vers., S. 81-92, 11 Fig.
- Teichmann**, Ludwig, **61**, Das Saugader-System vom anatomischen Standpunkt bearbeitet, S. XII und 1-124, 18 T., Leipzig.
- Tettenhamer**, Eugen, **93**, Ueber die Entstehung der acidophilen Leukocyten-granula aus degenerirender Kernsubstanz, in Anat. Anzeiger, 8. Jahrg., S. 223-228.
- Thoma**, Richard, **91**, Eine Entkalkungsmethode, in Zeit. Wiss. Mikroskopie, Bd. VIII, S. 191-192.
- Timofeew**, **94**, Zur Kenntniss der Nervenendigungen in den männlichen Geschlechtsorganen der Säuger, Anat. Anzeiger, Bd. IX, S. 342.
- **96**, Ueber eine besondere Art von eingekapselten Nervenendigungen in den männlichen Geschlechtsorganen bei Säugethieren, Anat. Anzeiger, Bd. XI, S. 44.
- Toldt**, Karl, **88**, Lehrbuch der Gewebelehre, 3. Aufl., 708 Sn., 210 Fig., Stuttgart.
- Tomarkin**, E., **93**, Lieberkühn'sche Krypten und ihre Beziehungen zu den Follikeln beim Meerschweinchen, in Anat. Anzeiger, 8. Jahrg., S. 202-205.
- Tornier**, Oskar, **86**, Ueber Bürstenbesätze an Drüsenepithelien, in Arch. mikr. Anat., Bd. xxVII, S. 181-191, T. 9.
- Triepel**, Hermann, **96**, Das elastische Gewebe in der Wand der Arterien der Schädelhöhle, in Anat. Hefte, Bd. VII, S. 191-214.
- Unna**, P. G., **83**, Entwicklungsgeschichte und Anatomie (der Haut), in Handb. spez. Path. Therapie, Ziemssen, Bd. XIV, 1. Hälfte, S. 1-114, 19 Fig.
- **91**, Notiz betreffend die Taenzer'sche Orceinfärbung des elastischen Gewebes, in Monatsschr. prakt. Dermatol., Bd. XII, S. 394-396.
- Vallete St. George**, von la, **67-87**, Abhandlungen über Spermatogenese bei verschiedenen Thieren, in Arch. mikr. Anat., Bd. III, S. 263; Bd. X, S. 495; Bd. XII, S. 797; Bd. XV, S. 261; Bd. XXV, S. 581; Bd. XXVII, S. 1; *ibid.*, S. 385; Bd. XXVIII, S. 1; Bd. XXX, S. 426.
- Virchow**, R., **50**, Einige neue Beobachtungen über Knochen- und Knorpelkörperchen, in Verh. Physik. Med. Ges., Würzburg, Bd. 1, S. 192-197.
- Waldeyer**, W., **70**, Eierstock und Ei, VI und 174 Sn., 6 T., Leipzig.

- Waldeyer, W.**, 71, Eierstock und Nebeneierstock, in Handb. Lehre von den Geweben, Stricker, S. 544-580, 8 Fig.
- 72, Hörnerv und Schnecke, in *ibid.*, S. 915-963, 19 Fig., Leipzig.
- 74, Mikroskopische Anatomie der Cornea, Sklera, Lider, und Conjunctiva, in Graefe u. Saemisch, Handb. ges. Augenheilk., Bd. 1, Th. 1, S. 169-264.
- 75, Ueber Bindegewebszellen, in Arch. mikr. Anat., Bd. XI, S. 176-194, T. 9.
- 82, Untersuchungen über Histogenese der Horngebilde insbesondere der Haare und Federn, in Beitr. Anat. Embryol., Festgabe Jakob Henle, Bonn, S. 141-163, T. 9b.
- 88, Ueber Karyokinese und ihre Beziehungen zu den Befruchtungsvorgänge, in Arch. mikr. Anat., Bd. xxxii, S. 1-122, 14 Fig.
- 91, Ueber einige neuere Forschungen im Gebiete der Anatomie des Centralnervensystems, in D. med. Wochenschr., 17. Jahrg., Nr. 44, ff., 64 Sn. (Separat), 10 Fig.
- Weigert, C.**, 91, Zur Markscheidenfärbung, in D. med. Wochenschr., Nr. 42, 9 Sn. (Separat).
- 95, Beiträge zur Kenntniss der normalen menschlichen Neuroglia, in Abh. Senkenb. Ges., Frankfurt a. M., Bd. XIX, S. 1-VI und 65-213, 13 T.
- Weismann, Aug.**, 61, Ueber das Wachsen der quergestreiften Muskeln nach Beobachtungen am Frosch, in Zeitschr. ration. Medizin, 3. Reihe, Bd. x, S. 263-284, T. 6, 7.
- Weldon, W. F. R.**, 85, On the Suprarenal Bodies of Vertebrata, in Quart. Journ. Micr. Sc., vol. xxv (N. S.), pp. 137-150, T. 11, 12.
- Werther, M.**, 86, Beobachtungen über die Absonderung der Salze in Speicheldrüsen, in Arch. Phys., Pflüger, Bd. xxxviii, S. 293-311.
- Wilson, E. B.**, 96, The Cell in Development and Inheritance, Macmillan & Co., 1896.
- Wolters, M.**, 91, Zur Kenntniss der Grundsubstanz und der Saftbahnen des Knorpels, in Arch. mikr. Anat., Bd. xxxvii, S. 492-512, T. 25.
- Zenker, K.**, 94, Chromkali-Sublimat-Eisessig als Fixierungsmittel, in München. med. Wochenschr., 41. Jahrg., Nr. 27, S. 532-534.
- Ziegler, H. E.**, 92, Ueber die embryonale Anlage des Blutes bei den Wirbelthieren, in Verh. D. Z. Ges., 2. Vers., S. 18-30, 3 Fig.
- Ziegler, H. E. u. F.**, 92, Beiträge zur Entwicklungsgeschichte von *Torpedo*, in Arch. mikr. Anat., Bd. xxxix, S. 56-102, 10 Fig., T. 3, 4.
- Zimmermann, A.**, 95, Das Mikroskop, Ein Leitfaden der Wiss. Mikroskopie, S. 1-VIII und 1-334, 231 Fig., Leipzig und Wien.
- Zimmermann, K. W.**, 93, Studien über Pigmentzellen, 1. Ueber die Anordnung des Archiplasmas in den Pigmentzellen der Knochenfische, in Arch. mikr. Anat., Bd. xli, S. 367-389, T. 23, 24.



# INDEX.

- ABBE'S apparatus, 19  
 Absorption of fat by intestine, 256  
 Accessory disc of Engelmann, 127  
   thread of spermatozome, 323  
 Acervulus, 381  
 Acetate of potash, mounting in, 47  
 Acetic acid, action of, on connective tissue,  
   118  
   sublimate solution as fixing fluid, 24  
 Achromatic portion of nucleus, 55  
   spindle, 62  
 Acid stains, 40  
 Acidophile cells, 187. See also *Cells*,  
   *eosinophile*.  
   granules, technic of, 205  
 Adipose tissue, 99  
 Agminated lymph-nodules, 177  
 Akrosome, 339  
 Alcohol as fixing solution, 22  
 Altmann's method of demonstrating gran-  
   ules in cells, 72  
   of mounting, 71  
   process of injection, 149  
 Alum-carmin as stain, 41  
 Alveolar ducts, 279  
   glands, 84  
 Alveoli, 84  
   of glands, 84  
   of lungs, 280  
 Amitosis, 57, 64  
 Amphiaster, 62  
 Amphibia, epithelium of alveoli of, 281  
 Amphophile granules, technic, 205  
 Ampullæ of Thoma, 182  
 Anaphases, 57, 63  
 Anastomoses of vessels, 199  
 Anilin stains, 42  
 Annulospiral nerve-ending, 162  
 Annulus fibrosus, 436  
   atrioventricularis, 191  
 Anterior elastic membrane of cornea, 410  
   endothelium of iris, 416  
   epithelium of crystalline lens, 428  
   ground bundle, 370  
   lymph-channels of eye, 429  
 Anterolateral columns, ascending, 370  
   descending, 370  
 Antrum of Graafian follicle, 309  
 Anus, 240  
 Apáthy's method for demonstration of fibril-  
   lar elements of nervous system, 404  
 Apicis dentis, foramen, 213  
 Apochromatic lens, 19  
 Aponeuroses, 96  
 Aqueous humor, 407  
 Arachnoid, 394  
 Arches of Corti, 448  
 Arcuate fibers of cornea, 411  
 Area cribrosa, 295  
   of Langerhans, pancreatic, 267  
   vasculosa, 168  
 Arrectores pilorum, 354  
 Arteriæ arciformes, 296  
   capsulares glomeruliferæ, 297  
 Arterial circle of Zinn, 426  
   trunks, great, 194  
 Arteries, 194  
   intralobular, 296  
   medium-sized, 195  
   precapillary, 196  
 Arteriolæ rectæ spuria, 296  
   rectæ verae, 297  
 Ascending anterolateral columns, 370  
 Atresia of ovarian follicles, 315  
 Attraction-sphere, 55  
 Auditory artery, internal, 452  
   canal, external, 435, 436  
   cells, outer, 449  
   hairs, 448  
   nerve, 452  
   organ, 435. See also *Ear*.  
   ossicles, 438  
   teeth, 446  
 Auerbach's plexus, 254  
 Auriculoventricular valves, 191  
 Axial canals of small intestines, 253  
   cords, 142  
   sheath of neuromuscular nerve end-  
   organs, 160  
   thread of spermatozome, 323  
   sheath of, 323  
 Axis-cylinder of nerve-fibers, 144  
   processes, 134  
 Axis-fibrils, 142  
 Axolemma, 142  
 Axones, 134  
 BAILLARGER'S striation, 379  
 Bars of intercellular cement, 80  
 Bartholin's glands, 322  
 Basement membranes, 75

- Basement membranes of small intestine, 246  
 Basic stains, 40  
 Basichromatin granules, 56  
 Basilar membrane, 444, 447  
 Basket cells of salivary glands, 228  
 Basophile granules, 174  
   technic of, 206  
 Bechtereff and Kaes's striation, 379  
 Benda's method for demonstration of medullary sheath, 399  
 Berkley's method for demonstrating nerves of liver, 274  
 Berlin blue as injection fluid, 49  
 Bertini's columns, 289  
 Bethe's method for staining neurofibrils and Golgi-nets, 405  
 Bile capillary, 258, 259  
 Bile-ducts, 263  
 Bismarck brown, 43  
 Bladder, 300  
 Blastema, 56  
 Blastomeres, 64, 73  
 Blood, 168  
   current, demonstration of, through vessels, 208  
   formation of, 168  
   islands, 168  
   plasma, 169, 176  
   platelets, 176  
   shadows, 170  
   sinus, 199  
   technic of, 203  
 Blood-cell, behavior of, in blood current, 177  
   red, nucleated, containing hemoglobin, 186  
 Blood-corpuscles, red, 169  
   white, 173  
 Blood-forming organs, 168  
   technic of, 202  
 Blood-vessels, 168, 193  
 Böhmer's hematoxylin, 41  
 Bone, 103  
   breakers, 111. See also *Osteoclasts*.  
   canaliculi, 103, 104  
   compact, of shaft, development of, 115  
   corpuscles, 104  
   isolation of, 123  
   development of, 107  
   endochondral, 107  
   intra-cartilaginous, 107  
   intramembranous, 107, 113  
   development of, 113  
   lacunæ of, 103, 104  
   lamellæ of, 104  
   large, examination of denser structure of, 121  
   spaces in, Ranvier's method to demonstrate, 121  
   structure of, 103  
 Bone-cells, 103  
 Bone-marrow, 185  
   blood-vessels in, 188  
   red, 185  
   technic of, 209  
   yellow, 185, 188  
 Bony cochlea, 443  
   labyrinth, 439  
 Borax-carmin, alcoholic, as stain, 40  
   aqueous, as stain, 40  
 Böttcher's cells, 450  
 Boundary zone, choroid, 413  
 Bowman's capsule, 287  
   glands, 457  
   membrane, 410  
 Brain-sand, 381  
 Bronchi, 277  
   branches of, 277  
 Bronchioles, 277  
   respiratory, 279  
 Brownian movement, 53  
 Bruch's membrane, 416  
 Brunner's glands, 236, 246  
 Budding, 56  
 Bulb hairs, 354  
 Bulbus oculi, 407  
 Bundles, tendon, primary, 96  
   secondary, 97  
 Burdach's column, 370  
 CÆCUM cupolare, 444  
   vestibulare, 444  
 Camera lucida, 20  
 Canada balsam as mounting medium, 46  
 Canaliculi, bone, 103, 104  
 Canalis communis, labyrinth of, 440  
 Capillaries, 198  
   bile, 258, 259  
   lymph, 201  
 Capsule, cartilage, 100  
   of glands, 84  
   of Glisson, 257  
   of lymph-gland, 178  
   of Tenon, 409  
 Carbol-xylol as clearing fluid, 47  
 Carbon dioxide, cutting tissues frozen with, 35, 36  
 Cardiac muscle-cells, 132  
 Carmin as stain, 40  
 Carmin-bleu de Lyon of Röse, 44  
 Carotid gland, 202  
 Cartilage, 99  
   capsule, 100  
   cell, 99  
   embryonal, 99  
   fibro-elastic, 102  
   ground-substance of, 99  
   hyaline, 99  
   lacunæ of, 100  
   matrix of, 99  
   nutrition of, 102  
 Cecum, 249  
 Cell, 51  
   auditory, 449  
   basket, of salivary glands, 228  
   blood-, behavior of, in blood current, 177  
   bone-, 103  
   Böttcher's, 450  
   Brownian movement of, 53  
   cartilage, 99  
   centro-acinal, 266

- Cell, chief, of acini of thyroid body, 284  
 of hypophysis, 381  
 of stomach, 239  
 peptic, 239  
 chromophilic, of hypophysis, 381  
 ciliated, cylindrical, 53  
 colloid, of acini of thyroid body, 284  
 cone-visual, 419  
 connective-tissue, fixed, 94  
 containing pigment, 184  
 cortical, small, of cerebellar cortex, 374  
 Deiters's, 449  
 delomorphous, 238  
 demonstration of granules in, 71  
 Altmann's method, 72  
 of structure of, 68  
 diagram of, 52  
 diffuse, of retina, 425  
 double staining of, 69  
 endothelial, 74, 86  
 demonstration of, 88  
 eosinophile, 187  
 transitional, 187  
 ependymal, 392  
 epithelial, isolated, examination of, 87  
 fat-, scheme of, 99  
 fixing of, 69  
 chromic acid for, 69  
 corrosive sublimate for, 69  
 Flemming's solution for, 69  
 picric acid for, 69  
 flagellate, 53  
 follicular, 334  
 ganglion, 134. See also *Ganglion cell*.  
 germinal, 85  
 giant, of bone-marrow, 187  
 gland-, 81  
 glandular, 54, 239  
 adelomorphous, 239  
 central, 239  
 chief, 239  
 peptic, 239  
 goblet, 81  
 granular, 95  
 of cerebellar cortex, 375  
 hair-, auditory, 448, 449  
 of utriculus, 442  
 Hensen's, 449, 450  
 hepatic, cords of, 258  
 lutein, 314  
 marrow, 186  
 mesameboid, 74  
 migratory, 94, 96, 175  
 molecular movement of, 53  
 monostratified, of retina, 425  
 muscle-, 123. See also *Muscle-cell*.  
 nerve-, 134. See also *Ganglion cell*.  
 neuro-epithelial, 85  
 neuroglial, 393  
 of Claudius, 450  
 of Golgi of cerebral cortex, 377  
 of Kupffer, 262  
 of Langerhans, 266  
 of Leydig, 431  
 of Martinotti of cerebral cortex, 377  
 of Purkinje of cerebellar cortex, 374
- Cell of Sertoli, 326  
 olfactory, 456  
 oxyntic, 238  
 parietal, 238  
 pigment, 71, 95, 96  
 pillar, of organ of Corti, 448  
 heads of, 448  
 plasma, 96  
 polarity of, 75  
 polygonal, of cerebral cortex, 376  
 polymorphous, of cerebral cortex, 377  
 polynuclear, 64  
 polystratified, of retina, 425  
 Purkinje's, 138  
 pyramidal, large, of cerebral cortex, 376  
 of cerebral cortex, 138  
 small, of cerebral cortex, 376  
 rod-visual, 418  
 segmentation, 64  
 seminal, primitive, 334  
 sense, 75  
 sexual, matured, 65  
 somatic, 65  
 spider-, 393  
 spindle, of cerebral cortex, 376  
 staining of, 69  
 stellate, of cerebellar cortex, 374  
 of cerebral cortex, 376  
 of liver, 262  
 sustentacular, 85, 334  
 technic of, 68  
 tegmental, 224  
 triangular, of cerebral cortex, 376  
 visual, 418  
 wandering, 53, 94, 96  
 with eosinophile granules, 187
- Cell-body, 52  
 of neurones, 134. See also *Ganglion cell*.
- Cell-division, 56  
 direct, 57, 64  
 indirect, 57  
 mitotic, diagrammatic, 58  
 of fertilized whitefish eggs, 60
- Cell-microsomes, 52
- Celloidin imbedding, 28  
 diagram for, 29  
 infiltration, 28  
 diagram for, 29  
 sections, cutting of, with sliding micro-  
 tome, 33  
 fixation of, to slide, 39
- Celloidin-paraffin imbedding, 29  
 infiltration, 29
- Cell-plate, 64
- Cell-spaces, 94
- Cementum, 215, 220
- Central artery of retina, 426  
 nervous system, 365  
 blood-vessels of, 397  
 membranes of, 393  
 technic of, 397  
 spindle, 62  
 vein of liver lobule, 258  
 of retina, 426
- Centro-acinal cells, 266

- Centrosome, 55  
 Centrosphere, 55  
 Cerebellar columns, direct, 370  
   cortex, 372  
     granular layer of, 375  
     medullary substance of, 375  
     molecular layer of, 372  
 Cerebral cortex, 375  
   cells of Golgi of, 377  
   cells of Martinotti of, 377  
   layer of large pyramidal cells, 376  
     of polymorphous cells, 377  
     of small pyramidal cells, 376  
   medullary substance of, 378  
   molecular layer of, 376  
 Ceruminous glands, 357, 436  
 Chemotaxis, 54  
 Chemotropism, 54  
 Chief cells of acini of thyroid body, 284  
   of hypophysis, 381  
   of stomach, 239  
 Chondrin, 103  
 Choroid, 407, 412  
   arteries of, 416  
   layers of, 412  
   plexus, 396  
 Choroidal fissure, 408  
 Chromatin, 55  
 Chromatolysis, 68  
   technic of, 68  
 Chromatophile granules of ganglion cell,  
   134  
 Chromic acid as fixing solution, 24  
   for cells, 69  
 Chromophilic cells of hypophysis, 381  
 Chromosomes, 61  
   daughter, 62  
 Chrzonszcwsky's physiologic auto-injection,  
   272  
 Chyle-vessels, 253  
 Cilia, 75  
   movement of, 87  
   of eyelids, 430  
 Ciliary body, 407, 412, 414  
   nerve supply of, 417  
   glands, 414  
   of Moll, 430  
   muscle, 414  
   processes, 414  
 Ciliated cell, 53  
 Circulatory system, 190  
   technic of, 210  
 Circulus arteriosus iridis major, 416  
   minor, 416  
 Circumanal glands, 250, 357  
 Circumvallate papillæ, 223, 225  
 Clarke's column, 367  
 Claudius' cells, 450  
 Clitoris, 322  
 Cloquet's canal, 429  
 Coal-tar stains, 42  
 Cochlea, 443  
   bony, 443  
   perilymph of, 454  
   spiral ganglion of, 452  
 Cochlear duct, 443, 444  
 Cohnheim's fields, 127  
   method for demonstrating nerve-fibers,  
     166  
 Coil-glands of skin, 357  
 Collective lens, 19  
 Colloid cells of acini of thyroid body, 284  
   material, 284  
 Colostrum, 362  
   corpuscles, 362  
 Columnæ rectales Morgagni, 250  
 Columns of Bertini, 289  
   of Burdach, 370  
   of Clarke, 367  
   of Goll, 370  
   of Türck, 370  
 Commissures, 371  
 Compound microscope, 17  
 Concretions, prostatic, 332  
 Condensers, 19  
 Cone-fibers of retina, 419  
 Cone-visual cells, 419  
 Coni vasculosi Halleri, 326  
 Conjunctiva, 430  
   scleral, 409  
 Connective tissue, 89. See also *Tissue*,  
   *connective*.  
 Connective-tissue cells, fixed, 94  
 Conus medullaris, 365  
 Convoluted tubules, 325, 327  
 Corium, 341, 344. See also *Dermis*.  
 Cornea, 407, 410  
   nerves of, 412  
   technic of, 434  
 Corneal corpuscles, 411  
   spaces, 411  
   technic of, 434  
 Corona radiata, 309  
 Corpora amylacea, 332  
 Corpus albicans, 315  
   Highmori, 325  
   luteum, 313  
 Corpuscles, connective-tissue, 94  
   blood-, red, 169  
   white, 173  
   bone, 104  
   isolation of, 123  
   colostrum, 362  
   corneal, 411  
   genital, 155  
   Golgi-Mazzoni, 350  
   Hassall's, 189, 190  
   Malpighian, 180, 182, 287, 289  
   Meissner's, 155  
   technic of, 364  
   of Grandry, 350  
   technic of, 364  
   of Herbst, 158, 350  
   technic of, 364  
   Pacinian, 157  
   technic of, 364  
 Corrosive sublimate as fixing fluid for car-  
   tilage, 120  
   as fixing solution, 23  
   for fixing cells, 69  
 Cortical cells, small, of cerebellar cortex,  
   374

- Cortical layer of hair, 351  
 nodules of lymph-glands, 179  
 substance of kidney, 288
- Corti's arches, 448  
 organ, 447  
 cells of, 447  
 characteristics of, 450  
 tunnel, 448
- Cover-slip, 20
- Cowper's glands, 332
- Cox's method for demonstration of ganglia cells, 401
- Crescents of Gianuzzi, 229
- Crista basilaris, 446
- Cristæ, 440, 441
- Crossed pyramidal columns, 370
- Crosses of Ranvier, 164, 165
- Crystalline lens, 428
- Cupola, 443
- Currents of diffusion, 27
- Cuticle, 341. See also *Epidermis*.  
 of hair, 351
- Cuticula, 54, 75  
 dentis, 213
- Cuticular membrane, 75  
 ridge, 436  
 structures, 75
- Cutis, 341
- Cytoplasm, 52
- Cytolymph, 53
- Czocor's cochineal solution, 41
- DAMAR as mounting medium, 47
- Daughter chromosomes, 62  
 stars, 336
- Decalcification, 122  
 v. Ebner's method, 122
- Decalcifying fluids, 122  
 hydrochloric acid, 122  
 nitric acid solution, 122
- Deiters's cells, 449  
 processes, 134
- Delafield's hematoxylin, 41
- Delomorphous cells, 238
- Demilunes of Heidenhain, 229
- Dendrites, 134, 135  
 of sensory neurones, 216
- Dendritic fibrous structures of Gruber, 437
- Dental sac, 218
- Dentin, 214, 218
- Dentinal bulbs, 217  
 fibers, 215, 216, 218  
 papillæ, 217  
 tubules, 214
- Dermis, 341  
 lymph-vessels of, 348
- Descemet's membrane, 411
- Descending anterolateral columns, 370
- Deutoplasmic granules, 311
- Diapedesis, 175, 201
- Diaster, 63, 336
- Diffuse cells of retina, 425  
 spongioblasts, 424
- Diffusion, current of, 27
- Digestive organs, 210
- Digestive organs, technic of, 269
- Dilator muscle of pupil, 416
- Direct cell-division, 57, 64.  
 cerebellar columns, 370  
 pyramidal tract, 370
- Discus proligerus, 309
- Dispirem, 63
- Double knife, 21  
 staining, 43  
 of cells, 69
- Doyère's elevation, 147
- Ductus endolymphaticus, 440, 454
- Dura mater, 393
- EAR, 435  
 external, 435  
 internal, 439  
 middle, 437  
 technic of, 455  
 vestibule of, 439
- Ectoderm, 51, 73  
 tissues derived from, 73
- Egg tubes, primary, of Pflüger, 307
- Ehrlich-Biondi triple stain, 45
- Ehrlich's hematoxylin, 42  
 leucocytic granules, 174  
 methylene-blue method for ganglion cells  
 and nerve-fibers, 402  
 neutrophile mixture, 206
- Ejaculatory ducts, 330
- Elastic fibers, 91  
 fibrous tissue, 98  
 membrane, anterior, of cornea, 410  
 posterior, of cornea, 411
- Eleidin, 343
- Embryonal cartilage, 99
- Enamel, 213  
 germs, 217  
 prisms, 213
- Encoche d'ossification, 112
- End-brush, 147, 151
- End-bulb of Krause, 154  
 cylindrical, 157
- Endocardium, 190
- Endolymph of membranous labyrinth, 453
- Endomysium, 129
- Endoneurium, 145
- Endoplasm, 188
- End-organs, nerve, neuromuscular, 158.  
 See also *Nerve end-organs, neuromuscular*.  
 neurotendinous, 162
- Endosteum, 185
- Endothelial and mesothelial cells, relations  
 of, 87  
 cells, 74, 86  
 demonstration of, 88
- Endothelium, 85  
 anterior, of iris, 416
- End-piece of Retzius, 323
- Engelmann's accessory disc, 127
- Entoderm, 51, 73  
 tissues derived from, 74
- Eosinophile cell, 187. See also *Cell, eosinophile*.

- Eosinophile granules, 174. See also *Granules, eosinophile*.
- Ependymal cells, 392
- Epicardium, 191
- Epidermis, 341  
 compensation for desquamation of, 344  
 layers of, 341  
 nerves of, technic of, 364  
 pigment in, 346  
 technic of, 362
- Epidural space, 394
- Epilamellar plexus, 232, 358
- Epimysium, 129
- Epiphysis, 380
- Epithelial cells, isolated, examination of, 87  
 tissue, 74  
 technic of, 87
- Epithelium, anterior, of crystalline lens, 428  
 ciliated, islands of, in cervical canal, 318  
 columnar, pseudostratified, 77  
 simple, 77  
 examination of, 87  
 germinal, of ovary, 307  
 glandular, 81  
 neuro-, 85  
 of urethra, 333  
 posterior, of iris, 416  
 respiratory, 280  
 simple, 76  
 cubic, 76  
 squamous, 76  
 stratified, 77  
 columnar, 79  
 squamous, 78  
 technic of, 87  
 transitional, 79
- Eponychium, 356
- Epoophoron, 322
- Erlicki's fluid, 25
- Erythroblasts, 186
- Erythrocytes, 169
- Esophagus, 233  
 technic for, 271
- Eustachian tube, 438, 439
- Excretory duct of testis, 329  
 ducts, membrane of, 82
- Exoplasm, 188
- External auditory canal, 435, 436  
 limiting membrane of retina, 420, 422
- Eye, 407  
 anterior lymph-channels of, 429  
 development of, 407  
 fetal blood-vessels of, 429  
 general structure of, 407  
 pigment layer of, 418  
 protective organs of, 430  
 technic for, 433  
 tunics of, 407
- Eyeball, 407  
 interchange of fluids in, 429
- Eyelids, 430  
 conjunctival portion of, 430  
 cuticular portion of, 430  
 middle layer of, 432  
 "third," 432.
- FALLOPIAN tubes, 316  
 nerve-supply of, 320  
 technic for, 340
- Farrant's gum glycerin, 48
- Fasciculus gracilis, 370
- Fat, absorption of, by intestine, 256  
 lobules, 99
- Fat-cell, scheme of, 99
- Fat-marrow, 185, 188
- Female genital organs, 306  
 pronucleus, 67
- Fenestra cochleæ, 438  
 rotunda, 438
- Fenestrated membranes, 98
- Ferrein's pyramids, 289
- Fertilization, diagram of, 66  
 process of, 65
- Fetal blood-vessels of eye, 429
- Fiber, cone-, of retina, 419  
 dentinal, 215  
 elastic, 91  
 intrafusel, of neuromuscular nerve end-organs, 159  
 Kupffer's reticular, 185  
 lens, 428  
 Müller's, of retina, 422  
 muscle-, striped, 124  
 nerve-, 142. See also *Nerve-fiber*.  
 Purkinje's, 190  
 muscle-cells of, 132  
 Remak's, 145  
 rod-, of retina, 419  
 Sharpey's, 106  
 sustentacular, of Deiters's cells, 450  
 tunnel-, 452  
 white, of connective tissue, 90
- Fiber-baskets of retina, 423
- Fibræ circulares, 415
- Fibrillar mass of Flemming, 53
- Fibrils of axial cord, demonstration of, 165
- Fibrin, 176, 207  
 demonstration of, 208
- Fibrocartilage, white, 102
- Fibro-elastic cartilage, 102
- Filiform papillæ, 222
- Filum terminale, 365
- Fimbriæ linguæ, 223
- Fixation to slide, of sections, 38
- Fixing methods, 22  
 solutions, 22  
 acetic sublimate, 24  
 alcohol, 22  
 chromic acid, 24  
 corrosive sublimate, 23  
 for cartilage, 120  
 Erlicki's, 25  
 Flemming's, 22  
 Fol's, 23  
 formalin, 25  
 formol, 25  
 Hayem's, 203  
 Hermann's, 23  
 Müller's, 24  
 nitric acid, 24  
 osmic acid, 22  
 for cartilage, 120

- Fixing solutions, picric acid, 23  
 picric-nitric acid, 23  
 picric-osmic-acetic acid, 24  
 picric-sublimate-osmic acid, 24  
 picrosulphuric acid, 23  
 Rabl's, 24  
 Zenker's, 25
- Flagellate cell, 53
- Flagellum of spermatozoon, 323
- Flemming's fibrillar mass, 53  
 interfibrillar substance, 53  
 solution, 22  
 for fixing cells, 69
- Flower-like nerve-ending, 162
- Fluids in eyeball, interchange of, 429
- Foam-structures, 73
- Foliate papillæ, 223
- Follicles, simple, of adenoid tissue, 177
- Follicular cells, 334
- Folliculi linguales, 225
- Fol's solution, 23
- Fovea centralis, 421
- Fontana's spaces, 415
- Foramen apicis dentis, 213
- Foramina nervosa, 446  
 papillaria, 293
- Formalin as fixing solution, 25
- Formol as fixing solution, 25
- Fragmentation, direct, 65
- Free-hand sectioning, 21
- Freezing apparatus for sliding microtome, 35
- Friedländer's glycerin-hematoxylin, 42
- Front lens, 19
- Fundus of fovea centralis, 421
- Fungiform papillæ, 222
- Funiculi of nerve-trunk, 145  
 compound, 147
- GANGLIA, 382  
 spinal, 382  
 sympathetic, 385
- Ganglion cell, 134  
 bipolar, 135, 137  
 chromatophile granules of, 134  
 demonstration of, 166  
 layer of retina, 420, 425  
 multipolar, 137  
 of Dogiel, in spinal ganglia, 384  
 sympathetic, 140  
 technic of, 399  
 unipolar, 137  
 spiral, of cochlea, 452
- Gärtner's duct, 322
- Gastric crypts, 237  
 glands, 237  
 body of, 238  
 fundus of, 238  
 neck of, 238
- Gastrulation, 73
- Gelatin-carmin as injection fluid, 48
- Gelatinous substance of Rolando, 367
- Genital corpuscles, 155  
 organs, female, 306
- Genital organs, male, 323
- Genito-urinary organs, 287
- Germ centers of lymphoid tissue, 175, 178  
 layers, 51
- Germinal cells, 85  
 epithelium of ovary, 307  
 spot, 56  
 vesicle, 65
- Germes, enamel, 217
- Giant-cells, 64, 187
- Gianuzzi's crescents, 229
- Giraldès, organ of, 329
- Gland-cell, 81
- Glands, alveolar, 84  
 Brunner's, 236, 246  
 capsule of, 84  
 carotid, 202  
 ceruminous, 357, 436  
 ciliary, 414  
 Moll's, 430  
 circumanal, 250, 357  
 classification of, 82  
 coil-, of skin, 357  
 gastric, 237. See also *Gastric glands*.  
 lacrimal, 432  
 lenticular, 241  
 Lieberkühn's, 245  
 lymph-, 177, 178. See also *Lymph-glands*.  
 mammary, 359. See also *Mammary glands*.  
 mixed, 230  
 mucous, 228  
 multicellular, 82  
 of Bartholin, 322  
 of Bowman, 457  
 of Cowper, 332  
 of Littré, 333  
 of Moll, 357  
 of Montgomery, 361  
 of mouth, small, 231  
 of oral cavity, 227  
 of skin, 357. See also *Skin, glands of*.  
 of Tyson, 334  
 parotid, 228  
 pineal, 350  
 saccular, 84  
 salivary, 228. See also *Salivary glands*.  
 sebaceous, 358  
 serous, 228  
 structure of, 82  
 sublingual, 228  
 submaxillary, 230  
 sudoriparous, 357  
 suprarenal, 301. See also *Suprarenal glands*.  
 sweat-, 357  
 thymus, 188  
 thyroid, 284  
 tubular, 82  
 branched, 83  
 compound, 83  
 reticulated, 83
- Glandula carotica, 202

- Glandulæ buccales, 211  
 duodenales, 236  
 labiales, 211
- Glandular cells, 54, 239. See also *Cell, glandular*.  
 epithelium, 81
- Glassy layer of choroid, 412, 414  
 membrane, 352
- Glia covering of pia mater, 396
- Glisson's capsule, 257
- Glomeruli arteriosi cochleæ, 453
- Glomerulus, 287
- Glomus caroticum, 202
- Glossary of literature, 460
- Glycerin, Farrant's gum, 48  
 mounting in, 47
- Glycerin-albumen for fixing paraffin sections to slide, 38
- Goblet cells, 81
- Gold chlorid as stain for capsules of cartilage, 120
- Golgi-Mazzoni corpuscle, 350
- Golgi's cell of cerebral cortex, 377  
 methods for demonstration of ganglion cells, 399  
 mixed, 401  
 rapid, 401  
 slow, 400  
 preparations, methods of mounting, 402  
 tendon spindle, 162
- Goll's column, 370
- Gowers's columns, 370
- Graafian follicle, 309  
 antrum of, 309  
 bursting of, 313
- Grandry's corpuscles, 350  
 technic for, 364
- Granular cells, 95  
 of cerebellar cortex, 375  
 layer, Tomes', 220  
 sole plate, 148
- Granules, acidophile, technic for, 205  
 amphophile, technic for, 205  
 basophile, 174  
 technic for, 206  
 demonstration of, in cells, 71  
 deutoplasmic, 311  
 eosinophile, 174  
 cells with, 187  
 technic for, 205  
 interstitial, of Kölliker, 129  
 leucocytic, Ehrlich's, 174  
 mast-cell, technic for, 205  
 neutrophile, 174  
 technic for, 206  
 yolk, 311
- Gray matter, 136  
 substance of spinal cord, 365
- Ground bundle, anterior, 370  
 plexus of cornea, 412
- Ground-substance, interfascicular, 97  
 of areolar connective tissue, 93  
 of cartilage, 99
- Gruber's dendritic fibrous structures, 437
- Gustatory organs, 223
- HAIR, 350  
 auditory, 448  
 bulb, 351, 354  
 cells of utriculus, 442  
 cortical layer of, 351  
 cuticle of, 351  
 follicle, 351  
 nerve-fibers of, 354  
 germ, 351  
 glassy membrane of, 352  
 growth of, 353  
 medullary substance of, 351  
 olfactory, 457  
 papilla, 351  
 root, 351  
 root-sheaths of, 351  
 inner, 351  
 outer, 351  
 shaft, 351  
 shedding of, 354  
 technic for, 364
- Hamulus, 444
- Hassall's corpuscles, 189, 190
- Haversian canals, 103  
 spaces, 111
- Hayem's solution, 203
- Hearing, organ of, 435  
 technic for, 455
- Heart, 168, 190  
 coats of, 190  
 elastic tissue of, distribution in, 191  
 muscle-cell, 149  
 nerve supply of, 192
- Heidenhain's demilunes, 229  
 iron-lack hematoxylin, 42
- Helicotrema, 444
- Heliotropism, 54
- Heller's plexus, 251
- Hemalum as stain, 42
- Hematin, 169
- Hematoidin, demonstration of, 207
- Hematoxylin as stain, 41. See also *Stains*.  
 Delafield's, for demonstrating canalicular system in cartilage, 120
- Hematoxylin-eosin as stain, 44
- Hematoxylin-safranin of Rabl as stain, 44
- Hemin, 169  
 isolation of, 207
- Hemoglobin, 169  
 demonstration of, 206
- Hemokonia, 176
- Henle's layer, 351  
 loop, 288, 291  
 ascending limb of, 288, 291  
 descending limb of, 288, 291  
 sheath, 147
- Hensen's cells, 449, 450  
 median disc, 127
- Hepatic cells, cords of, 258  
 cords, 258
- Herbst's corpuscles, 158, 350  
 technic for, 364
- Hermann's solution, 23
- Heterotypic form of mitosis, 64
- Highmore, body of, 325
- Hilum of lymph-gland, 178

- Histology, general, 51  
     special, 168  
 Homeotypic mitosis, 64  
 Honing microtome knife, 36  
 Horn-sheath of nerve fibers, 142  
 Howship's lacunæ, 111  
 Huber's method for mounting Golgi's pre-  
     parations, 402  
 Huschke's auditory teeth, 446  
 Huxley's layer, 351  
 Hyaline cartilage, 99  
 Hyaloid arteries, posterior, 429  
     canal, 429  
     membrane, 427  
 Hyaloplasm, 53  
 Hydatids of Morgagni, 322  
 Hydrochloric acid as decalcifying fluid,  
     122  
 Hydrotropism, 54  
 Hymen, 321  
 Hypolamellar plexus, 232  
 Hypophysis, 381
- IMBEDDING, 25**  
     celloidin, 28. See also *Celloidin imbed-*  
         *ding*.  
     celloidin-paraffin, 29  
     paraffin, 26. See also *Paraffin imbed-*  
         *ding*.  
     tissues, box for, 26  
 Immersion lens, 19  
 Implantation cone, 135  
 Indifferent fluids, 21  
     Kronecker's, 21  
     physiologic saline solution, 21  
     Ranvier's iodine and potassium iodide,  
         21  
     Ripart and Petit's, 21  
     Schultze's iodized serum, 21  
 Indirect cell-division, 57  
 Inferior nasal artery of retina, 427  
     vein, 427  
     papillary artery, 426  
     vein, 426  
 Infiltration, 25  
     celloidin, 28. See also *Celloidin infil-*  
         *tration*.  
     celloidin-paraffin, 29  
     paraffin, 26. See also *Paraffin infiltra-*  
         *tion*.  
 Infundibula, 279  
 Injection fluids, 48  
     Berlin blue, 49  
     gelatin-carmin, 48  
     methods of, introduction to, 48  
     of lymph-channels, 49  
     of lymph-spaces, 49  
     of lymph-vessels, 49  
 Inner molecular layer of retina, 420, 423  
     nuclear layer of retina, 420, 423  
 Intercellular bridges, 75, 342  
     demonstration of, 88  
     spaces, 75  
     substance, 73  
 Interfascicular ground-substance, 97  
 Interfibrillar substance of Flemming, 53  
 Interglobular spaces, 215  
 Interlobular duct of pancreas, 266  
 Intermediate disc of Krause, 127  
     tubule of pancreas, 266  
 Internal auditory artery, 452  
     limiting membrane, 422  
 Interpapillary epithelial processes, 79  
 Interstitial granules of Kölliker, 129  
 Intertubular cell-masses of pancreas, 267  
 Intestine, 235  
     absorption of fat by, 256  
     blood supply, 251  
     large, 249  
     lymph supply of, 251  
     mucous membrane of, structure of, 235  
     nerve supply of, 251  
     secretion of, 256  
     small, 243  
         axial canals of, 253  
         crypt of, 248  
         lacuna of, 248  
         technic for, 271  
 Intracapsular plexuses, 387  
 Intralobular arteries of kidney, 296  
     vein, 258, 261, 298  
 Iodo-iodide of potassium stain to demon-  
     strate glycogen in cartilage, 121  
 Iris, 407, 412, 415  
     diaphragm, 18  
     layers of, 415, 416  
     nerve supply of, 417  
 Islands of ciliated epithelium in cervical  
     canal, 318  
 Isolating fluids, 87
- JAPANESE method for fixing paraffin sec-**  
**tions to slide, 39**  
 Jung's sliding microtome, 33, 34
- KARYOKINESIS, 57**  
     Karyokinetic cell-division, heterotypic, 336  
     homeotypic, 336  
 Karyolymph, 55  
 Karyolysis, 68  
     technic of, 68  
 Keratohyalin, 342  
     technic for, 362  
 Kidney, 287  
     arched collecting portion of tubules, 288,  
         293  
     blood-vessels of, 295  
     cortical substance of, 288  
     distal convoluted portion of tubules, 288,  
         292  
     intercalated portion of tubules, 288, 292  
     medullary substance of, 288  
     pelvis of, 300  
     proximal convoluted portion of tubules,  
         288, 290  
     straight collecting tubules of, 288  
 Knife, double, 21  
 Kölliker's interstitial granules, 129  
     muscle columns, 126

- Kopsch's technic for ganglion cells, 402  
 Krause's end-bulb, 154  
   cylindric, 157  
   intermediate disc, 127  
   transverse membrane, 127  
 Kronecker's fluid, 21  
 Krönig's varnish, 48  
 Kupffer's method of treating liver tissue,  
   273  
   reticular fibers, 185  
 Kytoblastema, 56
- LABIUM tympanicum, 446  
 vestibulare, 445  
 Labyrinth, bony, 439  
   development of, 454  
   membranous, 439, 440  
   osseous, 439  
 Lacrimal apparatus, 432  
   gland, 432  
   sac, 433  
 Lacteals of villi, 253  
 Lacuna of small intestine, 248  
 Lacunæ, Howship's, 111  
   of bone, 103, 104  
   of cartilage, 100  
 Lagena, 444  
 Lamellæ, 97  
   marrow, 104  
   of bone, 104  
   periosteal, 104  
 Lamina basilaris propria, 447  
   choriocapillaris, 413  
   cribrosa, 409, 425  
   elastica interna, 195  
   fusca, 409  
   propria of oral cavity, 211  
   reticularis, 447, 451  
   spiralis membranacea, 444, 447  
     ossea, 444, 445  
   suprachoroidea, 412  
   vasculosa Halleri, 413  
 Langerhans, areas of, 267  
   cells of, 266  
 Lanthanin, 56  
 Large intestine, 249  
 Larynx, 275  
 Lateral column, 367  
   mixed, 370  
 Layer of Henle, 351  
   of Huxley, 351  
 Leucocytes, 173, 187  
   polynuclear, amitotic division of, 64  
 Lens, 407  
   apochromatic, 19  
   capsule, 428  
   collective, 19  
   crystalline, 428  
   fibers, 428  
   front, 19  
   immersion, 19  
   ocular, 19  
   suspensory ligament of, 428  
   technic of, 434  
 Lenticular glands, 241
- Leydig's cells, 431  
 Lieberkühn's crypts, 245  
   glands, 245  
 Ligaments, 96  
 Ligamentum pectinatum iridis, 415  
   spirale, 444, 446  
 Limbus spiralis, 445  
 Limiting membrane, external, 420, 422  
   internal, 422  
 Lingual mucous membrane, 221  
   papillæ of, 221  
   papillæ, 221  
 Linin, 55  
 Liquor folliculi, 309  
 Literature, glossary of, 460  
 Littré's glands, 333  
 Liver, 257  
   development of, 265  
   lobules, 257  
   lymph-vessels of, 263  
   nerves of, 264  
   technic of, 274  
   technic of, 272  
     Kupffer's method, 273  
   vascular system of, 260  
 Lobes, renal, 287  
 Lobules, fat, 99  
   liver, 257  
   spleen, 182  
 Loop of Henle, 288, 291. See also  
   *Henle's loop*.  
 Löwit's method of demonstrating nerve-  
   fibers, 167  
 Lung, blood-vessels of, 281  
   lymphatics of, 282  
   tissue, 281  
 Lunula, 356  
 Lutein cells, 314  
 Lymph, 168  
   canalicular system, 94  
   capillaries, 201  
 Lymphatic glands, capsule of, 178  
   technic for, 208  
   system, 200  
 Lymph-channels, anterior, of eye, 429  
   injection of, 49  
 Lymph-follicles of tongue, 225  
   of tonsils, 225  
   solitary, 177  
 Lymph-glands, 177, 178  
 Lymph-nodules, 177  
   agminated, 177  
 Lymphocytes, 173, 175, 187  
 Lymphoid tissue, 177  
 Lymph-sinus, 179  
 Lymph-spaces, 201  
   injection of, 49  
   periaxial, of neuromuscular end-organ,  
     160  
   perichoroidal, 413  
 Lymph-vessels, 168, 200  
   injection of, 49
- MACERATING fluids, 87  
 Macula acustica sacculi, 441  
   utriculi, 441

- Macula lutea, 421  
     region of, 421  
 Magenta red as stain for connective tissue, 119  
 Male genital organs, 323  
     pronucleus, 67  
 Malpighian bodies, 180, 182  
     corpuscles, 180, 182, 287, 289  
     layer, technic of, 363  
 Mammary glands, 359  
     human, structure of, 360  
     lymphatics of, 361  
     milk of, 361  
 Mantle fibers, 63  
 Marginal thread of spermatozoon, 323  
     zone, 75  
 Marrow, bone-, 185. See also *Bone-marrow*.  
     cell, 186  
     fat-, 185, 188  
     spaces, primary, 109  
         secondary, 111  
 Martinotti's cells of cerebral cortex, 377  
 Mast-cell granules, technic of, 205  
 Matrix of areolar connective tissue, 93  
     of cartilage, 99  
     of nail, 355  
     sulcus of, 355  
 Mayer's picric-magnesia-carmin, 44  
 Median disc of Hensen, 127  
 Mediastinum testis, 325  
 Medullary cords, 179  
     cortex, projection fibers of, 378  
     rays, 288  
     sheath, 142  
         technic, 397-399  
     substance, association fibers of, 378  
         centripetal fibers of, 378  
         commissural fibers of, 378  
     of cerebellar cortex, 375  
         climbing fibers of, 375  
         mossy fibers of, 375  
     of cerebral cortex, 378  
     of hair, 351  
     of kidney, 288  
     of ovary, 306  
     terminal fibers of, 378  
 Medullated nerve-fibers, 144  
 Meissner's corpuscles, 155  
     technic of, 364  
     plexus, 255  
 Membrana capsulopupillaris, 429  
     præformativa, 220  
     prima of epithelium, 75  
     propria, 84  
     pupillaris, 429  
     tectoria Cortii, 447, 451  
 Membranous labyrinth, 439, 440  
 Meninges of central nervous system, 393  
 Merkel's terminal disc, 127  
 Mesameboid cells, 74  
 Mesenchyme, 74  
 Mesoderm, 51, 73  
     cells of, 74  
 Mesothelial and endothelial cells, relations of, 87  
 Mesothelium, 74, 85  
 Metakinesis, 62  
 Metaphases, 57, 62  
 Methylene-blue for staining of nerve-fibers, 403  
 Methyl-green, 43  
 Metschnikoff's phagocytes, 53  
 Microscope and its accessories, 17  
     coarse adjustment of, 18  
     compound, 17  
     description of, 17  
     fine adjustment of, 18  
     parts of, 17  
     simple, 17  
 Microscopic preparation, 20  
     technic, introduction to, 17  
 Microtome, 30  
     knife, honing of, 36  
     sharpening of, 36  
     laboratory, 31  
     rocking, 31  
     sliding, 31  
         cutting celloidin sections with, 33  
         paraffin sections with, 31  
         freezing apparatus for, 35  
         of Jung, 33, 34  
         varieties of, 37  
 Migratory cells, 94, 96, 175  
 Milk, 361  
 Mitosis, 57  
     demonstration of, 69  
     heterotypic form of, 64  
     homeotypic, 64  
 Mitotic cell-division, diagrammatic, 58  
     of fertilized whitefish eggs, 60  
 Mixed gland, 230  
     lateral column, 370  
 Modiolus, 443  
 Molecular movement of cells, 53  
 Moll's ciliary glands, 430  
     glands, ciliary, 357  
 Monaster, 62  
 Mononuclear eosinophile cells, 187  
 Monostratified cells of retina, 425  
 Montgomery's glands, 361  
 Morgagni's hydatids, 322  
 Morula mass, 73  
 Mother skein, 61  
 Motor endings in striated voluntary muscle, 150  
     end-plate, 148  
     nerve-endings, 147  
     neurones, 138  
         peripheral, diagram of, 148  
 Mounting, 21, 46  
     Altmann's method of, 71  
 Mouth, small glands of, 231  
 Mucematein, 271  
 Mucicarmin, 271  
 Mucosa of oral cavity, 211  
 Mucous glands, 228  
     membrane of intestine, 236  
 Müller's fibers, 415  
     of retina, 422  
     fluid, 24  
 Multicellular glands, 82

- Muscle-casket, 127  
 Muscle-cell, 123  
   cardiac, 132  
   heart, 149  
   nonstriated, 124, 149  
   of fibers of Purkinje, 132  
   smooth, 124  
   striped, 123  
   unstriated, 123  
 Muscle-columns of Kölliker, 126  
 Muscle-fasciculi, 129  
 Muscle-fibers, striped, 124  
 Muscular tissue, 123  
   technic of, 132  
 Muscularis mucosæ of intestine, 236  
   of pharynx, 234  
   of small intestine, 246  
 Myelin sheath, 142  
 Myelocytes, 186  
 Myeloplaxes, 187  
 Myoblasts, 131  
 Myocardium, 191
- NAIL**, 355  
   bed, 355  
   sulcus of, 355  
   body of, 355  
   lunula of, 356  
   matrix, 355  
   sulcus of, 355  
   root, 355  
   walls, 355
- Nasal artery, inferior, of retina, 427  
   superior, of retina, 427  
   cavity, 456  
   technic of, 457  
   duct, 433  
   vein, inferior, of retina, 427  
   superior, of retina, 427
- Nerve, auditory, 452  
   end-organs, neuromuscular, 158  
     axial sheath of, 159  
     distal polar region of, 159  
     equatorial region of, 159  
     intrafusal fibers of, 159  
     proximal polar region of, 159  
   neurotendinous, 162  
     end-organs of Golgi-Mazzoni, 350  
     of Grandry, 350  
     of Herbst, 159  
     of Krause, 154  
     of Meissner, 155  
     of Ruffini, 350  
   optic, 425. See also *Optic nerve*.  
   pilomotor, 355  
   Nerve-cell, 134. See also *Ganglion cell*.  
   Nerve-ending, annulospiral, 162  
     flower-like, 162  
     motor, 147  
     sensory, 151  
       encapsulated, 152, 154  
       free, 152  
   Nerve-fiber layer of retina, 425  
   Nerve-fibers, 142  
     Nerve-fibers ending in muscle tissue, telodendria of, 147  
     medullated, 144  
     nonmedullated, 145  
     staining of, with methylene-blue, 403  
   Nerve-trunk, peripheral, diagram to show composition of, 146  
   Nervous system, central, 365  
     blood-vessels of, 397  
     membranes of, 393  
     technic of, 397  
   tissue, 133  
     technic of, 164  
     tunic of eye, 407, 418
- Neura, 134  
 Neuraxones, 134  
 Neurilemma, 143  
   nuclei, 143  
 Neurites, 134  
 Neuroblasts, 133  
 Neurodendron, 134  
 Neuro-epithelial cells, 85  
 Neuro-epithelium, 85  
 Neuroglia, 392  
   staining of, 406  
 Neuroglial cells, 393  
 Neurokeratin, 142  
 Neuromuscular nerve end-organs, 158. See also *Nerve end-organs*, *neuromuscular*.  
 Neurone, 134  
   cell-bodies of, 134. See also *Ganglion cell*.  
   centripetal, peripheral, 139  
   motor, 138  
     peripheral, diagram of, 148  
   relationship of, 389  
   sensory, peripheral, 139  
     diagram of, 152
- Neuroplasm, 142  
 Neuropodia, 136  
 Neurotendinous nerve end-organs, 162  
 Neutrophile granules, 174  
   technic of, 206  
   mixture, Ehrlich's, 206  
 Nitric acid, aqueous solution of, as decalcifying fluid, 122  
   as fixing solution, 24
- Nodes of Ranvier, 143  
   demonstration of, 164
- Nodules, 177  
   cortical, 179  
   lymph-, 177. See also *Lymph-nodules*.  
   secondary, 175, 178  
   terminal, of spermatosome, 323
- Nonmedullated fibers, demonstration of, 166  
   nerve-fibers, 145
- Nonstriated muscle-cell, 124, 149  
 Normoblasts, 186  
 Nuclear division, 56  
   membrane, 56  
   sap, 55  
   stains, 40
- Nucleated red blood-cells containing hemoglobin, 186  
 Nucleolus, 51  
   true, 56  
 Nucleoplasm, 55

- Nucleus, 51, 55  
 dorsalis, 307  
 segmentation, 65  
 Nuel's space, 450
- OBJECTIVE system, 19
- Ocular lens, 19
- Odontoblasts, 215, 216, 218
- Oil of bergamot as clearing fluid, 47  
 of cloves as clearing fluid, 47  
 of organum as clearing fluid, 47
- Olfactory bulb, 379  
 glomerular layer, 379  
 granular layer, 380  
 layer of mitral cells, 379  
 of peripheral fibers, 379  
 of pyramidal cells, 379  
 molecular layer of, 379  
 stratum gelatinosum, 379  
 cell, 456  
 hairs, 457  
 region of nasal cavity, 456
- Oocytes, 312
- Oppel method for demonstrating reticular  
 liver fibers, 274
- Optic cup, 408  
 nerve, 407, 425  
 blood-vessels of, 426  
 papilla, 420  
 region of, 420  
 stalks, 408  
 vesicles, primary, 407  
 secondary, 408
- Ora serrata, 422
- Oral cavity, 211  
 glands of, 227  
 technic of, 269
- Orbiculus ciliaris, 414
- Orcein as stain for connective tissue, 118
- Organ of Corti, 447. See also *Corti's organ*.
- Organs, blood-forming, 168
- Osmic acid as fixing solution, 22  
 for cartilage, 120
- Osseous labyrinth, 439
- Ossification, 107  
 centers of, 107  
 groove, 112  
 ridge, 112
- Osteoblasts, 109
- Osteoclasts, 111
- Otolithic membrane, 442
- Otoliths, 442
- Outer fiber layer of retina, 420  
 molecular layer of retina, 420, 423
- Ova, 65  
 primitive, 307
- Ovary, 306  
 blood-vessels of, 316  
 cortex of, 306  
 germinal epithelium of, 307  
 medullary substance of, 306  
 stroma of, 306  
 technic of, 340
- Ovula Nabothi, 318
- Ovum, 306  
 changes in, during development, 311  
 ripe, 312  
 technic of, 340
- Oxychromatin granules, 56
- Oxyntic cells, 238
- PACCHIONIAN bodies, 395
- Pacinian corpuscles, technic of, 364
- Pal's method for demonstration of medullary sheath, 398
- Pancreas, 265  
 blood supply of, 268  
 interlobular duct of, 266  
 intermediate tubule of, 266  
 intertubular cell-masses of, 267  
 nerve supply of, 268  
 technic of, 274
- Pancreatic duct, 265
- Panniculus adiposus, 346
- Papilla spiralis-cochleæ, 441
- Papillæ, 78  
 circumvallate, 223, 225  
 dentinal, 217  
 filiform, 222  
 foliate, 223  
 fungiform, 222  
 hair, 351  
 lingual, 221  
 optic, 420  
 region of, 420  
 tactile, 345  
 vascular, 345
- Papillary artery, inferior, 426  
 superior, 426
- vein, inferior, 426  
 superior, 426
- Paracarmin as stain, 40
- Paradidymis, 329
- Paraffin imbedding, 26  
 diagram for, 28  
 infiltration, 26  
 diagram for, 28  
 removal of, 40  
 sections, cutting of, with sliding microtome, 31  
 distilled water for fixing of, to slide, 38  
 fixing of large number to cover-slips, 39  
 glycerin-albumin for fixing of, to slide, 38  
 Japanese method of fixing to slide, 39
- Paralinnin, 55
- Paranuclein, 56
- Paraplast, 53, 81
- Parathyroid glands, 285
- Parenchymatous tissues, sectioning of, 21
- Parietal cells, 238
- Parioophoron, 322
- Parotid gland, 228
- Pars ciliaris retinæ, 414, 422  
 iridica retinæ, 422  
 papillaris, 344  
 reticularis, 344
- Partsch's cochineal solution, 41

- Pellicula, 54  
 Pelvis of kidney, 300  
   renal, 299, 300  
 Penis, 332  
   erectile tissue of, 333  
   nerve supply of, 334  
 Perforating fibers of cornea, 411  
 Periaxial lymph-space, 160  
 Pericardium, 191  
 Pericellular plexuses, 386  
 Perichondrium, 101  
 Perichoroidal lymph-spaces, 413  
 Perilymph of cochlea, 454  
 Perilymphatic spaces, 201  
 Perimysium, 129  
 Perineurium, 146  
 Periosteum, 203  
 Peripheral centripetal neurones, 139  
   motor neurone, diagram of, 148  
   nerve terminations, 147  
   sensory neurones, 139  
   diagram of, 152  
 Peritendineum, 97  
 Perivascular spaces, 201  
 Petit and Ripart's solution, 21  
 Petit's canal, 428  
 Pfüger's primary egg tubes, 307  
 Phagocytes, 175  
   Metschnikoff's, 53  
 Phalangeal plate, 449, 450  
   process, 449  
 Pharynx, 233  
 Physiologic excavation of retina, 420  
 Pia intima, 395  
   mater, 395  
 Pial funnels, 396  
 Picric acid as fixing solution, 23  
   for cell, 69  
   as stain, 44  
 Picric-magnesia-carmin as stain, Mayer's,  
   44  
 Picric-nitric acid as fixing solution, 23  
 Picric-osmic-acetic acid solution as fixing  
   fluid, 24  
 Picric-sublimate-osmic acid solution as fix-  
   ing fluid, 24  
 Picrocarmin as stain for connective tissue  
   in cartilage, 120  
   for elastic fibers in cartilage, 120  
   of Ranvier, 43  
   of Weigert, 43  
 Picrosulphuric acid as fixing solution, 23  
 Pigment, 90  
   cell, 71, 95, 96  
   in epidermis, 346  
   layer of eye, 418  
   membrane, 408  
   of eye, 407  
   origin of, 316  
 Pillar cells, 448  
   heads of, 448  
 Pilomotor nerves, 355  
 Pineal gland, 380  
 Pituitary body, 381  
 Plasma cells, 96  
 Plexus, choroid, 396  
   Plexus, epilamellar, 232  
   ground, of cornea, 412  
   hypolamellar, 232  
   intracapsular, 387  
   myenteric, 254  
   of Auerbach, 254  
   of Heller, 251  
   of Meissner, 255  
   pericellular, 386  
   subepithelial, of cornea, 412  
   superficial, of cornea, 412  
 Placæ palmatæ, 318  
   semilunares, 250  
   sigmoideæ, 237  
   transversales recti, 250  
 Plural staining, 43  
 Polar body, 65  
   field, 64  
   rays, 62  
 Polarity of cell, 75  
 Polygonal cells of cerebral cortex, 376  
 Polykaryocyte, 175  
 Polymorphous cells of cerebral cortex, 377  
 Polynuclear cells, 64  
   leucocytes, 64  
 Polystratified cells of retina, 425  
 Portal vein, 260  
 Posterior elastic membrane of cornea, 411  
   epithelium of iris, 416  
   hyaloid arteries, 429  
 Potassium bichromate-osmic acid solution,  
   400  
 Precapillary arteries, 196  
   veins, 197  
 Precartilag, 99  
 Primary blastodermic layers, 73  
   germ layers, 73  
   marrow spaces, 109  
   optic vesicles, 407  
   tendon bundles, 96  
 Primitive ova, 307  
   seminal cells, 334  
 Primordial ova, 307  
 Prominentia spiralis, 446  
 Promontory ridge, 439  
 Pronucleus, female, 67  
   male, 67  
 Prophases, 57, 60  
 Prostate, 330  
   blood-vessels of, 332  
   nerve supply of, 332  
   secretion of, 332  
 Prostatic bodies, 332  
   concretions, 332  
 Protoplasm, 51, 81  
 Protoplasmic currents, 68  
   stains, 40  
 Protozoa, 51  
 Pseudopodia, 53  
 Pulp cords of spleen, 182  
 Pupil, dilator muscle of, 416  
   sphincter muscle of, 416  
 Purkinje's cells, 138  
   of cerebellar cortex, 374  
   fibers, 190  
   muscle-cells of, 132

- Purkinje's vesicle, 306  
 Purpurin, alkaline, as stain for calcium carbonate in bone, 122  
 Pyramidal cells, large, of cerebral cortex, 376  
   of cerebral cortex, 138  
   small, of cerebral cortex, 376  
   columns, crossed, 370  
   tract, direct, 370  
 Pyramids of Ferrein, 289  
  
 QUINTUPLE hydroquinon developer, 401  
  
 RABL'S hematoxylin-safranin stain, 44  
   solution, 24  
 Rami cochleares, 452  
   vestibulares, 452  
 Ramón y Cajal's technic for retina, 435  
 Ranvier's crosses, 164, 165  
   iodin and potassium iodid solution, 21  
   method for demonstrating spaces in bone, 121  
   for examination of connective tissue, 117  
   nodes, 143  
   . demonstration of, 164  
   picrocarmin, 43  
 Real image, 19  
 Recessus cameræ posterioris, 427  
   cochleæ, 454  
 Rectum, 249  
 Red blood-cells, nucleated, containing hemoglobin, 186  
   blood-corpuscles, 169  
   bone-marrow, 185  
 Reissner's membrane, 444, 447  
 Relationship of neurones, 389  
 Remak's fibers, 145  
   demonstration of, 166  
 Renal lobes, 287  
   pelvis, 299, 300  
 Renflement biconique, 143  
 Respiration, organs of, 275  
   technic of, 286  
 Respiratory bronchioles, 279  
   epithelium, 280  
   region of nasal cavity, 456  
   accessory cavities of, 456  
 Rete testis, 325, 327  
 Retia mirabilia, 199  
 Retina, 407, 408, 418  
   blood-vessels of, 426  
   layers of, 418-420, 423  
   macula lutea of, 421  
   Müller's fibers of, 422  
   optic papilla of, 420  
   ora serrata of, 422  
   pars ciliaris retinæ, 422  
   iridica retinæ, 422  
   relation of elements of, to one another, 423  
   technic of, 434  
 Retinaculæ cutis, 346  
 Retzius, end-piece of, 323  
  
 Ribbon sectioning, 32  
 Ripart and Petit's solution, 21  
 Ripe ova, 312  
 Rocking microtome, 31  
 Rod-fibers of retina, 419  
 Rod-visual cells, 418  
 Rolando's gelatinous substance, 367  
 Root-sheaths of hair, 351. See also *Hair*, *root-sheaths of*.  
 Röse's carmin-bleu de Lyon, 44  
 Rouleaux, 169, 170  
 Rudder membrane of spermatozome, 323  
  
 SACCULAR glands, 84  
 Sacculus, 440, 441, 454  
 Saccus endolymphaticus, 440, 454  
 Safranin as stain, 43  
 Salivary glands, 228  
   blood-supply of, 232  
   lymphatics of, 232  
   nerve supply of, 232  
   scheme of, 227  
 Sarcolemma, 125  
 Sarcolytes, 131  
 Sarcous elements, 126, 128  
 Scala media, 444  
   tympani, 444  
   vestibuli, 444  
 Schlemm's canal, 409  
 Schmidt - Lantermann-Kuhn's segments, 142  
 Schultze's iodized serum, 21  
 Schwann's sheath, 143  
 Sclera, 407, 409  
   blood-vessels of, 410  
   technic of, 434  
 Scleral conjunctiva, 409  
   sulcus, inner, 410  
 Sebaceous glands, 358  
 Secondary marrow spaces, 111  
   nodule, 175, 178  
   optic vesicle, 408  
   tendon bundles, 97  
 Secretion of intestine, 256  
   process of, 84  
   vacuoles, 259  
 Section staining, 40  
   stretchers, 35  
 Sectioning, 21, 30  
   double knife for, 21  
   free-hand, 21  
   of parenchymatous tissues, 21  
   ribbon, 32  
 Segmentation cell, 64  
   nucleus, 65  
 Selective stains, 40  
 Semen, 323  
   technic of, 340  
 Semicircular canals, 442  
   anterior superior vertical, 440  
   external, 440  
   horizontal, 440  
   posterior inferior vertical, 440  
 Semilunar fold, 443  
   valves, 191

- Seminal cells, primitive, 334  
vesicles, 330
- Sense cells, 75
- Sense-organs, special, general considerations of, 458
- Sensory nerve-endings, 151  
encapsulated, 152, 154  
free, 152  
neurones, peripheral, diagram of, 152
- Septa renis, 289
- Septum posticum, 395
- Serous cavities, 201  
gland, 228
- Sertoli's cells, 326
- Sexual cells, matured, 65
- Sharpening microtome knife, 36
- Sharpey, fibers of, 106
- Sheath of Schwann, 143
- Sihler's method of demonstrating nerve-endings, 167
- Silver-impregnation of thin membranes, 49
- Simple epithelium, 76. See also *Epithelium, simple*.  
microscopes, 17
- Sinus, 199  
blood, 199  
lactiferus, 360  
pocularis, 332
- Skin, 341  
and appendages, 341  
technic of, 362  
blood-vessels of, 350  
glands of, 357  
nerve-endings in, 348  
nerves of, 348  
pigment of, technic of, 363  
structure of, technic of, 363  
technic of, 362  
true, 341  
vascular system of, 347
- Slides, 20
- Sliding microtome, 31. See also *Microtome, sliding*.
- Small intestine, 243. See also *Intestine, small*.
- Smell, organ of, 456  
technic of, 457
- Sole nuclei, 148  
plate, granular, 148
- Solitary lymph-follicles, 177
- Somatic cell, 65
- Soudan III as stain for fat, 120
- Special histology, 168  
sense-organs, general considerations of, 458
- Specimens, drawing of, 20  
examination of, 19  
permanent, preparation of, 46
- Sperma, 323
- Spermatids, 66, 336  
development of, into spermatosomes, 336
- Spermatoblast, 338
- Spermatocytes, 66  
of first order, 335
- Spermatogenesis, 334
- Spermatogones, 66
- Spermatogonia, 334
- Spermatosome, 323  
accessory thread of, 323  
axial thread of, 323  
sheath of, 323  
development of, from spermatids, 336  
flagellum of, 323  
head of, 323  
marginal thread of, 323  
middle piece of, 323  
rudder membrane of, 323  
tail of, 323  
terminal nodule of, 323  
undulating membrane of, 323
- Spermatozoa, 53, 65, 66
- Spermatozoon, 323. See also *Spermatozome*.
- Sphincter muscle of pupil, 416
- Spider-cells, 393
- Spinal cord, 365  
anterior median fissure of, 365  
gray substance of, 365  
horns of, 367  
posterior median septum of, 365  
structure of, 365  
white substance of, 365  
ganglia, 382  
ganglion cell of Dogiel, 384
- Spindle cells of cerebral cortex, 376
- Spiral ganglion of cochlea, 452
- Spirem, 61
- Spleen, 180  
lobules, 182
- Splenic pulp, 183
- Spongioblasts, 392  
diffuse, 424  
stratum of, 424
- Spongionoplasm, 53
- Staining, 40  
double, 43  
in bulk, 45  
diagram showing method, 46  
in section, diagram showing method, 46  
neurofibrils and Golgi-nets, Bethe's method for, 405  
of cells, 69  
of nervous tissue, 402  
of neuroglia, 406  
plural, 43  
purpose of, 40  
section, 40
- Stains, 40  
acid, 40  
alkaline purpurin, for calcium carbonate in bone, 122  
alum-carmin, 41  
anilin, 42  
basic, 40  
Bismarck brown, 43  
borax-carmin, alcoholic, 40  
aqueous, 40  
carmin, 40  
carmin-bleu de Lyon, of R6se, 44  
coal-tar, 42  
Czocor's cochineal solution, 41  
Ehrlich-Biondi triple, 45

- Stains for adipose tissue, 119  
 gold chlorid, for capsules of cartilage, 120  
 hemalum, 42  
 hematoxylin, 41  
   Böhrer's, 41  
   Delafield's, 41  
     for demonstrating canalicular system in cartilage, 120  
   Ehrlich's, 42  
     for lime-salts in bone, 122  
   Friedländer's glycerin-, 42  
   Heidenhain's iron, 42  
 hematoxylin-eosin, 44  
 hematoxylin-safranin of Rabl, 44  
 iodo-iodid of potassium, to demonstrate glycogen in cartilage, 121  
 magenta red, for connective tissue, 119  
 methyl-green, 43  
 nuclear, 40  
 orcein, for connective tissue, 118  
 paracarmin, 40  
 Partsch's cochineal solution, 41  
 picric acid, 44  
 picric-acid-fuchsin, Van Gieson's, 399  
 picric-magnesia-carmin, Mayer's, 44  
 picrocarmin, for connective tissue in cartilage, 120  
   for elastic fibers in cartilage, 120  
   Ranvier's, 43  
   Weigert's, 43  
 protoplasmic, 40  
 safranin, 43  
 selective, 40  
 Soudan III, for fat, 120  
 Stellate cells, 262  
   large, of cerebellar cortex, 375  
   of cerebellar cortex, 374  
   of cerebral cortex, 376  
 Stellulæ vasculosæ, 414  
 Stomach, 235, 237  
   technic of, 271  
 Stomata, 85  
 Straight tubules of testis, 325  
 Stratified epithelium, 77  
 Stratum circulare, 437  
   corneum, 343  
   gelatinosum, 379  
   germinativum, 341  
   granulosum, 309, 341  
   lucidum, 343  
     technic of, 362  
   Malpighii, 341  
     technic of, 363  
   proprium of oral cavity, 211  
   radiatum, 437  
   spinosum, 342  
   spongioblasts, 424  
   submucosum of oral cavity, 212  
 Stria vascularis, 246  
 Striation of Baillarger, 379  
   of Bechtereff and Kaes, 379  
 Striped muscle-cell, 123  
   muscle-fibers, 124  
 Stroma of red blood-cells, 169, 170  
   of iris, 416  
 Stroma of ovary, 306  
 Subarachnoid space, 394  
 Subdural space, 394  
 Subepithelial plexus of cornea, 412  
 Sublingual gland, 228  
 Submaxillary gland, 230  
 Submucosa of intestine, 236  
   of oral cavity, 212  
 Subpia, 396  
 Substantia gelatinosa, 367  
   propria of cornea, 410  
 Succus prostaticus, 332  
 Sudoriferous duct, 357  
 Sudoriparous glands, 357  
 Sulcus of matrix of nail, 355  
   scleral, inner, 410  
   spiralis internus, 446  
 Superficial plexus of cornea, 412  
 Superior nasal artery of retina, 427  
   vein, 427  
     papillary artery, 426  
     vein, 426  
 Suprarenal glands, 301  
   blood-vessels of, 303  
   nerves of, 304  
   technic for, 305  
 Suspensory ligament of lens, 428  
 Sustentacular cells, 85, 224, 334  
   fiber of Deiters' cells, 450  
 Sweat-glands, 357  
   nerves of, 358  
 Sympathetic ganglia, 140, 385  
 TACTILE papillæ, 345  
 Tæniæ coli, 236  
   of large intestine, 250  
 Tapetum cellulolum, 413  
   fibrosum, 413  
 Taste-buds, 223  
 Taste-pore, 224  
 Teasing, 20  
 Technic, microscopic, introduction to, 17  
 Teeth, 213  
   adult, structure of, 213  
   auditory, 446  
   development of, 217  
   pulp of, 215  
 Tegmental cells, 224  
 Teichmann's crystals, 169  
   isolation of, 207  
 Tela submucosa, 212  
 Telodendria, 135  
   of nerve-fibers ending in muscle tissue, 147  
 Telodendrion, 147, 151  
 Telolemma nuclei, 148  
 Telophases, 57, 64  
 Temperature, effects of, on tissues, 27  
 Tendons, 96  
   bundles, primary, 96  
     secondary, 97  
   fasciculi, 96  
   spindle, Golgi, 162  
 Tenon's capsule, 409  
 Terminal disc of Merkel, 127

- Terminal ledges, 80  
 nodule of spermatozome, 323
- Testes, 324  
 blood-vessels of, 329  
 lymphatics of, 329  
 nerve-supply of, 329  
 technic of, 340
- Theca folliculi, 309
- Thoma's ampullæ, 182
- Thymus gland, 188
- Thyroid gland, 284
- Tigroid granules, 134
- Tissue, 73  
 adipose, 99  
   stains for, 119  
 connective, 89  
   areolar, 93  
   cellular elements of, 94  
   ground-substance of, 93  
   matrix of, 93  
   fibrous, 93  
   mucous, 92  
   Ranvier's method for examination of, 117  
   reticular, 92  
   technic of, 117  
 effects of temperature on, 27  
 epithelial, 74  
 erectile, of penis, 333  
 fibrous, elastic, 98  
 frozen with carbon dioxid, cutting of, 35, 36  
 lymphoid, 177  
 muscular, 123  
   technic of, 132  
 nervous, 133  
   technic of, 164
- Toluol as clearing fluid, 47
- Tomes' granular layer, 220  
 processes, 218
- Tongue, 221  
 lymph-follicles of, 225
- Tonsils, lymph-follicles of, 225
- Tooth-pulp, 215
- Trabeculæ of liver, 258
- Trachea, 276
- Transitional eosinophile cells, 187
- Transverse disc, 127  
 membrane of Krause, 127
- Triangular cells of cerebral cortex, 376
- Trophoplasts, 347
- Trypsin digestion for differentiating connective and elastic tissues, 118
- Tubular glands, 82. See also *Glands, tubular*.
- Tubule, dentinal, 214  
 intermediate, of pancreas, 266  
 straight collecting, of kidney, 288  
 uriniferous, 287, 293  
   schematic diagram of, 297
- Tubuli recti of testis, 325
- Tunica albuginea, 84, 324  
 dartos, 346  
 externa of eye, 407  
 fibrosa oculi, 407, 409  
 interna of eye, 407, 418
- Tunica media of eye, 407, 412  
 mucosa of intestine, 236  
 propria of oral cavity, 211  
 sclerotica, 407, 409. See also *Sclera*.  
 vaginalis, 324  
 vasculosa, 324  
   of eye, 407, 412
- Tunnel of Corti, 448
- Tunnel-fibers, 452
- Türk's column, 370
- Tympanic investing layer of basilar membrane, 447  
 membrane, 436  
 layers of, 436
- Tympanum, 437
- Tyson's glands, 334
- UNDULATING membrane of spermatozome, 323
- Unstriated muscle-cell, 123
- Ureter, 299, 300
- Urethra, epithelium of, 333  
 submucosa of cavernous portion of, 333
- Urinary organs, 287  
 technic for, 305
- Uriniferous tubules, 287, 293  
 schematic diagram of, 297
- Uterus, 317  
 blood supply of, 319  
 layers of, 318  
 lymphatics of, 319  
 nerve supply of, 320  
 technic of, 340
- Utriculosaccular duct, 440
- Utriculus, 440, 441, 454  
 wall of, 442
- VACUOLES, 54  
 secretion, 259
- Vagina, 320  
 sensory nerve-endings in, 322  
 technic of, 340  
 vestibule of, 322
- Valvulæ conniventes, 236
- Van Gieson's picric-acid-fuchsin stain, 399
- Vas aberrans Halleri, 328  
 deferens, 329  
 epididymidis, 326, 328  
 spirale, 447
- Vasa afferentia, 178, 296  
 efferentia, 178, 325, 327  
 recta spuria, 297
- Vascular canals, 103  
 papillæ, 345  
 system, 190  
 tunic of eye, 407, 412
- Vater-Pacinian corpuscles, 157
- Veins, 197  
 central, 258  
 intralobular, 258, 261, 298  
 portal, 260  
 precapillary, 197  
 smaller, 197  
 valves of, 198

- Venæ arciformes, 298  
   stellatæ, 298  
   vorticosæ, 413  
 Ventrolateral column, 367  
 Ventromesial column, 367  
 Venulæ rectæ, 298  
 Vesicula prostatica, 332  
 Vestibular membrane, 444, 447  
 Vestibule of ear, 439  
   of nasal cavity, 456  
   of vagina, 322  
 Villi of mucous membrane of small intestine, 243  
   of small intestine, lacteals of, 253  
 Virchow's bone corpuscles, 104  
   isolation of, 123  
 Virtual image, 19  
 Visual cells, 418  
 Vitreous body, 407, 427  
   membrane, 412, 414  
 Volkmann's canals, 106  
 von Ebner's process of decalcification, 122  
 von Koch's technic for bone, 123
- WAGNER'S spot, 306  
 Wandering cells, 53, 94, 96  
 Water, distilled, for fixing paraffin sections to slide, 38
- Weigert's methods for demonstration of medullary sheath, 397, 398  
   picrocarmin, 43  
 Wharton's jelly, 92  
 White blood-corpuscles, 173  
   fibers, 90  
   fibrocartilage, 102  
   rami communicantes, 387  
   fibers, 387  
   substance of spinal cord, 365  
 Wirsungian duct, 265  
 Wolfian duct, 322
- XYLOL as clearing fluid, 47  
   as intermediate fluid, 26
- YELLOW bone-marrow, 185, 188  
 Yolk granules, 311
- ZENKER'S fluid, 25  
 Zinn's arterial circle, 426  
   zonule, 428  
 Zona pellucida, 311  
 Zonula ciliaris, 407, 428  
 Zonule of Zinn, 428







---

---

# Catalogue <sup>of</sup> the Medical Publications

---

---

OF

---

---

## W. B. SAUNDERS & COMPANY

---

---

PHILADELPHIA    3 3 3 3 3 3 3    LONDON  
925 Walnut Street    3 3 3 3 3 3 3    161 Strand

---

---

Arranged Alphabetically and Classified under Subjects  
See pages 38, 39 for a List of Contents classified according to subjects

---

---

**T**HE books advertised in this Catalogue as being *sold by subscription* are usually to be obtained from traveling solicitors, but they will be sent direct from the office of publication (charges of shipment prepaid) upon receipt of the prices given. All the other books advertised are commonly for sale by booksellers in all parts of the United States; but books will be sent to any address, carriage prepaid, on receipt of the published price.

Money may be sent at the risk of the publisher in either of the following ways: A postal money order, an express money order, a bank check, and in a registered letter. Money sent in any other way is at the risk of the sender.

**SPECIAL OFFER.** To physicians of approved credit books will be sent, postpaid, on the following terms: \$5.00 cash upon delivery of books, and monthly payments of \$5.00 thereafter until full amount is paid. Physicians not known to the house will be expected to furnish the names of satisfactory references. Any one or two volumes will be sent on thirty days' time to those who do not care to make a larger purchase.

---

---

### LATEST PUBLICATIONS

- American Illustrated Medical Dictionary.** See page 6.  
**International Text-Book of Surgery.** See page 17.  
**Böhm, Davidoff, and Huber's Histology.** See page 9.  
**Salinger and Kalteyer's Modern Medicine.** See page 25.  
**Da Costa's Modern Surgery—Third (Revised) Edition.** See page 11.  
**Stengel's Pathology—Third (Revised) Edition.** See page 28.  
**American Text-Book of Physiology—Second (Revised) Ed.** Page 5.  
**Friedrich and Curtis on Nose, Throat, and Ear.** See page 13.  
**Leroy's Histology.** See page 19.  
**Ogden on the Urine.** See page 23.  
**Pyle's Personal Hygiene.** See page 24.  
**Stoney's Surgical Technic for Nurses.** See page 30.  
**Hyde and Montgomery's Syphilis and Venereal Diseases—Revised and Enlarged Edition.** See page 16.  
**Garrigues' Diseases of Women—Third (Revised) Edition.** Page 13.  
**Levy and Klemperer's Clinical Bacteriology.** See page 20.  
**Scudder's Treatment of Fractures.** See page 26.  
**Senn's Tumors—Second (Revised) Edition.** See page 27.  
**Beck on Fractures.** See page 8.  
**Saunders' Medical Hand-Atlases.** See pages 33, 34, 35.  
**American Pocket Med. Dictionary—Third (Revised) Ed.** Page 6.



# SAUNDERS' AMERICAN TEXT-BOOKS

**T**HE extraordinary success attending the publication of the American Text-Books is a source of gratification alike to the Editors and to the Publishers. The advent of each successive volume of the series has been signalized by the most flattering comment from both the Profession and the Press. The high consideration accorded these text-books, and their attainment to an authoritative position in current medical literature, attest the fact that the publication of the series has become a matter of international interest, expressed by the demand for these publications from all parts of the civilized world.

In the short period that has elapsed since the issue of the first volume of the series

## Over One Hundred Thousand Copies

of the various text-books have found their way into the hands of students and into the libraries of physicians, and the American Text-Books have been adopted and recommended as text-books and books of reference in

## 148 Leading Medical Schools and Universities

of the United States and Canada. The increasing favor in which the books are held, as they become better known and consulted, clearly indicates that much larger sales are yet to come, and that the time is not far distant when the American Text-Books will be "required" for study in every important medical center.

Illustrated Catalogue of the "American Text-Books" sent free upon application

## An American Text-Book of Applied Therapeutics.

By 43 Distinguished Practitioners and Teachers. Edited by JAMES C. WILSON, M.D., Professor of the Practice of Medicine and of Clinical Medicine in the Jefferson Medical College, Philadelphia. One handsome imperial octavo volume of 1326 pages. Illustrated. Cloth, \$7.00 net; Sheep or Half Morocco, \$8.00 net. *Sold by Subscription.*

"As a work either for study or reference it will be of great value to the practitioner, as it is virtually an exposition of such clinical therapeutics as experience has taught to be of the most value. Taking it all in all, no recent publication on therapeutics can be compared with this one in practical value to the working physician."—*Chicago Clinical Review.*

## An American Text-Book of the Diseases of Children. Second Edition, Revised.

By 65 Eminent Contributors. Edited by LOUIS STARR, M.D., Consulting Pediatricist to the Maternity Hospital, etc.; assisted by THOMPSON S. WESTCOTT, M.D., Attending Physician to the Dispensary for Diseases of Children, Hospital of the University of Pennsylvania. In one handsome imperial octavo volume of 1244 pages, profusely illustrated. Cloth, \$7.00 net; Sheep or Half Morocco, \$8.00 net. *Sold by Subscription.*

"This is far and away the best text-book on children's diseases ever published in the English language, and is certainly the one which is best adapted to American readers. We congratulate the editor upon the result of his work, and heartily commend it to the attention of every student and practitioner."—*American Journal of the Medical Sciences.*

## An American Text-Book of Diseases of the Eye, Ear, Nose, and Throat.

By 58 Prominent Specialists. Edited by G. E. DE SCHWEINITZ, M.D., Professor of Ophthalmology in the Jefferson Medical College, Philadelphia; and B. ALEXANDER RANDALL, M.D., Professor of Diseases of the Ear in the University of Pennsylvania. Imperial octavo, 1251 pages; 766 illustrations, 59 of them in colors. Cloth, \$7.00 net; Sheep or Half Morocco, \$8.00 net. *Sold by Subscription.*

The present work is the only book ever published embracing diseases of the intimately related organs of the eye, ear, nose, and throat. Its special claim to favor is based on encyclopedic, authoritative, and practical treatment of the subjects. It is essentially a text-book on the one hand, and, on the other, a volume of reference to which the practitioner may turn for a series of articles written by men who are authorities on the subjects portrayed by them. Therefore, the practical side of the question has been brought into prominence, but never to the neglect of pathology or the important facts in the special chapters on Embryology, Anatomy, and Physiology.

"No one will gainsay the general excellence of the work which it is our pleasure to review, for the volume is a most delightful exposition of the subjects. The articles are complete, forceful, and 'snappy.' The reviewer is impressed by the excellent subdivision of the subjects and by the admirable judgment shown by the authors in their choice of collaborators. While the work is essentially a text-book, it may be truly said to be a volume of reference containing a series of articles, written by men who are authorities on the subjects portrayed by them."—*American Journal of the Medical Sciences.*

"This text-book is the most valuable single volume that has ever appeared on these branches of medicine."—*Annals of Ophthalmology.*

## An American Text-Book of Genito-Urinary and Skin Diseases.

By 47 Eminent Specialists and Teachers. Edited by L. BOLTON BANGS, M.D., Professor of Genito-Urinary Surgery, University and Bellevue Hospital Medical College, New York; and W. A. HARDAWAY, M.D., Professor of Diseases of the Skin, Missouri Medical College. Imperial octavo volume of 1229 pages, with 300 engravings and 20 full-page colored plates. Cloth, \$7.00 net; Sheep or Half Morocco, \$8.00 net. *Sold by Subscription.*

"This voluminous work is thoroughly up to date, and the chapters on genito-urinary diseases are especially valuable. The illustrations are fine and are mostly original. The section on dermatology is concise and in every way admirable."—*Journal of the American Medical Association.*

"This volume is one of the best yet issued of the publisher's series of 'American Text-Books.' The list of contributors represents an extraordinary array of talent and extended experience. The book will easily take the place in comprehensiveness and value of the half dozen or more costly works on these subjects which have heretofore been necessary to a well-equipped library."—*New York Polyclinic.*

## An American Text-Book of Gynecology, Medical and Surgical. Second Edition, Revised.

By 10 of the Leading Gynecologists of America. Edited by J. M. BALDY, M.D., Professor of Gynecology in the Philadelphia Polyclinic, etc. Handsome imperial octavo volume of 718 pages, with 341 illustrations in the text and 38 colored and half-tone plates. Cloth, \$6.00 net; Sheep or Half Morocco, \$7.00 net. *Sold by Subscription.*

"It is practical from beginning to end. Its descriptions of conditions, its recommendations for treatment, and above all the necessary technique of different operations, are clearly and admirably presented. . . . It is well up to the most advanced views of the day, and embodies all the essential points of advanced American gynecology. It is destined to make and to hold a place in gynecological literature which will be peculiarly its own."—*Medical Record*, New York.

## An American Text-Book of Legal Medicine and Toxicology.

Edited by FREDERICK PETERSON, M.D., Chief of Clinic, Nervous Department, College of Physicians and Surgeons, New York; and WALTER S. HAINES, M.D., Professor of Chemistry, Pharmacy, and Toxicology in Rush Medical College, Chicago. *In Preparation.*

## An American Text-Book of Obstetrics.

By 15 Eminent American Obstetricians. Edited by RICHARD C. NORRIS, M.D.; Art Editor, ROBERT L. DICKINSON, M.D. Handsome imperial octavo volume of 1014 pages, with nearly 900 beautiful colored and half-tone illustrations. Cloth, \$7.00 net; Sheep or Half Morocco, \$8.00 net. *Sold by Subscription.*

"Permit me to say that your American Text-Book of Obstetrics is the most magnificent medical work that I have ever seen. I congratulate you and thank you for this superb work, which alone is sufficient to place you first in the ranks of medical publishers."—ALEXANDER J. C. SKENE, *late Professor of Gynecology in the Long Island College Hospital, Brooklyn, N. Y.*

"This is the most sumptuously illustrated work on midwifery that has yet appeared. In the number, the excellence, and the beauty of production of the illustrations it far surpasses every other book upon the subject. This feature alone makes it a work which no medical library should omit to purchase."—*British Medical Journal.*

## An American Text-Book of Pathology.

Edited by LUDVIG HEKTOEN, M.D., Professor of Pathology in Rush Medical College, Chicago; and DAVID RIESMAN, M.D., Demonstrator of Pathologic Histology in the University of Pennsylvania.

*In Preparation.*

### CONTRIBUTORS.

LEWELLYS F. BARKER, Chicago.  
H. D. BEVEA, Philadelphia.  
RICHARD C. CABOT, Boston.  
WILLIAM S. CARTER, Galveston.  
JOSEPH COLLINS, New York.  
LUDVIG HEKTOEN, Chicago.  
WARD A. HOLDEN, New York.  
HARRY F. LEWIS, Chicago.  
JOSEPH MCFARLAND, Philadelphia.  
LOUIS J. MITCHELL, Chicago.

FRANK H. MONTGOMERY, Chicago.  
A. G. NICHOLS, Montreal.  
A. P. OHLMACHER, Gallipolis, Ohio.  
CHAS. B. PENROSE, Philadelphia.  
DAVID RIESMAN, Philadelphia.  
JAMES A. SPALDING, Portland, Maine.  
A. A. STEVENS, Philadelphia.  
V. C. VAUGHAN, Ann Arbor.  
J. COLLINS WARREN, Boston.  
ALFRED S. WARTHIN, Ann Arbor.

## An American Text-Book of Physiology.

By 10 of the Leading Physiologists of America. Edited by WILLIAM H. HOWELL, PH.D., M.D., Professor of Physiology in the Johns Hopkins University, Baltimore, Md. Two royal octavo volumes of about 600 pages each. Fully illustrated.

Per volume: Cloth, \$3.00 net; Sheep or Half Morocco, \$3.75 net.

### Second Edition, Revised, in Two Volumes.

The entire book has been carefully revised in the light of the latest progress in physiology. Many changes have been made throughout the volume and numerous illustrations have been added. The section dealing with the Central Nervous System has been entirely rewritten and a chapter on Physical Chemistry has been added.

"We can commend it most heartily, not only to all students of physiology, but to every physician and pathologist, as a valuable and comprehensive work of reference, written by men who are of eminent authority in their own special subjects."—*London Lancet*.

"To the practitioner of medicine and to the advanced student this volume constitutes, we believe, the best exposition of the present status of the science of physiology in the English language."—*American Journal of the Medical Sciences*.

## An American Text-Book of Surgery. Third Edition.

By 11 Eminent Professors of Surgery. Edited by WILLIAM W. KEEN, M.D., LL.D., F.R.C.S. (Hon.); and J. WILLIAM WHITE, M.D., PH.D. Handsome octavo volume of 1230 pages, with 496 wood-cuts in the text and 37 colored and half-tone plates. Thoroughly revised and enlarged, with a section devoted to "The Use of the Röntgen Rays in Surgery." Cloth, \$7.00 net; Sheep or Half Morocco, \$8.00 net.

### Over 35,000 Copies Sold.

"Personally, I should not mind it being called **THE** TEXT-BOOK (instead of **A** TEXT-BOOK), for I know of no single volume which contains so readable and complete an account of the science and art of Surgery as this does."—EDMUND OWEN, F.R.C.S., *Member of the Board of Examiners of the Royal College of Surgeons, England*.

"If this text-book is a fair reflex of the present position of American surgery, we must admit it is of a very high order of merit, and that English surgeons will have to look very carefully to their laurels if they are to preserve a position in the van of surgical practice."—*London Lancet*.

"The work is without doubt the best single-volume surgery extant and will remain the leading text-book as long as it is kept up to its present high standard."—*The Clinical Review*, Chicago.

Illustrated Catalogue of the "American Text-Books" free on application.

THE NEW STANDARDTHE NEW STANDARD

# The American Illustrated Medical Dictionary.

For Practitioners and Students. A Complete Dictionary of the Terms used in Medicine, Surgery, Dentistry, Pharmacy, Chemistry, and the kindred branches, including much collateral information of an encyclopedic character, together with new and elaborate tables of Arteries, Muscles, Nerves, Veins, etc.; of Bacilli, Bacteria, Micrococci, Streptococci; Eponymic Tables of Diseases, Operations, Signs and Symptoms, Stains, Tests, Methods of Treatment, etc., etc. By W. A. NEWMAN DORLAND, A.M., M.D., Editor of the "American Pocket Medical Dictionary." Handsome large octavo, nearly 800 pages, bound in full flexible leather. Price, \$4.50 net; with thumb index, \$5.00 net.

**Gives a Maximum Amount of Matter in a Minimum Space and at the Lowest Possible Cost.**

This is an entirely new and unique work, intended to meet the need of practitioners and students for a complete up-to-date dictionary of moderate price. It contains more than twice the material in the ordinary students' dictionary, and yet, by the use of a clear, condensed type and thin paper of the finest quality, it forms an extremely handy volume only  $1\frac{3}{4}$  inches in thickness. It is a beautiful specimen of the book-maker's art. It is bound in full flexible leather, and is just the kind of a book that a man will want to keep on his desk for constant reference. The book makes a special feature of the newer words, and defines hundreds of important terms not to be found in any other dictionary. It is especially full in the matter of tables, containing more than a hundred of great practical value. An important feature of the book is its handsome illustrations and colored plates drawn especially for the work, including new colored plates of Arteries, Muscles, Nerves, Veins, Bacteria, Blood, etc.—twenty-four in all. The book will appeal to both practitioners and students, since, besides a complete vocabulary, it gives to the more important subjects extended consideration of an encyclopedic character. This new work has been aptly termed by a competent critic "The New Standard."

## The American Pocket Medical Dictionary.

Edited by W. A. NEWMAN DORLAND, M.D., Assistant Obstetrician to the Hospital of the University of Pennsylvania; Fellow of the American Academy of Medicine. Containing the pronunciation and definition of the principal words used in medicine and kindred sciences, with 64 extensive tables. Handsomely bound in flexible leather, with gold edges. Price \$1.00 net; with thumb index, \$1.25 net.

### THIRD EDITION, REVISED.

This is the ideal pocket lexicon. It is complete, defining all the terms of modern medicine, and forming an unusually complete vocabulary. It gives the pronunciation of all the terms. It makes a special feature of the newer words neglected by other dictionaries. It contains a wealth of anatomical tables of special value to students. It forms a handy volume, indispensable to every medical man.

"This dictionary is, beyond all doubt, the best one among pocket dictionaries."—*St. Louis Medical and Surgical Journal*.

"This is a handy pocket dictionary, which is so full and complete that it puts to shame some of the more pretentious volumes."—*Journal of the American Medical Association*.

## The American Year-Book of Medicine and Surgery.

A Yearly Digest of Scientific Progress and Authoritative Opinion in all branches of Medicine and Surgery, drawn from journals, monographs, and text-books of the leading American and Foreign authors and investigators. Arranged with critical editorial comments, by eminent American specialists, under the editorial charge of GEORGE M. GOULD, M.D. Year-Book of 1900 in two volumes—Vol. I., including *General Medicine*; Vol. II., *General Surgery*. Per volume: Cloth, \$3.00 net; Half Morocco, \$3.75 net. *Sold by Subscription.*

“It is difficult to know which to admire most—the research and industry of the distinguished band of experts whom Dr. Gould has enlisted in the service of the Year-Book, or the wealth and abundance of the contributions to every department of science that have been deemed worthy of analysis. . . . It is much more than a mere compilation of abstracts, for, as each section is entrusted to experienced and able contributors, the reader has the advantage of certain critical commentaries and expositions . . . proceeding from writers fully qualified to perform these tasks. . . . It is emphatically a book which should find a place in every medical library.”—*London Lancet.*

## Abbott on Transmissible Diseases.

The Hygiene of Transmissible Diseases: their Causation, Modes of Dissemination, and Methods of Prevention. By A. C. ABBOTT, M.D., Professor of Hygiene and Bacteriology, University of Pennsylvania. Octavo, 311 pages, with numerous illustrations. Cloth, \$2.00 net.

It is not the purpose of this work to present the subject of Hygiene in the comprehensive sense ordinarily implied by the word, but rather to deal directly with but a section, certainly not the least important, of the subject—viz., that embracing a knowledge of the preventable specific diseases. Incidentally there are discussed those numerous and varied factors that have not only a direct bearing upon the incidence and suppression of such diseases, but are of general sanitary importance as well.

“The work is admirable in conception and no less so in execution. It is a practical work, simply and lucidly written, and it should prove a most helpful aid in that department of medicine which is becoming daily of increasing importance and application—namely, prophylaxis.”—*Philadelphia Medical Journal.*

## Anders' Practice of Medicine. Fourth Revised Edition.

A Text-Book of the Practice of Medicine. By JAMES M. ANDERS, M.D., PH.D., LL.D., Professor of the Practice of Medicine and of Clinical Medicine, Medico-Chirurgical College, Philadelphia. In one handsome octavo volume of 1292 pages, fully illustrated.

Cloth, \$5.50 net; Sheep or Half Morocco, \$6.50 net.

### FOUR EDITIONS IN THREE YEARS.

The third edition of this work was so quickly exhausted as to render it unnecessary to make extensive alterations in the present issue. Numerous changes in the text, however, have been made in all parts, and considerable new matter has been added, with a view to enhancing the general usefulness of the work. A number of subjects have been written anew, among which some of the more important are Sprue, Ileocolitis in Children, and Acute Cholecystitis. The modern methods of diagnosis, as well as the most recent advances in therapeutics, have been introduced.

“It is an excellent book,—concise, comprehensive, thorough, and up to date. It is a credit to you; but, more than that, it is a credit to the profession of Philadelphia—to us.”—JAMES C. WILSON, *Professor of the Practice of Medicine and Clinical Medicine, Jefferson Medical College, Phila.*

“The book is a good one, and for the average general practitioner will be of distinct service for its detail of treatment.”—*Bulletin of the Johns Hopkins Hospital.*

**Ashton's Obstetrics. Fourth Edition, Revised.**[See *Saunders' Question-Compends*, page 37.]**Baldy—American Text-Book of Gynecology.**[See *American-Text-Book of Gynecology*, page 4.]**Ball's Bacteriology. Fourth Edition, Revised.**[See *Saunders' Question-Compends*, page 37.]**Bangs and Hardaway—American Text-Book of Genito-Urinary and Skin Diseases.**[See under *American Text-Books* on page 4.]**Bastin's Botany.**

Laboratory Exercises in Botany. By EDSON S. BASTIN, M.A., late Professor of Materia Medica and Botany, Philadelphia College of Pharmacy. Octavo, 536 pages, with 87 plates. Cloth, \$2.00 net.

"It is unquestionably the best text-book on the subject that has yet appeared. The work is eminently a practical one. We regard the issuance of this book as an important event in the history of pharmaceutical teaching in this country, and predict for it an unqualified success."—*Alumni Report to the Philadelphia College of Pharmacy.*

**Beck on Fractures.**

Fractures. By CARL BECK, M.D., Surgeon to St. Mark's Hospital and the New York German Poliklinik, etc. With an appendix on the Practical Use of the Röntgen Rays. 335 pages, 170 illustrations. Cloth, \$3.50 net.

**Just Issued.**

In this book the author devotes particular attention to the value of Röntgen rays in the diagnosis of different varieties of fractures. Publications on this subject hitherto have not claimed to be more than tentative sketches. This book represents an effort to embody in a systematic treatise the important essentials of this subject, based on the extensive experience of the author in X-ray work. This comparatively new field Dr. Beck has made practically his own, and the large number of skiagraphs contained in the book have been pronounced by competent critics the finest specimens of such work in existence.

"This work is important as being the first attempt to bring before the profession in a systematic way the study of fractures by means of the Röntgen rays. The use of the Röntgen rays with its technique is fully explained, and the practical points are brought out with a thoroughness which merits high praise."—*Medical Record.*

**Beck's Surgical Asepsis.**

A Manual of Surgical Asepsis. By CARL BECK, M.D., Surgeon to St. Mark's Hospital and the New York German Poliklinik, etc. 306 pages; 65 text-illustrations and 12 full-page plates. Cloth, \$1.25 net.

**Boisliniere's Obstetric Accidents, Emergencies, and Operations.**

Obstetric Accidents, Emergencies, and Operations. By L. CH. BOISLINIERE, M.D., late Emeritus Professor of Obstetrics, St. Louis Medical College. 381 pages, handsomely illustrated. Cloth, \$2.00 net.

## **Böhm, Davidoff and Huber's Histology.**

A Text-Book of Human Histology. Including Microscopic Technic. By DR. A. A. BÖHM and DR. M. VON DAVIDOFF, of Munich, and G. CARL HUBER, M.D., Junior Professor of Anatomy and Director of Histological Laboratory, University of Michigan. Handsome octavo of 503 pages, with 351 beautiful original illustrations. Cloth, \$3.50 net.

**Just Issued.**

The work of Drs. Böhm and Davidoff is well known in the German edition, and has been considered one of the most practically useful books on the subject of human histology. This American edition, though based upon the second revised German edition, has been in great part rewritten and very much enlarged by Dr. Huber, who has also added over 100 original illustrations. The book contains particularly full and explicit instructions in the matter of technic, and it will undoubtedly prove of the utmost value to students and practical workers in the histological laboratory.

## **Brockway's Medical Physics. Second Edition, Revised.**

[See *Saunders' Question-Compends*, page 37.]

## **Butler's Materia Medica, Therapeutics, and Pharmacology. Third Edition, Revised.**

A Text-Book of Materia Medica, Therapeutics, and Pharmacology. By GEORGE F. BUTLER, PH.G., M.D., Professor of Materia Medica and of Clinical Medicine in the College of Physicians and Surgeons, Chicago. Octavo, 874 pages, illustrated.

Cloth, \$4.00 net; Sheep or Half Morocco, \$5.00 net.

A clear, concise, and practical text-book, adapted for permanent reference no less than for the requirements of the class-room.

The recent important additions made to our knowledge of the physiological action of drugs are fully discussed in the present edition. The book has been thoroughly revised and many additions have been made.

"Taken as a whole, the book may fairly be considered as one of the most satisfactory of any single-volume works on materia medica in the market."—*Journal of American Medical Association*.

## **Cerna on the Newer Remedies. Second Edition, Revised.**

Notes on the Newer Remedies, their Therapeutic Applications and Modes of Administration. By DAVID CERNA, M.D., PH.D., Demonstrator of Physiology in the Medical Department of the University of Texas. Rewritten and greatly enlarged. Post-octavo, 253 pages.

Cloth, \$1.00 net.

## **Chapin on Insanity.**

A Compendium of Insanity. By JOHN B. CHAPIN, M.D., LL.D., Physician-in-Chief, Pennsylvania Hospital for the Insane; Honorary Member of the Medico-Psychological Society of Great Britain, of the Society of Mental Medicine of Belgium, etc. 12mo, 234 pages, illustrated.

Cloth, \$1.25 net.

"The practical parts of Dr. Chapin's book are what constitute its distinctive merit. We desire especially to call attention to the fact that on the subject of therapeutics of insanity the work is exceedingly valuable. It is not a made book, but a genuine condensed thesis, which has all the value of ripe opinion and all the charm of a vigorous and natural style."—*Philadelphia Medical Journal*.

## Chapman's Medical Jurisprudence and Toxicology. Second Edition, Revised.

Medical Jurisprudence and Toxicology. By HENRY C. CHAPMAN, M.D., Professor of Institutes of Medicine and Medical Jurisprudence in the Jefferson Medical College of Philadelphia. 254 pages, with 55 illustrations and 3 full-page plates in colors. Cloth, \$1.50 net.

"The best book of its class for the undergraduate that we know of."—*New York Medical Times*.

## Church and Peterson's Nervous and Mental Diseases. Second Edition.

Nervous and Mental Diseases. By ARCHIBALD CHURCH, M.D., Professor of Nervous and Mental Diseases, and Head of the Neurological Department, Northwestern University Medical School, Chicago; and FREDERICK PETERSON, M.D., Clinical Professor of Medical Diseases, Woman's Medical College, New York; Chief of Clinic, Nervous Department, College of Physicians and Surgeons, New York. Handsome octavo volume of 843 pages, profusely illustrated.

Cloth, \$5.00 net; Sheep or Half Morocco, \$6.00 net.

This book is intended to furnish students and practitioners with a practical working knowledge of nervous and mental diseases. Written by men of wide experience and authority, it presents the many recent additions to the subject. The book is not filled with an extended dissertation on anatomy and pathology, but, treating these points in connection with special conditions, it lays particular stress on methods of examination, diagnosis, and treatment. In this respect the work is unusually complete and valuable, laying down the definite courses of procedure which the authors have found most generally satisfactory.

"The work is what it aims to be—an epitome of what is to-day known of nervous diseases, prepared for the student and practitioner in the light of the authors' experience. From article to article there is full consideration, and from page to page almost uniform excellence. . . . We believe that no work having at the same time the merit of sound subject-matter presents the difficult subject of insanity in such a reasonable and readable way."—*Chicago Medical Recorder*.

"The volume remains a compact, thorough, and modern presentation of the most recent conceptions of nervous and mental diseases. To be clear, brief, and thorough, and at the same time authoritative, are merits which ensure popularity. The medical student and practitioner will find in this volume a ready and reliable resource."—*New York Medical Journal*.

## Clarkson's Histology.

A Text-Book of Histology, Descriptive and Practical. By ARTHUR CLARKSON, M.B., C.M. Edin., formerly Demonstrator of Physiology in the Owen's College, Manchester; late Demonstrator of Physiology in Yorkshire College, Leeds. Large octavo, 554 pages; 22 engravings in the text and 174 beautifully colored original illustrations.

Cloth, strongly bound, \$4.00 net.

"The work must be considered a valuable addition to the list of available text-books, and is to be highly recommended."—*New York Medical Journal*.

"This is one of the best works for students we have ever noticed. We predict that the book will attain a well-deserved popularity among our students."—*Chicago Medical Recorder*.

## Cohen and Eshner's Diagnosis. Second Edition, Revised.

[See *Saunders' Question-Compends*, page 37.]

**Corwin's Physical Diagnosis. Third Edition, Revised.**

Essentials of Physical Diagnosis of the Thorax. By ARTHUR M. CORWIN, A.M., M.D., Instructor in Physical Diagnosis in Rush Medical College, Chicago; 219 pages, illustrated. Cloth, \$1.25 net.

"It is excellent. The student who shall use it as his guide to the careful study of physical exploration upon normal and abnormal subjects can scarcely fail to acquire a good working knowledge of the subject."—*Philadelphia Polyclinic*.

"A most excellent little work. It brightens the memory of the differential diagnostic signs, and it arranges orderly and in sequence the various objective phenomena to logical solution of a careful diagnosis."—*Journal of Nervous and Mental Diseases*.

**Cragin's Gynecology. Fourth Edition, Revised.**

[See *Saunders' Question-Compends*, page 37.]

**Crookshank's Bacteriology. Fourth Edition, Revised.**

A Text-Book of Bacteriology. By EDGAR M. CROOKSHANK, M.B., Professor of Comparative Pathology and Bacteriology, King's College, London. Octavo volume of 700 pages, with 273 engravings and 22 original colored plates. Cloth, \$6.50 net; Half Morocco, \$7.50 net.

"To the student who wishes to obtain a good *résumé* of what has been done in bacteriology, or who wishes an accurate account of the various methods of research, the book may be recommended with confidence that he will find there what he requires."—*London Lancet*.

**DaCosta's Surgery. Third Edition, Revised.**

Modern Surgery, General and Operative. By JOHN CHALMERS DA COSTA, M.D., Professor of Practice of Surgery and Clinical Surgery, Jefferson Medical College, Philadelphia; Surgeon to the Philadelphia Hospital, etc. Handsome octavo volume of 1117 pages, profusely illustrated. Cloth, \$5.00 net; Sheep or Half Morocco, \$6.00 net.

**Enlarged by Over 200 Pages with More Than 100 New Illustrations.**

The remarkable success attending DaCosta's "Manual of Surgery," and the general favor with which it has been received, have led the author in this revision to produce a complete treatise on modern surgery along the same lines that made the former editions so successful. The book has been entirely rewritten and enlarged by over 200 pages. More than 100 new illustrations have been added. The old editions have long been a favorite not only with students and teachers, but also with practising physicians and surgeons, and it is believed that the present work will find an even wider field of usefulness.

"The author has presented concisely and accurately the principles of modern surgery. The book is a valuable one, which can be recommended to students, and is of great value to the general practitioner."—*American Journal of the Medical Sciences*.

"We know of no small work on surgery in the English language which so well fulfils the requirements of the modern student."—*Medico-Chirurgical Journal*, Bristol, England.

**Davis's Obstetric Nursing.**

Obstetric and Gynecologic Nursing. By EDWARD P. DAVIS, A.M., M.D., Professor of Obstetrics in the Jefferson Medical College and Philadelphia Polyclinic; Obstetrician and Gynecologist to the Philadelphia Hospital. 12mo volume of 350 pages, fully illustrated.

*Ready Shortly.*

**De Schweinitz on Diseases of the Eye.** Third Edition, Revised.

Diseases of the Eye. A Handbook of Ophthalmic Practice. By G. E. DE SCHWEINITZ, M.D., Professor of Ophthalmology in the Jefferson Medical College, Philadelphia, etc. Handsome royal octavo volume of 696 pages, with 256 fine illustrations and 2 chromo-lithographic plates. Cloth, \$4.00 net; Sheep or Half Morocco, \$5.00 net.

The third edition of this book, destined, it is hoped, to meet the favorable reception accorded to its predecessors, has been revised thoroughly and much new matter introduced. Particular attention has been given to the important relations which micro-organisms bear to many ocular disorders. Several new paragraphs appear, among which are considerations of new forms of Conjunctivitis and Corneal Affection, Röntgen Rays for Detecting Foreign Bodies in the Vitreous, Eucain, and Holocain. Certain articles, as well as a portion of the chapter on Operations, have been largely rewritten. New illustrations have been added.

"It is hardly too much to say that for the student and practitioner beginning the study of Ophthalmology, it is the best single volume at present published."—*Medical News*.

"A clearly written, comprehensive manual. One which we can commend to students as a reliable text-book, written with an evident knowledge of the wants of those entering upon the study of this special branch of medical science."—*British Medical Journal*.

"A work that will meet the requirements not only of the specialist, but of the general practitioner in a rare degree. I am satisfied that unusual success awaits it."—WILLIAM PEPPER, M.D., *Professor of the Theory and Practice of Medicine and Clinical Medicine, University of Pennsylvania*.

**De Schweinitz and Randall—American Text-Book of Diseases of the Eye, Ear, Nose, and Throat.**

[See *American Text-Book of Diseases of the Eye, Ear, Nose, and Throat*, page 3.]

**Dorland's Dictionaries.**

[See *American Illustrated Medical Dictionary* and *American Pocket Medical Dictionary* on page 6.]

**Dorland's Obstetrics.**

A Manual of Obstetrics. By W. A. NEWMAN DORLAND, M.D., Assistant Demonstrator of Obstetrics, University of Pennsylvania; Instructor in Gynecology in the Philadelphia Polyclinic. 760 pages; 163 illustrations in the text and 6 full-page plates. Cloth, \$2.50 net.

"By far the best book on this subject that has ever come to our notice."—*American Medical Review*.

"It has rarely been our duty to review a book which has given us more pleasure in its perusal and more satisfaction in its criticism. It is a veritable encyclopedic of knowledge, a gold mine of practical, concise thoughts."—*American Medico-Surgical Bulletin*.

**Dürck and Hektoen—Atlas of Pathologic Histology.**

[See *Saunders' Medical Hand-Atlases*, page 35.]

## Eichhorst's Practice of Medicine.

A Text-Book of the Practice of Medicine. By Dr. HERMAN EICHHORST, Professor of Special Pathology and Therapeutics and Director of the Medical Clinic, University of Zurich. Translated and edited by AUGUSTUS A. ESHNER, M.D., Professor of Clinical Medicine in the Philadelphia Polyclinic. *In Press.*

## Friedrich and Curtis on the Nose, Throat, and Ear.

Rhinology, Laryngology, and Otology and Their Significance in General Medicine. By DR. E. P. FRIEDRICH, of Leipzig. Edited by H. HOLBROOK CURTIS, M.D., Consulting Surgeon to the New York Nose and Throat Hospital. Octavo, 348 pages. Cloth, \$2.50 net.

### Just Issued.

In this work the author's object has been to point out the interdependence between disease of the entire organism and diseases of the nose, pharynx, larynx, and ear, and to incorporate the new discoveries of these specialties into the scheme of general medicine. He has endeavored to point out the means of an active co-operation between general medicine and the above-named specialties, and thus to bring to the attention of the general practitioner special symptoms and methods which should be of the greatest importance to him in the recognition and treatment of his cases.

## Frothingham's Guide for the Bacteriologist.

Laboratory Guide for the Bacteriologist. By LANGDON FROTHINGHAM, M.D.V., Assistant in Bacteriology and Veterinary Science, Sheffield Scientific School, Yale University. Illustrated. Cloth, 75 cts. net.

## Garrigues' Diseases of Women. Third Edition, Revised.

Diseases of Women. By HENRY J. GARRIGUES, A.M., M.D., Gynecologist to St. Mark's Hospital and to the German Dispensary, New York City. Octavo, 756 pages, with 367 engravings and colored plates. Cloth, \$4.50 net; Sheep or Half Morocco, \$5.50 net.

The entire work has been carefully and thoroughly revised; what seemed antiquated or of minor importance in a text-book has been left out; a large amount of new material has been incorporated, bringing the work absolutely up to date, and many new illustrations have been added.

"We think it one of the few really good books on gynecology for the general practitioner."—*New York Medical Journal.*

"Taken as a whole, the work is one of the most complete which we have seen printed in English."—*Bulletin of Johns Hopkins Hospital.*

"The work can be earnestly recommended as a faithful exponent of American gynecology, conceived in a spirit of moderation and conservatism."—*Medical Record.*

"It reflects the large experience of the author, both as a clinician and a teacher, and comprehends much not ordinarily found in text-books on gynecology. The book is one of the most complete treatises on gynecology that we have, dealing broadly with all phases of the subject."—*American Journal of the Medical Sciences.*

"One of the best text-books for students and practitioners which has been published in the English language; it is condensed, clear, and comprehensive. The profound learning and great clinical experience of the distinguished author find expression in this book in a most attractive and instructive form. Young practitioners to whom experienced consultants may not be available, will find in this book invaluable counsel and help."—THAD. A. REAMY, M.D., LL.D., *Professor of Clinical Gynecology, Medical College of Ohio.*

## Gleason's Diseases of the Ear. Second Edition, Revised.

[See Saunders' Question-Compends, page 37.]

## Golebiewski and Bailey—Atlas of Diseases Caused by Accidents.

[See Saunders' Medical Hand-Atlases, page 35.]

## Gould and Pyle's Curiosities of Medicine.

Anomalies and Curiosities of Medicine. By GEORGE M. GOULD, M.D., and WALTER L. PYLE, M.D. An encyclopedic collection of rare and extraordinary cases and of the most striking instances of abnormality in all branches of Medicine and Surgery, derived from an exhaustive research of medical literature from its origin to the present day, abstracted, classified, annotated, and indexed. Handsome imperial octavo volume of 968 pages, with 295 engravings in the text and 12 full-page plates.

**POPULAR EDITION: Cloth, \$3.00 net; Half Morocco, \$4.00 net.**

In view of the great success of this magnificent work, the publisher has decided to issue a "Popular Edition" at a price so low that it may be procured by every student and practitioner of medicine. Notwithstanding the great reduction in price, there will be no depreciation in the excellence of typography, paper, and binding that characterized the earlier editions.

"The authors have rendered a great service to writers and teachers, and many will have their labors greatly lightened by a reference to this storehouse of information."—*Journal of the American Medical Association*.

"The book is a monument of untiring energy, keen discrimination, and erudition. . . . We heartily recommend it to the profession."—*Lancet*, London.

"Drs. Gould and Pyle have evolved in this volume a monumental work of industry and patience and skill, and have contributed a priceless addition to the medical literature of the world."—*University Medical Magazine*.

## Grafstrom's Mechano-Therapy.

A Text-Book of Mechano-Therapy (Massage and Medical Gymnastics). By AXEL V. GRAFSTROM, B.Sc., M.D., late Lieutenant in the Royal Swedish Army; late House Physician City Hospital, Blackwell's Island, New York. 12mo, 139 pages, illustrated. Cloth, \$1.00 net.

## Griffith on the Baby. Second Edition, Revised.

The Care of the Baby. By J. P. CROZER GRIFFITH, M.D., Clinical Professor of Diseases of Children, University of Pennsylvania; Physician to the Children's Hospital, Philadelphia, etc. 12mo, 404 pages, with 67 illustrations in the text and 5 plates. Cloth, \$1.50 net.

"The best book for the use of the young mother with which we are acquainted. . . . There are very few general practitioners who could not read the book through with advantage."—*Archives of Pediatrics*.

"The whole book is characterized by rare good sense, and is evidently written by a master hand. It can be read with benefit not only by mothers, but by medical students and by practitioners who have not had large opportunities for observing children."—*American Journal of Obstetrics*.

### **Griffith's Weight Chart.**

Infant's Weight Chart. Designed by J. P. CROZER GRIFFITH, M.D., Clinical Professor of Diseases of Children in the University of Pennsylvania, etc. 25 charts in each pad. Per pad, 50 cts. net.

### **Grünwald and Grayson—Atlas of Diseases of the Larynx.**

[See *Saunders' Medical Hand-Atlases*, page 34.]

### **Haab and De Schweinitz—Atlas of External Diseases of the Eye.**

[See *Saunders' Medical Hand-Atlases*, page 34.]

### **Hart's Diet in Sickness and in Health.**

Diet in Sickness and in Health. By MRS. ERNEST HART, formerly Student of the Faculty of Medicine of Paris and of the London School of Medicine for Women; with an INTRODUCTION by SIR HENRY THOMPSON, F.R.C.S., M.D., London. 220 pages. Cloth, \$1.50 net.

### **Haynes' Anatomy.**

A Manual of Anatomy. By IRVING S. HAYNES, M.D., Adjunct Professor of Anatomy and Demonstrator of Anatomy, Medical Department of the New York University, etc. 680 pages, illustrated with 42 diagrams in the text and 134 full-page half-tone illustrations from original photographs of the author's dissections. Cloth, \$2.50 net.

"This book is the work of a practical instructor—one who knows by experience the requirements of the average student, and is able to meet these requirements in a very satisfactory way. The book is one that can be commended."—*Medical Record*, New York.

### **Heisler's Embryology.**

A Text-Book of Embryology. By JOHN C. HEISLER, M.D., Professor of Anatomy in the Medico-Chirurgical College, Philadelphia. Octavo volume of 405 pages, handsomely illustrated. Cloth, \$2.50 net.

The facts of embryology having acquired in recent years such great interest in connection with the teaching and with the proper comprehension of human anatomy, it is of first importance to the student of medicine that a concise and yet sufficiently full text-book upon the subject be available. It was with the aim of presenting such a book that this volume was written; the author, in his experience as a teacher of anatomy, having been impressed with the fact that students were seriously handicapped in their study of the subject of embryology by the lack of a text-book full enough to be intelligible, and yet without that detail which characterizes the larger treatises, and which so often serves only to confuse and discourage the beginner.

"The book is written to fill a want which has distinctly existed and which it definitely meets; commendation greater than this it is not possible to give to anything."—*Medical News*, New York.

"We can heartily recommend the book and believe it will be of great value."—*New York Medical Journal*.

### **Hektoen and Riesman—American Text-Book of Pathology.**

[See *American Text-Book of Pathology*, page 5.]

## Hirst's Obstetrics. Second Edition.

A Text-Book of Obstetrics. By BARTON COOKE HIRST, M.D., Professor of Obstetrics in the University of Pennsylvania. Handsome octavo volume of 848 pages, with 618 illustrations and 7 colored plates. Cloth, \$5.00 net; Sheep or Half Morocco, \$6.00 net.

This work is intended as an ideal text-book for the student no less than an advanced treatise for the obstetrician and for general practitioners. It represents the very latest teaching in the practice of obstetrics by a man of extended experience and recognized authority, which fact, combined with the brilliant presentation of the subject, renders it one of the most notable books on obstetrics.

"It is a fresh, live contribution to the subject, written in a broad and catholic spirit, and gains by contrast to the various systems so much in vogue at the present day. Dr. Hirst has the experience, the facility of pen, and the knack of teaching; he knows how to separate the chaff from the wheat; the consequence is an admirable text-book of obstetrics—modern, scientific, convincing."—*The Medical News*, New York.

"The illustrations are numerous and are works of art, many of them appearing for the first time. The arrangement of the subject-matter, the foot-notes, and index are beyond criticism. As a true model of what a modern text-book on obstetrics should be, we feel justified in affirming that Dr. Hirst's book is without a rival."—*New York Medical Record*.

"The number of excellent text-books on obstetrics is so great that any new book, to merit and secure the attention of the profession, must possess a high grade of excellence. Such merit is possessed by Dr. Hirst's book. The work is pre-eminently a practical one, and will be valuable whether in the hands of a tyro in obstetrics or in those of a veteran practitioner who wishes to ascertain the latest and best in this line of work."—*Philadelphia Medical Journal*.

## Hofmann and Peterson—Atlas of Legal Medicine.

[See *Saunders' Medical Hand-Atlases*, page 34.]

## Howell—American Text-Book of Physiology.

[See *American Text-Book of Physiology*, page 5.]

## Hyde and Montgomery on Syphilis and the Venereal Diseases.

Syphilis and the Venereal Diseases. By JAMES NEVINS HYDE, M.D., Professor of Skin and Venereal Diseases, and FRANK H. MONTGOMERY, M.D., Associate Professor of Skin, Genito-Urinary, and Venereal Diseases in Rush Medical College, Chicago, Ill. Octavo, 594 pages, profusely illustrated. Cloth, \$4.00 net.

### Second Edition, Revised and Greatly Enlarged.

In the present edition every page has received careful revision; many subjects, notably that on Gonorrhoea, have been rewritten and much new material has been added throughout the book. With a view to better illustration of the subjects considered, a number of new cuts have been introduced and a series of handsome colored lithographic plates. This revision has enhanced the practical value of the work and enormously increased its field of usefulness.

"There are few books which approach it in clearness, and for thorough adaptation to students' needs it is without a peer in the language."—*Journal of Cutaneous and Genito-Urinary Diseases*.

"We can commend this manual to the student as a help to him in his study of venereal diseases."—*Liverpool Medico-Chirurgical Journal*.

"The best student's manual which has appeared on the subject."—*St. Louis Medical and Surgical Journal*.

# The International Text-Book of Surgery. In Two Volumes.

By American and British Authors. Edited by J. COLLINS WARREN, M.D., LL.D., F.R.C.S. (Hon.), Professor of Surgery, Harvard Medical School, Boston; and A. PEARCE GOULD, M.S., F.R.C.S., Lecturer on Practical Surgery and Teacher of Operative Surgery, Middlesex Hospital Medical School, London, Eng. Vol. I. *General Surgery*.— Handsome octavo, 947 pages, with 458 beautiful illustrations and 9 lithographic plates. Vol. II. *Special or Regional Surgery*.— Handsome octavo, 1072 pages, with 471 beautiful illustrations and 8 lithographic plates. *Sold by Subscription*.

Prices per volume: Cloth, \$5.00 net; Sheep or Half Morocco, \$6.00 net.

In presenting a **new work on surgery** to the medical profession the publisher feels that he need offer no apology for making an addition to the list of excellent works already in existence. Modern surgery is still in the transition stage of its development. The art and science of surgery are advancing rapidly, and the number of workers is now so great and so widely spread through the whole of the civilized world that there is certainly room for another work of reference which shall be **untrammelled by many of the traditions of the past**, and shall at the same time present with due discrimination the results of modern progress. There is a real need among practitioners and advanced students for a work on surgery encyclopedic in scope, yet so condensed in style and arrangement that the matter usually diffused through four or five volumes shall be given in one-half the space and at a correspondingly moderate cost.

The aim of the editors has been to produce a **reliable text-book of surgery** embodying a clear but succinct statement of our present knowledge of surgical pathology, symptomatology, and diagnosis, and such a detailed account of treatment as to form a reliable guide to modern practice. While not aiming at the merely novel, they have carefully **omitted antiquated methods** and they believe that the reader will find in these pages only what is practically useful to-day.

The ever-widening field of surgery has been developed largely by special work, and this method of progress has made it practically impossible for one man to write authoritatively on the vast range of subjects embraced in a modern text-book of surgery. In order, therefore, to accomplish their object, the editors have sought the aid of **men of wide experience and established reputation** in the various departments of surgery. They have been able, by means of careful scrutiny and editing of the manuscripts, to secure uniformity of standard and teaching.

One of the most timely features of the work is the extended consideration given to **Military, Naval, and Tropical Surgery**. The treatment of these topics is based on the latest experiences of Military and Naval warfare, including that gained during the Spanish-American war and the present wars in the Philippines and in South Africa, and bringing the subject absolutely down to date.

"It is the most valuable work on the subject that has appeared in some years. The clinician and the pathologist have joined hands in its production, and the result must be a satisfaction to the editors as it is a gratification to the conscientious reader."—*Annals of Surgery*.

"This is a work which comes to us on its own intrinsic merits. Of the latter it has very many. The arrangement of subjects is excellent, and their treatment by the different authors is equally so. What is especially to be recommended is the painstaking endeavor of each writer to make his subject clear and to the point. To this end particularly is the technique of operations lucidly described in all necessary detail. And withal the work is up to date in a very remarkable degree, many of the latest operations in the different regional parts of the body being given in full details. There is not a chapter in the work from which the reader may not learn something new."—*Medical Record*, New York.

## **Jackson's Diseases of the Eye.**

A Manual of Diseases of the Eye. By EDWARD JACKSON, A.M., M.D., Emeritus Professor of Diseases of the Eye in the Philadelphia Polyclinic and College for Graduates in Medicine. 12mo volume of 535 pages, with 178 beautiful illustrations, mostly from drawings by the author. Cloth, \$2.50 net.

### **Recently Issued.**

This book is intended to meet the needs of the general practitioner of medicine and the beginner in ophthalmology. More attention is given to the conditions that must be met and dealt with early in ophthalmic practice than to the rarer diseases and more difficult operations that may come later. It is designed to furnish efficient aid in the actual work of dealing with disease, and therefore gives the place of first importance to the recognition and management of the conditions present in actual clinical work.

"It is truly an admirable work. . . . Written in a clear, concise manner, it bears evidence of the author's comprehensive grasp of the subject. The term 'multum in parvo' is an appropriate one to apply to this work. It will prove of value to all who are interested in this branch of medicine."—*Medical Record*, New York.

## **Jackson and Gleason's Diseases of the Eye, Nose, and Throat. Second Edition, Revised.**

[See *Saunders' Question-Compends*, page 37.]

## **Jakob and Eshner—Atlas of Internal Medicine and Clinical Diagnosis.**

[See *Saunders' Medical Hand-Atlases*, page 34.]

## **Jakob and Fisher—Atlas and Epitome of the Nervous System.**

[See *Saunders' Medical Hand-Atlases*, page 35.]

## **Keating's Life Insurance.**

How to Examine for Life Insurance. By JOHN M. KEATING, M.D., Fellow of the College of Physicians of Philadelphia; Vice-President of the American Pædiatric Society; Ex-President of the Association of Life Insurance Medical Directors. Royal octavo, 211 pages. With a plate prepared by Dr. McClellan from special dissections, and numerous other illustrations. Cloth, \$2.00 net.

## **Keen on the Surgery of Typhoid Fever.**

The Surgical Complications and Sequels of Typhoid Fever. By WM. W. KEEN, M.D., LL.D., F.R.C.S. (Hon.), Professor of the Principles of Surgery and of Clinical Surgery, Jefferson Medical College, Philadelphia; Corresponding Member of the Société de Chirurgie, Paris; Honorary Member of the Société Belge de Chirurgie, etc. Octavo volume of 386 pages, illustrated. Cloth, \$3.00 net.

"This is probably the first and only work in the English language that gives the reader a clear view of what typhoid fever really is, and what it does and can do to the human organism. This book should be in the possession of every medical man in America."—*American Medico-Surgical Bulletin*.

**Keen's Operation Blank. Second Edition, Revised Form.**

An Operation Blank, with Lists of Instruments, etc., Required in Various Operations. Prepared by W. W. KEEN, M.D., LL.D., F.R.C.S. (Hon.), Professor of the Principles of Surgery and of Clinical Surgery in Jefferson Medical College, Philadelphia.

Price per pad, blanks for fifty operations, 50 cts. net.

**Keen and White—An American Text-Book of Surgery.**

[See *American Text-Book of Surgery*, page 5.]

**Kyle on the Nose and Throat. Second Edition.**

Diseases of the Nose and Throat. By D. BRADEN KYLE, M.D., Clinical Professor of Laryngology and Rhinology, Jefferson Medical College, Philadelphia; Consulting Laryngologist, Rhinologist, and Otologist, St. Agnes' Hospital. Octavo, 646 pages; over 150 illustrations and 6 lithographic plates. Cloth, \$4.00 net; Half Morocco, \$5.00 net.

This book presents the subject of Diseases of the Nose and Throat in as concise a manner as is consistent with clearness, keeping in mind the needs of the student and general practitioner as well as those of the specialist. The illustrations are particularly fine, being chiefly original. With the practical purpose of the book in mind, extended consideration has been given to details of treatment, each disease being considered in full, and definite courses being laid down to meet special conditions and symptoms.

"It is a thorough, full, and systematic treatise, so classified and arranged as greatly to facilitate the teaching of laryngology and rhinology, and must prove most convenient and satisfactory both for students and practitioners."—*International Medical Magazine*.

"A valuable guide for both the student and practitioner in all that pertains to diseases of the nose and throat. It is a practical book, and will be a valuable addition to the library of the general practitioner."—*Chicago Medical Recorder*.

**Lainé's Temperature Chart.**

Temperature Chart. Prepared by D. T. LAINÉ, M.D. Size 8 x 13 1/2 inches. A conveniently arranged Chart for recording Temperature, with columns for daily amounts of Urinary and Fecal Excretions, Food, Remarks, etc. On the back of each chart is given in full the method of Brand in the treatment of Typhoid Fever.

Price, per pad of 25 charts, 50 cts. net.

**Leroy's Histology.**

The Essentials of Histology. By LOUIS LEROY, M.D., Professor of Histology and Pathology, Vanderbilt University, Nashville, Tennessee. 12mo. 225 pages, with 71 original illustrations. Cloth, \$1.00 net.

**A New Volume in Saunders' Question-Compend Series.**

The object of this book is to collect within a limited space and in a convenient form the essential facts in histology. At the same time the author has endeavored not to sacrifice clearness and intelligibility to the necessities of condensation. While specially designed for students, the work will be useful to practitioners who desire to acquire in a short time sufficient histology to enable them understandingly to read pathology. The illustrations in the volume are original and particularly fine.

## Levy and Klemperer's Clinical Bacteriology.

The Elements of Clinical Bacteriology. By DR. ERNST LEVY, Professor in the University of Strassburg, and FELIX KLEMPERER, Privat-docent in the University of Strassburg. Translated and edited by AUGUSTUS A. ESHNER, M.D., Professor of Clinical Medicine in the Philadelphia Polyclinic. Octavo, 440 pages, fully illustrated.

Cloth, \$2.50 net.

This book represents an attempt to group the results of bacteriological investigation from a clinical point of view. Bacteriology has become more and more an indispensable aid to medical art. It has enlarged our comprehension of the nature of infectious diseases, and it has established their prophylaxis, diagnosis, and treatment upon a broader basis. The work aims to show how useful to the physician in his double capacity of counselor of the well and coadjutor of the sick are bacteriological thought and action.

"The book is one with which every practitioner who desires to keep in touch with the advances of his profession should be familiar."—*New York Medical Journal*.

## Lockwood's Practice of Medicine.

A Manual of the Practice of Medicine. By GEORGE ROE LOCKWOOD, M.D., Professor of Practice in the Woman's Medical College of the New York Infirmary, etc. 935 pages, with 75 illustrations in the text and 22 full-page plates.

Cloth, \$2.50 net.

"Gives in a most concise manner the points essential to treatment usually enumerated in the most elaborate works."—*Massachusetts Medical Journal*.

## Long's Syllabus of Gynecology.

A Syllabus of Gynecology, arranged in Conformity with "An American Text-Book of Gynecology." By J. W. LONG, M.D., Professor of Diseases of Women and Children, Medical College of Virginia, etc.

Cloth, interleaved, \$1.00 net.

## Macdonald's Surgical Diagnosis and Treatment.

Surgical Diagnosis and Treatment. By J. W. MACDONALD, M.D. Edin., F.R.C.S., Edin., Professor of the Practice of Surgery and of Clinical Surgery in Hamline University; Visiting Surgeon to St. Barnabas' Hospital, Minneapolis, etc. Handsome octavo, 800 pages, fully illustrated. Cloth, \$5.00 net; Sheep or Half Morocco, \$6.00 net.

This work aims in a comprehensive manner to furnish a guide in matters of surgical diagnosis. It sets forth in a systematic way the necessities of examinations and the proper methods of making them. The various portions of the body are then taken up in order and the diseases and injuries thereof succinctly considered and the treatment briefly indicated. Practically all the modern and approved operations are described with thoroughness and clearness. The work concludes with a chapter on the use of the Röntgen rays in surgery.

"A thorough and complete work on surgical diagnosis and treatment, free from padding, full of valuable material, and in accord with the surgical teaching of the day."—*The Medical News*, New York.

"The work is brimful of just the kind of practical information that is useful alike to students and practitioners. It is a pleasure to commend the book because of its intrinsic value to the medical practitioner."—*Cincinnati Lancet-Clinic*.

## **Mallory and Wright's Pathological Technique.**

Pathological Technique. A Practical Manual for Laboratory Work in Pathology, Bacteriology, and Morbid Anatomy, with chapters on Post-Mortem Technique and the Performance of Autopsies. By FRANK B. MALLORY, A.M., M.D., Assistant Professor of Pathology, Harvard University Medical School, Boston; and JAMES H. WRIGHT, A.M., M.D., Instructor in Pathology, Harvard University Medical School, Boston. Octavo, 396 pages, handsomely illustrated. Cloth, \$2.50 net.

This book is designed especially for practical use in pathological laboratories, both as a guide to beginners and as a source of reference for the advanced. The book will also meet the wants of practitioners who have opportunity to do general pathological work. Besides the methods of post-mortem examinations and of bacteriological and histological investigations connected with autopsies, the special methods employed in clinical bacteriology and pathology have been fully discussed.

"I have been looking forward to the publication of this book, and I am glad to say that I find it to be a most useful laboratory and post-mortem guide, full of practical information and well up to date."—WILLIAM H. WELCH, *Professor of Pathology, Johns Hopkins University.*

"One of the most complete works on the subject, and one which should be in the library of every physician who hopes to keep pace with the great advances made in pathology."—*Journal of the American Medical Association.*

## **Martin's Minor Surgery, Bandaging, and Venereal Diseases. Second Edition, Revised.**

[See *Saunders' Question-Compends*, page 37.]

## **Martin's Surgery. Seventh Edition, Revised.**

[See *Saunders' Question-Compends*, page 37.]

## **McFarland's Pathogenic Bacteria.**

Text-Book upon the Pathogenic Bacteria. By JOSEPH MCFARLAND, M.D., Professor of Pathology and Bacteriology in the Medico-Chirurgical College of Philadelphia, etc. Octavo volume of 621 pages, finely illustrated. Cloth, \$3.25 net.

### **Third Edition, Increased in Size by Over 100 Pages.**

Since the work first appeared, extensive progress has been made in the subjects of which it treats, making it necessary to materially increase the size of the book. The matter upon Infection and Immunity has been entirely rewritten; other new chapters appear here and there, and much of the substance of the book has been altered or recast. The principal changes will be found where the advances have been most rapid—that is, under Tuberculosis, Diphtheria, Tetanus, Plague, etc. Much new matter has been added to the Technic of Bacteriology.

"It is excellently adapted for the medical students and practitioners for whom it is avowedly written. . . . The descriptions given are accurate and readable, and the book should prove useful to those for whom it is written."—*London Lancet.*

"The author has succeeded admirably in presenting the essential details of bacteriological technics, together with a judiciously chosen summary of our present knowledge of pathogenic bacteria. . . . The work, we think, should have a wide circulation among English-speaking students of medicine."—*New York Medical Journal.*

"It may be looked upon as an exceedingly comprehensive and well thought-out manual from which to study the morphology and biology of the pathogenic bacteria."—*British Medical Journal.*

**Meigs on Feeding in Infancy.**

Feeding in Early Infancy. By ARTHUR V. MEIGS, M.D.

Bound in limp cloth, flush edges, 25 cts. net.

**Moore's Orthopedic Surgery.**

A Manual of Orthopedic Surgery. By JAMES E. MOORE, M.D., Professor of Orthopedics and Adjunct Professor of Clinical Surgery, University of Minnesota, College of Medicine and Surgery. Octavo volume of 356 pages, handsomely illustrated. Cloth, \$2.50 net.

A practical book based upon the author's experience, in which special stress is laid upon early diagnosis and treatment such as can be carried out by the general practitioner. The teachings of the author are in accordance with his belief that true conservatism is to be found in the middle course between the surgeon who operates too frequently and the orthopedist who seldom operates.

"A most attractive work. The illustrations and the care with which the book is adapted to the wants of the general practitioner and the student are worthy of great praise."—*Chicago Medical Recorder*.

"A very demonstrative work, every illustration of which conveys a lesson. The work is a most excellent and commendable one, which we can certainly endorse with pleasure."—*St. Louis Medical and Surgical Journal*.

**Morris's Materia Medica and Therapeutics. Fifth Edition, Revised.**

[See *Saunders' Question-Compends*, page 37.]

**Morris, Wolff, and Powell's Practice of Medicine. Third Edition, Revised.**

[See *Saunders' Question-Compends*, page 37.]

**Morten's Nurses' Dictionary.**

Nurses' Dictionary of Medical Terms and Nursing Treatment. Containing Definitions of the Principal Medical and Nursing Terms and Abbreviations; of the Instruments, Drugs, Diseases, Accidents, Treatments, Operations, Foods, Appliances, etc., encountered in the ward or in the sick-room. By HONNOR MORTEN, author of "How to Become a Nurse," etc. 16mo, 140 pages. Cloth, \$1.00 net.

**Mraček and Bangs—Atlas of Syphilis and the Venereal Diseases.**

[See *Saunders' Medical Hand-Atlases*, page 34.]

**Mraček and Stelwagon—Atlas of Diseases of the Skin.**

[See *Saunders' Medical Hand-Atlases*, page 34.]

**Nancrede's Anatomy. Sixth Edition, Thoroughly Revised.**

[See *Saunders' Question-Compends*, page 37.]

**Nancrede's Anatomy and Dissection. Fourth Edition.**

Essentials of Anatomy and Manual of Practical Dissection. By CHARLES B. NANCREDE, M.D., LL.D., Professor of Surgery and of Clinical Surgery, University of Michigan, Ann Arbor. Post-octavo, 500 pages, with full-page lithographic plates in colors and nearly 200 illustrations. Extra Cloth (or Oilcloth for dissection-room), \$2.00 net.

**Nancrede's Principles of Surgery.**

Lectures on the Principles of Surgery. By CHAS. B. NANCREDE, M.D., LL.D., Professor of Surgery and of Clinical Surgery, University of Michigan, Ann Arbor. Octavo, 398 pages, illustrated. Cloth, \$2.50 net.

The present book is based on the lectures delivered by Dr. Nancrede to his undergraduate classes, and is intended as a text-book for students and a practical help for teachers. By the careful elimination of unnecessary details of pathology, bacteriology, etc., which are amply provided for in other courses of study, space is gained for a more extended consideration of the Principles of Surgery in themselves, and of the application of these principles to methods of practice.

"The author is deserving of the highest praise for the manner in which the subject has been presented. The work is written in a scientific spirit, and presents each subject in the light of the most recent scientific investigations. . . . Should he of inestimable value not only to the student of to-day but to the graduate of past years."—*American Journal of the Medical Sciences*.

"The subject is treated on the most recent lines of scientific research; the facts are impressively presented and the practical side is always well in touch with the theory."—*Annals of Surgery*.

**Norris—American Text-Book of Obstetrics.**

[See *American Text-Book of Obstetrics*, page 4.]

**Norris's Syllabus of Obstetrics. Third Edition, Revised.**

Syllabus of Obstetrical Lectures in the Medical Department of the University of Pennsylvania. By RICHARD C. NORRIS, A.M., M.D., Instructor in Obstetrics and Lecturer on Clinical and Operative Obstetrics, University of Pennsylvania. Crown octavo, 222 pages.

Cloth, interleaved for notes, \$2.00 net.

**Ogden on the Urine. Just Issued.**

Clinical Examination of the Urine and Urinary Diagnosis. A Clinical Guide for the Use of Practitioners and Students of Medicine and Surgery. By J. BERGEN OGDEN, M.D., Instructor in Chemistry, Harvard Medical School; Assistant in Clinical Pathology, Boston City Hospital. Handsome octavo, 416 pages, with 54 illustrations and a number of colored plates. Cloth, \$3.00 net.

The design of this work is to present in as concise a manner as possible the chemistry of the urine and its relation to physiologic processes; the most approved working methods, both qualitative and quantitative; the diagnosis of diseases and disturbances of the kidneys and urinary passages. In addition to chemic and microscopic methods, which have been described in detail, special attention has been paid to diagnosis, including our present knowledge of the character of the urine, the diagnosis and differentiation of diseases of the kidneys and urinary passages; an enumeration of the prominent clinical symptoms of each disease; and, finally, the peculiarities of the urine in certain general diseases of the body.

## Penrose's Diseases of Women. Third Edition, Revised.

A Text-Book of Diseases of Women. By CHARLES B. PENROSE, M.D., PH.D., formerly Professor of Gynecology in the University of Pennsylvania; Surgeon to the Gyneccean Hospital, Philadelphia. Octavo volume of 531 pages, handsomely illustrated. Cloth, \$3.75 net.

In this work, which has been written for both the student of gynecology and the general practitioner, the author presents the best teaching of modern gynecology untrammelled by antiquated theories or methods of treatment. In most instances but one plan of treatment is recommended, to avoid confusing the student or the physician who consults the book for practical guidance.

"I shall value very highly the copy of Penrose's 'Diseases of Women' received. I have already recommended it to my class as **THE BEST** book."—HOWARD A. KELLY, *Professor of Gynecology and Obstetrics, Johns Hopkins University, Baltimore, Md.*

"Although we have already called attention to its peculiar value as a practical book for the student, we feel that the new edition should not be dismissed without further commendation. . . . We can only reaffirm our belief that Dr. Penrose has rendered a distinct service to his generation by giving us what approaches very closely to the ideal text-book. We predict that its superiority will be recognized by teachers as well as students."—*American Journal of the Medical Sciences.*

## Powell's Diseases of Children. Second Edition.

[See *Saunders' Question-Compends*, page 37.]

## Pryor—Pelvic Inflammations.

The Treatment of Pelvic Inflammations through the Vagina. By W. R. PRYOR, M.D., Professor of Gynecology in New York Polyclinic. 12mo, 248 pages, handsomely illustrated. Cloth, \$2.00 net.

"This subject, which has recently been so thoroughly canvassed in high gynecological circles, is made available in this volume to the general practitioner and student. Nothing is too minute for mention and nothing is taken for granted; consequently the book is of the utmost value. The illustrations and the technique are beyond criticism."—*Chicago Medical Recorder.*

## Pye's Bandaging.

Elementary Bandaging and Surgical Dressing. With Directions concerning the Immediate Treatment of Cases of Emergency. For the use of Dressers and Nurses. By WALTER PYE, F.R.C.S., late Surgeon to St. Mary's Hospital, London. Small 12mo, with over 80 illustrations. Cloth, flexible covers, 75 cts. net.

## Pyle's Personal Hygiene. Just Issued.

A Manual of Personal Hygiene. Proper Living upon a Physiologic Basis. Edited by WALTER L. PYLE, M.D., Assistant Surgeon to the Wills Eye Hospital, Philadelphia. Octavo volume of 344 pages, fully illustrated. Cloth, \$1.50 net.

The object of this manual is to set forth plainly the best means of developing and maintaining physical and mental vigor. It represents a thorough exposition of living upon a physiologic basis. There are chapters upon the hygiene of the digestive apparatus, the skin and its appendages, the vocal and respiratory apparatus, eye, ear, brain, and nervous system, and a chapter upon exercise. The book is the conjoint work of several well-known American physicians and medical teachers, each writing upon a subject to which he has given special study, thus assuring for the book an originality and authority not possessed by any similar treatise.

## Raymond's Physiology.

A Manual of Physiology. By JOSEPH H. RAYMOND, A.M., M.D., Professor of Physiology and Hygiene and Lecturer on Gynecology in the Long Island College Hospital; Director of Physiology in the Hoagland Laboratory, etc. 382 pages, with 102 illustrations in the text and 4 full-page colored plates. Cloth, \$1.25 net.

"Extremely well gotten up, and the illustrations have been selected with care. The text is fully abreast with modern physiology."—*British Medical Journal*.

## Salinger and Kalteyer's Modern Medicine.

Modern Medicine. By JULIUS L. SALINGER, M.D., Demonstrator of Clinical Medicine, Jefferson Medical College, and F. J. KALTEYER, M.D., Assistant Demonstrator of Clinical Medicine, Jefferson Medical College. Handsome octavo, 801 pages, illustrated. Cloth, \$4.00 net.

### Just Issued.

This is a work for students and practitioners, in which internal medicine is considered in relation to etiology, symptomatology, pathology, diagnosis, and treatment, especial prominence being given to practical methods in the examination of blood, sputum, gastric secretions, and urine, and to methods of physical diagnosis. In the present era the practice of medicine includes the study of a number of these specialties, so that it has frequently been necessary for the student to procure separate books upon these topics. For this reason it has appeared advisable for the authors to include in the volume, as far as possible, the essentials of these branches as applied to Clinical Medicine. The matter represents the very latest approved knowledge in the various departments, the newest works in English, French, and German having been consulted throughout the preparation of the book.

## Saundby's Renal and Urinary Diseases.

Lectures on Renal and Urinary Diseases. By ROBERT SAUNDBY, M.D. Edin., Fellow of the Royal College of Physicians, London, and of the Royal Medico-Chirurgical Society; Professor of Medicine in Mason College, Birmingham, etc. Octavo volume of 434 pages, with numerous illustrations and 4 colored plates. Cloth, \$2.50 net.

## Saunders' Pocket Medical Formulary. Sixth Edition, Revised.

By WILLIAM M. POWELL, M.D., Author of "Essentials of Diseases of Children"; Member of Philadelphia Pathological Society. Containing 1844 formulæ from the best-known authorities. With an Appendix containing Posological Table, Formulæ and Doses for Hypodermic Medication, Poisons and their Antidotes, Diameters of the Female Pelvis and Fetal Head, Obstetrical Table, Diet List for Various Diseases, Materials and Drugs used in Antiseptic Surgery, Treatment of Asphyxia from Drowning, Surgical Remembrancer, Tables of Incompatibles, Eruptive Fevers, etc., etc. Handsomely bound in flexible morocco, with side index, wallet, and flap. \$2.00 net.

### New Edition, Enlarged by Over 200 New Formulæ.

"This little book, that can be conveniently carried in the pocket, contains an immense amount of material. It is very useful, and, as the name of the author of each prescription is given, is unusually reliable."—*Medical Record*, New York.

**Sayre's Pharmacy. Second Edition, Revised.**[See *Saunders' Question-Compends*, page 37.]**Schaeffer and Edgar—Atlas of Obstetrical Diagnosis and Treatment.**[See *Saunders' Medical Hand-Atlases*, page 35.]**Schaeffer and Norris—Atlas of Obstetrics.**[See *Saunders' Medical Hand-Atlases*, page 35.]**Scudder's Fractures. Second Edition, Revised.**

The Treatment of Fractures. By CHAS. L. SCUDDER, M.D., Assistant in Clinical and Operative Surgery, Harvard Medical School. Octavo, 433 pages, with nearly 600 original illustrations.

Polished Buckram, \$4.50 net; Half Morocco, \$5.50 net.

**First Edition (2500 Copies) Exhausted in Five Months.**

This book is intended to serve as a guide to the practitioner and student in the treatment of fractures of bones, being a practical statement of the generally recognized methods of dealing with fractures. The attention of the student is diverted from theories to the actual conditions that exist in fractured bones, and he is encouraged to determine for himself how to meet the conditions found in each individual case. Methods of treatment are described in minute detail, and the reader is not only told, but is *shown*, how to apply apparatus, for, as far as possible, all the details are illustrated. This elaborate and complete series of illustrations constitutes a feature of the book. There are nearly 600 of them, all from new and original drawings and reproduced in the highest style of art.

"It is in the highest degree practical. Too much credit cannot be given to the author for the care which he has taken to describe the methods of examination and treatment so exactly as to enable the practitioner to understand them without difficulty. The illustrations are abundant and the text clear; the methods given are elaborately illustrated and explained. This makes the work particularly valuable to the general practitioner."—*University Medical Magazine*.

"This admirably illustrated and carefully written work furnishes one of the best guides with which we are familiar in the management of the accidents that fall within the range of this difficult branch of surgery."—*Chicago Medical Recorder*.

"The work produces a favorable impression by the general manner in which the subject is treated. Its descriptions are concise and clear and the treatment sound. The physical examination of the injured part is well described, and . . . the method of making these examinations is illustrated by a liberal use of cuts."—*American Journal of the Medical Sciences*.

"The present work covers the ground admirably. . . . The text is excellent and the illustrations are accurate. . . . This treatise expresses the idea of a clear-thinking worker in a most interesting field of surgery."—*New York Medical Journal*.

**Senn's Genito-Urinary Tuberculosis.**

Tuberculosis of the Genito-Urinary Organs, Male and Female. By NICHOLAS SENN, M.D., PH.D., LL.D., Professor of the Practice of Surgery and of Clinical Surgery, Rush Medical College, Chicago. Handsome octavo volume of 320 pages, illustrated. Cloth, \$3.00 net.

"An important book upon an important subject, and written by a man of mature judgment and wide experience. The author has given us an instructive book upon one of the most important subjects of the day."—*Clinical Reporter*.

"A work which adds another to the many obligations the profession owes the talented author."—*Chicago Medical Recorder*.

## Senn's Practical Surgery.

Practical Surgery. By NICHOLAS SENN, M.D., PH.D., LL.D., Professor of the Practice of Surgery and of Clinical Surgery, Rush Medical College, Chicago. Handsome octavo volume of 800 pages, profusely illustrated. *In Press.*

This book deals with practical subjects, and is intended for the general practitioner, special attention being paid to emergency surgery. Shock, hemorrhage, and wound treatment are fully considered, and a complete account is given of gunshot wounds and their treatment. All emergency operations that come under the care of the general practitioner are described in detail and fully illustrated.

The experimental work of the author has been utilized whenever it was deemed necessary to serve as a basis for new methods of practice. The section on Military Surgery is based on the author's experience as chief of the operating staff with the army in the field during the Spanish-American War, and on his observations during the Greco-Turkish War. Intestinal Surgery is given a prominent place, and the consideration of this subject is the result of the clinical experience of the author as surgeon and teacher of surgery for a quarter of a century.

## Senn's Syllabus of Surgery.

A Syllabus of Lectures on the Practice of Surgery, arranged in conformity with "An American Text-Book of Surgery." By NICHOLAS SENN, M.D., PH.D., LL.D., Professor of the Practice of Surgery and of Clinical Surgery in Rush Medical College, Chicago. Cloth, \$1.50 net.

"The author has evidently spared no pains in making his Syllabus thoroughly comprehensive, and has added new matter and alluded to the most recent authors and operations. Full references are also given to all requisite details of surgical anatomy and pathology."—*British Medical Journal.*

## Senn's Tumors. Second Edition, Revised.

Pathology and Surgical Treatment of Tumors. By N. SENN, M.D., PH.D., LL.D., Professor of Surgery and of Clinical Surgery, Rush Medical College; Professor of Surgery, Chicago Polyclinic; Attending Surgeon to Presbyterian Hospital; Surgeon-in-Chief, St. Joseph's Hospital, Chicago. *Second Edition, Thoroughly Revised.* Octavo volume of 718 pages, with 478 illustrations, including 12 full-page plates in colors. Prices: Cloth, \$5.00 net; Sheep or Half Morocco, \$6.00 net.

In the present edition the text has been carefully revised and many additions have been made. A new section has been added on Sarcoma of the Decidua. Many of the old illustrations have been eliminated, and are replaced by others intended to explain more satisfactorily the subjects they represent. Most of the new illustrations are original.

"The most exhaustive of any recent book in English on this subject. It is well illustrated, and will doubtless remain as the principal monograph on the subject in our language for some years. The book is handsomely illustrated and printed, and the author has given a notable and lasting contribution to surgery."—*Journal of the American Medical Association.*

"Altogether it is a broad book, full of interesting facts, eminently sound in its pathology, and founded on an exceptionally large experience of a conscientious and painstaking observer."—*Medical Record*, New York.

## Shaw's Nervous Diseases and Insanity. Third Edition, Revised.

[See *Saunders' Question-Compends*, page 37.]

## **Starr—American Text-Book of Diseases of Children.**

[See *American Text-Book of Diseases of Children*, page 3.]

## **Starr's Diets for Infants and Children.**

Diets for Infants and Children in Health and in Disease. By LOUIS STARR, M.D., Editor of "An American Text-Book of the Diseases of Children." 230 blanks (pocket-book size), perforated and neatly bound in flexible morocco. \$1.25 net.

## **Stelwagon's Diseases of the Skin. Fourth Edition, Revised.**

[See *Saunders' Question-Compends*, page 37.]

## **Stengel's Pathology. Third Edition, Thoroughly Revised.**

A Text-Book of Pathology. By ALFRED STENDEL, M.D., Professor of Clinical Medicine in the University of Pennsylvania; Visiting Physician to the Pennsylvania Hospital; Physician to the Philadelphia Hospital, etc. Handsome octavo, 873 pages, nearly 400 illustrations, many in colors. Cloth, \$5.00 net; Sheep or Half Morocco, \$6.00 net.

In this work the practical application of pathological facts to clinical medicine is considered more fully than is customary in works on pathology. While the subject of pathology is treated in the broadest way consistent with the size of the book, an effort has been made to present the subject from the point of view of the clinician. The general relations of bacteriology to pathology are discussed at considerable length, as the importance of these branches deserves. The pathology of individual organs and tissues is treated systematically and quite fully under subheadings that clearly indicate the subject-matter to be found on each page. The present edition has been thoroughly revised with the intention of bringing the subject-matter up to date and amplifying the sections on Pathologic Physiology. The favorable reception of previous editions has convinced the author that his purpose of supplying a moderate-sized book on clinical pathology has found favor with the profession.

"I consider the work abreast of modern pathology, and useful to both students and practitioners. It presents in a concise and well-considered form the essential facts of general and special pathological anatomy, with more than usual emphasis upon pathological physiology."—WILLIAM H. WELCH, *Professor of Pathology, Johns Hopkins University, Baltimore, Md.*

"This volume is intended to present the subject of pathology in as practical a form as possible, and especially from the point of view of the clinical pathologist. These objects have been faithfully carried out and a valuable text-book is the result. Taking the book as a whole we can most favorably recommend it to our readers as a thoroughly practical work on clinical pathology."—*The London Lancet.*

"The outcome of the effort is a source of satisfaction and congratulation. The work is in every way to be cordially commended."—*Philadelphia Medical Journal.*

## **Stengel and White on the Blood.**

The Blood in its Clinical and Pathological Relations. By ALFRED STENDEL, M.D., Professor of Clinical Medicine, University of Pennsylvania; and C. Y. WHITE, JR., M.D., Instructor in Clinical Medicine, University of Pennsylvania.

## **Stevens' Materia Medica and Therapeutics. Second Edition, Revised.**

A Manual of Materia Medica and Therapeutics. By A. A. STEVENS, A.M., M.D., Lecturer on Physical Diagnosis in the University of Pennsylvania; Professor of Pathology in the Woman's Medical College of Pennsylvania; Physician to St. Agnes' Hospital. Post-octavo, 445 pages. Flexible Leather, \$2.00 net.

"The author has faithfully presented modern therapeutics in a comprehensive work, and, while intended particularly for the use of students, it will be found a reliable guide and sufficiently comprehensive for the physician in practice."—*University Medical Magazine*.

## **Stevens' Practice of Medicine. Fifth Edition, Revised.**

A Manual of the Practice of Medicine. By A. A. STEVENS, A.M., M.D., Lecturer on Physical Diagnosis in the University of Pennsylvania; Professor of Pathology in the Woman's Medical College of Pennsylvania. Specially intended for students preparing for graduation and hospital examinations. Post-octavo, 519 pages; illustrated. Flexible Leather, \$2.00 net.

"The frequency with which new editions of this manual are demanded bespeaks its popularity. It is an excellent condensation of the essentials of medical practice for the student, and may be found also an excellent reminder for the busy physician."—*Buffalo Medical Journal*.

## **Stewart and Lawrance's Medical Electricity.**

[See *Saunders' Question-Compends*, page 37.]

## **Stewart's Physiology. Fourth Edition, Revised.**

A Manual of Physiology, with Practical Exercises. For Students and Practitioners. By G. N. STEWART, M.A., M.D., D.Sc., lately Examiner in Physiology, University of Aberdeen, and of the New Museums, Cambridge University; Professor of Physiology in the Western Reserve University, Cleveland, Ohio. Octavo volume of 894 pages; 336 illustrations and 5 colored plates. Cloth, \$3.75 net.

In the present edition the book has been revised and in parts rewritten. A considerable amount of new matter has been added, especially to the chapter on The Central Nervous System. The additions in the other parts of the volume have been balanced, for the most part, by the omission of some passages and the abridgment of others, so that its bulk is only slightly increased.

"It will make its way by sheer force of merit, and amply deserves to do so. It is one of the very best English text-books on the subject."—*London Lancet*.

"Of the many text-books of physiology published, we do not know of one that so nearly comes up to the ideal as does Professor Stewart's volume."—*British Medical Journal*.

## **Stoney's Materia Medica for Nurses.**

Materia Medica for Nurses. By EMILY A. M. STONEY, Graduate of the Training-School for Nurses, Lawrence, Mass.; late Superintendent of the Training-School for Nurses, Carney Hospital, South Boston, Mass. Handsome octavo volume of 306 pages. Cloth, \$1.50 net.

"So far as we can see, it contains about everything that a nurse ought to know in regard to drugs. As a reference-book for nurses, it will, without question, be very useful."—*Journal of the American Medical Association*.

## Stoney's Nursing. Second Edition, Revised.

Practical Points in Nursing. For Nurses in Private Practice. By EMILY A. M. STONEY, Graduate of the Training-School for Nurses, Lawrence, Mass.; late Superintendent of the Training-School for Nurses, Carney Hospital, South Boston, Mass. 456 pages, illustrated with 73 engravings in the text and 8 colored and half-tone plates.

Cloth, \$1.75 net.

In this volume the author explains, in popular language and in the shortest possible form, the entire range of *private* nursing as distinguished from *hospital* nursing, and the nurse is instructed how best to meet the various emergencies of medical and surgical cases when distant from aid or when thrown on her own resources.

An especially valuable feature of the work will be found in the directions to the nurse how to *improvise* everything ordinarily needed in the sick-room.

The Appendix contains much information in compact form that will be found of great value to the nurse, including Rules for Feeding the Sick; Recipes for Invalid Foods and Beverages; Tables of Weights and Measures; List of Abbreviations; Dose-List; and a complete Glossary of Medical Terms and Nursing Treatment.

"There are few books intended for non-professional readers which can be so cordially endorsed by a medical journal as can this one."—*Therapeutic Gazette*.

"This is a well-written, eminently practical volume, which covers the entire range of private nursing as distinguished from hospital nursing, and instructs the nurse how best to meet the various emergencies which may arise, and how to prepare everything ordinarily needed in the illness of her patient."—*American Journal of Obstetrics and Diseases of Women and Children*.

## Stoney's Surgical Technic for Nurses.

Bacteriology and Surgical Technic for Nurses. By EMILY A. M. STONEY, late Superintendent of the Training-School for Nurses, Carney Hospital, South Boston, Mass. 12mo volume, fully illustrated.

Cloth, \$1.25 net.

Just Issued.

This work is intended as a modern text-book of Surgical Nursing both in hospital and private practice. The first part of the book is devoted to Bacteriology and Antiseptics; the second part to Surgical Technic, Signs of Death, and Autopsies. The matter in the book is presented in an attractive and practical form, and it will doubtless prove of distinct value to all nurses who are called upon to attend surgical cases.

## Thomas's Diet Lists. Second Edition, Revised.

Diet Lists and Sick-Room Dietary. By JEROME B. THOMAS, M.D., Visiting Physician to the Home for Friendless Women and Children and to the Newsboys' Home; Assistant Visiting Physician to the Kings County Hospital. Cloth, \$1.25 net. Send for sample sheet.

"This book will save the practitioner a great deal of work, and be distinctly to his advantage."—*Journal of the American Medical Association*.

"The collection of diet-lists and the accompanying sick-room dietary is a convenience that will be appreciated by every physician."—*New York Medical Journal*.

## Thornton's Dose-Book and Prescription-Writing.

Dose-Book and Manual of Prescription-Writing. By E. Q. THORNTON, M.D., Demonstrator of Therapeutics, Jefferson Medical College, Philadelphia. 334 pages, illustrated. Cloth, \$1.25 net.

"Full of practical suggestions; will take its place in the front rank of works of this sort."—*Medical Record*, New York.

## Van Valzah and Nisbet's Diseases of the Stomach.

Diseases of the Stomach. By WILLIAM W. VAN VALZAH, M.D., Professor of General Medicine and Diseases of the Digestive System and the Blood, New York Polyclinic; and J. DOUGLAS NISBET, M.D., Adjunct Professor of General Medicine and Diseases of the Digestive System and the Blood, New York Polyclinic. Octavo volume of 674 pages, illustrated. Cloth, \$3.50 net.

An eminently practical book, intended as a guide to the student, an aid to the physician, and a contribution to scientific medicine. It aims to give a complete description of the modern methods of diagnosis and treatment of diseases of the stomach, and to reconstruct the pathology of the stomach in keeping with the revelations of scientific research. The book is clear, practical, and complete, and contains the results of the authors' investigations and their extensive experience as specialists.

Particular attention is given to the important subject of dietetic treatment. The diet-lists are very complete, and are so arranged that selections can readily be made to suit individual cases.

"This is the most satisfactory work on the subject in the English language."—*Chicago Medical Recorder*.

"The article on diet and general medication is one of the most valuable in the book, and should be read by every practising physician."—*New York Medical Journal*.

"Its chief claim lies in its clearness and general adaptability to the practical needs of the general practitioner or student. In these relations it is probably the best of the recent special works on diseases of the stomach."—*Chicago Clinical Review*.

## Vecki's Sexual Impotence.

The Pathology and Treatment of Sexual Impotence. By VICTOR G. VECKI, M.D. From the second German edition, revised and enlarged. Demi-octavo, 291 pages. Cloth, \$2.00 net.

## Vierordt's Medical Diagnosis. Fourth Edition, Revised.

Medical Diagnosis. By DR. OSWALD VIERORDT, Professor of Medicine at the University of Heidelberg. Translated, with additions, from the fifth enlarged German edition, with the author's permission, by FRANCIS H. STUART, A.M., M.D. Handsome royal octavo volume of 603 pages; 194 fine wood-cuts in text, many of them in colors.

Cloth, \$4.00 net; Sheep or Half Morocco, \$5.00 net.

In this work, as in no other hitherto published, are given full and accurate explanations of the phenomena observed at the bedside. It is distinctly a clinical work by a master teacher, characterized by thoroughness, fullness, and accuracy. It is a mine of information upon the points that are so often passed over without explanation. Especial attention has been given to the germ-theory as a factor in the origin of disease.

In the present edition of this highly successful work many alterations have been made, especially in the sections on Gastric Digestion and the Nervous System. It will be found that all the qualities which served to make the earlier editions so acceptable have been developed with the evolution of the work to its present form.

"Rarely is a book published with which a reviewer can find so little fault as with the volume before us. Each particular item in the consideration of an organ or apparatus, which is necessary to determine a diagnosis of any disease of that organ, is mentioned; nothing seems forgotten. The chapters on diseases of the circulatory and digestive apparatus and nervous system are especially full and valuable. The reviewer would repeat that the book is one of the best—probably the best—which has fallen into his hands."—*University Medical Magazine*.

## **Watson's Handbook for Nurses.**

A Handbook for Nurses. By J. K. WATSON, M.D. Edin. American Edition, under supervision of A. A. STEVENS, A.M., M.D., Lecturer on Physical Diagnosis, University of Pennsylvania. 12mo, 413 pages, 73 illustrations. Cloth, \$1.50 net.

This work aims to supply in one volume that information which so many nurses at the present time are trying to extract from various medical works, and to present that information in a suitable form. Nurses must necessarily acquire a certain amount of medical knowledge, and the author of this book has aimed judiciously to cater to this need with the object of directing the nurses' pursuit of medical information in proper and legitimate channels.

"The intelligent nurse will find this a most convenient manual, and there are many things in it that the physician might find of use. In recommending text-books to nurses it could be put in the first rank."—*Journal of the American Medical Association.*

## **Warren's Surgical Pathology. Second Edition.**

Surgical Pathology and Therapeutics. By JOHN COLLINS WARREN, M.D., LL.D., F.R.C.S. (Hon.), Professor of Surgery, Harvard Medical School. Handsome octavo, 873 pages; 136 relief and lithographic illustrations, 33 in colors. With an Appendix on Scientific Aids to Surgical Diagnosis and a series of articles on Regional Bacteriology. Cloth, \$5.00 net; Sheep or Half Morocco, \$6.00 net.

In the second edition of this book all the important changes have been embodied in a new Appendix. In this new chapter the author has aimed to present in as practical a manner as possible the resources of surgical pathology. In addition to an enumeration of the scientific aids to surgical diagnosis, there is presented a series of sections on regional bacteriology, in which are given a description of the flora of the affected part, and the general principles of treating the affections they produce, based upon the views of the best authorities.

"It is the handsomest specimen of book-making . . . that has ever been issued from the American medical press."—*American Journal of the Medical Sciences*, Philadelphia.

"A most striking and very excellent feature of this book is its illustrations. Without exception, from the point of accuracy and artistic merit, they are the best ever seen in a work of this kind. Many of those representing microscopic pictures are so perfect in their coloring and detail as almost to give the beholder the impression that he is looking down the barrel of a microscope at a well-mounted section."—*Annals of Surgery.*

## **Wilson—American Text-Book of Applied Therapeutics.**

[See *American Text-Book of Applied Therapeutics*, page 3.]

## **Wolff on Examination of Urine.**

[See *Saunders' Question-Compends*, page 37.]

## **Wolff's Medical Chemistry. Fifth Edition, Revised.**

[See *Saunders' Question-Compends*, page 37.]

## **Zuckerkindl and DaCosta—Atlas of Operative Surgery.**

[See *Saunders' Medical Hand-Atlases*, page 34.]

# SAUNDERS'

---

## MEDICAL HAND-ATLASES.

---

The series of books included under this title surpass any similar volumes ever published for **scientific accuracy, pictorial beauty, compactness, and cheapness.**

**Colored Plates.** Each volume contains from **50 to 100 colored plates**, besides numerous illustrations in the text. The colored plates have been executed by the most skillful German lithographers, in some cases more than twenty impressions being required to obtain the desired result. Each plate is accompanied by a full and appropriate **description**, and each book contains a condensed but adequate **outline of the subject** to which it is devoted.

**Substitute for Clinical Observation.**

Such observation, of course, is available only to the residents in large medical centers; and even then the requisite variety is seen only after long years of routine hospital work. To those unable to attend important clinics these books will be absolutely indispensable, as presenting in a complete and convenient form the most accurate reproductions of clinical work, interpreted by the most competent of clinical teachers.

**Moderate Price.**

In planning this series of books arrangements were made with representative publishers in the chief medical centers of the world for the publication of translations of the atlases into nine different languages, the lithographic plates for all being made in Germany, where work of this kind has been brought to the greatest perfection. The enormous expense of making the plates being shared by the various publishers, the cost to each one was reduced to practically one-tenth. Thus by reason of their **universal translation** and reproduction, affording international distribution, the publishers have been enabled to secure for these atlases the **best artistic and professional talent**, to produce them in the **most elegant style**, and yet to offer them at a **price heretofore unapproached in cheapness.**

**Four More Languages.**

During the past year, Saunders' Medical Hand-Atlases have been translated and published in four more languages—Dutch, Japanese, Roumanian, and Bohemian—so that now this remarkable series can be had in **thirteen different languages**, or practically every language of the civilized world. The various languages in which the volumes have appeared include English, German, French, Italian, Russian, Spanish, Japanese, Dutch, Danish, Swedish, Roumanian, Bohemian, and Hungarian.

**Fifty Thousand Copies.**

Two years ago Mr. Saunders contracted with the original publisher for 100,000 copies of the twenty-six volumes that are to compose this series of books. Of these twenty-six volumes only ten have appeared, and yet **50,000 copies** have already been imported.

The volumes in this series are selling with remarkable rapidity, and there is every indication that over 100,000 copies will be sold of these ten volumes alone. Basing the sales of future numbers on those already issued, the prospects are that the original contract will be exceeded three times over, and that the sale of the complete series will reach at least **300,000 copies.**

On account of the marked favor with which these books have been received by the medical profession, and the enormous sales that they seem destined to reach, the publisher has been enabled to prepare and furnish special additional colored plates, making the series even **handsomer and more complete** than was originally intended.

**Adopted by the U. S. Army.**

As an indication of the great practical value of the Atlases and of the immense favor with which they have been received, it should be noted that the Medical Department of the U. S. Army has adopted the "Atlas of Operative Surgery" as its standard, and has ordered the book in large quantities for distribution to the various regiments and army posts.

**For list of volumes see next two pages.**

**SPECIAL OFFER.**

As it is impossible to realize the beauty of these Atlases without an opportunity to examine them, we make the following offer: Any one of these books will be sent to physicians, postpaid, upon request. If you want the book, you have merely to remit the price; if not, return the book by mail.

**Descriptive circular, containing sample plates, sent free on application to the publisher.**

# Saunders' Medical Hand-Atlases.

VOLUMES NOW READY.

**Atlas and Epitome of Internal Medicine and Clinical Diagnosis.** By DR. CHR. JAKOB, of Erlangen. Edited by AUGUSTUS A. ESHNER, M.D., Professor of Clinical Medicine, Philadelphia Polyclinic. 68 colored plates, 64 text-illustrations, 259 pages of text. Cloth, \$3.00 net.

"The charm of the book is its clearness, conciseness, and the accuracy and beauty of its illustrations. It deals with facts. It vividly illustrates those facts. It is a scientific work put together for ready reference."—*Brooklyn Medical Journal*.

**Atlas of Legal Medicine.** By DR. E. R. VON HOFMANN, of Vienna. Edited by FREDERICK PETERSON, M.D., Chief of Clinic, Nervous Dept., College of Physicians and Surgeons, New York. With 120 colored figures on 56 plates and 193 beautiful half-tone illustrations. Cloth, \$3.50 net.

"Hofmann's 'Atlas of Legal Medicine' is a unique work. This immense field finds in this book a pictorial presentation that far excels anything with which we are familiar in any other work."—*Philadelphia Medical Journal*.

**Atlas and Epitome of Diseases of the Larynx.** By DR. L. GRÜNWARD, of Munich. Edited by CHARLES P. GRAYSON, M.D., Physician-in-Charge, Throat and Nose Department, Hospital of the University of Pennsylvania. With 107 colored figures on 44 plates, 25 text-illustrations, and 103 pages of text. Cloth, \$2.50 net.

"Aided as it is by magnificently executed illustrations in color, it cannot fail of being of the greatest advantage to students, general practitioners, and expert laryngologists."—*St. Louis Medical and Surgical Journal*.

**Atlas and Epitome of Operative Surgery.** By DR. O. ZUCKERKANDL, of Vienna. Edited by J. CHALMERS DACOSTA, M.D., Professor of Practice of Surgery and Clinical Surgery, Jefferson Medical College, Philadelphia. With 24 colored plates, 217 text-illustrations, and 395 pages of text. Cloth, \$3.00 net.

"We know of no other work that combines such a wealth of beautiful illustrations with clearness and conciseness of language, that is so entirely abreast of the latest achievements, and so useful both for the beginner and for one who wishes to increase his knowledge of operative surgery."—*Münchener medicinische Wochenschrift*.

**Atlas and Epitome of Syphilis and the Venereal Diseases.** By PROF. DR. FRANZ MRAČEK, of Vienna. Edited by L. BOLTON BANGS, M.D., Professor of Genito-Urinary Surgery, University and Bellevue Hospital Medical College, New York. With 71 colored plates, 16 black-and-white illustrations, and 122 pages of text. Cloth, \$3.50 net.

"A glance through the book is almost like actual attendance upon a famous clinic."—*Journal of the American Medical Association*.

**Atlas and Epitome of External Diseases of the Eye.** By DR. O. HAAB, of Zurich. Edited by G. E. DE SCHWEINITZ, M.D., Professor of Ophthalmology, Jefferson Medical College, Philadelphia. With 76 colored illustrations on 40 plates and 228 pages of text. Cloth, \$3.00 net.

"It is always difficult to represent pathological appearances in colored plates, but this work seems to have overcome these difficulties, and the plates, with one or two exceptions, are absolutely satisfactory."—*Boston Medical and Surgical Journal*.

**Atlas and Epitome of Skin Diseases.** By PROF. DR. FRANZ MRAČEK, of Vienna. Edited by HENRY W. STELWAGON, M.D., Clinical Professor of Dermatology, Jefferson Medical College, Philadelphia. With 63 colored plates, 39 half-tone illustrations, and 200 pages of text. Cloth, \$3.50 net.

"The importance of personal inspection of cases in the study of cutaneous diseases is readily appreciated, and next to the living subjects are pictures which will show the appearance of the disease under consideration. Altogether the work will be found of very great value to the general practitioner."—*Journal of the American Medical Association*

# Saunders' Medical Hand-Atlases.

## VOLUMES JUST ISSUED.

**Atlas and Epitome of Special Pathological Histology.** By DR. H. DÜRCK, of Munich. Edited by LUDVIG HEKTOEN, M.D., Professor of Pathology, Rush Medical College, Chicago. In Two Parts. Part I. *Just Ready*, including the Circulatory, Respiratory, and Gastro-intestinal Tract, with 120 colored figures on 62 plates and 158 pages of text. Part II. *Ready Shortly*. Price of Part I., \$3.00 net.

**Atlas and Epitome of Diseases Caused by Accidents.** By DR. ED. GOLEBIEWSKI, of Berlin. Translated and edited with additions by PEARCE BAILEY, M.D., Attending Physician to the Department of Corrections and to the Almshouse and Incurable Hospitals, New York. With 40 colored plates, 143 text-illustrations, and 600 pages of text. Cloth, \$4.00 net.

**Atlas and Epitome of Gynecology.** By DR. O. SCHÄFFER, of Heidelberg. *From the Second Revised German Edition.* Edited by RICHARD C. NORRIS, A.M., M.D., Gynecologist to the Methodist Episcopal and the Philadelphia Hospitals; Surgeon-in-Charge of Preston Retreat, Philadelphia. With 90 colored plates, 65 text-illustrations, and 308 pages of text. Cloth, \$3.50 net.

## IN PRESS FOR EARLY PUBLICATION.

**Atlas and Epitome of Obstetrical Diagnosis and Treatment.** By DR. O. SCHÄFFER, of Heidelberg. *From the Second Revised German Edition.* Edited by J. CLIFTON EDGAR, M.D., Professor of Obstetrics and Clinical Midwifery, Cornell University Medical School. 72 colored plates, numerous text-illustrations, and copious text.

**Atlas and Epitome of the Nervous System and Its Diseases.** By PROFESSOR DR. CHR. JAKOB, of Erlangen. *From the Second Revised German Edition.* Edited by EDWARD D. FISHER, M.D., Professor of Diseases of the Nervous System, University and Bellevue Hospital Medical College, New York. 83 plates and a copious text.

**Atlas and Epitome of Labor and Operative Obstetrics.** By DR. O. SCHÄFFER, of Heidelberg. *From the Fifth Revised German Edition.* Edited by J. CLIFTON EDGAR, M.D., Professor of Obstetrics and Clinical Midwifery, Cornell University Medical School. With 126 colored illustrations.

**Atlas and Epitome of General Pathological Histology.** With an Appendix on Pathohistological Technic. By DR. H. DÜRCK, of Munich. Edited by LUDVIG HEKTOEN, M.D., Professor of Pathology, Rush Medical College, Chicago. With 80 colored plates, numerous text-illustrations, and copious text.

**Atlas and Epitome of Ophthalmoscopy and Ophthalmoscopic Diagnosis.** By DR. O. HAAB, of Zürich. *From the Third Revised and Enlarged German Edition.* Edited by G. E. DE SCHWEINITZ, M.D., Professor of Ophthalmology, Jefferson Medical College, Philadelphia. With 149 colored figures and 82 pages of text.

ADDITIONAL VOLUMES IN PREPARATION.



# Saunders' Question-Compend Series.

Price, Cloth, \$1.00 net per copy, except when otherwise noted.

"Where the work of preparing students' manuals is to end we cannot say, but the Saunders Series, in our opinion, bears off the palm at present."—*New York Medical Record*.

1. **Essentials of Physiology.** A new work in preparation.
2. **Essentials of Surgery.** By EDWARD MARTIN, M.D. Seventh edition, revised, with an Appendix and a chapter on Appendicitis.
3. **Essentials of Anatomy.** By CHARLES B. NANCREDE, M.D. Sixth edition, thoroughly revised and enlarged.
4. **Essentials of Medical Chemistry, Organic and Inorganic.** By LAWRENCE WOLFF, M.D. Fifth edition, revised.
5. **Essentials of Obstetrics.** By W. EASTERLY ASHTON, M.D. Fourth edition, revised and enlarged.
6. **Essentials of Pathology and Morbid Anatomy.** By F. J. KALTEYER, M.D. *In preparation.*
7. **Essentials of Materia Medica, Therapeutics, and Prescription-Writing.** By HENRY MORRIS, M.D. Fifth edition, revised.
- 8, 9. **Essentials of Practice of Medicine.** By HENRY MORRIS, M.D. An Appendix on URINE EXAMINATION. By LAWRENCE WOLFF, M.D. Third edition, enlarged by some 300 Essential Formulæ, selected from eminent authorities, by WM. M. POWELL, M.D. (Double number, \$1.50 net.)
10. **Essentials of Gynecology.** By EDWIN B. CRAGIN, M.D. Fourth edition, revised.
11. **Essentials of Diseases of the Skin.** By HENRY W. STELWAGON, M.D. Fourth edition, revised and enlarged.
12. **Essentials of Minor Surgery, Bandaging, and Venereal Diseases.** By EDWARD MARTIN, M.D. Second edition, revised and enlarged.
13. **Essentials of Legal Medicine, Toxicology, and Hygiene.** This volume is at present out of print.
14. **Essentials of Diseases of the Eye, Nose, and Throat.** By EDWARD JACKSON, M.D., and E. B. GLEASON, M.D. Second edition, revised.
15. **Essentials of Diseases of Children.** By WILLIAM M. POWELL, M.D. Second edition.
16. **Essentials of Examination of Urine.** By LAWRENCE WOLFF, M.D. Colored "VOGEL SCALE." (75 cents net.)
17. **Essentials of Diagnosis.** By S. SOLIS-COHEN, M.D., and A. A. ESHNER, M.D. Second edition, thoroughly revised.
18. **Essentials of Practice of Pharmacy.** By LUCIUS E. SAYRE. Second edition, revised and enlarged.
20. **Essentials of Bacteriology.** By M. V. BALL, M.D. Fourth edition, revised.
21. **Essentials of Nervous Diseases and Insanity.** By JOHN C. SHAW, M.D. Third edition, revised.
22. **Essentials of Medical Physics.** By FRED. J. BROCKWAY, M.D. Second edition, revised.
23. **Essentials of Medical Electricity.** By DAVID D. STEWART, M.D., and EDWARD S. LAWRENCE, M.D.
24. **Essentials of Diseases of the Ear.** By E. B. GLEASON, M.D. Second edition, revised and greatly enlarged.

## A NEW VOLUME.

25. **Essentials of Histology.** By LOUIS LEROY, M.D. With 73 original illustrations.

Pamphlet containing specimen pages, etc., sent free upon application.

# CLASSIFIED LIST

## OF THE

# MEDICAL PUBLICATIONS

## OF

## W. B. SAUNDERS & COMPANY

### ANATOMY, EMBRYOLOGY, HISTOLOGY.

<b>Böhm, Davidoff, and Huber</b> —A Text-Book of Histology, . . . . .	9
<b>Clarkson</b> —A Text-Book of Histology, . . . . .	10
<b>Haynes</b> —A Manual of Anatomy, . . . . .	15
<b>Heisler</b> —A Text-Book of Embryology, . . . . .	15
<b>Leroy</b> —Essentials of Histology, . . . . .	19
<b>Nancrede</b> —Essentials of Anatomy, . . . . .	37
<b>Nancrede</b> —Essentials of Anatomy and Manual of Practical Dissection, . . . . .	23

### BACTERIOLOGY.

<b>Ball</b> —Essentials of Bacteriology, . . . . .	37
<b>Crookshank</b> —A Text-Book of Bacteriology, . . . . .	11
<b>Frothingham</b> —Laboratory Guide, . . . . .	13
<b>Levy and Klemperer's</b> Clinical Bacteriology, . . . . .	20
<b>Mallory and Wright</b> —Pathological Technique, . . . . .	21
<b>McFarland</b> —Pathogenic Bacteria, . . . . .	21

### CHARTS, DIET-LISTS, ETC.

<b>Griffith</b> —Infant's Weight Chart, . . . . .	15
<b>Hart</b> —Diet in Sickness and in Health, . . . . .	15
<b>Keen</b> —Operation Blank, . . . . .	19
<b>Laine</b> —Temperature Chart, . . . . .	19
<b>Meigs</b> —Feeding in Early Infancy, . . . . .	22
<b>Starr</b> —Diets for Infants and Children, . . . . .	28
<b>Thomas</b> —Diet-Lists, . . . . .	30

### CHEMISTRY & PHYSICS.

<b>Brockway</b> —Essentials of Medical Physics, . . . . .	37
<b>Wolff</b> —Essentials of Medical Chemistry, . . . . .	37

### CHILDREN.

<b>An American Text-Book</b> of Diseases of Children, . . . . .	3
<b>Griffith</b> —Care of the Baby, . . . . .	14
<b>Griffith</b> —Infant's Weight Chart, . . . . .	14
<b>Meigs</b> —Feeding in Early Infancy, . . . . .	22
<b>Powell</b> —Essentials of Diseases of Children, . . . . .	37
<b>Starr</b> —Diets for Infants and Children, . . . . .	28

### DIAGNOSIS.

<b>Cohen and Eshner</b> —Essentials of Diagnosis, . . . . .	37
<b>Corwin</b> —Physical Diagnosis, . . . . .	11
<b>Macdonald</b> —Surgical Diagnosis and Treatment, . . . . .	20
<b>Vierordt</b> —Medical Diagnosis, . . . . .	31

### DICTIONARIES.

<b>The American Illustrated</b> Medical Dictionary, . . . . .	6
<b>The American Pocket</b> Medical Dictionary, . . . . .	6
<b>Morten</b> —Nurses' Dictionary, . . . . .	22

### EYE, EAR, NOSE, & THROAT.

<b>An American Text-Book</b> of Diseases of the Eye, Ear, Nose, and Throat, . . . . .	3
<b>De Schweinitz</b> —Diseases of the Eye, . . . . .	12
<b>Friedrich and Curtis</b> —Rhinology, Laryngology, and Otology, and their Significance in General Medicine, . . . . .	13
<b>Gleason</b> —Essentials of Diseases of the Ear, . . . . .	37
<b>Grünwald and Grayson</b> —Atlas of Diseases of the Larynx, . . . . .	34
<b>Haab and De Schweinitz</b> —Atlas of External Diseases of the Eye, . . . . .	34
<b>Jackson</b> —Manual of Diseases of the Eye, . . . . .	18
<b>Jackson and Gleason</b> —Essentials of Diseases of the Eye, Nose, and Throat, . . . . .	37
<b>Kyle</b> —Diseases of the Nose and Throat, . . . . .	19

### GENITO-URINARY.

<b>An American Text-Book</b> of Genito-Urinary and Skin Diseases, . . . . .	4
<b>Hyde and Montgomery</b> —Syphilis and the Venereal Diseases, . . . . .	16
<b>Martin</b> —Essentials of Minor Surgery, Bandaging, and Venereal Diseases, . . . . .	37
<b>Mraček and Bangs</b> —Atlas of Syphilis and the Venereal Diseases, . . . . .	34
<b>Saundby</b> —Renal and Urinary Diseases, . . . . .	25
<b>Senn</b> —Genito-Urinary Tuberculosis, . . . . .	26
<b>Vecki</b> —Sexual Impotence, . . . . .	31

### GYNECOLOGY.

<b>American Text-Book</b> of Gynecology, . . . . .	4
<b>Cragin</b> —Essentials of Gynecology, . . . . .	37
<b>Garrigues</b> —Diseases of Women, . . . . .	13
<b>Long</b> —Syllabus of Gynecology, . . . . .	20
<b>Penrose</b> —Diseases of Women, . . . . .	24
<b>Pryor</b> —Pelvic Inflammations, . . . . .	24
<b>Schaeffer and Norris</b> —Atlas of Gynecology, . . . . .	35

### MATERIA MEDICA, PHARMACOLOGY, & THERAPEUTICS.

<b>An American Text-Book</b> of Applied Therapeutics, . . . . .	3
<b>Butler</b> —Text-Book of Materia Medica, Therapeutics, and Pharmacology, . . . . .	9
<b>Cerna</b> —Notes on the Newer Remedies, . . . . .	9
<b>Morris</b> —Essentials of Materia Medica and Therapeutics, . . . . .	37
<b>Saunders' Pocket</b> Medical Formulary, . . . . .	25
<b>Sayre</b> —Essentials of Pharmacy, . . . . .	37
<b>Stevens</b> —Manual of Therapeutics, . . . . .	29
<b>Stoney</b> —Materia Medica for Nurses, . . . . .	29
<b>Thornton</b> —Dose-Book and Manual of Prescription-Writing, . . . . .	37

**MEDICAL JURISPRUDENCE AND TOXICOLOGY.**

**Chapman**—Medical Jurisprudence and Toxicology, . . . . . 10  
**Golebiewski and Bailey**—Atlas of Diseases Caused by Accidents, . . . . . 35  
**Hofmann and Peterson**—Atlas of Legal Medicine, . . . . . 34

**NERVOUS AND MENTAL DISEASES, ETC.**

**Chapin**—Compendium of Insanity, . . . . . 9  
**Church and Peterson**—Nervous and Mental Diseases, . . . . . 10  
**Shaw**—Essentials of Nervous Diseases and Insanity, . . . . . 37

**NURSING.**

**Davis**—Obstetric and Gynecologic Nursing, . . . . . 11  
**Griffith**—The Care of the Baby, . . . . . 14  
**Hart**—Diet in Sickness and in Health, . . . . . 15  
**Meigs**—Feeding in Early Infancy, . . . . . 22  
**Morten**—Nurses' Dictionary, . . . . . 22  
**Stoney**—Materia Medica for Nurses, . . . . . 29  
**Stoney**—Practical Points in Nursing, . . . . . 30  
**Stoney**—Surgical Technic for Nurses, . . . . . 30  
**Watson**—Handbook for Nurses, . . . . . 32

**OBSTETRICS.**

**An American Text-Book** of Obstetrics, . . . . . 4  
**Ashton**—Essentials of Obstetrics, . . . . . 37  
**Boislinière**—Obstetric Accidents, . . . . . 8  
**Dorland**—Manual of Obstetrics, . . . . . 12  
**Hirst**—Text-Book of Obstetrics, . . . . . 16  
**Norris**—Syllabus of Obstetrics, . . . . . 23  
**Schaeffer and Edgar**—Atlas of Obstetrical Diagnosis and Treatment, . . . . . 35

**PATHOLOGY.**

**An American Text-Book** of Pathology, . . . . . 5  
**Dürk and Hektoen**—Atlas of Pathologic Histology, . . . . . 35  
**Kalteyer**—Essentials of Pathology, . . . . . 37  
**Mallory and Wright**—Pathological Technique, . . . . . 21  
**Senn**—Pathology and Surgical Treatment of Tumors, . . . . . 27  
**Stengel**—Text-Book of Pathology, . . . . . 28  
**Warren**—Surgical Pathology and Therapeutics, . . . . . 32

**PHYSIOLOGY.**

**An American Text-Book** of Physiology, . . . . . 5  
 —Essentials of Physiology, . . . . . 37  
**Raymond**—Manual of Physiology, . . . . . 25  
**Stewart**—Manual of Physiology, . . . . . 29

**PRACTICE OF MEDICINE.**

**An American Year-Book** of Medicine and Surgery, . . . . . 7  
**Anders**—Text-Book of the Practice of Medicine, . . . . . 7  
**Eichhorst**—Practice of Medicine, . . . . . 13  
**Lockwood**—Manual of the Practice of Medicine, . . . . . 20  
**Morris**—Essentials of Practice of Medicine, . . . . . 37  
**Salinger and Kalteyer**—Modern Medicine, . . . . . 25  
**Stevens**—Manual of Practice of Medicine, . . . . . 29

**SKIN AND VENEREAL.**

**An American Text-Book** of Genito-Urinary and Skin Diseases, . . . . . 4  
**Hyde and Montgomery**—Syphilis and the Venereal Diseases, . . . . . 16  
**Martin**—Essentials of Minor Surgery, Bandaging, and Venereal Diseases, . . . . . 37  
**Mracek and Stelwagon**—Atlas of Diseases of the Skin, . . . . . 34  
**Stelwagon**—Essentials of Diseases of the Skin, . . . . . 37

**SURGERY.**

**An American Text-Book** of Surgery, . . . . . 5  
**An American Year-Book** of Medicine and Surgery, . . . . . 7  
**Beck**—Fractures, . . . . . 8  
**Beck**—Manual of Surgical Asepsis, . . . . . 8  
**Da Costa**—Manual of Surgery, . . . . . 11  
**International Text-Book** of Surgery, . . . . . 17  
**Keen**—Operation Blank, . . . . . 19  
**Keen**—The Surgical Complications and Sequels of Typhoid Fever, . . . . . 18  
**Maddonald**—Surgical Diagnosis and Treatment, . . . . . 20  
**Martin**—Essentials of Minor Surgery, Bandaging, and Venereal Diseases, . . . . . 37  
**Martin**—Essentials of Surgery, . . . . . 37  
**Moore**—Orthopedic Surgery, . . . . . 22  
**Nancrede**—Principles of Surgery, . . . . . 23  
**Pye**—Bandaging and Surgical Dressing, . . . . . 24  
**Scudder**—Treatment of Fractures, . . . . . 26  
**Senn**—Genito-Urinary Tuberculosis, . . . . . 26  
**Senn**—Practical Surgery, . . . . . 27  
**Senn**—Syllabus of Surgery, . . . . . 27  
**Senn**—Pathology and Surgical Treatment of Tumors, . . . . . 27  
**Warren**—Surgical Pathology and Therapeutics, . . . . . 32  
**Zuckerkindl and Da Costa**—Atlas of Operative Surgery, . . . . . 34

**URINE & URINARY DISEASES.**

**Ogden**—Clinical Examination of the Urine, . . . . . 23  
**Saundby**—Renal and Urinary Diseases, . . . . . 25  
**Wolff**—Essentials of Examination of Urine, . . . . . 37

**MISCELLANEOUS.**

**Abbott**—Hygiene of Transmissible Diseases, . . . . . 7  
**Bastin**—Laboratory Exercises in Botany, . . . . . 8  
**Golebiewski and Bailey**—Atlas of Diseases Caused by Accidents, . . . . . 35  
**Gould and Pyle**—Anomalies and Curiosities of Medicine, . . . . . 14  
**Grafstrom**—Massage, . . . . . 14  
**Keating**—How to Examine for Life Insurance, . . . . . 18  
**Pyle**—A Manual of Personal Hygiene, . . . . . 24  
**Saunders' Medical Hand-Atlases**, . . . . . 33, 34, 35  
**Saunders' Pocket Medical Formulary**, . . . . . 25  
**Saunders' Question-Compend**, . . . . . 36, 37  
**Stewart and Lawrence**—Essentials of Medical Electricity, . . . . . 37  
**Thornton**—Dose-Book and Manual of Prescription-Writing, . . . . . 37  
**Van Valzah and Nisbet**—Diseases of the Stomach, . . . . . 31

10/10















